Digitized by Illinois College of Optometry

Digitized by Illinois College of Optometry

Digitized by Illinois College of Optometry

Digitized by Illinois College of Optometry

Digitized by Illinois College of Optometry

Digitized by Illinois College of Optometry

Digitized by Illinois College of Optometry

Digitized by Illinois College of Optometry

A TEXT-BOOK

ON

DISEASES OF THE EYE

BY

HENRY D. NOYES, A.M., M.D.

Professor of Ophthalmology and Otology in Bellevue Hospital Medical College; Executive Surgeon to the New York Eye and Ear Infirmary; recently President of the American Ophthalmological Society; Member of the New York Ophthalmological Society; recently Vice-President of the New York Academy of Medicine; Permanent Member of the New York State Medical Society; Member of the American Medical Association, etc., etc.

Second and Revised Edition

ILLUSTRATED BY 5 CHROMO-LITHOGRAPHIC PLATES, 10 PLATES IN BLACK AND COLORS, AND 269 WOOD-ENGRAVINGS

NEW YORK

WILLIAM WOOD & COMPANY

1896

Digitized by Illinois College of Optometry

Copyrighted, 1894
WILLIAM WOOD & COMPANY

Digitized by Illinois College of Optometry

Carl F. Shepard Memorial Library
Illinois College of Optometry
14014

PREFACE TO SECOND EDITION.

In revising this treatise numerous additions have been made to render it more complete. For example, those parts of cerebral anatomy and pathology which have a bearing upon the eye have been discussed at unusual length for such a work; this is true both for the motor nerves and for the optic nerves. Some chapters have been considerably modified and some have been rewritten; for example, those on granular conjunctivitis, asthenopia, sympathetic ophthalmia, glaucoma, cataract, hemianopsia, etc. Throughout the book the attempt has been made to set forth the most recent and well-established views in ophthalmology, and references to authorities have been abundantly inserted that readers may be aided in further research. The writer's judgment on new suggestions has been freely given on points where he has opinions. He is indebted to his friend, Dr. John E. Weeks, for the pathological statements respecting so-called Bright's retinitis and for his drawings which illustrate it. For preparation of the index he again acknowledges with thanks the painstaking work of Dr. D. W. Hunter. Additional cuts and plates have been inserted, and attention is called to the list on p. xiii. The author has been much gratified by the kind reception which his work has met, and has for this reason sought in this edition to make it still more worthy of acceptance.

Digitized by Illinois College of Optometry

Digitized by Illinois College of Optometry

PREFACE TO THE FIRST EDITION.

THE present work has grown out of a treatise on diseases of the eye, published in December, 1881, in Wood's Library of Standard Medical Authors. The same arrangement of subjects is adhered to: presenting in the first part the general anatomy and physiology of the eye with its functional disorders, and in the second part its inflammations and organic textural changes, and the lesions of the accessory parts. That this order is both scientific and natural seems evident. The spirit of the book is clinical, but an adequate preparation for clinical and practical work demands a wide range of preliminary knowledge. This is true of all branches of medicine. To the study and experience needed in general medicine, must be added for proper treatment of troubles of the eye, a considerable acquaintance with physics, mathematics, and physiological optics.

The knowledge which they furnish finds its chief application in unravelling functional disorders of sight, viz., errors of refraction and accommodation, and motility. These subjects as well as the operative surgery of the eye will always constitute a field of special practice. But in dealing with pathological conditions or inflammations, the physician must take his share with the ophthalmologist. Nor can he refuse to take in hand the ophthalmoscope, because it is not only essential to discovery of deep lesions of the organ, but its revelations often have an important bearing upon remote pathological conditions.

In accordance with the practical intent of the book, mathematical formulæ have been omitted; pathology and microscopic anatomy have been presented so far as seemed helpful to an intelligent account of morbid processes; the share which micro-organisms have in exciting diseases of the eye, has been fully recognized; no little labor has been spent in setting forth its intimate relations to the

Digitized by Illinois College of Optometry

brain and nervous system, as both illustrations and descriptions testify; the participation of the eye in numerous general diseases or lesions, of remote organs, such as the kidneys, the uterus, the heart, etc., and the reflex influence which the eye can sometimes exert upon distant parts have been set forth.

The writer has quoted his own cases and experiences, and stated his own opinions; he has familiarized himself with the work of others, not only in their writings, but pretty largely by personal acquaintance, and drawn freely upon their labors, as may be seen by the references in the text, and by the bibliography.

Of the illustrations many are familiar, while not a few have either not hitherto appeared in ophthalmic text-books, or are original.

In depicting diseases of the fundus oculi, black and white have been used for many of the ordinary lesions, while colored plates have been reserved for special conditions, some of which are familiar and others unusual.

The liberality of the publishers in the number and quality of the illustrations has been a source of gratification and will be appreciated.

For the compilation of the copious indices acknowledgment is due to the author's friend, Dr. D. W. Hunter. In them references will be found to passages where the connection of general diseases with eye pathology is mentioned, and one will need only to look under the head of such diseases for the ocular complication.

To the medical profession, who have greatly honored him with their confidence, and to the classes of Bellevue Hospital Medical College whom he has taught and who have rewarded his efforts by their attention and respect, the author offers this volume as an attempt to discharge a great debt.

Digitized by Illinois College of Optometry

CONTENTS.

PART FIRST.

CHAPTER I.

GENERAL ANATOMY OF THE GLOBE.

PAGE

Measurements—Component Structures—Vessels of the Globe and their Relations to the Diagnosis of Diseases of the Eye, . . 1–9

CHAPTER II.

GENERAL PHYSIOLOGY OF THE EYE.

Refraction: Cardinal Points—Optic Axis: Visual Line: Line of Fixation: Angle Alpha: Angle Gamma—Accommodation—Functions of the Retina: Blind Spot—Visual Acuity—Form Sense—Test Types—Visual Field: Perimeters: Eccentric Vision—Color Sense—Daltonism: Color Blindness—Light Sense: Photometer of Förster: Phosphenes: Vascular Image of Purkinje—Visual Purple, ... 10–34

CHAPTER III.

HOW TO EXAMINE THE EYE.

External Inspection—Oblique Illumination—Tension—Mobility—Anæsthetics—Functional Examination, ... 35–38

CHAPTER IV.

THE OPHTHALMOSCOPE.

Instruments, their Principles and Varieties—The Fundus Oculi in Health, ... 39–52

CHAPTER V.

GLASSES.

Spherical: Cylindric: Toric—Arrangement and Nomenclature—Dioptries: Prisms, ... 53–60

CHAPTER VI.

ACCOMMODATION AND ITS ERRORS.

Presbyopia—Second Sight—Spasm—Paralysis and Paresis, . . 61–68

Digitized by Illinois College of Optometry

CHAPTER VII.

ERRORS OF REFRACTION.

PAGE

Ametropia, viz.: Hypermetropia, Myopia, Astigmatism—Diagnosis of Refractive Errors—Subjective and Objective Methods—Mydriatics—Ophthalmoscopic Optometry—Schmidt-Rimpler's Method—Shadow Test—Thomson's Method. *Hypermetropia:* Anatomical Characteristics: Symptoms: Complications: Diagnosis: Prognosis: Treatment: Length of Axis in H. *Myopia:* Length of Axis in M.: Causes—Functional Disturbances and Pathological Anatomy—Prognosis: Diagnosis: Prophylaxis: Treatment. *Astigmatism:* Definition: Varieties: Symptoms: Dr. Thomas Young: Stokes' Lens: Diagnosis by Ophthalmoscope—by Shadow Test—by Ophthalmometer of Javal and Schiotz: Disc of Placido—Anisometropia—Incidental Effects of Glasses, ... 69–131

CHAPTER VIII.

BINOCULAR VISION.

Anatomy and Physiology of Ocular Muscles—Horopter—Homonymous and Heteronymous Images: *Paralysis* of Muscles: Symptoms: Diagnosis—Special Paralyses—Etiology: Origin of Nerves animating Ocular Muscles: their Nuclei—Basal, Nuclear, Orbital, Cortical Paralysis—Prognosis—Treatment—Prisms, Tenotomy, Advancement—the Oculo-orbital Fascia—Congenital Paralysis—*Spasm* of Muscles—*Nystagmus—Conjugate Deviation*, ... 132–176

CHAPTER IX.

STRABISMUS CONCOMITANS.

Varieties—Measurement—Etiology—Amblyopia—Course—Cause of Strabismus—Treatment: Atropine, Eserine, Glasses, Operation: its Mechanism and Ultimate Result—Strabismus deorsum vergens, and sursum vergens, ... 177–196

CHAPTER X.

ASTHENOPIA.

Accommodative—Properties and Uses of Prisms—Muscular—the Metre-angle, how Measured, its Relation to Prisms—Adduction and Abduction—General Divisions and Considerations—Subjective Symptoms: Objective Symptoms—Tests by Prisms—The Prism Carrier—Perimetric Examination—Retinal Anæsthesia—Nasal Disorders—Treatment—Prisms—Operations, . 197–230

PART SECOND.

CHAPTER I.

GENERAL CONSIDERATIONS.

General Treatment—Shades—Protective Glasses—Bandages—Asepsis: Antisepsis—Anæsthetics: Cocaine—Instruments—Mydriatics: Myotics—Collyria—Means of Reducing Tension, . . 231–246

Digitized by Illinois College of Optometry

CHAPTER II.

THE EYELIDS AND CONJUNCTIVA.

PAGE

Anatomy—Blepharitis marginalis—Hordeolum—Chalazion—Phlegmon—Tarsitis—Eczema—Xanthelasma—Molluscum contagiosum—Herpes zoster Ophthalmicus—Epithelioma, Lupoid—Nævi—Diseases of Eyelashes—Entropium—Ectropium—Blepharoplasty—Blepharophimosis—Cantholysis—Canthoplasty—Tarsoraphy—Injuries and Lacerations—Coloboma—Epicanthus—Spasm of Orbicularis—Paralysis of Orbicularis—Ptosis—Burns—Symblepharon—Anchyloblepharon, ... 247–291

CHAPTER III.

THE LACHRYMAL APPARATUS.

Anatomy—Diseases of Lachrymal Gland—Dacryocystitis—Chronic—Acute—Lachrymal Fistula—Leptothrix lachrymalis, . . 292–307

CHAPTER IV.

THE CONJUNCTIVA.

Anatomy and Physiology—*Conjunctivitis*—Hyperæmia Palpebralis—Conjunctivitis Simplex, Catarrhalis, Symptomatic, Metastatic, Catarrho-rheumatic—Purulenta, Neonatorum, Gonorrhoica—Plastica: Croupous—Diphtheritic, Acute and Chronic—Granulosa: Trachoma—Papillary—Follicularis—Treatment—Xeroma—Sequelæ—*Morbid Growths: Vernal Catarrh—Phlyctenulæ: Herpes: Pemphigus; Traumatic Conjunctivitis—Ecchymosis—Pterygium*, ... 308–370

CHAPTER V.

THE CORNEA.

Anatomy—Physiology—Pathology—Keratitis: Phlyctenula: Herpes: Pemphigus: Keratitis vasculosa—Malarial Keratitis: Keratitis Interstitialis: Syphilitica—Suppurativa—Ulcerativa—Purulenta discreta—Ulcus Corneæ Serpens: Neuroparalytic Keratitis: Kerato-malacia—Ulcers—Keratitis postica, Dendritica, or Arborescens—Mycotica, Interpalpebral Degeneration—Sclerosis—Arcus senilis: Sequelæ—Opacity: Fistula—Staphyloma, Cornea conica: Morbid Growths, ... 371–423

CHAPTER VI.

THE SCLERA.

Anatomy—Episcleritis—Scleritis—Sclero-keratitis—Staphyloma, . 424–429

CHAPTER VII.

THE IRIS.

Anatomy and Physiology—Mydriasis—Myosis—Hippus—Iridodonesis—Congenital Defects: Albinism—Irideremia—Coloboma Membrana pupillaris—Iritis: Serosa, Spongiosa, Plastica, Suppurativa—Complications: Symptoms—Sequelæ—Causes—Prognosis—Treatment—Varieties: Syphilitic, Rheumatic, Gouty, Gonorrhœal—Tumors—Tubercles—Sarcoma—Cysts, . 430–453

Digitized by Illinois College of Optometry

CHAPTER VIII.

OPERATIONS ON THE IRIS.

PAGE

Iridectomy—Iridotomy—Iridorhexis—Iridavulsion—Corelysis—Iridodesis, ... 454–461

CHAPTER IX.

THE CILIARY BODY.

Anatomy—Ciliary Muscle — Cyclitis : Serous, Plastic, Purulent, Acute and Chronic : Traumatic—Hypotony—Ophthalmo-malacia: Morbid Growths, ... 462–470

CHAPTER X.

THE CRYSTALLINE LENS.

Anatomy — Development — Images of Purkinje — Arcus senilis Lentis—Dislocation, ... 471–477

CHAPTER XI.

CATARACT.

Pathology — Symptoms — Examination — Varieties — Diagnosis—Complications — Prognosis — Treatment—Soft Cataract—Discission—Simple Linear Extraction—Extraction of Hard Cataract, with Iridectomy, without Iridectomy—Secondary Cataract--Glasses for Aphakia, ... 478–511

CHAPTER XII.

THE VITREOUS BODY.

Anatomy—Hyalitis—Persistent Hyaline Artery—Synchisis Scintillans—Muscæ Volitantes — Cysticercus — Membranes — Hemorrhage—Foreign Bodies, ... 512–518

CHAPTER XIII.

WOUNDS AND INJURIES.

Contusions and Blows—Wounds—Foreign Bodies—The Magnet—Burns, ... 519–530

CHAPTER XIV.

SYMPATHETIC OPHTHALMIA.

Irritation—Inflammation—Causes—Stages—Prognosis—Symptoms—Neuro-retinitis—Mode of Transmission—Treatment—Iridectomy—Enucleation—Optico-ciliary Neurectomy—Exenteration—Risk of Enucleation, ... 531–547

CHAPTER XV.

GLAUCOMA.

Degrees of Tension—Glaucoma Simplex—Symptoms—Development—Glaucoma Acutum—Subacutum—Chronicum—Hemorrhagicum — Secondarium — Buphthalmus — Diagnosis—Prognosis—

Digitized by Illinois College of Optometry

PAGE

Etiology and Pathogenesis — Pathology—Treatment—Iridectomy — Sclerotomy — Posterior Sclerotomy—Malignant Glaucoma—Cystoid Cicatrix—Rationale of Iridectomy—Results, . 548–572

CHAPTER XVI.

THE CHOROIDEA.

Anatomy—Albinism—Coloboma—Choroiditis—Pathology— Colloid Degeneration—Symptoms and Subdivisions—Metamorphopsia —Megalopsia—Micropsia—Treatment—Choroiditis Metastatica —Panophthalmitis Suppurativa—Laceration of the Choroid—Hemorrhage—Detachment—Tubercles—Tumors—Ossification, 573–593

CHAPTER XVII.

THE RETINA.

Minute Anatomy—Opaque Nerve Fibres—Coloboma of the Macula —Hyperæmia—Pulsations of Arteries and Veins—Anæmia—Spasm of Arteries—Ischæmia—Embolism and Thrombosis—Hemorrhage—Retinitis Apoplectica—Miliary Aneurisms—Retinitis: various appearances—Etiology—Acute Traumatic Retinitis—Retinitis Simplex—Albuminurica under various conditions — Pathology — Glycosurica — Leucocythæmica — Syphilitica—Proliferans — Punctata Albescens—Pigment Degeneration—Neuro-retinitis pigmentosa—Detachment—Pathogenesis—Glioma—Pseudo-glioma, ... 594–640

CHAPTER XVIII.

THE OPTIC NERVE.

Anatomy and Physiology of Optic Nerve, and of Brain connected with it—Coloboma of Sheath—Opaque Nerve Fibres—Connective Tissue on Disc—Hyperæmia—Anæmia—Hemorrhage—Papillitis—Neuro-retinitis—Neuritis Hemorrhagica—Peri-neuritis—Subjective Symptoms—Pathological Anatomy—Etiology — Pathogenesis — Prognosis— Treatment — Retrobulbar Neuritis: Chronic, Acute, Toxic, Alcoholic, Tobacco—Atrophy of Optic Nerve—Morbid Anatomy, ... 641–693

CHAPTER XIX.

AMBLYOPIA AND AMAUROSIS.

Traumatic—Concussion of Spinal Cord—By Lightning, from Hemorrhage—Toxic: by Quinine, by Salicylic Acid—Uræmic—Glycosuric: by Pregnancy—Hysterical—Dyslexia, Paralexia, Alexia —Hemeralopia—Snow-blindness—Dental Amblyopia—Hyperæsthesia—Hemianopia: monocular, homonymous, binocular, nasal, bitemporal—Causes—Diagnosis—Amaurosis in Young Children — Undiscovered Monocular Blindness — Simulated Blindness, ... 694–721

CHAPTER XX.

THE ORBIT.

Anatomy — Periostitis Orbitæ— Cellulitis—Phlegmon—Inflammation of Oculo-orbital Fascia—Thrombosis of Veins and of Cav-

Digitized by Illinois College of Optometry

PAGE

ernous Sinus—Tumors—Tumors of Optic Nerve—Extenteratio Orbitæ—Pulsating Exophthalmus—Enophthalmus Traumaticus—Empyema of Frontal Sinus—Hemorrhage into Orbit—Wounds and Injuries—Fractures—Wound of Optic Nerve — Foreign Bodies in Orbit—Exophthalmic Goitre, ... 722–767

CHAPTER XXI.

USE OF ARTIFICIAL EYES.

Mules' Artificial Vitreous, ... 768–770

CHAPTER XXII.

STATISTICS OF EYE DISEASES.

Relative Proportion of Eye Diseases—Cohn—Causes of Blindness, Magnus, etc., ... 771–776

BIBLIOGRAPHY, ... 777–780

Digitized by Illinois College of Optometry

LIST OF ILLUSTRATIONS.

FIG.			PAGE
1.	Section of Eye, horizontal	Heitzmann.	3
2.	Ciliary Region	Heitzmann.	4
3.	Section of Eye showing Uvea	Merkel, G. and S.	5
4.	Blood-vessels of Eye	Leber.	7
5.	Refraction by a spherical Surface		11
6.	Cardinal Points	Landolt.	13
7.	Angle Alpha, angle Gamma, etc	Landolt.	14
8.	Reflex from Cornea and Lens	Helmholtz.	16
9.	Changes during Accommodation	Landolt.	17
10.	Relative Accommodation	Loring.	19
11.	Retina: Macula Lutea	Stricker.	20
12.	Blind Spot	Helmholtz.	21
13.	Perimeter	Priestley Smith.	25
14.	Boundaries of Color Sense	Landolt.	27
15.	Optogram on Retina	Ayers.	33
16.	Oblique Illumination	Noyes.	36
17.	Ophthalmoscopy—direct Method	Noyes.	40
18.	Ophthalmoscopy—indirect Method	Noyes.	41
19.	Loring's Ophthalmoscope	Loring.	42
20.	Loring's Ophthalmoscope	Loring.	43
21.	Noyes' Ophthalmoscope	Noyes.	45
22.	Optic Disc Surface and Section	Landolt.	48
23.	Blood-vessels of Retina	Leber.	49
24.	Varieties of spherical Lenses	Ganot.	53
25.	Cylindric Lenses	Noyes.	54
26.	Nachet's Spectacle Frame	Tiemann & Co.	58
27.	Emmetropia, Hypermetropia and Myopia	Brown.	69
28.	Course of parallel Rays in convex Lens	Ganot.	69
29.	Parallax of Vessels in excavated Disc		75
30.	Explanation of Shadow Test	Nettleship.	77
31.	Explanation of Shadow Test	Nettleship.	78
32.	Scheiner's Test	Follin.	82
33.	Myopia with Crescent	Nettleship.	97
33*a*.	Section of Myopic Eye	Nettleship.	97
34.	Myopia with choroidal Lesions	Jaeger.	98
35.	Supratraction of Optic Fibres in Myopia	Weiss.	98
36.	Myopia, Choroidal Crescent	Jaeger.	99
37.	Myopia, circum-papillary Atrophy	Jaeger.	100
38.	Myopia, Lesion at Macula	Jaeger.	101
39, 40.	Course of Rays through cylindric Lens	Fick.	113
41, 42, 43, 44, 45.	Varieties of Astigmatism	Hartridge.	115

Digitized by Illinois College of Optometry

FIG.		PAGE
46, 47.	Tests for Astigmatism.....Green.	119
48.	Tests for Astigmatism.....Green.	120
49.	Ophthalmometer of Javal and Schiotz.....Noyes.	124
50, 51.	Images seen by Ophthalmometer.....Javal.	125
52.	Disc of Placido.....Noyes.	126
53.	Axes of ocular Muscles.....Landolt.	133
54.	Converging visual Lines.....Follin.	136
55.	Diverging visual Lines.....Follin.	137
56, 57, 58, 59.	Images in muscular Paralysis.....Zehender.	142
60, 61, 62, 63.	Images in muscular Paralysis.....Zehender.	143
64.	Section of Skull in frontal Plane through Sphenoid.....Henle.	145
65.	Base of Brain, Pons and Medulla.....	146
66.	Optic Commissure and Tract.....Merkel, G. and S.	147
67.	Oblique view of sagittal Section of Mid-brain.....Henle.	148
68.	Diagram—Lesion of Pons with alternating motor Paralysis..Starr.	149
69.	Diagram—Lesion of Pons with alternating Anæsthesia....Starr.	149
70.	Section of caudal Edge of anterior Corp. Quadrigem..Obersteiner.	150
71.	Sagittal Section of Medulla modified from Edinger.....	151
72.	Diagram of Nuclei in Medulla.....Knies.	152
73.	Nuclei of third and fourth Nerves.....Perlia.	153
74.	Nuclei of third and fourth Nerves.....Edinger.	153
75.	A. Section of Brain on median Plane.....Starr.	156
	B. Localization Centres.....Starr.	156
76.	Horizontal Section of internal Capsule.....M. Foster.	157
77.	Strabismus Forceps.....	189
78.	Strabismus Hook.....	189
79.	Refraction by a Prism.....Ganot.	198
80.	Displacement of Object by Prism.....	199
81.	Adduction by Prisms.....	199
82.	Abduction by Prisms.....	200
83.	Metric Angle.....Nagel.	203
84, 85.	Prisms in Series for testing at a remote distance.....Noyes.	211
86.	Prism-Carrier for testing at the working distance.....Noyes.	213
87.	Speculum, flat View.....Noyes.	238
88.	Speculum, profile View.....Noyes.	239
89.	Tarsi Palpebrarum.....Schwalbe.	247
90.	Exterior of Eye and Lids.....Schwalbe.	248
91.	Section through Globe and Orbit.....Schwalbe.	249
92.	Section of upper Lid.....Schwalbe.	251
93.	Eye-lid Clamp Forceps.....Noyes.	254
94.	Operation for spasmodic Entropium.....Meyer.	264
95.	Hotz's Operation for Entropium.....Hotz.	266
96.	Green's Operation for Entropium.....Green.	266
97.	Ectropium at inner Canthus.....Galezowski.	269
98, 99, 100, 101.	Operations for Ectropium.....Meyer.	270
102, 103.	Blepharoplasty.....Noyes.	274
104, 105, 106, 107.	Blepharoplasty.....Noyes.	275
108.	Blepharoplasty.....Noyes.	276
109, 110, 111, 112.	Blepharoplasty.....Noyes.	277
113.	Laceration of upper Lid.....Lawson.	279
114.	Wound of lower Lid, etc.....Noyes.	279
115, 116.	Operation for Ptosis.....Wecker.	286

Digitized by the College of Optometry

FIG.		PAGE
117, 118.	Symblepharon.....Meyer.	289
119.	Abscess of lachrymal Sac.....Noyes.	296
120.	Empyema of frontal Sinus.....Noyes.	297
121, 122.	Lachrymal Knives.....	300
123, 124, 125, 126, 127.	Lachrymal Probes.....	300
128.	Gouge for lachrymal Duct.....Noyes.	303
129.	Abscess of lachrymal Sac.....Noyes.	305
130.	Desmarres' Elevators.....	324
131.	Gonococci.....Michel.	326
132.	Trachoma Follicles.....Fuchs.	345
133.	Forceps for follicular Trachoma.....Noyes.	349
134.	Squeezing follicular Trachoma.....Noyes.	349
135.	Gibson's Forceps for everting Lids.....	353
136.	Pterygium.....	369
137.	Corneal Corpuscles.....Stricker.	373
138, 139.	Keratitis Mycotica.....Haab.	376
140.	Ulcer of Cornea.....Galezowski.	380
141.	Herpes Corneæ.....Haab.	384
142, 143.	Teeth in hereditary Syphilis and from Mal-nutrition..Noyes.	391
144.	Keratitis with Hypopyum.....Galezowski.	397
145.	Keratitis Postica.....Galezowski.	408
146.	Keratitis Dendritica (vel Arborescens).....Hansen-Grut.	409
147.	Tattooing Needle.....	413
148, 149, 150.	Staphyloma Corneæ.....	415
151.	Operation for Staphyloma Corneæ.....Noyes.	418
152.	Epithelioma Corneæ.....Noyes.	423
153, 154.	Membrana Pupillaris perseverans.....	439
155.	Congestion in Iritis.....	441
156.	Posterior Synechiæ.....Sichel, Jr.	441
157, 158.	Occlusion and Exclusion of Pupil.....Sichel, Jr.	444
159, 160, 161.	Forceps, Tyrrell's Hook, and Lance Knives.....	455
162.	Matthieu's Iris Forceps.....	456
163, 164.	Iridectomy.....Meyer.	457
165, 166.	Iridectomy.....Meyer.	458
167.	Wecker's Forceps-scissors.....Wecker.	459
168, 169, 170.	Iritomy Knife-needles.....	460
171, 172.	Ciliary Muscle in H. and M.....Iwanoff.	463
173, 174.	Plastic Cyclitis.....Alt.	465
175, 176.	Irido-Cyclitis.....Alt.	465
177, 178.	Plastic Cyclitis.....Alt.	465
179, 180, 181.	Results of Cyclitis.....Noyes.	468
182.	Eye of embryo Calf at third Month.....Kölliker.	471
183.	Images from Cornea and Lens.....Helmholtz.	472
184.	Dislocation of Lens..... Lawson.	474
185.	Zonular (laminated) Cataract.....Meyer.	483
186, 187, 188.	Congenital Cataract.....Wilde.	484
189, 190.	Congenital Cataract.....Wilde.	484
191.	Anterior Polar Cataract.....Wilde.	484
192.	Discission of Cataract.....Meyer.	490
193.	Linear Extraction of Cataract upward.....Wolfe.	492
194.	Linear Extraction of Cataract outward.....Meyer.	493
195.	Section of Cornea in various Methods of Cataract Extraction..... Sichel, Jr.	496

Digitized by the Boston College of Optometry

FIG.		PAGE
196.	Graefe's linear Extraction—making the Section.....Noyes.	497
197.	Graefe's linear Extraction—making the Section .....Meyer.	498
198.	Wire Retractor for upper Lid .....Noyes.	499
199.	Cataract Knife.....	504
200, 201.	Cystitome and Spatula : Fixation Bident	504
202.	Secondary Cataract .....Galezowski.	508
203, 204, 205.	Knife, Needles, and Hook for membranous Cataract.....	509
206.	Persistent hyaloid Artery.....Little.	513
207.	Connective Tissue in Vitreous.....Jaeger.	514
208, 209.	Irido-dialysis : Rupture of Sclera .....Lawson.	519
210.	Wound of Cornea, Eyelid and Cheek.....Noyes.	522
211.	Appliance for oblique Illumination .....Noyes.	523
212.	Iridectomy after sympathetic Ophthalmia .....Lawson.	539
213.	Myopia and Glaucoma .....Jaeger.	549
214, 215.	Excavation of optic Nerve : Glaucoma.....Jaeger.	550
216.	Sclerotomy—downward or bilateral.....Lawson.	565
217.	Colloid Deposits in Choroid.....Müller.	575
218.	Patch of Choroiditis.....Michel.	576
219.	Exudative Choroiditis ; peripheral.....Jaeger.	Plate
220, 221, 222, 223, 224.	Atrophic Choroiditis.....Jaeger.	Plate
225.	Choroiditis atrophica in Myopia.....Jaeger.	582
226.	Diagram of minute Structure of Retina.....Stricker.	595
227.	Minute Anatomy of Retina .....Perrin et Poncet.	596
228.	Embolism of Arteria Centralis Retinæ .....Magnus.	602
229.	Dilated Choroidal Capillaries.....Perrin et Poncet.	605
230.	Section of Retina in Morbus Brightii.....Weeks.	617
231.	Retinis albuminurica .....Weeks.	618
232.	Section of Iris in Albuminuric Retinitis.....Weeks.	619
233.	Choroidal Lesion in Albuminuric Retinitis.....Perrin et Poncet.	619
234.	Retinitis Pigmentosa.....Meyer.	628
235.	Optic Commissure and Tract.....Merkel, G. and S.	641
236.	Medulla Oblongata and Pons.....Edinger.	642
237.	Diagram of Optic Tractus Fibres, etc.....Edinger.	643
238.	Scheme of Cerebral visual Apparatus.....Obersteiner.	646
239.	Sections of Occipital Lobe, to show visual centre.....Henschen	648
240.	Schweigger's Perimeter.....Schweigger.	653
241.	Transverse Section of Skull.....Henle.	654
242, 243.	Cerebral Convolutions.....Gowers.	655
244.	Localization Areas on Brain Surface.....Starr.	656
245.	Functional Centres of Brain Surface.....Berger.	656
246.	Connective Tissue on Optic Disc.....Massillon.	659
247.	Hemorrhage within Optic Nerve Sheath.....Priestley-Smith.	661
248.	Papillitis—Section of Globe..... Allbutt.	663
249.	Distention of Optic Sheath in Neuritis..Pagenstecher and Genth.	667
250.	Optic Neuritis—Microscopic Section ....Pagenstecher and Genth.	668
251.	Optic Neuritis—Longitudinal Section ....Edmunds and Lawford.	669
252.	Optic Neuritis—Cross Section..... ...Edmunds and Lawford.	670
253.	Optic Neuritis—Cross Section.....Uhthoff.	685
254.	Optic Neuritis—Cross Section.....Uhthoff.	685
255.	Atrophy of Optic Nerve.....Jaeger.	690
256.	Section of Optic Nerve, Normal.....Perrin et Poncet.	691
257.	Section of Optic Nerve, Atrophic.....Perrin et Poncet.	691

Digitized by the Internet Archive of Ophthalmology

FIG.		PAGE
258.	Diagram to illustrate left Hemianopia .....Seguin.	715
259.	Angioma of Orbit and neighboring Skin. .....Bull.	739
260.	Plastic Operation for Occlusion of Orbit.....Noyes.	742
261.	Empyema of Frontal Sinus.....Noyes.	749
262.	Diagram of origin of Ocular Muscles at Orbital Apex.....Merkel.	755
263.	Section of Muscles at Apex of Orbit .....Merkel.	755
264.	Section of Skull through Optic Canals.....Berger and Tyrman.	758
265.	Patient with Foreign Body (Breech-pin) in Orbit, etc. .....Noyes.	762
266.	The above-mentioned Foreign Body (natural size)..... ...Noyes.	763
267.	Skull prepared to show the Position of the Breech-pin in the Orbit and Cranial Cavity—the Separated frontal Bone Exhibits the Place of Trephining for Cerebral Abscess .....Noyes.	763
268.	Exophthalmic Goitre... ....Noyes.	764
269.	Artificial Eyes	769

Digitized by Illinois College of Optometry

Digitized by Illinois College of Optometry

DISEASES OF THE EYE.

PART FIRST.

CHAPTER I.

GENERAL ANATOMY OF THE GLOBE.

THE eyeball is a spheroid, rotating in the orbit, upon a cushion of fat and fibrous tissue, and protected by the eyelids. The fibrous membrane on which it rests, called *oculo-orbital fascia* or *capsule of Tenon,* is shaped into a cup and moistened by serum: and in front it is lubricated by secretion from its covering membrane, *the conjunctiva,* and from the lachrymal glands. It consists externally of the *cornea* and *sclerotica* or *sclera.* A line perpendicular to the centre of the cornea is its *antero-posterior diameter* or *axis;* and intersecting this at the centre of rotation we have the vertical and the transverse axes. A plane through both vertical and antero-posterior diameters will touch the surface on its *vertical meridian.* A similar plane, passing through the transverse and antero-posterior axes, will form at the surface the *horizontal meridian.* The plane passing transversely through the vertical meridian forms the *equator,* and the extremities of the antero-posterior axis are the *poles* of the eye. All planes going through the geometrical centre form *principal meridians* or *great circles.* Planes vertical to the axis but not passing through this centre form *lesser circles.* or those of latitude.

At birth the normal length is 17.5 mm. and the full size is not reached until after puberty. The following table of measurements is

Digitized by Illinois College of Optometry

compiled from various authors, viz., Jaeger, Merkel, Reuss, etc.; chiefly from Merkel.

Antero-posterior diameter externally,	24.3	mm.
Transverse, " "	23.6	"
Vertical, " "	23.4	"
Sclera, thickness behind,	1.	"
Cornea, thickness at apex,	.9	"
" " " margin,	1.1	"
" radius of front surface,	7.7	"
" diameter of its base (Jaeger, 12 mm.)	11.6	"
" height of apex above base,	2.6	"
Pupil, average diameter,	4.	"
Lens, thickness (axis) in repose[1] (Reuss),	3.8	"
" equatorial diameter,	8.7 to 10.3	"
" radius of anterior surface (Reuss),	10.6	"
" " " posterior " (Reuss, 8.2 mm.) Aubert,	6.	"
Distance from outer surface of cornea to lens (Horstmann), (Apparent distance .5 mm. less.)	3.	"
Depth of anterior chamber,	2.6	"
Vitreous axis,	15.1	"
Retina, thickness at optic disc,	.4	"
" " at fovea centralis,	.1	"
" diameter of fovea centralis,	.2 to .4	"
Optic disc, diameter,	1.4	"
Distance from centre of optic disc to centre of fovea,	4.0	"
Internal axis of eyeball from apex of cornea to surface of fovea (Becker),	23.87	"

Absolute accuracy in all these details is not attainable; even the length of the axis measured to the fovea centralis is not settled, because it is not absolutely uniform among normal eyes. For further details see Nagel[2] and Becker.[3]

Going from before backward we find the following parts, viz.: *the cornea;* the space called *aqueous chamber* filled by aqueous humor, and which contains also the *iris;* it divides the aqueous chamber into the *anterior and posterior chambers,* and is itself perforated by an opening, *the pupil; the crystalline lens,* inclosed in a capsule which by certain fibres is attached at its edge to the tips of the ciliary processes; behind the lens the *corpus vitreum* or *vitreous humor;* in contact with the vitreous is the *retina,* into which passes the *optic nerve;*

[1] "Untersuchungen über die optische Constanten Ametropischer Augen," Graefe's Archiv, xxiii., 4, p. 183.

[2] G. u. S. "Handbuch," Bd. ii., pp. 280 to 290.

[3] Ibid., Bd. v., pp. 432 to 442.

Digitized by Illinois College of Optometry

external to the retina is the *choroid*, which, at a place near the corneal edge, takes the name of *ciliary body*, and is raised into folds called *ciliary processes*, and is also continuous with the iris; outside of the choroid and in front, joined to the cornea, is the *sclera*, which behind is continuous with the sheath of the optic nerve. The optic nerve passes through the sclera and choroid and joins the retina.

Figure 1 illustrates and describes the facts mentioned.

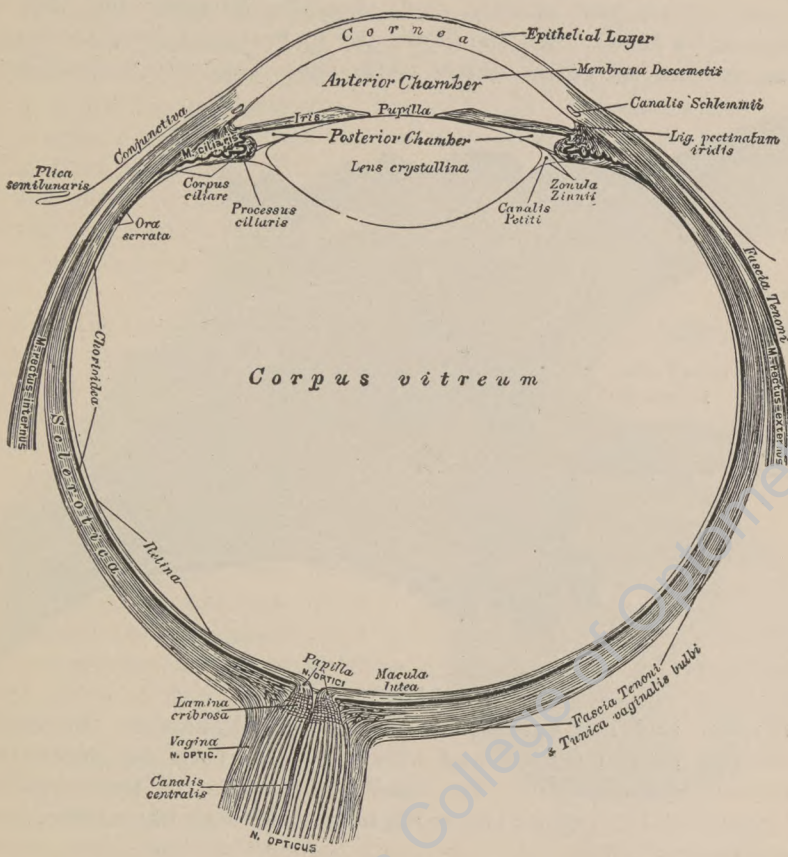

Fig. 1.

For practical purposes it is important to understand correctly the relations of the parts composing the anterior half of the eye. The subjoined diagram, Fig. 2, presents them, in most respects, satisfactorily.

The edge or *limbus corneæ* is a ring-shaped space about 1 to 2 mm. in breadth whose borders are often very ill defined; the epithelium here increases in thickness and merges into the conjunctiva.

A practical point to be noted is that the limit of the transparent

Digitized by Illinois College of Optometry

cornea lies in front of the place from which the iris springs; hence, the anterior chamber can be punctured through the sclera. A clear perception of this fact is indispensable in operating at this region. The existence of that congeries of vessels called the *canal of Schlemm* or the *circular venous sinus,* is also to be noted. It has important relations to the physiology of the anterior chamber. It is the outlet by which the aqueous humor finds its way into the circulation, and is supposed by Schwalbe to have in its wall minute clefts for this purpose; but this is disputed by Leber. At the angle are to be found delicate fibres passing from the cornea across to the iris. They are insignificant

FIG. 2.

in man, and are called the pectiniform ligament. In lower animals, viz.: in the ox and in swine, etc., they are more developed, and constitute the *canal of Fontana.* Upon theories of intraocular pressure, the parts now alluded to have important significance.

The aqueous humor is derived from the vessels of the iris and ciliary processes. The posterior chamber is entirely shut off from the anterior chamber by contact of the iris with the lens, and even when the pupil is well dilated the contact continues. The anterior chamber appears to have much less than its real depth, which is from 2.6 mm. to 3.5 mm., for the same reason that a brook is likely to deceive us as to the depth of water. Refraction brings the iris nearer than it really is, and likewise betrays us into wading deeper than we thought to go. In each case we may have cause for regret.

Digitized by Illinois College of Optometry

The sphincter of the iris makes the pupillary part of the membrane thicker than the rest of it. Another point to be observed is that the ciliary processes do not touch the rim of the crystalline. There is always a separation between them. The zonula of Zinn, or suspensory ligament of the lens, comes from the posterior surface of the ciliary processes, and is attached to the lens-capsule (see Fig. 1.) It splits into fine fibres, of which more go to the anterior surface of the lens than to the posterior.

Passing to the deep part of the eye, we have the *retina*, beginning at the optic nerve and lining the concavity of the globe to the posterior edge of the ciliary body. Because this edge is irregular it is called the *ora serrata*. The retina is transparent and near the optic nerve is thicker than at any other part. At a point 4 mm. from the centre of the nerve, on its temporal side, and about 1 mm. below it, is a depression called the *fovea centralis*. Around it the retina has a faint yellowish or tawny color over an ill-defined elliptical space, and this region is called the *macula lutea*, or *yellow spot*. Its greatest diameter, which is horizontal, is about 0.8 mm. The thickness of the retina near the nerve is 0.3 mm. The *fovea centralis* is 0.2 mm. in diameter. Outside of the retina is the *choroid*, which is perforated by the optic nerve, and consists chiefly of blood-vessels and pigment and connective tissue. The pigment is of a dark brown color, and varies in amount in different persons. We find a layer of hexagonal epithelium, filled with pigment-granules and each containing a nucleus; this was formerly assigned to the choroid, but is now regarded as the most exterior layer of the retina. In the choroidal stroma are irregular cells with stellate processes and nuclei filled with pigment-granules. There is also free pigment scattered among the vessels. The choroidal vessels will be mentioned hereafter. At the point where the retina terminates, or no longer possesses nerve-elements, we have the beginning of that part of the choroid called the *ciliary body* (Fig. 3). It is divided into the *pars non plicata* behind, and the *pars plicata* in front. The plicæ or folds are some seventy in number, and of unequal length. They consist of a congeries of vessels, which in front lift themselves up into projecting masses, and are called the *ciliary processes*. The great abundance and

FIG. 3.—*Cc*, Cilliary process; *Vv*, venæ vorticosæ.

Digitized by Illinois College of Optometry

plexiform arrangement of blood-vessels in the choroid and ciliary processes is necessary to secrete the pigment and to furnish nutritive material for the vitreous body and lens, which have no blood-vessels.

Outside of the ciliary body, inserted between it and the sclera, is a mass of muscular fibres, known as the *ciliary muscle* (see Fig. 2). Its most exterior fibres run in the meridians of the eye; those which lie next, run in oblique directions which slant more and more as we go deeper, until we come to the innermost set, which take a circular direction. The whole mass, in meridional section, has a triangular form, whose apex and point of attachment is near the canal of Schlemm. For reference to the variations in its form and size, see chapter on refraction.

The place of attachment is called by Gerlach the *ligamentum annulare*. The anatomy of this region of the eye was long misunderstood, and there is likely to be confusion from the variety of terms which have been employed at different periods. The insertion of the ciliary muscle is upon the choroid, and its effect is to relax the fibres which pass from the tips of the ciliary processes to the margin of the lens, and which fibres are known as the zonula of Zinn, or suspensory ligament of the lens. This name is also extended to a transparent membrane which lies between the ciliary body and the vitreous. The purpose and effect of the ciliary muscle is to permit the crystalline lens to become more convex. The space between the ciliary processes and the margin of the lens has importance in reference to the escape of fluid from the vitreous to the canal of Schlemm and the exterior circulation of the eye. The iris has pigment, blood-vessels, epithelium, and also muscular fibres which regulate the size of the pupil ; iris, ciliary body, and choroid, are together known as the *uvea*.

We have next to speak of the vessels of the eye, and for much of our knowledge of the details of their arrangement we are indebted to Leber, whose diagram is introduced below (Fig. 4).

There are four systems of vessels, which may be distinguished from each other: 1st, the arteria centralis retinæ, which enters the eye through the optic nerve, is destined exclusively for the retina and optic nerve, and forms few anastomoses with other vessels, and those chiefly at the edge of the optic disc (*rami communicantes*). At the choroidal opening through which the nerve passes to reach the retina is found the only communication between the retina and choroid, and the optic nerve, and it is known as the *circle of Haller*. There is also communication between the sheath of the nerve near the sclera and the above-mentioned vessels. The retinal system is remarkably isolated, and by Cohn is classed as "a terminal system;" 2d, the posterior, or short ciliary arteries

Digitized by Harvard College of Optometry

which perforate the posterior part of the sclera and supply the choroid, and, with the long ciliary arteries, are the chief source of the elaborate vascular system of the choroid, of the ciliary body, and of the iris; 3d, the anterior ciliary arteries derived from vessels which come from the recti muscles and perforate the sclera about four to six millimetres behind the cornea. They are visible to the naked eye, more or less conspicuously, and supply the ciliary body, the iris, and the anterior part of the sclera, and furnish the plasma

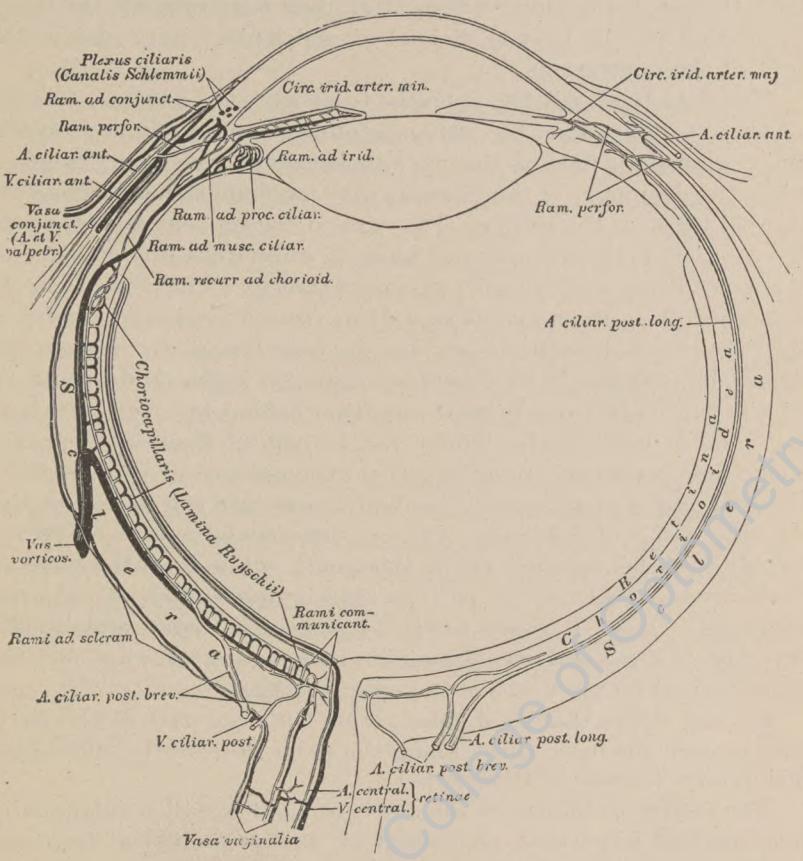

FIG. 4.

which nourishes the cornea. These vessels join with the branches of the posterior ciliary arteries, and at the border of the cornea send off loops, which constitute the peculiar vascularity of this region. Moreover they here anastomose with, 4th, the vessels which have come from the ocular conjunctiva. It thus happens that for a zone about the cornea there is a system of vessels which have communication with the face and with the deep and the superficial tissues of the eye. The vessels proper to the conjunctiva are of

Digitized by Illinois College of Optometry

darker hue than those more deep, and they can be moved about as the membrane is slipped over the sclera by traction of the lids. This statement of the anatomy of the vessels shows how untrustworthy is any attempt to make a diagnosis of the locality of an inflammatory process by fixing attention chiefly on the kind of hyperæmia. The vascular phenomena are important as auxiliary evidence, but do not take the first rank in deciding a diagnosis.

The non-vascular structures of the globe form so much of its bulk, that some statements respecting their nutrition and the lymph circulation will be proper; Schoeler[1] and Knies[2] have elaborately studied these questions.

The fluid to supply the aqueous, to nourish the lens and to nourish the anterior part of the vitreous, comes from the ciliary processes and posterior surface of the iris (at Schoeler's "secretory angle"), while the deep part of the vitreous may have nourishment from the choroid through the retina. The current for the lens goes through the canal of Petit and does not seem to come from the vitreous (on this point Knies and Schoeler are at variance). The cornea may be nourished from the aqueous as well as from its adjacent vessels at the limbus. It, like the sclera, *has no true lymphatic* vessels, but numerous channels in its substance, through which fluid passes. It admits fluid both from in front and from behind, but the epithelium and endothelium greatly hinder the transit of fluid, as is proven when these layers are removed either mechanically or by ulceration. From the corneal substance the fluid passes into the veins, and also into the canal of Schlemm; and the intraocular lymph current is largely from behind forward to this point; while from the vitreous it also goes out along the perivascular lymph spaces of the venæ vorticosa. Here it comes into the supra-choroidea and besides entering the general circulation it also makes its way into the inter-vaginal lymph space of the optic sheath.

Stilling states that fluid passes from the deep part of the vitreous through the optic nerve along the space outside the effete hyaloid artery (*Canal of Cloquet*).

The degree of fulness of the globe, or what is called *intraocular tension*, has important physiological and pathological bearings. Much study has been given to it. To a remarkable degree the intraocular circulation is independent of the systemic vessels because shut within a special cavity, yet a slight relationship exists (Schulten[3]). The tone of its vessels and consequently the tension of the globe, are largely controlled by the nerves. For example, stimulation of the sympathetic in the neck contracts the ocular blood-

[1] Jahresbericht, Berlin, 1882, pp. 52 to 92.
[2] Archives of Ophth. and Otol., vol. vii., p. 347.
[3] Graefe's Archiv, Bd. xxix., Abth. 111, p. 1.

Digitized by the Internet Archive

vessels, and the effect may be sufficient to cause dilatation of the pupil. Both arteries and veins become smaller and the intraocular tension falls. The same result ensues from irritation of the spinal cord above the third or fourth vertebræ, but not below this point.

Irritation of sensitive nerves, as when creosote is applied to the cornea, causes contraction of the pupil and increase of tension. A similar increase occurs after irritation of the sciatic nerve.

If, on the other hand, the contractility of the vessels is destroyed, they passively dilate and tension rises. Prolonged pressure on the globe will have this result, as Donders observed, and if this be done by injecting fluid into the globe and subsequently allowing the pressure to fall, it does not return to the normal because the vessels have been paralyzed and remain dilated. Schoeler says that cutting the sympathetic increases the secretion of aqueous humor and diminishes its excretion. He also says that the fifth nerve contains fibres which influence secretion within the eye, and can increase, hasten, and modify it more when it is cut within the cranium, than after division of the sympathetic. He also asserts that he found these fibres to lie on the medial fourth of the width of the nerve; he cut the nerve three-quarters across behind the ganglion of Gasser, and because the innermost fourth remained, no changes occurred in the secretions of the eye. When these last fibres were cut the changes took place.

Paracentesis of the anterior chamber is followed by paresis and enlargement of the vessels, and the aqueous humor becomes fibrinous. This proceeding, therefore, has ultimate effects which may be directly contrary to what is desired; and a similar remark applies to strong pressure by a bandage.

In experimental research tubes called manometers are inserted into the eye, and the ordinary intraocular pressure is equal to twenty-five millimetres of mercury.

Digitized by Illinois College of Optometry

CHAPTER II.

GENERAL PHYSIOLOGY OF THE EYE.

Refraction.

Like the photographer's camera, the eye consists of an arrangement of lenses to throw a luminous picture upon a sensitive surface. The former we have in the cornea with the aqueous humor, in the crystalline lens and the vitreous. The cornea and the lens are the essential refractive or dioptric apparatus. The sensitive or percipient structure is the retina.

The properties of a lens are determined by (1) the transparency and homogeneity of its structure, (2) by its refractive power or *index*, (3) by its form; and (4) its effect is varied according to its distance from the surface on which the picture is formed.

Absolute transparency is never met with in nature, and both the cornea and lens become visible by the light which cannot pass through but is reflected from their substance. Neither are these structures perfectly homogeneous and especially is this true of the lens. Refractive power or index signifies the ratio by which light falling on a medium, is diverted from its previous course through air—and it is assumed that the direction is not perpendicular, and that the surface of the medium is plane, and not curved. If air be called 1, the refractive index of the cornea is the same as of water, viz., 1,336, while the index of the crystalline is 1,437. All lenses have curved surfaces, and the form of the cornea and lens have been carefully studied. See table below. The greater the number of surfaces in a refractive system, the more complex the problem. As light goes from one medium to another of different refractive index it is deviated, and every surface must be taken into account. Moreover, the separation of the surfaces from each other has its influence.

The first deviation is at the exterior of the cornea, and no other takes place until we reach the surface of the lens:—because we may neglect the thickness of the cornea, and the aqueous humor

Digitized by University of California Library

has no effect because its index is the same as that of the cornea. At the posterior surface of the lens another refraction occurs, making three in all.

The following diagram represents the conditions in a simple optical system.

Let *a b* represent a spherical surface separating a less refracting medium from one of higher refracting power. Let *n* be the centre of the curve, and draw O A through the centre and normal to the curve at *p;* the line O A becomes the axis of the surface and rays passing through this line are not deviated. All rays impinging perpendicularly upon *a b*, like *m d* and *m' e*, will also suffer no deviation but go to *n*. The point *n* is therefore called the *nodal point*. All other rays in passing through *a b* will undergo refraction. If the medium on the side O be of lower index than the medium on the side A, rays going in the direction from O to A will be refracted toward the axis. Rays which are parallel to O A like

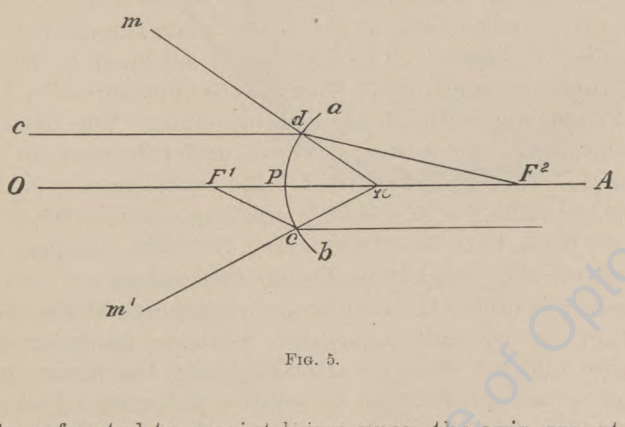

FIG. 5.

c d will be refracted to a point lying upon the axis, say at F^2, and this point is called the *posterior* or *second principal focus*. If rays pass from the side A to the side O, and are parallel to the axis, they will be refracted toward the axis, and will meet upon it at a point F', which is called the *anterior* or *first principal focus*. F^1 is nearer *a b* than F^2. The point P, where the optic axis cuts the surface, is called the *principal point*. The anterior principal focus F^1, the posterior principal focus F^2, the principal point P, and the nodal point *n*, are called the *cardinal points* of a refractive system.

Let us apply these principles to the human eye.

The simplest optical instrument is an eye from which the lens has been removed. We are then presented with only one refractive surface, and have to take account of its index and its curve. Rays from

Digitized by the Internet Archive of Optometry

a luminous point farther than twenty feet or five metres from the eye may be considered to be parallel, because the degree of divergence possible with the average diameter of the pupil may be discarded. Parallel rays will be refracted by the cornea so as to unite at a focus 33.8 mm. behind it, if they fall upon its convex surface. If, however, parallel rays are supposed to pass in the opposite direction and fall upon the concave surface, they will unite at a point or focus 26 mm. in front of it. The first is called the posterior principal focus, the second is called the anterior principal focus of the cornea. The difference between these figures is exactly the length of the radius of curve of the cornea, viz., 7.8 mm.

In the crystalline surrounded by air, we have a bi-convex lens whose index is 1.437, and whose front surface is curved on a radius of about 10 mm. and the back surface on a radius of 6 mm. The principal focus is at about 50 mm., and this is the same both for the anterior and posterior principal foci, neglecting the thickness of the lens. Both for the cornea and for the crystalline separately, it is easy to determine by simple construction or by simple formulæ the place and size of the image when the distance and size of the object is known. The curves are assumed to be spherical and the angles so small that they may be measured by the arc as well as by the sine without appreciable error. The optical centre for the cornea is the centre of curve, and this may be called its nodal point. The optical centre for the crystalline, if both its surfaces had the same curve, would be midway between the extremities of its two radii, that is at its centre, but with unequal radii it is a little nearer the side having the shorter radius.

If now we combine the cornea and crystalline at the distance at which they are normally separated, we have an optical problem much more difficult when we attempt to fix the place and size of the image. Gauss furnished its solution in a general way and abstractly, while Listing made special application of the theory to the eye. He also simplified the calculations, and made them applicable to what he called the reduced eye, in which a single refractive surface of a particular curve is substituted for the actual construction. For an explanation of the cardinal points of a compound optical system, reference must be made to other works, especially Landolt, "The Refraction and Accommodation of the Eye," translated by Culver, Edinburgh, 1886. We shall only enumerate them as consisting of three pairs, viz., the anterior and posterior principal foci, the anterior and posterior principal points, and the anterior and posterior nodal points. The first two are widely separated, the one being in front of the cornea and the other at the fovea centralis retinæ; the second pair are close together and situated between the cornea and lens; the third pair are also close together and lie just behind the lens. The nodal points are usually spoken

of as a single point, the posterior one being chosen. It is the optical centre where rays cross, and its position determines the size of retinal images and the refractive quality of the eye. The subjoined diagram from Landolt indicates the position of all these points upon a schematic eye three times magnified.

The measurements are thus tabulated:

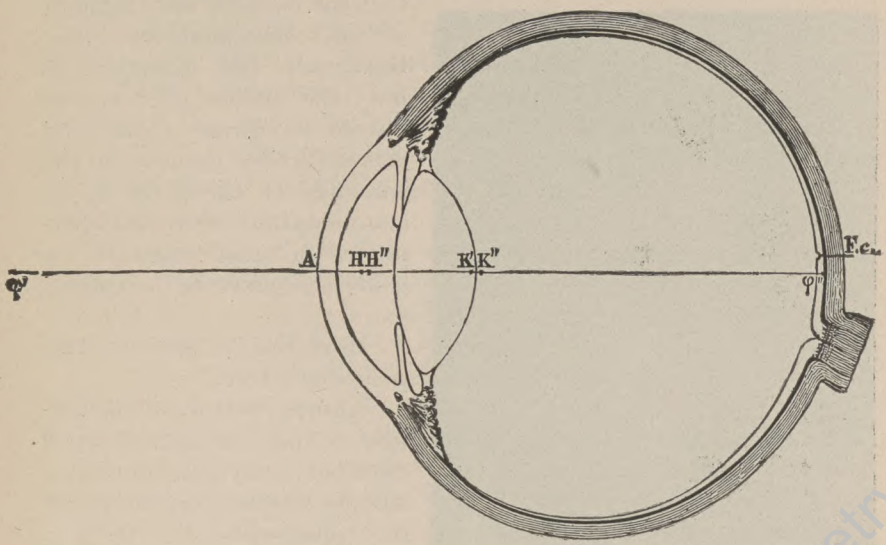

FIG. 6.

Distance from the apex of the cornea A of the anterior or first principal focus φ', . . .	= 13.745 mm.
Of the first principal point H′, ...	= 1.753 "
Of the second principal point H″, ...	= 2.110 "
Of the first nodal point K′, ...	= 6.968 "
Of the second nodal point K″, ...	= 7.325 "
Of the posterior or second principal focus φ'', . .	= 22.823 "
Separation between the principal points which is the same as between the nodal points, . . .	= 0.3569 "
The second nodal point is almost upon the posterior surface of the lens, behind it.	= 0.1254 "

The length of the optical axis is taken at 22.8 mm., which does not precisely agree with calculations made in a different way, which carry it up to 23.8 or 24 mm. This small discrepancy illustrates the very great attention which has been bestowed on the problems

Digitized by Illinois College of Optometry

of physiological optics, and upon this foundation has been erected the superstructure which has made our clinical and practical methods so precise and effective.

Other facts remain to be stated. The curve of the cornea has been assumed to be that of a sphere, which is not correct. It has been called an ellipsoid, which is approximately correct, while in fact the curve is very difficult of exact determination. (See Burnett.[1]) But inasmuch as only the middle part is employed in direct vision and this is further reduced by the lessening of the pupil in accommodation, we are still permitted in most cases to assume the curve to be spherical.

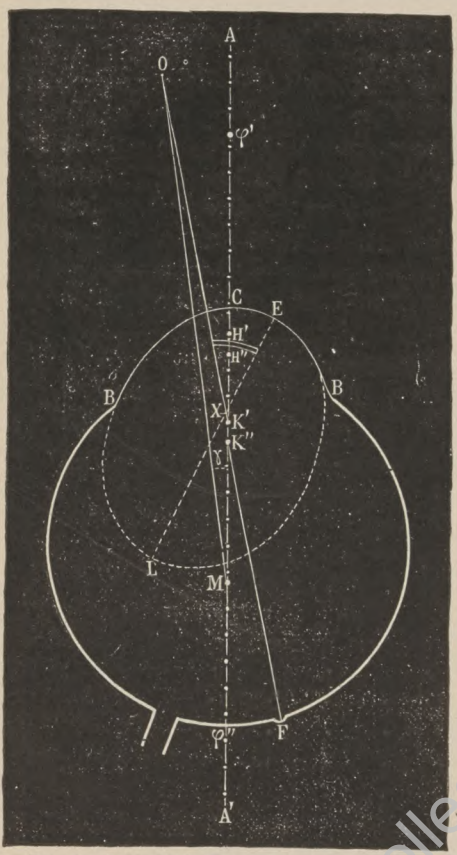

FIG. 7.—*A A'*, Optic axis; *φ'*, anterior focus; *φ''* posterior focus; *H' H''*, principal points; *K' K''*, nodal points; *M*, centre of motion; *C*, centre of cornea; *B B*, base of cornea; *E L*, major axis of the corneal ellipsoid; *F*, *fovea centralis*; *O*, point of fixation; *K' O*, line of vision; *M O*, line of fixation; *O X E*, angle alpha; *O M A*, angle gamma.

More will be said on this point hereafter.

Another feature of the cornea is that its optical apex does not always, and in reality seldom, exactly coincides with its topographical centre. This point has practical value and may be illustrated by a diagram modified from Landolt, which is exaggerated for the sake of clearer explanation. In it are laid out various lines which are to be distinguished. (1st) A A', which is the axis of the globe, passing through C the centre of the cornea and through K the nodal point and M the centre of motion. The last-named is situated about 13.7 mm. behind the summit of the cornea and 9 mm. in front of the retina. The corneal axis is EL and its extremity is to be outside of C the apparent centre of the cornea (the diagram represents the right eye); (2d) another line drawn from O, the object looked at, through the nodal point to the fovea centralis is the *vis-*

[1] Archives of Ophthalmology (Knapp), vol. xii., p. 1, 1883.

Digitized by the Internet Archive

ual line. Where this intersects at X the axis of the cornea, is found the *angle alpha* which represents the displacement of the cornea from the visual line. Usually this is outward and then is called plus; sometimes it is inward and is then called minus, or it may not exist. In extreme cases it amounts to 12° on the horizontal plane, usually not more than 5°, and it may also deviate slightly in a vertical sense.

In the crystalline we meet with another special feature, that its density and refractive index increase from the surface to the centre. By its arrangement in layers its refractive power is increased. Neither is the lens alike in all its sectors, and for this reason the image of a luminous point like a star, is never a mathematical point, but has irregular radiations, and to each individual the stars have dissimilar radiations.

Such are some of the irregularities of the optical structure of the eye. It becomes the equivalent of a lens whose focal length is 15.5 mm. or $\frac{3}{5}$ of an inch. This is most simply expressed by the diagrammatic eye of Donders in which the cornea has a radius of 5 mm.; the optic axis is 20 mm.; the nodal point is 5 mm. from the cornea and 15 mm. from the retina; while the anterior principal focus is 15 mm. in front of the cornea.

By this model it is easy to reckon the size of images on the retina, and the results are approximately true. It is only necessary to divide the distance of the object in millimetres by 15 to show how much smaller is the retinal image than the object.[1] A rod one metre in height placed at 15 metres distance (15,000 mm.) gives a retinal image 1,000 times smaller than itself and therefore 1 mm. in size. An object 10 mm. high at 300 mm., about 12 inches from the eye, gives an image one twentieth of its size, viz., $\frac{1}{2}$ mm.

In the example last cited we have introduced another element in the problem of refraction; we have brought the object near the eye. When this is done, the image no longer falls at the same distance from the cornea, but retires to a point farther behind, in accordance with the law of conjugate foci or reciprocal relation between object and image in all lenses. The nearer the object the more divergent become the rays, and the degree of divergence increases very rapidly as the object approaches, because measured by angular increase. The retina cannot retire and if no modification is made, either by increasing the convexity of the crystalline or by advancing its position farther from the retina, there can be no sharp and clear picture. Each luminous point of the object will not be represented by a point on the retina, but by a circle. The circles of dispersion often exhibit colors, chiefly blue and red,

[1] See Donders' "Accommodation and Refraction of the Eye," p. 178.

by breaking the light into its component elements. To obviate this difficulty, the eye is provided with a means of adjustment or accommodation when objects are presented near it.

Accommodation.

If in a dark room a light be held in front of the eye, its image will be reflected from the surfaces of the cornea and of the crystalline. That from the cornea though small is conspicuous, those from the lens are best seen with dilated pupil and when the light is held at one side. Purkinje called attention to them; Helmholtz utilized them to determine what happens when the eye adjusts itself to view a near object. He measured their size and the changes of

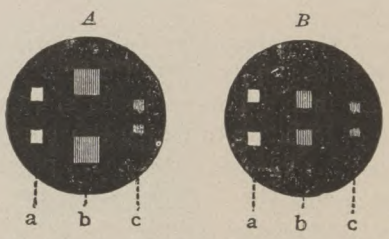

A. EYE IN REPOSE. *B*. EYE DURING ACCOMMODATION.

FIG. 8.

In *A* and *B* the light comes through square openings in a disc.
a. Image from the cornea (erect).
b. Image from the anterior surface of the lens.
c. Image from the posterior surface of the lens (inverted).

form and place which they undergo, by an instrument which he invented for this purpose—the ophthalmometer.

We may sum up the changes in the eye during accommodation as follows: the pupil becomes smaller, the front of the lens becomes more convex, and, by advancing a little, carries with it the iris and reduces the distance between it and the cornea; the posterior surface of the lens becomes inappreciably more convex. The lens is thus increased in thickness and its equatorial diameter lessened. The ciliary processes swell. These changes of the ciliary processes have been proved by inspecting the eyes of albinoes, and eyes in which iridectomy has been performed (Coccius, Becker, Hjort). The active agent is the ciliary muscle, and the mode of its action is believed to be as follows: the muscle contracts, becomes thicker, and presses the ciliary processes nearer the optic axis, and enlarges their volume. At the same time the fibres draw upon the zonula (suspensory ligament of the lens) and release the crystalline from the tension under which by its anatomical construction, like a

Digitized by Illinois College of Optometry

bundle of watch springs, it is kept, and it, by its elasticity, increases its anterior convexity while its border grows more rounded. The distance between lens border and ciliary processes is not altered, neither does the lens increase in volume. The aqueous humor becomes slightly displaced toward the periphery of the chamber, and the pupil diminishes. The actual increase of the axis of the lens, in accommodating from infinity to five inches, is 0.4 mm. The radius of the anterior surface of the lens is shortened from 10 mm. to 6 mm., the radius of the posterior surface from 6 mm. to $5\frac{1}{2}$ mm. The lens increases from a central thickness of 3.6 mm. to 4 mm. (see Mauthner: "Vorlesungen," 1872, p. 20). The changes are shown in Fig. 9, copied from Landolt.

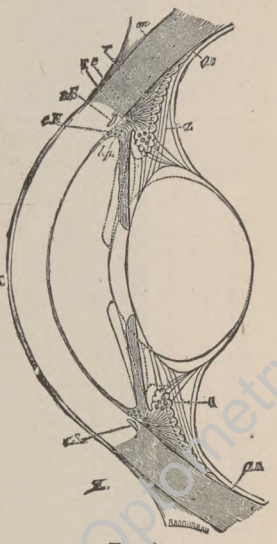

FIG. 9.

The nerves which preside over the action of the ciliary muscle and the pupil are the ciliary, of which some come from the ciliary or lenticular ganglion, and others from the large ciliary nerves. For further remarks see pupil, p. 432.

What is the extent and course of the accommodation?

We know that in early life the degree of accommodation is highest, and that it steadily diminishes. Donders, to whom we owe most of our knowledge on this subject, showed that if at ten years of age the nearest point of distinct vision is at 2.8 inches, at twenty it has receded to 3.9 inches, at thirty to 5.7 inches, at fifty to 16 inches.

At first thought, the diminution which occurs at the age of thirty does not seem important. We know that lenses are, in respect to their power, to each other inversely as their focal length. A lens of 4 inches focus is to one of 12 inches focus as $\frac{1}{4}$ is to $\frac{1}{12}$. The former is three times as strong as the latter, and the difference between them is $\frac{1}{4}-\frac{1}{12}=\frac{1}{6}$, that is, it equals a lens of 6 inches focus. Now, in comparing the accommodation at ten years of age with that present at thirty, we are to use the formula $\frac{1}{2.8}-\frac{1}{5.7}=\frac{1}{5.5}$. In other words, by thirty years of age the eye has lost one-half its power of accommodation, at fifty years we have $\frac{1}{2.8}-\frac{1}{16}=\frac{1}{3.4}$, which is a loss of almost $\frac{8}{10}$, its original accommodative power.

The nearest point to which the eye can adjust itself is called the near-point of accommodation, denoted by the symbol P (*punctum proximum*). The farthest point of accommodation is denoted by the symbol R (*punctum remotum*), or far-point. The breadth or range of accommodation is expressed by the formula, $\frac{1}{P}-\frac{1}{R}$, and

Digitized by the Internet Archive of Optometry

is equivalent to the difference in refractive power of lenses whose principal foci are P and R. The range of accommodation becomes, therefore, a lens of definite focus, whose refractive power is expressed by $\frac{1}{A}$. Now, in normal eyes, up to about fifty-five years of age, R is at an infinite distance, and the refraction is denoted by $\frac{1}{P} - \frac{1}{\infty}$, that is, it equals the near-point. But, beyond this age, the far-point goes still farther away than infinity, an expression not absurd in mathematical language, and which means that the eye can now bring to a focus rays which are slightly convergent, and, as light from natural objects never travels in converging lines, a convex lens is needful to enable the eye perfectly to see distant objects. The course of the accommodation is given in the subjoined table, constructed by Donders, and taken from Nagel (G. und S., Bd. VI., p. 466), and is given both in metres and in English inches:

Age in Years.	Distance of P in Metres.	Distance of R in Metres.	Distance of P in English Inches.	Distance of R in English Inches.	Breadth of A.	
					Metres D.	Inches.
10	0.071	∞	2.8	∞	14 D	1 : 2.8
15	0.083	∞	3.32	∞	15.	1 : 2.3
20	0.100	∞	4.	∞	10.	1 : 4.
25	0 128	∞	5.1	∞	8.5	1 : 5.1
30	0.143	∞	5.7	∞	7.	1 : 5.7
35	0.182	∞	7.2	∞	5.5	1 : 7.2
40	0.222	∞	8.88	∞	4.5	1 : 8.8
45	0.286	∞	11.44	∞	3.5	1 : 11.44
50	0.400	∞	16.	∞	2.5	1 : 16.
55	0.666	—4. (H 0.25)	26.64	—160.	1.75	1 : 41.
60	2.	—2. (H 0.5)	80.	— 80.	1.	1 : 40.
65	—4.	—1.33 (H 0.75)	—160.	— 57.	0.5	1 : 80.
70	—1.	—0.8 (H 1.25)	— 40.	— 32.	0.25	1 : 160.
75	—0.571	—0.571 (H 1.75)	— 25.	— 23.	0.	1 : 0.
80	—0.4	—0.4 (H 2.5)	— 16.	— 16.	0.	1 : 0.

Another and familiar way of exhibiting the variations of accommodation with age is by a diagram first employed by Donders and reduced to dioptries by Landolt.

The above measurements relate to the accommodation of one eye by itself; they are not strictly true when both eyes, working simultaneously, are considered. The binocular accommodation is rather less than the monocular. In binocular sight the visual lines converge upon the object, and a suitable amount of A is exerted, according to the distance of the object. There is, therefore, a relation between convergence of visual lines and A. This relationship is of great importance in dealing with objects near the eye, and we speak of it as the *relative* accommodation. For a given angle of convergence it is possible for the eyes to put forth a greater and also a less degree of A than the distance of the object requires. We illustrate by a diagram, Fig. 9, in which, upon the line AB, the visual lines converge at a point O, which is at the same time the

Digitized by the College of Optometry

place for which the eyes are accommodated. While the visual lines remain at the same angle of inclination, it is possible to see O correctly when it is viewed either through a convex glass, which will by so much diminish the effort of accommodation and place it virtually at A, or through a concave glass, which will compel greater effort of A, and make the object seem to be at C. If, with a person fifteen years old, O be taken at 12″, then a convex glass about $\frac{1}{14}$ can be used, which will carry the accommodation to 72 inches, while a concave glass, viz., about $\frac{1}{9}$, will be accepted, which will bring the

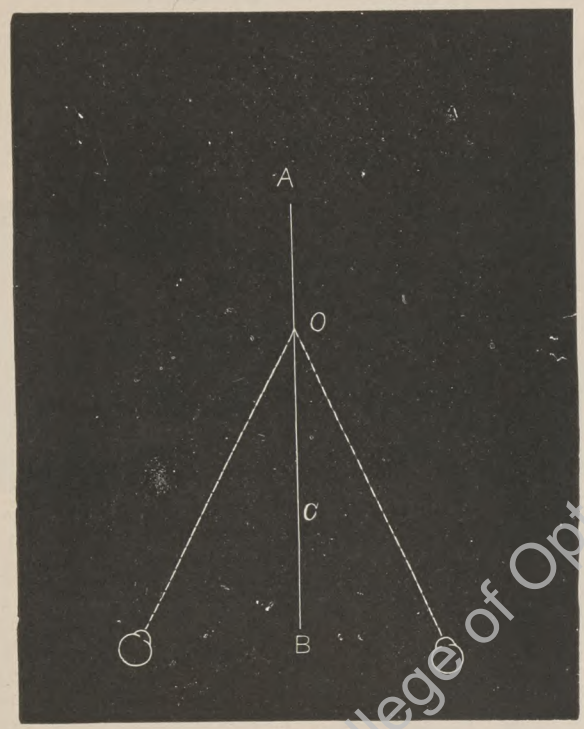

FIG. 10.

accommodation to 5.33″ (Donders). The former, found by the convex glass, gives the negative side, and the latter, found by the concave glass, gives the positive side of the relative A. With parallel visual lines, concave glasses $-\frac{1}{11}$ can be overcome, which bring the object to 11 inches. But if convergence be at 4″, concave glasses can no longer be used; only convex can be employed, and therefore the relative A is entirely negative. The practical result of these investigations is that for a given amount of convergence there must be a certain ratio of positive A to negative A, else the eyes soon grow weary. Graefe said that the positive side must be about

Digitized by Illinois College of Optometry

equal to the negative, but age and the refractive quality of the eye make important differences. In later life when the accommodation has become much restricted, its reserve part very greatly diminishes and without any discomfort to the individual. While some reserve of relative A must remain experience shows that in this matter there is great diversity among individuals. Peculiarities of refraction and of muscular capacity have great influence. This subject will be again referred to when treating of muscular asthenopia.

Functions of the Retina.

The retina is made up of nerve-elements of peculiar structure, of the fibres coming to it from the optic nerve, of epithelium, and of connective tissue. The only elements we now need to consider are the *bacilli* or *rods and cones*. They are upon the outer surface of the retina, next the epithelium, and may be likened to the pile of velvet, because they stand perpendicularly to its surface. At the fovea centralis they are most numerous and elongated, the cones alone existing here. The minute structure of the retina at the fovea centralis is shown in Fig. 11, which is taken from Schultze's schematic section, given in Stricker. The fibres of the optic nerve are the innermost of the nerve elements; thickest around the disc, at the fovea they are thinnest. They convey to the brain the impressions excited, and are themselves not capable of being stimulated by light. The blind spot (Mariotte) in each visual field is thus explained. If, with the right eye, one look at the cross in Fig. 12 (from Helmholtz) placed at about twelve inches distance, the circular white spot will correspond to the size of the vacancy in the field of most persons. The cross is above the level of the centre of the circle, because the fovea centralis is lower than the middle of the optic disc.

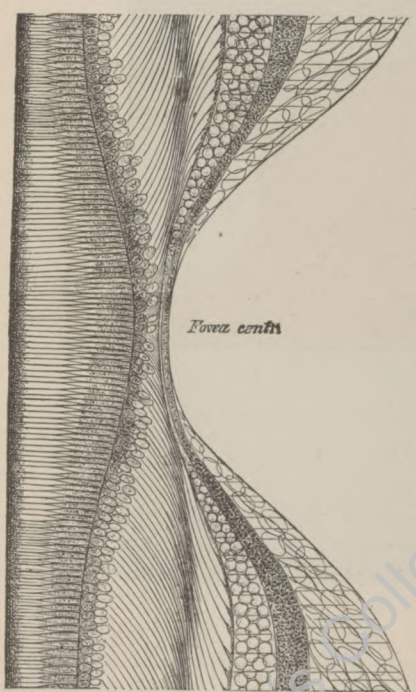

Fig. 11.

Digitized by Illinois College of Optometry

All parts of the retina up to the ora serrata are capable of perceiving light. The impressible surface is not quite a hemisphere, and if it stood out beyond the obstruction of the nose and the other surroundings of the eye, it would include within its scope a corresponding exterior hemisphere, or field of vision. The space which the eye at rest can cover in vision, varies according to the facial peculiarities of each person and the prominence of the eye from the orbit; we shall return to the subject of the visual field farther on. The middle of the retina is its most sensitive part, and when we give attention to an object, *i.e.*, look at it, we turn the eye so that the object shall be imaged on the fovea centralis.

We have already learned the size of the image for a given distance of an object; we have now to inquire what is the smallest image which the retina is able to distinguish: in other words what is the *normal acuity of vision?* The problem must be taken on its

FIG. 12.

practical side, and it does not mean the perception of a point of light like a star. We have three properties in the retina, the form sense or acuity of vision, the color sense, and the light sense. Naturally the last is presupposed in both the others, yet sometimes it demands separate investigation. The determination of the *form sense or acuity of vision* has been studied by Helmholtz, Aubert and others as a problem of physiology.

It is found that the smallest perceptible angle is one which forms an image covering two cones. For accurate vision the image must reach the outer extremity of the cones. The thickness of the retina at the fovea is .15 mm. The smallest visual angle for black lines on a white surface is taken by Aubert at 52″. This corresponds to an image about .004 mm. long. Snellen, who first worked out the question of visual acuity in a practical way, has taken the angle of 1′ (one minute) as the average degree of visual power. He has given the formula $V = \frac{d}{D}$ to represent it. V stands for *visus;* d for the distance at which the object is placed, and D is the distance at which it ought to be seen and which is placed above the type. He has

Digitized by the Google Collection of Optometry

constructed test types with letters whose stroke shall at 6 metres subtend an angle of 1′, and the entire letter, supposed to be contained in a square, subtends an angle of 5′. The first editions of his test types were constructed upon the scale of Paris feet, the recent editions are according to the metric scale, and for 20′ we now take 6 metres. In the last editions the numbers formerly known as xx and xxx have been changed for smaller letters to correspond to the reduced distance, because 20 Paris feet = 6.5 metres.

The separation between the letters has an important influence. In the English edition of Snellen, the interspaces are three fifths the height of the letters. White letters upon a black surface seem larger by irradiation. It appears that differences of illumination have less influence upon eyes with normal acuity than upon those with reduced acuity.

An important consideration is the age of the subject. Cohn found the children in a village school among the mountains had, when tested by Snellen's "hooks" (which are the characters to take the place of letters for those who do not know the alphabet) v = 2 in 47% (114 eyes); v = 2 to 1½ in 34% (85 eyes); v = 1½ to 1 in 15.5% (38 eyes); v = 1 in 2.8% (7 eyes). Total of 244 eyes. In old age the opposite condition usually appears. Cohn, in 1874 (Nagel's Jahresbericht, Fünfter Jahrgang, p. 210), examined 100 persons between 60 and 84 years, dwellers among the mountains. He found 88 eyes with v better than 1 and 34 eyes with v = 1. It is commonly said that v = ½ is normal after 60. Among savages vision is always high. Occupation and mode of life also have an influence. Those who are occupied upon near objects and who do not live much in view of objects at a great distance usually have lower acuity.

It would appear from Seggert's examinations that persons in health between 20 and 25 years, who have v greater than 1, have as an average $v=\frac{23.62}{xx}$ (l.c., p. 98) and the visual angle is therefore 4′ 14″. This conclusion is after examination of 2,253 eyes. Another point to be mentioned is that binocular is better than monocular vision. Common experience testifies to this fact; while Seggert has shown that if one eye is inferior to the other, vision will in 85% be equal to that of the better eye. Reference will be made to this hereafter, under the head of anisometropia.

Snellen's types are the usually accepted standard, and they may be employed with the qualifications which have been set forth. Monoyer has given a table in which the series is made to progress in tenths, from 1 to 0.1. This system is to be preferred over all others because of the regularity and smallness of the intervals between the sizes of types. (See p. 33.)

Many other test types have been published; in some the visual angle is taken at 4′. In some the more difficult letters of Snellen are left out. Dr. John Green, of St. Louis, has issued a table in which he adopts a plainer form of letter, Gothic rather than Egyptian, and he fills out gaps in the series of Snellen's types by making the series more correctly progressive in an arithmetical series. The spacing of his letters makes them more difficult to decipher than the English edition of Snellen. For ignorant persons Snellen pro-

Digitized by Illinois College of Optometry

vided characters which the patient is to describe by telling which side of the figure is open and whither it points. Burchardt has a set of tests composed of dots arranged in groups, and of different sizes, and he takes the distance much greater than Snellen. His tests are for use in the military service and while he sets acuity higher than Snellen, it is not as easy to use his tests as Snellen's. Seggel, after careful comparison of the two on a large scale, gives Snellen's the preference (l.c., p. 84). Mauthner says that acuity which with Snellen may be 1, will with Burchardt be 1¼.

In testing a patient, he is placed at six metres from the card, or if this distance is not available, at the greatest distance possible. (Pflüger has issued a set of letters which can be viewed by reflection in a mirror and so gain distance). The series extends from X to CC. If vision is better than 1 or $\frac{6}{6}$ or $\frac{20}{XX}$ it will be perhaps $\frac{6}{X}$ or $\frac{6}{XII}$. On the other hand it may be less than 1 and be $\frac{6}{XXX}$, $\frac{6}{XL}$ or $\frac{6}{CC}$ (metric). If less than the last-mentioned amount, the card may be brought to the patient and the vision given accordingly, say $\frac{3}{CC}$ or if in feet $\frac{8}{CC}$ or less. The rule should always be observed to place the actual distance of the test types as the numerator of the fraction. When V is very low, say $\frac{5}{C}$ (in feet) it is often impossible to decide between $\frac{5}{CC}$ and $\frac{5}{C}$, and the same uncertainty may appear with $V = \frac{20}{LXX}$. It is in this class of cases, that illumination has most influence. To this must be added the influence of the size of the pupil; because persons with low V, see with dispersion circles, and the smaller the pupil the smaller the circles of dispersion. It is surprising to note what sharpness of sight, or rather what "discerning power," as Nagel calls it, will sometimes be found in persons who have slight opacities of the cornea, incipient cataract, astigmatism, etc. Although the retinal image is very badly outlined, they are able to draw inferences as to form and features which persons who rely chiefly on the accuracy of retinal images cannot in any degree compete with. Such persons show decidedly much better vision for near, than for distant objects. Hence, the little value which attaches to examinations by reading fine print. Power of accommodation, size of the pupil and skill in deciphering obscure characters, make such examinations untrustworthy as measures of visual acuity; although for the patients they have great practical importance and consolation. Certain letters are well known to be more easily recognized than others. Cattell experimented with a special apparatus on this matter. He viewed the letters for very brief periods of time in uniform light, and made 270 exposures of each letter. They were of the plainest form and the stroke of uniform thickness. The order of legibility he found to be W Z M D H K N X A Y O G L Q I S C T R P B V F U J E. W was seen 241 times correctly; K N X A Y between 180 and 150 times; B V F U J about 100 times; E was recognized only 63 times out of the

270. In the small letters the order of legibility was d k m q h b p w u l j t v z r o f n a x y e i g c s.

He found that, to read a letter, light must act upon the retina from .001 to .0017 of a second, varying greatly in different individuals and in the same individual at different times. "The Inertia of the Eye and the Brain," Cattell, *Brain*, vol. 8, p. 294, 1885–86.

It is understood that Snellen's types are to be viewed by good ordinary daylight. On cloudy days the visual power is naturally less. To avoid this inaccuracy, Dr. H. Derby proposed that the test should always be by artificial light. In all cases where the light is not normal, the observer, if his own vision be good, should compare the patient's vision with his own. That a much smaller visual angle is attained by some persons and that a very bright light, like direct sun, greatly increases acuity, is well understood.

The value of illumination in affecting vision has been elaborately studied by Posch (*Arch. of Oph. and Otol.*, v. III. and IV., p. 295, 1876), who formulates the law that under a given degree of illumination and with one which is 16 times greater, acuteness of vision increases in arithmetical progression, while illumination progresses geometrically; such a ratio of increase is observed, if the light be neither very feeble nor very intense. Seggel (Graefe's *Archiv f. Ophth.*, Bd. XXX., II., 69, 1884, has given an analysis of his visual examinations in the German army, not employing photometric methods like Posch, but noting the differences between bright and rainy days. His examinations were made in a barrack with windows to the north. He found that between bright sky and rainy weather, eyes which had $v = \frac{20}{xx}$, or better, would show a difference represented by 6 : 5. If, however, in good light $v = \frac{12}{xx}$ the difference would be as 4 : 3. For such as had $v = \frac{6}{xx}$ the difference would be as 3 : 2 (l.c., p. 87).

Visual Field—Indirect Vision.

Let us now study the functions of the eccentric parts of the retina. The first fact which we notice is, that outside of the fovea, acuity declines very rapidly. For instance, at 1° outside of it, acuity of vision is reduced to $\frac{1}{3}$; at 2° or 3° V = $\frac{1}{6}$ (Königshofer). If the fingers be spread widely, they can be counted at almost the outer limit of the field of vision. But, for the peripheral parts of the retina, we confine our examination to the recognition of form, without attempting to ascertain discriminating power. This investigation is called taking the field of vision. It is done for each eye alone, the other being covered. To do this properly, an arc of a circle must be placed in front of the patient, which shall be not less than 90° nor more than 180° in extent. Its radius should be about 12 inches or 30 cm. The eye to be examined must be at the centre of the circle, and fixed steadfastly upon the point directly in front. An object, the size of which will be chosen according to the accuracy

Digitized by the College of Optometry

demanded—generally a white object, ½ inch square, is suitable—will then be moved along the arc from its centre to its extremity, or better, *vice versa*. When the perception has been determined with the arc in one meridian, it must be turned to another, until the whole field has been explored. Beginning with the arc in the horizontal position, it will be carried around to the vertical position, and a determination made for each meridian at intervals of 15° or 30°. The examination is easily made by an instrument called a perimeter, invented by Aubert and put in practical form by Förster. Many others have been made, in some of which a true hemisphere is used (Schirk, Dyer), or a quadrant is employed. In some, a diagram of the field is automatically traced (Stevens, McHardy), while a simple form consisting of a quadrant, the invention of Priestley Smith (see Fig. 13), has a place in front of the observer for inserting a blank on which a diagram of the field can be quickly and easily pricked off. This instrument, which has been imitated by Meyrowitz, is the most convenient of all.



FIG. 13.

In the absence of instruments, it is easy to take the field upon a flat surface for a distance 45° each way from the line of vision, because the tangent of 45° is equal to radius. If the eye be put at 15 inches from the wall, a circle on the wall with a radius of 15 inches gives 45°. If the space be divided into three equal zones, the first circle will be at 18° and the second at 33°. On such a surface, scotomata may be ascertained, but it is none the less important to investigate the peripheral parts of the field.

The outlines of the visual field are far from symmetrical. Its greatest extent is on the temporal side. On the opposite side the limit is determined by the height of the nose, while above, the eyebrow, and below, the cheek, fix the extent of its boundaries. The position of the eye in the orbit, the configuration of the face, the size of the pupil, and the length of the optical axis, are factors which enter into the form of the field. Usually the extent on the temporal side is 90°; on the nasal side, 50°. Above it is 50°, and below it is 65°. These figures are liable to great variations in different persons. To be sure that the full limit belonging to each

Digitized by the Pacific College of Optometry

case is secured, the observer may sight across the arc from extreme positions on the outer, inner, or upper sides, and note upon it the place across which he is able to catch a view of the patient's pupil. This marks the limit to which the field ought to extend, and should be noted on the chart as the boundary to which the field should correspond.

The numbering of the meridians has not yet been uniformly agreed upon. By some, including Priestley Smith, the top of the vertical meridian is the starting point, and 180° are counted each way, the temporal side called plus and the nasal side minus. Others begin at the left (Förster) and go around 360°, 90° being at the top. The difference is not very important. We must always remember that the temporal sides of the fields correspond to the crossed fibres of the tractus optici, and the nasal sides to the uncrossed fibres. Moreover that the right halves of the respective fields belong to the left optic nerve and *vice versa*. At least three meridians should be taken in each quadrant. To get the field on the nasal side to its absolute limit, the eye may be turned to fix on a spot 30° to the temporal side. In glaucoma simplex this suggestion has value. Sometimes the light must be greatly reduced to discover either limited defects within, or encroachments upon the periphery of the field. Another device sometimes helpful, is to make the patient face the window, and the glare of the light will sometimes bring out a limitation which would not occur in a normal eye. A perimeter is not needed to make out hemianopsia, such as happens from brain disease, and the same is often true of cases of detachment of the retina. The hand moved from point to point as the patient looks in the observer's face will discover the defect.

A small and portable perimeter has lately been made by Schweigger which is convenient for use at patients' homes.

Measurement of the blind spot can be made by using a small bright test object with the perimeter. It is increased in some cases of myopia and of papillitis. It varies normally from 4° to 7° 30′. The measurement of the angle of converging strabismus can also be made with the perimeter by sighting across it to the eye which does not fix.

The chief reason for the great reduction of visual acuity outside the fovea is the inferior sensibility of the retina. For objects very peripherically situated an additional reason would be anticipated in the distortion which images undergo when rays fall at very oblique angles. Fick, however, has shown ("Handbuch der Physiologie," Hermann, p. 80), that the position of the crystalline and its laminated structure very largely antagonize this source of error, and that the eye is eminently periscopic. That there is not absolute accuracy may be seen in emmetropic eyes, which are always hypermetropic on very oblique axes.

Digitized by Illinois College of Optometry

Color Sense.

Examinations of the color sense are called for in two classes of cases. First in those whose defect is caused by disease, and second in those in whom it is congenital. The two methods are unlike, and the conditions existent are also unlike. The pathological cases simply present modifications of the normal kind of perception, and there may be either a central region or a peripheral region deficient. The other class of cases, viz., those which are congenital, will be separately considered.

The capacity for recognizing colors of every hue, pertains only to

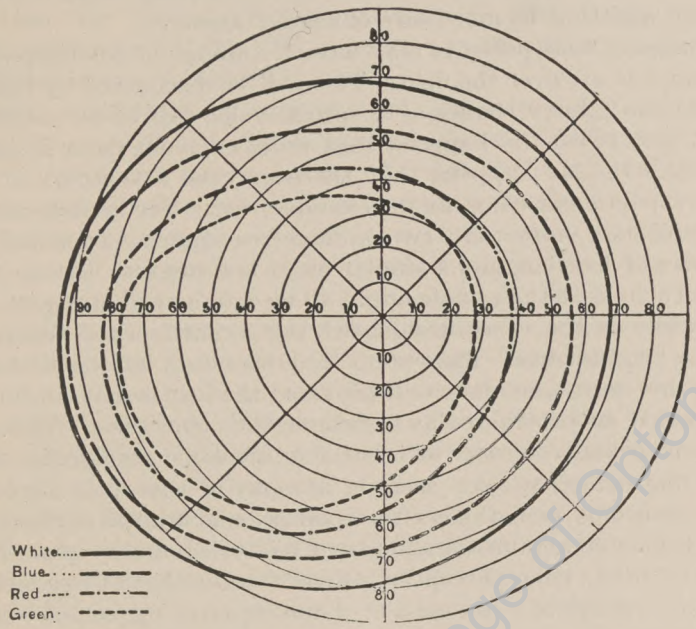

Fig. 14.

the middle region of the retina. Much depends, however, on the purity and luminosity of the color as well as on the degree of light. Very large and luminous colored surfaces can be recognized at the extreme limits of the field, as for instance a red house in sunlight; but we are dealing with small objects. The colors employed are blue, yellow, red, and green, and we use bits of card of from 1 cm. to 4 cm. square for the field; while for central perception we reduce the size to 2 mm. square. There is a natural boundary of the area over which each color can be recognized, and this varies according to the color. Landolt has given the chart, Fig. 14, which maps the limits of the colors named. While within the

Digitized by the College of Optometry

boundaries of green, all other tints can be known, and for the red, also yellow and blue; and for the space within yellow, also the blue; outside of yellow, only blue can be seen (Fig. 13); and outside of blue, no color is recognizable. These color limits cannot be held to be uniform even among normal eyes, but they have value as a general statement.

In making the test, a bit of card-board, 2 cm. square, of the proper tint, is put on the end of a rod and brought across the field, always beginning from the end of the perimetric arc. It is well to have different colors on its opposite sides, that, by turning the card around occasionally, we may guard against mistake or deception. One may have several rods, each having cards of different color, and thus be more sure of correct answers.

It happens that patients may have a dimness of color-sense for a certain hue all over the field. This will be discovered by finding out that the fainter shades of a special color fail to be correctly noted. But it usually happens that more than one color is dimly discerned. It also happens that there may be a scotoma in the field of a particular color, as for example, red. For its detection a small card not more than two millimetres square is to be held at the centre of fixation, and a similar one a few degrees to one side of it. The one at the middle ought to be equally brilliant with the other, while in the cases designated the eccentric card seems to have the brighter hue. The extent and boundary of the scotoma can, by this means, be made out, provided the test be not continued for a period so protracted as to fatigue the color sense. This examination belongs to cases of tobacco or alcoholic amblyopia, etc.

We find defective color sense in atrophy of the optic nerve, in chronic glaucoma, sometimes after apoplexy and injuries of the head, in amblyopia and amaurosis, and also in hysterical amblyopia. As a measure of direct color perception, Oliver[1] states that at five metres one should recognize a red card of 3 mm. square, a green of 2 mm., yellow of 2.5 mm., and blue of 8 mm.

Congenital defect of color sense, or *Daltonism,* has attracted great attention within eighteen years, and the literature of the subject is copious. For proper understanding of signals on railways and ships, and in some other cases, defect in color perception produces liability to mistakes whose consequences may be sufficiently serious. That accidents have not occurred more frequently when color-blind persons have been responsible for the interpretation of signals, is due to their possessing in most instances very acute perception of shades and degrees of light. They are often unaware of their defect. The condition is frequently hereditary. Horner gives a case of transmission from grandfather to

[1] Archives of Ophthalmology, vol. xi., p. 65, Am. Ed.

Digitized by Google

grandson during eight generations. Both eyes are affected; yet six cases are on record where only one was concerned. The actual frequency of color blindness is on the average 5% among men and less than ½% among women. The common error is inability to distinguish red from green, while other colors are appreciated. There are differences among these persons; some confound light red with dark green, and these are red blind, while others confound dark red with light green, and they are green blind. A much smaller class of persons have "blue-yellow" or violet blindness.

Very searching and interesting studies have been made by Donders, Koenig,[1] Hirschberg and others upon the vision of these persons with the solar spectrum. In place of red and green bands, they see only yellow of varying intensity, and recognize very subtle shadings of light. With some, the spectrum is shortened at the red end, with others it is not.

When candidates for employment in the service of a railway are to be tested, the method is by the worsteds of Holmgren, which are of all hues and tied in skeins. A mass of them, about 100, are thrown upon a white cloth and the person examined is asked to pick out tints which resemble the hue of certain standard test skeins. The first test is a skein of light green, the second test is a skein of light purple or rose, which is the complement of the green. A third test which is only confirmatory and suitable for persons whose defect is extreme, is a scarlet or brilliant red. The standard green is put into the person's hand, and with correct perceptions he has no difficulty in matching it with congruous colors. But if his color sense is defective, he will be guided not by the tint, but by the luminosity of the shades. Blues and yellows he understands and avoids; but among tints of a greenish hue he will take up grays, light browns, yellows, and skeins of tan and dove color, "confusion colors." He will hesitate over uncertain colors and when he has picked out all which he regards as similar to the green, this bunch will be put aside and he will proceed in the same way with the second test, the light purple or rose. In this hue red and blue are mixed, the red predominating. The first test shows that the color defect is of the red-green variety; the second test will decide whether the deficiency is greater with red or with green. The red-blind individual chooses out the light reds and grays and greens, and avoids the dark. The green-blind selects the dark and avoids the light reds and violets. If with the second test only purple skeins are selected, the person is only partially color-blind for red and green. In case, besides purples, he picks out only blue and violet or one of them, he is completely red-blind. If with purple he selects only green and gray or one of them, he is completely green-blind.

[1] Graefe's Archiv, xxx., 11, 154.

The third test applies to those who are totally red-and-green blind and is confirmatory of the second.

A method similar to the above has been devised by Dr. Wm. Thomson, of Philadelphia, in which the skeins are arranged upon a frame and numbered, and the results of the examination are recorded on charts. It enables the examination to be made with facility by persons who have no expert knowledge, and the results can be sent to a central bureau.[1]

If the very rare case of violet or blue-yellow blindness should appear, purple, red and orange will be confused in the second test. Total color-blindness will be recognized by a confusion of all shades having the same intensity of light, and is also rare.

Stilling has published isochromatic tables for detecting color-blindness. Colored letters made up of small blocks are printed on a ground of confusion color, and they consequently cannot be made out by the color blind. The edition of 1880 is the best.

Donders used colored glass viewed by transmitted light. Woinow employed Maxwell's revolving discs; the method by colored shadows, and other methods have been used. Holmgren's worsteds are on the whole the most satisfactory. For elaborate details on this topic see Jeffries[2] and Burnett.[3]

Very recently Prof. Langley (*American Journal of Science*, xxxvi., Nov., 1888) has published the results of experiments upon the perception of colors in normal eyes. He found among four persons, all of whom had supposably normal perceptions, extraordinary differences; two were myopic and their ability far exceeded the others. His general conclusion is that, apart from individual peculiarities, the time required for the distinct perception of a very faint light is about one-half second. The visual effect produced by any given amount of (luminous) energy varies enormously according to the color of the light in question. For details see his paper and see also the article by Cattell in *Brain*, vol. 8, p. 294, 1885–86.

Light Sense.

In case of an occluded pupil, and of cataract, we manifestly are called upon to examine the degree of light perception. But in disease of the retina and optic nerve, and in cases of amblyopia it may also be important. Retinitis pigmentosa, hemeralopia, and nyctalopia are instances in point; and so is detachment of the retina. Opacity of the media cannot quench the light sense with a normal retina, nor can closing the lids do it.

A rough mode of testing is by passing over the eye the shadow of the hand or of the outspread fingers, or by throwing upon it the light from the ophthalmoscope removed to a considerable distance.

[1] Trans. Am. Oph. Soc., xvi. meeting, 1880, p. 142.

[2] "Color-Blindness," Boston, 1880. [3] Archiv for Ophthal., vol. x., p. 1.

Digitized by Harvard College Library

In the latter method the patient is asked to state from what direction the light comes, which gives the projecting power, likewise.

If an isolated spot of the retina is deficient in light perception we call it a *scotoma*, and if this be absolute, *i. e.*, for white light, it is known as a *positive scotoma;* if it refer only to the perception of colored light, as, for example, red, it is called a *negative scotoma.* The former implies reduced or absent form sense, the latter may be compatible with good visual acuity.

Deficient perception at the periphery has been already referred to under perimetry.

There is no recognized standard of normal light sense. The best known instrument for its examination is the photometer of Förster. It is a square box in which are placed black lines equal to Snellen LX, at one-third of a metre from the eye. A standard candle illuminates them and the degree of light is regulated by a window whose size is variable. When this window is two millimetres square we have the normal minimum and it can be enlarged to 1500 square mm.

Other methods, as by rotating discs, and by letters printed on gray backgrounds (Bjerrum), have been suggested, but for clinical purposes the simple methods above mentioned usually suffice.

The sensitiveness of the retina may be exhausted by exposure to very strong light, thereby producing total blindness. Leaving out of view direct sunlight and the electric arc light, the retina will become fatigued by prolonged exposure to light of much less intensity, and for this reason an increase in the number of gas burners beyond a certain luminosity blunts the sensibility of the retina. Artificial light is inferior to daylight (certain forms of electric light excepted) because it contains fewer blue and green rays. See remarks on p. 24.

Subjective sensations of light may be referred to. They are produced by pressure on the eye, by the galvanic current as it is connected or broken, by effort of accommodation in the dark. These appearances are called phosphenes. In certain cases of choroiditis and retinitis subjective light phenomena, like coruscations or a diffused glow are very troublesome. With widely dilated pupils (mydriasis) a diffused red light sometimes appears. A similar blue color is sometimes seen by patients immediately after the extraction of cataract.

The retina retains the impression of light for an appreciable time and with some persons the duration is annoying. It varies from $\frac{1}{40}$ to $\frac{1}{3}$ of a second, and gives rise to the so-called after-

Digitized by Harvard College Library

images. These are in colors complementary to the quality of light received. Bright windows of painted glass excite phantom images of opposite colors. Rapid alternations of light and shade will excite in the retina sensations of color (Rood)[1] at first green and with more rapid alternations, red. If we steadily gaze upon a very bright object and then close the lids, we have for a few moments a correct picture of the object in its light and shade, a positive after-image; soon the reverse picture appears, which is the negative after-image, and it gradually fades. (See Leconte,[2] Aubert.[3])

If in a dark room we look at a lamp through a pin-hole in a card, which we move quickly to and fro across the area of the pupil, we shall presently behold a phantom representation of the vessels of the retina. This phenomenon is called after the name of Purkinje, who first described it. It is caused by the displacement of the shadows of the retinal vessels cast upon the rods and cones as the angle at which the rays fall upon them quickly varies. It proves that the rods and cones are the percipient light structures; and the amount of parallax has been calculated, and the distance of the rods and cones from the blood-vessels deduced. The same appearance can be produced by condensing on the sclera by a 2-inch lens the light of a lamp in a dark room, and moving it rapidly over a small surface.

The Visual Purple.

Experiments upon living animals, made first in 1876, by Prof. Boll, of Bologna, and subsequently pursued by Prof. Kühne, of Heidelberg, have demonstrated the existence of a pigmentary substance in the retina, which is called the *visual purple* or *visual rose*. It is a secretion from the hexagonal pigment-epithelium of the retina.

Its properties are summed up by Dr. Ayers (in the *New York Medical Journal*, May 1881, p. 582), who says, that it is an albuminoid compound belonging to the outer segments of the rods and not to the cones. Its extraction requires a ten-per-cent solution of sodium chloride, or a two-per-cent solution of gall, and other steps which a foot-note describes. It is a photo-chemical substance, sensitive to light, and in man becomes bleached to a yellow hue. In some fishes, chiefly the deep-sea varieties, it is not changed in color by light, but remains purple. Its secretion in animals is increased by pilocarpine and muscarine. We know of no drugs or nerves whose action can diminish its quantity. When a person is for a long time kept in darkness, it becomes abundant; if bright light

[1] "Modern Chromatics," N. Y., 1879. [2] "Sight," D. S. Appleton, N. Y., 1882.
[3] Graefe und Saemisch, v. iii. 2, p. 508.

Digitized by Northern College of Optometry

be admitted the eye is painfully dazzled. On the other hand, it is bleached by light to a yellow hue, and perhaps because yellow is the most strongly antagonistic to chemical rays of light, the retina is not suitably stimulated and we do not see well on first entering a dark room. The purple seems needful to the appreciation of dim light, and its conversion into yellow may be a defence of the retina against the injurious influence of very bright light.

It is seen that the retina, in its chemical properties, bears out the analogy of the eye to a photographic camera in the most surprising and complete manner. Indeed, by confining rabbits in darkness for a length of time and then exposing them to a bright window crossed by bars, decapitating them in a room lighted only by a sodium flame, and treating the retina by a solution of alum, and in a manner similar to the usual processes of photography, a picture or optogram can be developed and fixed in the retina and preserved for future study. Such a picture is given in the diagram (Fig. 15) copied from the *New York Medical Jonrnal*, March, 1881, and taken by Dr. Ayers, who worked with Prof. Kühne in his laboratory.

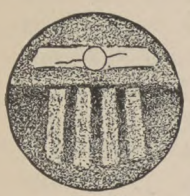

FIG. 15.

It is natural to imagine that this remarkable substance has an important relation to sight, but we cannot define its functions, because it is wanting in the cones which give us the best vision. The yellow material which gives name to the macula lutea, lies in the front retinal layers and has nothing to do with the purple. It is impossible to discover the purple by the ophthalmoscope, and it has nothing to do with the red color of the living fundus, as has been proved by Becker in albinos. It has been proved also that animals whose retina has been bleached not only can see, but can distinguish colors (Kühne).[1]

NOTE.—In the test series of Snellen the intervals from one line to the next are as follows:

Series:	$\frac{20}{X}$	$\frac{20}{XV}$	$\frac{20}{XX}$	$\frac{20}{XXX}$	$\frac{20}{XL}$	$\frac{20}{LL}$	$\frac{20}{LXX}$	$\frac{20}{C}$	$\frac{20}{CC}$
Intervals:	$\frac{2}{3}$	$\frac{1}{3}$	$\frac{1}{3}$	$\frac{1}{6}$	$\frac{1}{10}$	$\frac{1}{9}$	$\frac{1}{12}$	$\frac{1}{10}$	

The test types of Dr. John Green have less irregular intervals, but are by no means uniform. By the decimal system (Monoyer's) the interval between each line is $\frac{1}{10}$ and the degrees go from 0.1 to 1.0. What in Snellen's series is written as $\frac{20}{XL}$ becomes 0.5, and from $\frac{20}{XX}$ to $\frac{20}{XL}$ we have five lines instead of three. We secure

[1] "Handbuch der Physiologie," dritter Band, i. Theil—Gesichtssinn, 235 to 342, 1879. See also an account by W. S. Ayers, New York Medical Journal, May, 1881.

Digitized by Illinois College of Optometry

greater precision in determinations of vision, at the early stages of its decline, and also greater accuracy in correcting errors of refraction.

For additional detail upon the physiology of sight the reader is referred to "Text-book of Physiology" by M. Foster; Part IV., 1891, MacMillan & Co., sixth edition.

Digitized by Illinois College of Optometry

CHAPTER III.

HOW TO EXAMINE THE EYE.

A. We naturally first give heed to the external parts and we note the *lachrymal sac*, and press it with the finger; *the lids*—their edges, the cilia, the Meibomian follicles, lachrymal puncta, their cutaneous and their mucous surfaces, and they are to be turned over; the width to which the lids separate, their mobility—whether everted or inverted or thickened; the length of the palpebral slit; *the cornea*—whether transparent or blurred by opacity, its shape or curvature; the ocular *conjunctiva*—its color, the appearance of its vessels; the depth of the anterior chamber; the *pupil*—its size and mobility, its clearness; are both the pupils alike? the *iris*—its hue and brilliancy—is it adherent to the cornea or to the lens? is its periphery retracted? is its tissue healthy or atrophied? do both irides look alike? the *crystalline*—is it clear or smoky, or positively opaque?

Critical inspection of the cornea, iris and lens is of great importance, and while marked lesions will be obvious enough, the finer changes in the cornea and lens demand special attention. This is true both of the cornea and of the lens.

A good light and a fair exposure of the eye are to be secured, but great assistance is gained by resorting to two methods which are to be mentioned, viz.:

1st. Oblique or focal illumination by means of a convex lens whose focus is about two inches. This may be used in ordinary daylight, the patient being at a little distance from the window; or, still better, the examination may be made by gaslight in a dark room.

The lens is held about two inches from the eye, condensing the light on one side of it while the observer looks from the other side. The focus of the lens is made to play over the eye in all directions, deeper and more superficially as the various parts are to be examined. The contrast between the intense light of the focus and the shadow which surrounds it constitutes the chief advantage of this proceeding. Caution must be used not to subject cases to this method which are likely to suffer harm by the strong glare, but experience will soon indicate what patients are not to be thus investigated. For slight opacities or facets and in searching for foreign bodies upon the cornea, or for studying the iris and pupil, and for exploring the crystalline lens and anterior portion of the vitreous humor, oblique illumination is indispensable.

Digitized by the Osler Library of Ophthalmology

One may also use a magnifying lens in addition to the illuminating lens. Brücke's dissecting spectacles are extremely useful in giving stereoscopic vision besides magnifying power. They consist of a pair of convex glasses of 12 inches focus combined with prisms of about 7°, set with the bases inward.

2d. Another device of value is illumination by a small plane mirror, reflecting a dim light. If we have no other than the mirror usually made for the ophthalmoscope, which is concave and of about seven inches focus, it must be held at twelve or fifteen inches from the patient's eye to properly reduce the light. The examination must be made in a dark room, the lamp placed about six inches behind the head, so as to leave the face in shadow. Viewed through the hole in the mirror, at the distance of a foot or more, whatever opacities may exist in the cornea or in the lens are easily revealed. By little tilting movements of the mirror the light plays over the eye, and if opacities exist they flit like shadows across the illuminated pupil. A shadow appears where, before, the surface looked transparent, and again a clear surface comes out as the shadow glides to another spot. The same phenomena occur when the cornea has lost its natural curvature, and has become conical or bulges in any manner. The shadows caused by irregular reflection sometimes are very striking. More will be said on this point when we deal with diseases of the cornea and of the crystalline lens.

Fig. 16.

Examine the *tension* of the globe by pressure with the finger—is it elastic, yet firm, like the normal eye, or too resisting, or softer than normal? Does pressure cause pain, especially if made upon any spot of the ciliary region? Ascertain if the cornea and conjunctiva, if touched by a fleck of cotton, or by a hair, exhibit their proper *sensibility*.

Attend to the *mobility* of the eye, that its range of motion is sufficient in all directions, without tremor or spasm, or lagging; that the two eyes move in harmony, both for near and for distant objects, and in all directions. Whether there is apparent binocular vision, or if strabismus exist. A patient may volunteer the state-

Digitized by Illinois College of Optometry

ment, that he sees double, which may or may not suggest itself by the behavior of one or both eyes, and there will follow the suitable method of inquiry about double images and muscular paralysis. Only by systematic use of prisms can this topic be fully considered.

Protrusion of the globe on one or both sides will not be overlooked, and exploration of the border of the orbit with the finger, and especially of the foramina of exit of the supra-orbital and infra-orbital nerves, will not be omitted.

In a great number of cases the examination will not go farther, because there is some obvious malady which demands immediate action and further inquiry is superfluous.

Sometimes to accomplish what has been proposed will be difficult, because pain or spasm of the lids or photophobia or fear, makes the patient refuse to permit a complete investigation. Especially is this the case with burns and injuries, with cases of keratitis and iritis and conjunctivitis.

We may often gain our end by using a 4% solution of muriate of cocaine several times within twenty minutes. At first it smarts, but soon it allays distress and photophobia and also reduces hyperæmia. With children we may be obliged to employ anæsthetics, and my preference with them is for chloroform. In fact, I would use it rather than ether in many older subjects, when a brief inspection or quick manipulation is the only requirement.

The value of anæsthetics is greatly to be insisted upon in dealing with young children who have acute conjunctivitis and acute keratitis. Not only are they spared the infliction of pain, but the eye is less likely to sustain injury. It is not necessary to give anæsthetics in every examination, but ofttimes efficient treatment can be practised in no other way. I once treated a child, aged about five years, for granular conjunctivitis, during nine months, and gave her chloroform about eighty times. She not only got well of the disease, but evinced no ill effects from the chloroform, either at that time or in her adult life. The great immunity of children from evil effects of chloroform is well known.

B. We now give attention to the functional examination of the eye, and to the appearances to be seen by the ophthalmoscope.

A functional examination includes, 1st, the acuity of vision, for which we need test types, and a box of trial glasses; 2d, the field of vision, for which we want a perimeter; 3d, the color sense and sometimes the light sense; 4th, we inquire into the function of the muscles as to their adduction and abduction, etc., both for parallel axes and during convergence for the working point, and, 5th, we investigate the accommodation.

When examining visual acuity we are obliged to correct errors of refraction, and to discover them we have various methods at

command. The chief of these are the box of trial glasses, the ophthalmometer, and the ophthalmoscope. The first is to a great degree a subjective mode of examination, and liable to various sources of error. The second is purely objective, and if available is invaluable within its proper sphere. The third is also largely objective in its method, and if the observer is sufficiently expert he will often thus detect errors which trial glasses have either failed to discover or have reported falsely.

For any knowledge of the deeper parts, viz., those behind the crystalline, we are wholly dependent on the ophthalmoscope. To this we shall next give attention.

Digitized by Illinois College of Optometry

CHAPTER IV.

THE OPHTHALMOSCOPE.

THE invention of the ophthalmoscope by Helmholtz in 1851, was the result of a careful study of the conditions which ordinarily prevent the pupil from emitting light from the eye, or why it looks black. He demonstrated that this accorded with well-known laws of optics, of which one is that light passing through a lens follows the same lines both when entering and when returning, in case any can return. Hence, with a pupil not larger than four millimetres, an emergent beam is very small and must go straight to the luminous source in a path so narrow, that an observer will not be able to catch it, without screening off the light with his head. If, as Loring has pictured, an observer look through a tube traversing a candle flame held close to his own eye, he can then catch light reflected from another eye. Helmholtz's device was to reflect the light by a transparent mirror, consisting of three slips of plane glass. He set them at the angle of greatest polarization, so as to reduce the dazzling effect of reflection from the cornea. Ruete, in 1852, proposed a perforated metallic mirror. All the optical principles involved were fully discussed by Helmholtz (see "Physiologische Optik," 1867), and it has been left to others to improve practical details and working instruments.

The mirrors are either plane or concave. The latter usually have a focus of about seven inches; for special cases it may be shorter. The mirror need not be large, as Wadsworth has shown, for the useful part is very near the sight hole. The latter should be about 3½ to 4 mm. in diameter.

Artificial light is commonly used, while by proper arrangements, sunlight can be employed.

There are two methods of examination, viz., the direct and the indirect, or that with an upright image and that with an inverted image.

In employing the *direct* method, it is obvious that the surface commanded by the eye of the observer will be most extensive if the mirror be as close as possible to the patient, just as we would peep into a room through the key-hole. To view satisfactorily the fundus oculi—supposing its optical structure normal or as it is called

emmetropic, and with its accommodation suspended—the observer must put his own eye into a state for reception of parallel rays, *i. e.*, look as if the object were far away, notwithstanding he knows it is only about an inch distant. He can use but one eye ; what the other sees must be disregarded, or it must be closed. The practical details are as follows:

We darken the room and use a single light—an Argand gas-burner or a student's lamp. The object to be sought for is the optic disc, and the patient is bidden to look straight forward, while the observer looks in from the temporal side at an angle of about 15°. For the examination of the left eye the observer's left is used, and for the right eye the observer's right; the place of the lamp

FIG. 17.

being shifted and the instrument put into the corresponding hand; the observer comes as close to the eye as possible, and this may be within one inch or even within fifteen millimetres. If now the eyes of both be normal in refraction, and in both the accommodation be entirely at rest, the details of the eye-ground will be easily seen.

The other method, called the *indirect*, or *by the inverted image*, is as follows: the observer holds the mirror twelve or fourteen inches from the patient, and brings before the latter's eye, and within two inches of it, a biconvex lens of two and one-half inches focus. This lens condenses the light from the mirror, and also collects the emergent light into an inverted image which lies at about two and one-half inches from the lens, between it and the mirror. The observer examines this aerial image, and not the eye. It is bright, small, and covers a larger surface than is to be seen with the indirect method, and shows better the relation of the parts.

Digitized by the College of Optometry

To know where to direct the light, the observer should keep both his eyes open, and rest the upper edge of the mirror on the inner end of the brow. When he has thrown it on the eye, he will be attracted and embarrassed by the reflection from the cornea. This annoyance is greatest when the region of the macula is under inspection. One learns, after a time, to look beside this reflection and ignore it. When using the indirect method, the biconvex lens furnishes in addition two reflections of the mirror as small, round spots, and these are gotten out of the way by giving it a slight inclination. In this kind of examination the corneal reflex sometimes seems to cover the whole field. A little change in the position of the lens or mirror will remove it.

FIG. 18.

The direct method of examination presents fewer difficulties of instrumentation than does the indirect method, but it offers a more complicated problem than the other, because the refractive condition of the eye must be determined, and, if erroneous, must be corrected by proper glasses before the inspection of the fundus can take place. What in the beginning is a difficulty, becomes, after a time, a most valuable quality of the direct method.

What is the extent of field and what the magnifying power by these respective methods? It is assumed that both observer and observed have normal eyes, whose nodal point is 16.6 mm. from the retina. With the *direct* method the extent of field may be thus stated: If the observer could make his own nodal point coincide with the anterior principal focus of the patient's eye, he would have a field equal in size to the patient's pupil. This would bring the eyes within about 7 mm. of each other, which is not feasible. At

Digitized by the Internet Archive of Optometry

the nearest approach, with a pupil of 4 mm. we have a field of about 2 mm. or practically what covers the diameter of the optic disc. Another limitation is the size and form of the light employed. We see its image on the fundus long and narrow, and the bigger it is, the larger the illuminated space. It follows that we can view only a very small portion of the fundus at a time. The *magnifying power* will be that of a lens about 15 mm., or $\frac{3}{5}$ inch focus, and the distance from the eye is unimportant. It may be stated in terms of angles or by a conventional linear standard. By the former it will be 5° 43′, by the latter, taking 10 inches or 250 mm. as the distance of distinct vision, it will be 15 times, if we take 12 inches or 300 mm. as the standard, we have 18 times magnifying power.

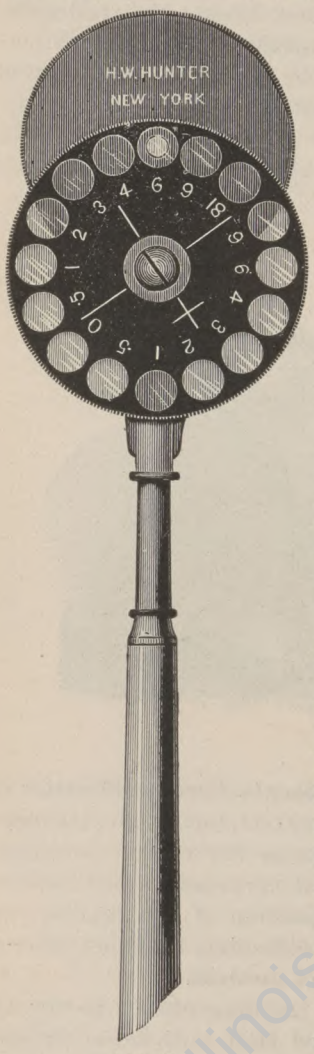

FIG. 19

By the *indirect* method the extent of field is determined by the diameter of the objective lens and its focal length; the latter being the more important. If this be $2\frac{1}{4}$ inches or 60 mm. focus, and the diameter be $1\frac{1}{3}$ inches or 30 mm. the extent of field will be 8 mm. diameter. This, however, is not realized because of the shape and size of the gas or other light. It amounts to about 5 diameters of the disc. Magnifying power is also determined by the focal length of the objective lens. With one of $2\frac{1}{4}$ inches, we have about 4 times, with a lens of 3 inches we have 5 times. That is, the weaker the lens the greater the amplification; at the same time the smaller the field.

Intensity of illumination is brighter with the indirect than with the direct method.

To be prepared for the various refractive errors which will be met, and also to correct such as may belong to the observer, a series of convex and concave glasses are placed behind the mirror. In the early instruments these were few in number and the mechanical parts simple. But as the value of the instrument in diagnosticating refractive errors became more fully appreciated, the number of glasses has been increased and the mechanism for them

Digitized by Illinois College of Optometry

more complex. No one has cultivated this kind of improvement more successfully than Loring, yet there are many other good devices, by Couper, Nettleship, Jackson and others. A moderately complete set of glasses is indispensable, even though accurate diagnosis of refractive errors is not sought. Without them one will often be limited to the use of the inverted image in studying the pathological changes of the fundus. In medical ophthalmoscopy this would be a serious hindrance to a just appreciation of changes in the optic nerve and retina. Fig. 19 shows a simple style of instrument

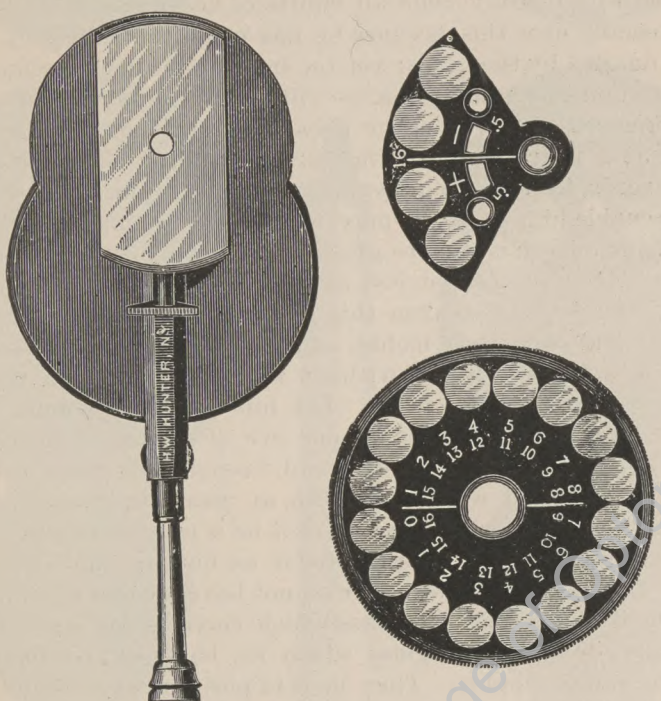

FIG. 20.

with 8 concave and 7 convex lenses. Still another, by Loring (see Fig. 20), gives 24 concave and 23 convex by interposing a quadrant on which are strong plus and minus glasses, and the series is still farther enlarged by using what are called half numbers.

Another arrangement has been introduced by the writer to enable an observer to command the series of lenses without removing the instrument from his eye. This is done by cog-wheels playing upon two discs which contain the lenses, and besides a full series of spherical glasses, cylindric glasses from the spectacle box can be inserted in a spring clip. See Fig. 21, p. 45.

Digitized by the Illinois College of Optometry

A long handle is a decided convenience unless a patient is in bed, when the ivory portion may, if needful, be unscrewed.

Another form of ophthalmoscope is the binocular (Giraud-Teulon) which gives stereoscopic effect and is available only for the inverted image. It is seldom employed. There are fixed or demonstrating ophthalmoscopes, Liebreich, Cusco, etc. Burke substituted a concave mirror for the convex lens in getting the inverted image and gains greater magnifying power.

In learning to use the ophthalmoscope, the first requirement is that both parties lay aside all efforts of accommodation. The patient usually does this, because he has no object to inspect, and his eye is dazzled by the glare; yet too much dependence cannot safely be placed on this assumption, as will be dwelt upon hereafter. The inexperienced observer never does this, but looks as he always would at a near object, and not as he would at a distant one—in other words, he calls in play his accommodation. To prove this and to enable him to see, he may, when using the direct method, put behind the mirror a concave glass of 10 inches focus. Then he will see the bottom of the eye, just as he would read a book ten inches away. But let him weaken this glass to 20 inches, and again he will see; and then to 40 inches, and perhaps he still will see. His problem is to see clearly, without any glass and with no effort. He must cultivate this habit. Let him practise looking with a convex glass of 8″ focus before one eye at a page 7½ inches away, or as much farther as he can read, keeping the other eye open. He will finally find whether he can, at pleasure, utterly abandon accommodation, or what fraction of it he is obliged to use. Whatever that may be, he is to allow for it as his personal equation of error. If, however, the observer do not have normal eyes, he must put behind the mirror the glass which corrects his sight for distance, plus or minus the glass which his habit of accommodation compels him to employ. Then he is in position to examine abnormal eyes. In doing this he will have to add to his correcting-glass, or subtract from it, the glass which corrects the error of the patient's eye. On a later page a slight modification of this statement will be made, and more details mentioned.

The following method of conducting an examination is suggested as being sure to cover all the points of a case.

First, illuminate the eye with the mirror from a distance of sixteen or eighteen inches, and let the light play from side to side over the cornea. This will show opacities in the cornea or lens and the degree of luminosity of the fundus. If the eye be of decidedly abnormal refraction or ametropic, retinal blood-vessels will be visible. They may indicate that the eye is either near-sighted or far-sighted. If the former, the vessels will move in a direction opposite to the

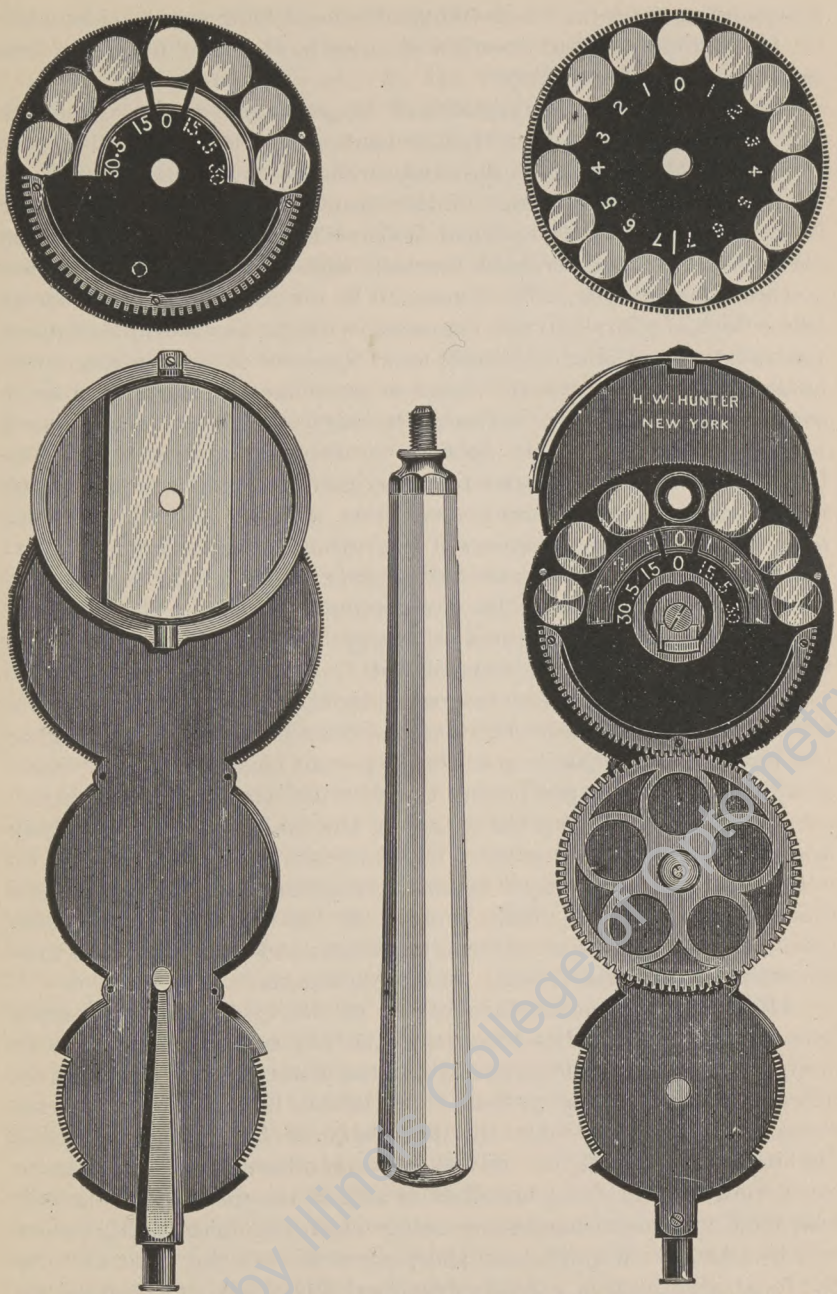

FIG. 21.—The mirror, besides swinging in the trunnions, may be rotated in a circular direction and thus assume any angle. The front disc is moved by the lowest wheel and the back disc by the upper and exposed wheel. There is a spring clip on the back of the instrument to carry a cylindric glass. In other particulars the instrument is copied after Dr. Loring's latest model. It gives command of a complete set of spherical glasses, both positive and negative, amounting to seventy-six in number, and cylindric glasses may be inserted at pleasure from the spectacle-box.

Digitized by Illinois College of Optometry
Carl F. Shepard Memorial Library
Illinois College of Optometry
14014

motion of the observer as he moves his head from side to side, while for far-sightedness the vessels will move in the same direction with the motions of the observer.

Having this preliminary idea of the state of the eye, the biconvex or objective lens may then be put up for the inverted image. The lens is held by the thumb and forefinger, while the little finger takes a support on the edge of the temple. To find the nerve, say in the right eye, let the patient look at the observer's left ear and *vice versa;* or look straight forward while the observer moves 15° to the temporal side. The lens is to be moved a little from side to side, which of course carries the image with it; and it will be noticed that parts upon deeper planes, as in the case of excavation of the optic nerve, have a greater range of movement than do the more superficial parts. For instance, the edge of the nerve will move less extensively than its bottom if there be excavation. The little finger may be allowed to press on the eye, at the same time lifting the lid, and thereby determine whether a little increase of tension will cause pulsation of the retinal vessels. After inspecting the nerve, the patient should be directed to look in every direction, to bring all parts of the eye-ground into view. The region of the macula will also be noted, although this will often not be well seen unless the pupil has been dilated.

Next, the eye should be inspected by the upright image, the observer coming so close to the face as even to touch it, and bringing the light to the requisite position to permit close approach. Now, it will be needful to put behind the mirror such glasses as neutralize refractive errors, and the details of the fundus will be more fully appreciated, besides learning what is the state of refraction. I do not mean to be understood as intimating that the diagnosis of the state of refraction will easily be made by the beginner—on the contrary, he will meet not a few difficulties; yet these may be surmounted by moderate ability and perseverance.

After having studied the bottom of the eye, a strong convex lens, say of three inches focus, may be put behind the mirror to enable one to inspect the crystalline, the anterior part of the vitreous, and the cornea, the patient being told to look in different directions, to throw into view the periphery of the lens or vitreous opacities not in the field. It will be well to turn down the light to get a view of very faint opacities in any of the media and one will look from various distances, by doing which the magnifying power will be altered. Finally, turn the patient to face the light and use the focal illumination already described (page 36). Of course, regard must be had to the sensitiveness of the patient's eye and its liability to injury by intense light. Very rarely does any result, and this is specially true of lesions of the optic nerve, retina, and

Digitized by Google

choroid. In very many cases, only the direct method need be used, and to the fundus as thus seen we will now call attention.

The Fundus Oculi as seen by the Ophthalmoscope, and especially by the upright image.—The larger the pupil the easier and more complete will be an examination, but one will seldom need to use atropia. If mydriasis is required, a 4% solution of cocaine will usually give sufficient enlargement in 20 or 30 minutes and it passes in a few hours. The object first sought is the optic nerve, which appears as a circular disc on which the retinal vessels are seen. For the recognition of the anatomy of the nerve compared with its ophthalmoscopic picture see Fig. 22. Its color varies from pinkish-white to deep red; often the whole surface is not of the same hue, a part being red and the rest pale, and this may be respectively the nasal side contrasted with the temporal side, or the circumference contrasted with the centre. The whiter parts reflect light more brilliantly because they are sunken and concave, and the paucity of fibres in the depressed part favors the penetration of light to, and its reflection from, the lamina cribrosa. The depression or so-called excavation often found in the nerve may be central and small, or in extent it may exceed half its diameter:—it may be a slope on the temporal side, or more rarely downward; or the outer half may be almost flat and below the level of the inner, like a step. The nerve is sometimes a true papilla, and the highest part may be central or on the nasal side. In all cases the tissue is translucent, so that one looks through a depth of substance, and the limit of inspection is the lamina cribrosa. The latter when seen is densely white, and is often mottled with dark spots. As the nerve-fibres come through its meshes, they lose their neurilemma and become transparent axis cylinders. The nerve is sometimes oval, with its long axis vertical, and, even when truly circular, may by reason of astigmatism seem to be oval in any direction. It sometimes has an irregular outline. The border is well defined, being sharply cut by the edge of the choroidal aperture, and often a black pigment deposit extends more or less about it. Sometimes the choroidal opening is appreciably larger than that in the sclera, and a narrow ring of the latter is to be observed. If the optic fibres are heaped together in a certain space, they will be easily recognized as they cross the edge of the disc and extend into the retina, sometimes to a considerable distance. In eyes deeply pigmented, the optic nerve is always by contrast more red, and the nerve-fibres are more distinct. Sometimes they make a complete fringe or aureole of hair-like radiating lines.

The conspicuous feature of the nerve is the network of vessels which appear upon it. They emerge and enter near its centre, and present many varieties of arrangement and subdivision. A single

arterial trunk usually comes up from the bottom of the disc and sends branches above and below, the veins taking a course nearly parallel with the arteries. It would be useless to attempt to describe all the varieties which the vessels present. The diagram from Leber (Fig. 23) gives the vessels and their nomenclature. Besides these main branches, there are many finer twigs which pass from the nerve in the horizontal meridian, and they are most numerous on the temporal side. The number of the vessels on the disc is exceedingly various, and sometimes they spring forward in large curves and take a sinuous course, or may even curve around each other in complete or partial spirals. Such peculiarities will have relation to the vascularity of the general system, and due allowance must be made. Sometimes the walls of the arteries are of unusual thickness for a certain distance beyond the disc, and then they have a whitish border.

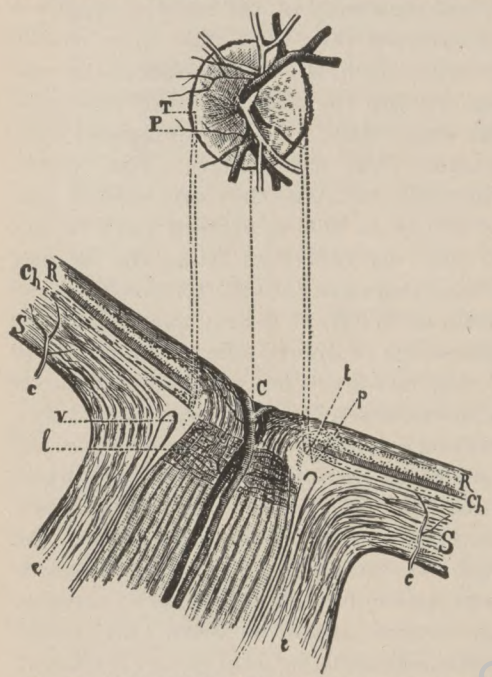

FIG. 22.—*i*, Internal sheath of optic nerve; *e*, *e*, external sheath of optic nerve; *v*, the intervaginal space; *l*, lamina cribrosa; *c*, *c*, posterior ciliary arteries; *S*, *S*, sclera; *Ch*, choroid; *R*, retina; *t*, *T*, tendinous or scleral ring; *p*, *P*, choroidal ring; *C*, optic papilla.

At the region of the yellow spot there are never any large vessels, but it will be seen that from the transverse branches above and below numerous small twigs are sent down which run almost to the fovea. So fine are these that for a long time it was declared that the region of the macula was the most poorly supplied with vessels. This, however, is erroneous, as has been shown by Nettleship, Becker, Loring, and others. Nettleship says: "On comparing different parts of the retina, I find that while in an area of $\frac{1}{2500}$ square inch in the yellow spot region, forty complete capillary meshes can be counted, not more than from six to nine are included in the same area at a spot $\frac{1}{10}$ inch behind the ora serrata, the injection being equally complete in both places. The area of the *fovea centralis*, which is destitute of vessels in the specimen here figured, is equal to about $\frac{1}{4200}$ square inch, and is irregularly oblong. It is scarcely larger than the single capillary meshes at the *ora serrata*."

Digitized by Illinois College of Optometry

Another frequent anomaly is that a vessel may come out at the margin of the optic nerve, or at a point beyond the margin, and go back to the retina. These have been called cilio-retinal vessels (see Nettleship: "Royal London Oph. Hosp. Reports," vol. ix., part 2, p. 161, December, 1877). Mr. N. found one such vessel in a microscopic examination of the optic nerve, and proved that it passed from the sclera, at the level of the lamina cribrosa, into the nerve and to the retina, and such vessels seem in all cases destined to the supply of the region of the macula lutea. The opportunity of seeing them is most often given in the choroidal crescent of myopic eyes.

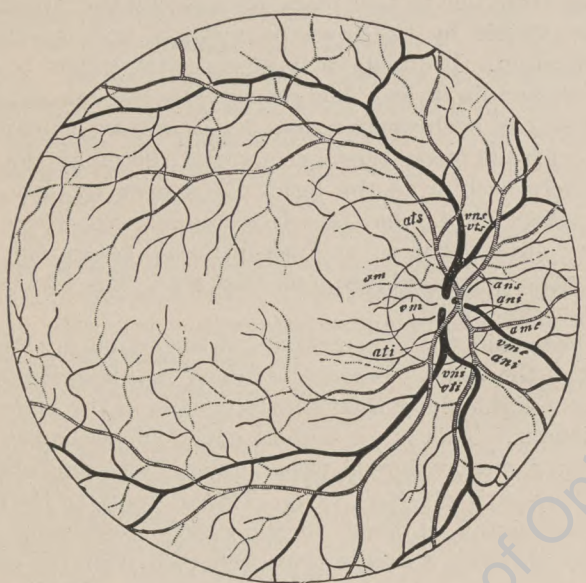

FIG. 23.—Blood-vessels of the Retina. *ans*, Arteria nasalis superior; *ani*, arteria nasalis inferior; *ats*, *ati*, arteria temporalis superior and inferior; *vns*, *vni*, vena nasalis superior and inferior; *ves*, *vti*, vena temporalis superior and inferior; *ame*, *vme*, arteria et vena mediana; *am*, *vm*, arteria et vena macularis.

The retina is to a slight degree discernible as a tissue, notwithstanding its transparency, and near the disc its optic nerve-layer usually appears, with greater or less conspicuousness, as fine hair-like lines radiating from the margin. Above and below they are most marked, and they cluster around the principal vessels. The visibility of the retina, as well as the tone of the fundus, depends chiefly on the quantity of pigment in the epithelium and in the choroid. In blue-eyed persons the retina seems very transparent, and the fundus of a brilliant red. In dark-eyed, and especially in dark-skinned persons, negroes, Indians, etc., the retina seems opalescent, and the hue of the fundus is dull, and of a dun or tan color.

Digitized by Illinois College of Optometry

The pigmentation is always deepest about the central region, because the epithelium is more saturated, while the remoter parts permit the choroidal vessels to be seen as light-red stripes with irregular islets of pigment. The surface of the retina sometimes shows a flashy, silvery reflection, which glances along the vessels and plays about the macula lutea. It alters in place and form, on the slightest movement of the eye or of the mirror, and the spot which it has left has a perfectly normal look. This is seen in dark eyes and in young children most frequently. It is not pathological. Another phenomenon is a circle which sometimes appears at the middle of the fundus, around the fovea as a centre, and has a diameter varying from one to two discs, as seen by the upright image. This is also visible by the inverted method, and is evidently an annular reflection. Probably in these cases the source of reflection is the membrana limitans. The reason why the macula should be the special seat of such appearances is its convexo-concave surface. The fovea centralis often shows as a small glistening dot, more or less completely circular as the light plays over it. Its concavity favors its action as a reflector. In a myopic eye, where this was seen, I have observed it to be most brilliant before the perfectly correcting glass was employed, and that when this was used it disappeared almost entirely.

It has been said that the arteries of the retina are smaller and brighter than the veins. It must be added that they exhibit a well-defined line of light along their centre, which, in the veins, is much less conspicuous. This is an optical effect whose cause has been disputed, and a most valuable paper upon it was published by Dr. Loring in Tr. Am. Oph. Soc., 1873. That it is due to the refractive action of the column of blood in the vessel condensing the light which passes through it and is again reflected from the underlying surface, has been proved to myself by two cases. In one of them there was an effusion of blood beneath the choroid, which made a dark patch. This was crossed by a vein on which no light-streak was present while it traversed this dark surface, but where situated upon the normal choroid, the usual streak was distinct. As the blood-patch became absorbed and a white scleral surface came to view, which was caused by rupture of the choroid, not only did the vessel recover its usual light-streak, but this became much more decided than upon the adjacent portions of the vessel. A second case bearing on this point was one of extreme colloid deposit upon the choroid, having all the brilliancy of the most marked patches of fatty degeneration, as found in albuminuric retinitis. This glittering surface was about two discs long and one disc wide, and was behind one of the transverse retinal arteries. As the artery crossed this spot, the whole vessel was a bright ribbon of light—the central

Digitized by the Internet Archive

streak being intensified and widened so as to equal the diameter of the vessel. On either side of this spot the artery had the usual appearance. It is therefore evident that the light-streak depends chiefly on the reflecting properties of the surface over which the vessels pass, and on the nature of the blood-column. That some reflection comes from the surface of the vessel is true, but it is excessively slight, as proved by my first case while the blood-patch was fresh and dark. The "light-streak" is, therefore, a phenomenon of refraction and reflection, and the light must pass through the vessel from in front and penetrate to the sclera, to be then reflected from the latter and again acted upon by the blood-vessel, which condenses it into the bright, luminous streak. This is essentially the view first announced by Loring (see "Trans. Amer. Oph. Soc.," 1881). Davis coincides with Loring's explanation, having repeated his experiments by letting the blood from the carotid of a cat flow through fine glass tubes (*Arch. of Ophth.* XX. 1., 1891). Story discusses the matter, and agrees with an opposing theory of Schneller, *Ophthal. Review*, April, 1892; while Dimmer is quoted by Story in favor of a totally different theory, viz.: that the reflex in the veins is from the surface of their blood column, and in the arteries is from the axial part of the blood stream (*Ophth. Review*, May, 1892). My observations above quoted have not been noticed by the writer mentioned, and my views remain unchanged.

Pulsation of the veins upon the optic disc is quite common. It is explained by Donders as the effect of the arterial tension communicated to the veins through the vitreous, and causing pulsatory movement on the optic disc, because here the column of venous blood is just escaping from the intraocular pressure. It is most apt to be seen when the veins are large. Schoen was able to study this in a patient whose pulse was only 16 to 23 per minute. He concluded that the venous pulse is merely the effect of the pulse of the artery upon the vein as the two vessels lie in juxtaposition in the optic nerve.—*Klin. Monatsblätter* (Zehender), Sept., 1881. Pulsation of the arteries occurs when the intraocular pressure rises to an abnormal degree, or in cases of disease of the heart (aortic valves) or large vessels, and under some other morbid circumstances. Pulsation of both arteries and veins can always be caused by pressure with the finger, and, if it be made very strong, the circulation can be entirely suspended.

In observing the fundus closely, if the tissues are normal and the refraction perfectly corrected, the retinal epithelium is seen as a granular surface, like the finest emery-paper, and its molecular look is perfectly distinct. A few glistening dots are sometimes seen near the macula, which appear to have no special importance.

Digitized by Illinois College of Optometry

The fovea centralis is always the most difficult spot to examine, especially with undilated pupil. It has a dull, red look, or may return, as above stated, a gray reflection, which may be a partial or complete ring, which flickers at the slighest movement, and is about one-fourth or one-sixth of a disc in diameter. In young persons it is widest and most distinct. The very centre is so deep in color as to be almost brown.

The degree to which the choroid can be seen varies with the pigmentation of the eye. In albinoes the vessels are visible, even about the macula. In greater degrees of pigmentation, some vessels may appear between the nerve and macula, and in all persons they are distinct at the eccentric parts of the fundus. They are of a light pink hue, appearing like flat stripes, and have a curvilinear arrangement and interlacement in distinct meshes. No distinction can be made in them between arteries and veins. Sometimes the place of beginning of the venæ vorticosæ is recognizable. Between the meshes of the choroidal vessels the pigment-stroma is seen in more or less dark patches of irregular shape. The visible choroidal vessels are always broader than the retinal trunks. Immediately around the optic nerve the choroidal pigment is often quite abundant over a considerable breadth of surface, and, as above said, the central part of the fundus is overspread with a uniform layer, which usually completely hides the choroidal vessels. For verification of above description, see colored plate at the back of the book.

Digitized by Illinois College of Optometry

CHAPTER V.

GLASSES.

As we shall have to consider the proper use of glasses in correcting errors of accommodation and refraction, we may say a few words in general upon their varieties and properties.

We have to deal with glasses of spherical curvature which are convex or concave, and we have glasses of cylindrical curvature, also convex or concave. We also have glasses whose surfaces are plane, but not parallel to each other, viz., prisms. Very exceptionally glasses ground to a hyperbola have been used.

In spherical glasses we have the following forms:

The convex are called positive or collective or magnifying glasses, and are denoted by the sign +. The concave are called negative or dispersive or minifying glasses, and are denoted by the sign —. The focus of a glass is the place where the rays from a given object

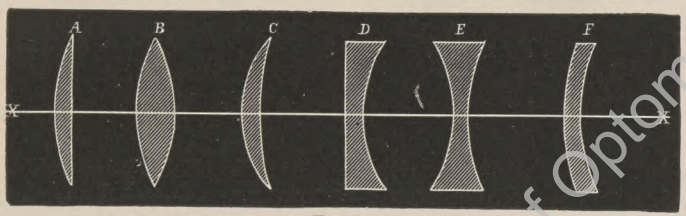

FIG. 24.

cross each other on the axis of the glass. For parallel rays the place of crossing is called the principal focus, and this is understood when no adjective is used. If an object be near enough to the lens to emit diverging rays, these, if they cross, do so at points called conjugate foci. For convex lenses the foci are real and positive, and on the side of the lens opposite to the object. For concave lenses the foci are negative, imaginary, or virtual, and on the same side with the object. But for convex glasses, if the object be situated at the principal focus, the rays after passing the lens will not converge, but be parallel; hence there will be no focus. If the object come still nearer, the rays will be divergent, and the focus virtual. For concave glasses the rays become more divergent as the object approaches the principal focus, and at this point rays cannot pass through, because the divergence becomes too great. In Figure 24,

Digitized by the College of Optometry

we have the principal forms of lenses, viz.: the plano-convex A, the biconvex B, the convex meniscus C, also the plano-concave D, the biconcave E, and the concave meniscus F. The first three are all positive, and the last three are all negative lenses. The biconcave and biconvex are supposed to have curvatures the same on each side, but this may not be, and frequently is not, the case.

Images from plus (*i.e.*, convex) glasses are inverted and smaller, if the object be beyond the principal focus. If the object be at the principal focus, no image is formed. If it be nearer than the principal focus, the image is not real, but is virtual and erect, and larger than the object; the lens then becomes a magnifier (loupe). Images from minus (*i.e.*, concave) glasses are always small, erect, and virtual, provided the object be farther than the principal focus. If an object lie at or nearer than the principal focus, no image can be formed.

Cylindric glasses are ground by a cylindric tool, and have a curve whose maximum is at right angles to the axis of the cylinder,

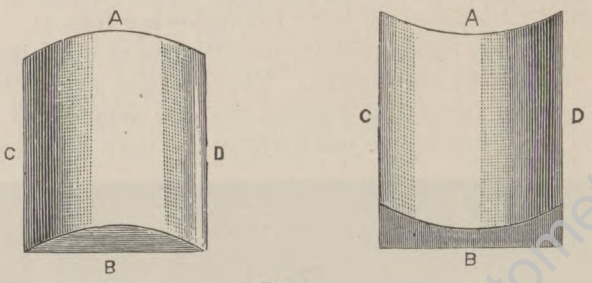

FIG. 25.

while in the direction parallel to the axis there is no curve. Such glasses cannot form images, although they may be said to have foci according to the laws of spherical lenses. Cylindric glasses are shown in Figure 25 and represented with square outlines. In practice they are cut oval like other glasses. The axis is shown to be along the middle of the curve and parallel to the vertical edge.

The Arrangement and Nomenclature of Glasses.—Formerly no better aid could be had in choosing glasses than the advice of the optician from whom they were purchased. At present, ophthalmic surgeons find their function to consist largely in advice upon this subject. They require a trial-case more or less complete, which must contain spherical and cylindric glasses, both convex and concave; also prisms from 1° up to 20°, and a suitable frame. A slip of red glass and an opaque screen are usually added. In giving numbers to glasses it was formerly the practice to do so upon the assumption that the index of refraction of the material was 1.5 ($\frac{3}{2}$),

Digitized by Illinois College of Optometry

and, for a double convex or double concave glass both whose curves were alike, the focus was found by the rule that the focus was equal to the radius of curvature.[1]

Another embarrassment is the want of uniformity in the inch measure among different nations. The following are samples: the English inch is 25.3 mm.; the Austrian is 26.34 mm.; the Prussian is 26.15 mm.; the Paris inch is 27.07 mm. Between the English and the Paris inch the difference is $\frac{1}{12}$. In the numbering of glasses, therefore, two things needed to be readjusted: first, the error arising from regarding the radius of a bi-spherical lens as the equivalent of its focus, and vice versa; secondly, the discrepancy as to the standard measure. The latter objection is overcome by abandoning the use of inches and employing the metric system of expression. The first difficulty is obviated by numbering glasses according to their refractive power and not according to their focus. Refracting power is the reciprocal or inverse of the focus. Thus, a lens of 30 inches focus has a refractive power of $\frac{1}{30}$. This fraction may be expressed in decimal form and it becomes .033. A lens of 20 inches focus has a refractive power of $\frac{1}{20}$, or .05. A lens of 4 inches focus has a refractive power of $\frac{1}{4}$, or .25.

The glasses in actual use began at the numbers with long foci, and came down to those of short foci—that is, from the weak to the strong; but there was no regularity in the progression; no common interval was observed (see column 1 of the table on page 57). Now, for purposes of scientific study, and for convenience in examinations, regularity of interval is highly convenient. Attempts have been made to secure this desideratum, and various intervals have been suggested, viz., the fractions $\frac{1}{216}$, $\frac{1}{120}$, $\frac{1}{80}$, $\frac{1}{60}$, $\frac{1}{48}$. When, however, the metric measure was substituted for the inch, it was also resolved to establish a metric interval which should become the unit of measure and the standard of gradation between numbers. Facility in calculations, and uniformity, both in gradation and in nomenclature, were the objects sought. The unit is a glass of one metre focal length, which in English measure equals 39.37 inches, and is called a dioptry (French dioptrie) (D). In French measure it would be 37 Paris inches. But this interval is too great, and therefore the metre is again divided into fractions. By the old

[1] This results from the formula $F=\frac{r}{2(n-1)}$; in which F stands for focus, r for radius and $n-1$ for index of refraction. If now $r=12$ and $n=1.5$, the formula becomes $F=\frac{12}{2(1.5-1)}=\frac{12}{1}=12$, that is, the focus is equal to the radius. It turns out that the glass now in use does not have the index 1.5, but a higher degree varying between 1.52 and 1.55 (Nagel). Javal assumes it to be 1.54. If we substitute this in the formula, we have $F=\frac{12}{2(1.54-1)}=\frac{12}{1.08}=11.1$. That is, the focus is less than 12 inches, and very nearly 11 inches.

Digitized by Google

method a lens was known by a number which was its radius of curve, and this was assumed to be the same as its focal length. It is now known by its refractive power, and this is expressed by the number of dioptries contained in it. It is seen that a metric measurement of glasses may be quite distinct from the system of dioptries. But, where the metric system has been adopted, the dioptric interval has also been accepted. Nagel gives in Graefe and Saemisch (B. VI., p. 310) the mode of converting the old into the new system of measure. He assumes the index of refraction at 1.528, which is German glass, and with this he finds the equivalent of a dioptry to be 41.5 English inches. If the index be that of French glass, at 1.54, the dioptry becomes 42.5 English inches; with index of 1.53 it becomes 41.7 English inches. Nagel proposes that, in transmuting the old to the new system, 40 inches be taken as the equivalent of the dioptry, and with this Javal concurs, the error not being very large. Therefore, an 80 inch glass $=0.5$D : $40''=1.$D : $20''=2.$D : $16''$ $=2.5$ D : $10'=4$ D. The table on the next page, modified from Mauthner, gives a sufficiently complete series, and according to both systems, accepting $40''$ as the dioptry.

It is seen that at the upper end of the scale the interval between glasses is small, viz., 0.25 D, but that beyond 3.5 D (11 inches) the interval is .5 D, and again becomes still greater. The reason for a large interval among the strongest glasses is that a slight alteration in their distance from the eye greatly modifies their refractive value, and any little change can be thus effected. The special advantage claimed on behalf of the dioptric system is the ease with which calculations can be made in adding and subtracting lenses. For instance, put two positive lenses, + 2 D and + 3 D, together, and their result is + 5 D. If + 3 D and −1 D are united, + 2 D results. If − 4 D and −2 D unite, − 6 D results. One need only deal with simple numbers, and remember the effect of the precedent signs of + or −. If lenses are to be united which are designated only by their foci, the calculation must be made in fractions, viz., + 3 D and + 1 D, become $\frac{1}{13}+\frac{1}{40}=\frac{4}{40}=\frac{1}{10}$. A lens of six inches focus added to one of twelve inches focus $\frac{1}{6}+\frac{1}{12}=\frac{1}{4}$.

The use of the system of dioptries makes calculations simple, but it is a mistake to imagine that it makes any practical difference in selecting glasses. We are compelled to take what the patient actually needs, and whether we express ourselves in terms of dioptries, or of focal length, or of refractive power, is not of strenuous importance. Certainly one dioptry is too large an interval, a half dioptry is often too small, and we may be obliged to choose glasses which do not come under this rubric at all. The essential thing is to know the real refractive worth of our glasses, and whether we reckon it in dioptries or by other means is indifferent.

Digitized by Google

Focus in Inches.	Number in Dioptries.	Focus in Inches.	Number in Dioptries.	Focus in Inches.	Number in Dioptries.
160	0.25	14	2.75	$4\frac{1}{2}$	9.
80	0.5	13	3.	4	10.
60	(0.67)	12	3.25	$3\frac{3}{4}$	10.5
50	0.75	11	3.5	$3\frac{1}{2}$	11.
40	1.00	10	4.	$3\frac{1}{4}$	12.
36	(1.11)	9	4 5	3	13.
30	1.25	8	5.	$2\frac{3}{4}$	14.
24	1.5	7	5.5	$2\frac{1}{2}$	16.
(22)	1.75	$6\frac{1}{2}$	6.	$2\frac{1}{4}$	18.
20	2.	6	6.5	2	20.
18	2.25	$5\frac{1}{2}$	7.5		
16	2.5	5	8.		

The above table shows the glasses according to the old enumeration in English inches and their equivalents in dioptries. We give below the dioptric series and its equivalent in inches.

Dioptries, D.	Inches approximately.	Dioptries, D.	Inches approximately.	Dioptries, D.	Inches approximately.
.5	80	3.5	11	11.	$3\frac{1}{4}$
.75	50	4.	10	12.	$3\frac{1}{8}$
1.	40	4.5	9	13.	3
1.25	30	5.	8	15.	$2\frac{3}{4}$
1.5	24	6.	$6\frac{3}{8}$	16.	$2\frac{1}{2}$
1.75	22	7.	$5\frac{1}{2}$	18.	$2\frac{1}{4}$
2.	20	8.	5	20.	2
2.5	16	9.	$4\frac{1}{2}$	40.	1
3.	13	10.	4		

Attempts have been made to make available a fewer number of glasses than the list above given, by using a spectacle-frame which may carry simultaneously a combination of three for each eye. Dr. E. G. Loring, jr., and Dr. John Green, and Dr. Roosa, have gotten up such a series, and where cheapness is more to be regarded than convenience it will answer the purpose. It must, however, be admitted that three glasses put in the place of one single glass will not in practice be the same, however correct the calculation, because by six reflecting surfaces the loss of light is three times greater than by two surfaces, and for strong glasses allowance must be made for their respective distances from the nodal point. If, however, the choice lies between an abridged series and no spectacle-box, the former alternative is much to be preferred. Such a box is sold by Meyrowitz Brothers in this city.

The power of glasses depends not only on their focus, but on the distance at which they stand from the nodal point. This varies according to the depth of the globe in the orbit, and the height of the nose, and the kind of frame. When, however, a glass is worn at the anterior focal distance of the eye, which is about 13 mm.

Digitized by University of Illinois College of Optometry

from the cornea, it has the least influence on the size of the retinal image—an important fact first pointed out by Giraud-Teulon[1] and later by Knapp. But moved to any other place its influence is important. At this position the visual angle is not altered, but the linear dimensions are changed. Usually the distance is about $\frac{3}{4}$ inch, or 2 cm. This is to be added to the power of a convex lens and subtracted from the power of a concave lens. The practical importance of this fact is chiefly felt among the stronger glasses. One who wears a glass as high as $+\frac{1}{6}$ finds that by slipping it down upon the nose it becomes stronger, and with persons who use cataract glasses this manœuvre is often of advantage. On the other hand, if a "deep" concave glass is worn, say $-\frac{1}{4}$, its power is diminished by holding it away from the eye, and increased if pushed

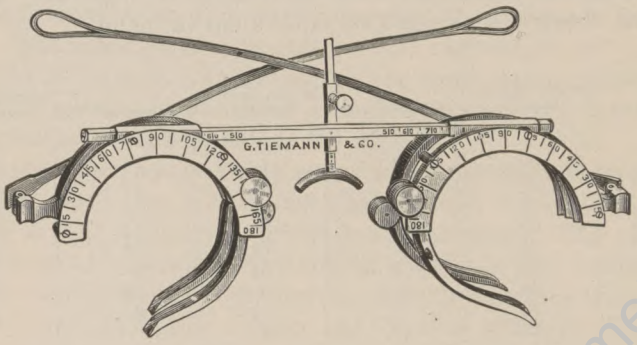

FIG. 26.

nearer to it. When discussing errors of refraction, reference will again be made to these points.

The frame in which trial glasses are placed is not an unimportant matter. There are many contrivances: some very elaborate and likewise heavy. A pattern made by Nachet in 1866, and which is now made by G. Tiemann & Co., New York, has served me for more than twenty years with great satisfaction. Its various adjustments are readily understood (see Fig. 26).

Bi-cylindric glasses are sometimes employed in lieu of bi-spherical lenses when very high numbers are required, as, for example, after extraction of cataract. They give a flatter field and less aberration. In case a cataract glass must have a cylindric surface amounting to two or more, perhaps as many as six dioptries, one surface may be composed of the cylindric convex surfaces with their axes at right angles, and the other surface may be spherical. An illustration is the following: a glass $+ 11.D_s \bigcirc + 6\ D_c\ 180°$ is resolved into $+ 5.D_s \bigcirc + 6\ D_c\ 90° + 12.D_c\ 180°$. That is because in one meri-

[1] Annales d'Oculistique, Sept., Oct., 1869.

Digitized by the Internet Archive of Optometry

dian + 17 D and in the opposite + 11 D being called for, the difference of 6 D is thrown into one surface by employing cylinders at right angles of + 12 D and 6 D, leaving for the opposite side 5 D (17—12), to be thrown into a spherical form. Such a lens is called "toric;" it is much thinner than the usual sphero-cylinder, gives a flatter and more correct field, a wider visual angle and better vision. The discussion of toric lenses is found in an article by Dr. John Green (Trans. Am. Ophth. Soc., 1890, p. 708). They are manufactured by a few opticians in Philadelphia and New York.

PRISMS used in ophthalmic practice are of only moderate angle, usually below 6°, rarely as high as 10°. Rays passing through them are deflected toward their base, and the apparent position of an object is shifted toward their angle. The least displacement occurs when rays fall perpendicularly upon the surface, and because this is plane they are not collected to a focus and do not form images. Some dispersion and decomposition of light takes place, and in direct ratio to the angle of incidence.

For prisms of small angle the degree of displacement is equal to half the angle—and until recently they have been designated simply by their angles. Another nomenclature has now been proposed to put them in harmony with the system of numbering other glasses, viz., according to their effect, and not according to their construction. The degree of deviation is found by combining a prism with a convex lens, and measuring the amount of displacement of the image at the focal plane. In the following table taken from the report of a committee (see Trans. Am. Ophth. Soc., 1888, p. 151), the displacement is given both in degrees and linear measurement (the sine or tangent of the angle, which for small angles are the same).

Angle of Deviation.	Angle of Refraction.	Linear Displacement at 0.5 metre.
0.5	0.93	4.3 mm.
1.	1.85	8.7 "
1.5	2.78	13.1 "
2.	3.70	17.4 "
2.5	4.63	21.8 "
3.	5.55	26.2 "
3.5	6.48	30.6 "
4.	7.40	34.9 "
5.	9.23	43.7 "
6.	11.5	52.5 "
7.	12.58	61.4 "
8.	14 63	70.1 "
9.	15.40	79. "
10.	18.18	88.1 "
15.	26.74	133.9 "

It is proposed to number prisms simply by the figures of the first column, leaving out of view their angle and the index of the glass.

A further development of the idea is the prism dioptry of Prentice (*Archives of Ophthalmology*, XIX., 1, 75, and XIX., 2 and 3, p. 128), in which the unit of measure is a prism which shall cause a tangent deflection of 1 centimetre at the distance of 1 metre, and this prism, P.D., becomes the multiple of the scale. Its angular value can be deduced from the preceding table, which is calculated for one-half the distance—and 1 P.D. will be very nearly a prism of 1°. But Mr. Prentice as a practical optician declares that he has found

by experiment that prisms noted as of 1° produce deflections varying from 9 to 12 millimetres. Doubtless we must aim at absolute accuracy in all kinds of glasses, and for this reason one or other of the above systems will in the future be chosen; yet for the present the notation by angles prevails. In the choice of prisms we cannot yet lay down rules with as much precision as in the case of focalizing glasses, yet they fulfil an important function, as will be explained hereafter. They may be used simply or in combination with convex or concave glasses. The benefit of prisms is found in connection with the functions of the ocular muscles, and the prism dioptry has a relation to the metric angle which will be hereafter referred to.

Digitized by Illinois College of Optometry

CHAPTER VI.

ACCOMMODATION AND ITS ERRORS.

Presbyopia.—The natural abatement of accommodation which takes place from the gradual hardening of the lens, has been already described. It remains to speak of it clinically. The period of life at which the ability to read ordinary print at the usual distance of fourteen inches becomes fatiguing, varies in emmetropes between forty-five and fifty years. At an earlier age there may be need of assistance in feeble persons or invalids, while in the very robust and especially in those who do not greatly tax their eyes in near work the occurrence of presbyopia may be further deferred. The size of the pupil has a material influence, and to its smallness some persons owe their immunity from glasses at the usual age. It is also common to find that a very slight myopia has existed in some individuals who ought, but do not, require glasses in near work. In other cases there may be incipient cataract to account for the refusal of glasses, as will be again mentioned. Presbyopia usually comes upon people like their gray hairs, without announcement or anticipation. They first complain that evening work is troublesome, the light seems dim, and if they bring the work closer, or provide better light, the print fails to become distinct. They find it better to hold the book farther away than formerly; the print seems pale, letters run together, their eyes smart and give pain. Frequently such symptoms are endured for months, and sometimes the reading distance is pushed as far away as the arm can conveniently stretch. On the other hand people who recognize the probable nature of their trouble are sometimes unwilling to have their true age suspected, and they give up reading. It is, indeed, sometimes ungracious to tell a lady that her troubles can be mended by using a pair of spectacles. While presbyopia usually comes on gradually, it sometimes appears very suddenly and also prematurely, as a result of severe nervous prostration.

The question is asked whether it is better to defer the use of glasses as long as possible. To this, the answer should be, that as soon as discomfort arises for need of them, they should be adopted. It is seldom that a glass so weak as .5 D is appropriate. The glass which usually is called for is + .75 D, + 53″ at the beginning.

Digitized by the Internet Archive

Practically many persons get on very well until they require + 1 D. A certain amount of accommodative power must remain in reserve to permit continuous and comfortable work. This law governs all muscular activity. How much reserve there should be, it is of little use to theorize, because the question is for each individual decided, according to his own needs. The reading distance varies greatly among emmetropes, and lies between ten and twenty inches; hence, much latitude is to be allowed in the number of the glass, and the occupation and requirements of the person are to be the guide. A portrait painter, a violinist, a book-keeper with large ledgers to run over, these and other workers use their eyes at a range which is proper to their calling, and not that which any theory demands. As to the amount of reserve accommodation, it need not be especially considered. The indication is to give the weakest glass which makes work easy at the accustomed distance. If one reads at 12″ and cannot easily see Snellen II nearer than 18″ the glass required is $\frac{1}{12} - \frac{1}{18} = \frac{3}{36} - \frac{2}{36} = \frac{1}{36} = 1$ D. In metric measure it is 3 D − 2 D = 1 D. The rate at which the strength of the glass should be increased is to be considered. About this the rule is not absolute. One must be guided by symptoms, usually no addition is needed for two years after first taking glasses; the interval may be longer. The increase should not be by greater increments than .75 D. When 3 D is reached, this glass can usually be maintained for several years. There will be need sometimes of a stronger glass by night than is used by day. In case one wears + 3 D for reading and finds suddenly a notable failure in reading power and must resort to a decidedly stronger glass, there is serious reason for a careful examination; this may indicate the onset of glaucoma simplex. In fact, rapid loss of accommodative power at middle life, whether a glass be employed or not, is a symptom to be regarded with suspicion. It is an accompaniment sometimes of diabetes. When glasses equal to + 4 D and higher, are used, there is a decided restraint in the range of accommodation. The working point is at a nearly fixed and unchangeable distance. Hence it is undesirable to advance to the strong numbers. This limitation is inherent in the working of the glasses. It follows of course that with the loss of A and the maintenance by glasses of the working distance at a given point, that the convergence is kept up at a uniform quantity notwithstanding the abatement of accommodation. Hence some of the annoyances of using reading glasses are connected with the disassociation between convergence and accommodation. Usually the function of convergence adapts itself to the state of A and no special arrangements are required. But where strong glasses are used, their prismatic effect must be remembered. If the visual axes pass through their inner edge,

Digitized by Google

they increase the adduction, while if the glasses are decentred inward and the axes pass through their outer half, they act as abductive prisms. The choice between spectacle frames and eye glasses is to be decided chiefly by considerations of convenience, and it is always desirable to give the glasses area enough to keep the frames practically out of the field.

Second Sight.—It happens sometimes that at or above sixty years of age, persons lay aside reading glasses and rejoice to find themselves restored again to what they call their youthful sight. This occurrence is not very rare and is popularly called *second sight.* I have examined many of these persons and found the explanation in sclerosis of the lens with or without opacities, and a small pupil. It has been clearly shown that the refractive index of the lens is in many cases increased and a real myopia may be induced. I can quote such instances, and many authors have written upon it, *e. g.* Mauthner,[1] Priestley Smith,[2] etc. It does not always follow in these cases that cataract will develop to maturity and one need not therefore mar the happiness of the person by dismal prognostications. While emmetropic persons must in the usual course of nature seek the aid of convex glasses at a certain age, the same necessity befalls hyperopes at a period earlier in proportion to the degree of their error. They have already called largely upon their accommodation, and while they enjoy more of it than others possess, their capacity is sooner exhausted. Hence resort to reading glasses at an early age is presumption of hyperopia.

On the other hand myopes will weaken the glasses which they have been using. With them accommodation has been little taxed, and if they have been used to working without glasses, it will be found that their working range is always limited. If they have a low grade of error they will be obliged to adopt convex glasses for work and retain concave glasses for the distance. The changes to which they will be subject are easily determined by subtracting from their far-point the number of dioptries required for their near-point. A patient with M = 5 D who would read at 13″ or 3 D must use 5−3 = 2 D. One who has M = 2 D and no longer has A sufficient to read at 13″ or 3 D must now use + 1 D.

Spasm of Accommodation.—The structure of the ciliary muscle is in some respects still an unsettled question. Composed of meridional (Brücke's) and circular (Müller's) fibres, the precise course which they assume is not fully determined. Some fibres would appear to be oblique and therefore intermediate in direction between the above sets. It is well known that the relative proportion of these fibres differs in eyes of different refractive quality.

[1] "Vorlesungen über die Optischen Fehler der Augen," p. 460.

[2] Ophthalmic Review.

In H the circular are far more numerous than in M, while in M the meridional exceed the number present in H. Emmert has sought to show that the meridional fibres have an active effect in flattening the lens, which would carry the focus farther back, but such an assertion lacks proof and is contrary to the natural presumption. Myopic eyes accommodate feebly, but on becoming habituated to glasses in early life they soon acquire a normal range. Whether in such cases there would be found a proportionate increase in circular fibres would be worth investigation. In myopic eyes there is always a certain tone of accommodation which is removed by atropia, but in hypermetropic eyes the proportion of permanent contraction of the ciliary muscle is much higher. This amount of effort is what may be called the tonic state of the muscle. It is impracticable to measure its normal limits. On the other hand an undue degree of constant effort is called spasm of accommodation. For example, if a slight hypermetropia is changed into a myopia of 3 D, or should a hypermetrope of 6 D refuse to accept a glass stronger than 1.5 D. Such are extreme cases and we are called upon to take account of them and of lesser grades whenever they are associated with pain or asthenopia.

The *causes* of spasm are local, viz., such as lie in the structure of the eye, in the condition of the motor muscles, in injuries and in external inflammations such as conjunctivitis, keratitis, episcleritis, etc. These are reflex causes of spasm. There are also less frequent cases of spasm due to irritation of the central nervous system, as in epilepsy and hysteria and it may even be associated with hemiplegia; irritation of the sympathetic in the neck and of the cilio-spinal region of the cord have also been assigned as causes. It has been found that one eye alone has been affected, but this is altogether contrary to the rule. An injured eye may set up sympathetic irritation in its fellow of which a component symptom will be spasm of accommodation. All the above-mentioned causes are exceptional and rare, while refractive and muscular errors are by far the common and ordinary causes. That central nervous lesions and various reflex causes have such an effect is indubitable. We are authorized to infer it from the frequency with which the pupil is affected by remote nervous causes. Both the ciliary muscle and the sphincter pupillæ are under control of the third nerve and at independent centres. The sympathetic presides over the dilatation of the pupil, and it is claimed by Emmert that it has the same control over the meridional fibres of the ciliary muscle. This is, however, not proven. We may have spasm of the ciliary muscle without contraction of the pupil; and it is recognized that while the nucleus of the third nerve on the anterior part of the floor of the fourth ventricle looks like a single mass, it is functionally divisible into several centres, the

Digitized by the Internet Archive

centres for the pupil and for the ciliary muscle being in its front yet separate (see page 153).

The diagnosis of spasm rests upon the refraction of the eye when tested by glasses for distance, compared with the refraction proved to exist when examined objectively by the ophthalmoscope, and with the status under the influence of mydriatics. Moreover, if a patient has the habit of reading at a distance too near in proportion to the state of refraction, this indicates spasm. Let a patient read with convex glasses, say 3 D. He should see Snellen II from 13″ to 6″ if his accommodation be $\frac{1}{12}$, or to 4″ if it be $\frac{1}{6}$. If now he can read only at 8″ and brings the book to 3″, the difference between $\frac{1}{13}$ and $\frac{1}{8}$ shows the amount of A which he cannot relax, *i.e.* $\frac{1}{21}$. This examination is not to be accounted of more significance than it deserves, because it must be estimated in connection with other symptoms, and the function of convergence has a special influence which must not be overlooked. For this reason it is my habit not to use simple convex lenses in this mode of testing, but lenses combined with abductive prisms. To these reference will be made in speaking of asthenopia.

The condition occurs chiefly among asthenic subjects, and more especially among young persons and students.

Examination by the ophthalmoscope sometimes shows that even under its illumination, spasm is not relaxed; this may be evidenced by variations in distinctness of the fundus under the observer's eye, or it may entirely elude detection until developed by protracted use of atropia.

Treatment.—In cases of muscular or refractive error the appropriate glasses will be all that is required. In what may be called idiopathic cases, abstinence from use and the employment of mydriatics will usually control the trouble. But in some severe cases the artificial leech to the temples and injections of strychnine (Nagel) have been required. The vigor with which atropia is to be used varies considerably. In some and especially in young subjects, it will have to be pushed to the verge of intoxication; of which the symptoms are always unpleasant and may be dangerous. It is better to keep up the remedy for one or two weeks in moderate doses than to resort to the strong solutions. The most frequent remedy is sulphate of atropia, and for young subjects 2 grains to the ounce is sufficient, or at the most 4 grains to the ounce, used thrice daily, 2 drops in the eye. The dilation of the pupil which also occurs may compel the use of colored glasses. Other substances may be employed in case atropia is inefficient or has unpleasant effects. Such are duboisine sulphate and salicylate and still more recent is hyoscyamine and its isomeric form hyoscine. These alkaloids, while more potent than atropia, are also liable to cause toxic

constitutional effects and must be resorted to with caution. Duboisine may be used in ½% doses, *i.e.*, gr. ij. ad ℥ i., one drop at a time until its tolerance is proved.

It also may happen that the spasm will recur either because the local causes return or because of constitutional conditions. In the obstinate or recurring cases strychnia as a tonic may be used either by the stomach or hypodermically, while special pains must be taken to discover any co-operative cause in weakness of the muscles or in error of refraction, such as hypermetropia or astigmatism. If there be general debility and an asthenic condition, special care must be taken as to food, sleep, exercise, absence of excitement, abstinence in reading and close work.

An extremely frequent cause of spasm is insufficiency of the recti externi muscles, a condition whose occurrence is far more prevalent than has been recognized. To this attention will be called and the remedy will be found either in the use of prisms or in tenotomy of the interni (see note, p. 68).

Paralysis and Paresis of Accommodation.—A merely feeble accommodation and incapability of endurance, is not what is now referred to. We speak of a real abatement of degree irrespective of age. The causes of these conditions may be local, but are generally found in some constitutional disorder or in some lesion of the oculo-motor nerve, either along its track or at its origin, or of the nerves from the ciliary ganglion. We do not take into account the cases of total paralysis of the third nerve which will necessarily include the accommodation. It is not even necessary that the pupil should be implicated. The most frequent cause is diphtheria, and the effect may follow soon after or during convalescence, or at some remote period. It may disappear and recur. It may be the chief symptom of persistence of the poison or it may be only one of many other paralyses. It is asserted by Mooren and Hutchinson that other affections of the throat not diphtheritic, can cause paralysis of accommodation. After fevers, typhoid and recurrent, after articular rheumatism, in diabetes, in trichinosis, in cerebro-spinal sclerosis, in locomotor ataxia, in essential anæmia, from debilitating excesses as by masturbation or venereal indulgence, or alcoholism; as an incident in uterine disease and especially as the result of syphilitic affections we may have impairment or paralysis of the ciliary muscle. If the affection is one-sided, the cause will be local and we search for it anywhere along the third nerve to its origin, and the probability will be in favor of syphilis. Injuries of the bones of the orbit or of the eye have an effect probably through reflex influence, and the same has been noted in neuralgia of the dental and other branches of the fifth nerve. Out of this long catalogue of ailments, which is still incomplete, one may well find it

Digitized by Google

sometimes difficult to select the correct etiology. Diagnosis need not be dwelt upon; the affection publishes itself by the same tokens that we are familiar with in presbyopia by their more complete manifestation. Prognosis is important because the local malady may be the forerunner of a more serious disease which will compromise the life or general welfare of the patient. Such will be the cases in which diabetes or an obscure syphilitic disease of the tertiary type, or disseminated sclerosis, or locomotor ataxy, sometimes general paresis and occasionally insanity, are looming up, or have already descended upon their victim. For this reason a careful search must be made in the whole domain of pathological clinical research in case some obvious cause is not discovered. (See Gowers.) The history of the patient will be thoroughly sifted. In the greater number of cases happily the prognosis is good, as, for instance, in diphtheria and after fevers, whether typhoid or recurrent.

Treatment is, of course, both constitutional and local. The constitutional must be decided on general principles of therapeutics as connected with causation. It is to be stated with emphasis that all convalescents must be strenuously cautioned against overtaxing their eyes at the peril of serious paretic and asthenopic trouble of the ciliary muscle. To amuse themselves by reading or sewing to pass the weary hours, is considered a harmless thing, but it too often proves serious in its effects. Women after confinement, or with chronic uterine trouble, patients getting well of scarlet fever, or from severe internal inflammations, need special warning on this matter. If the patient is going about, as strength improves the eye power will improve. The above remark applies to abated capacity for employment of accommodation. When we have to deal with a real paralysis or paresis the great local remedy is sulphate of eserine. It must not be given in concentrated doses, but a solution one-half or one-eighth of a grain to the ounce dropped into the eye once daily, is enough. The pupil will contract slightly and the accommodation will soon be stimulated to action; the near-point is not to be forced to undue proximity and the influence will last for several hours and then gradually decline. Pilocarpine is less energetic and if eserine be unpleasant in its effects on the conjunctiva, muriate of pilocarpine gr. iv. ad ℥ i. may be instilled once or twice daily. The constant galvanic current may be employed with eight to twelve cells, the positive pole over the superior cervical ganglion of the sympathetic at the upper part of the sterno-mastoid, with the negative pole over the closed lids. The current to be kept up for two or three minutes and not to be interrupted. The real value of the galvanization is difficult to estimate, while the influence of myotics is undoubted. It is important, however, to use them in moderation, because they

merely stimulate the muscular fibres and do not act on the cause. We wish to improve their nutrition and not exhaust them.

It is also permissible to assist persons in this condition by suitable convex glasses for work or reading. If, as sometimes happens, they are sensitive to light, a little tint of blue may be added. It is needless to give any rules for prescribing the glasses. It is, however, proper to guard the patient against presuming upon the value of the help thus afforded him, and venturing to use his eyes as if they were not really crippled. Moderate and not reckless use is all that can be permitted.

NOTE.—In discussing spasm of accommodation that condition has been chiefly in view which is to a great degree unconnected with errors of refraction and motility. When such errors are the cause of spasm, it is not always needful to direct a prolonged treatment by mydriatics. The hydrobromate of homatropine, gr. xx. ad ʒ i., dropped into the eye every ten minutes for six or eight times in succession will effect relaxation and permit the prescription of a suitable glass. As the solution of this strength is irritating, a 4% solution of cocaine may be employed previous to its use. It usually excites considerable hyperæmia. Its effects disappear within twenty-four or thirty-six hours. Some oculists rely much on this method. I seldom resort to it because the ophthalmometer, the ophthalmoscope provided, if astigmatism has been found, with the needful cylinder in the clip, and a little patience with trial glasses will master the large number of cases. When obstinate spasm of accommodation confronts me I employ atrophia and with vigor, making a small allowance for the so-called tonic accommodation, about 0.5 D. We have no remedy which will act on the ciliary muscle without acting on the iris and *vice versa*.

Digitized by Illinois College of Optometry

CHAPTER VII.

ERRORS OF REFRACTION.

THE eye so constructed that rays from a distant object form a perfectly distinct image on the retina is refractively normal and is called emmetropic (E). The eye which does not collect parallel rays to a focus on the retina is ametropic.

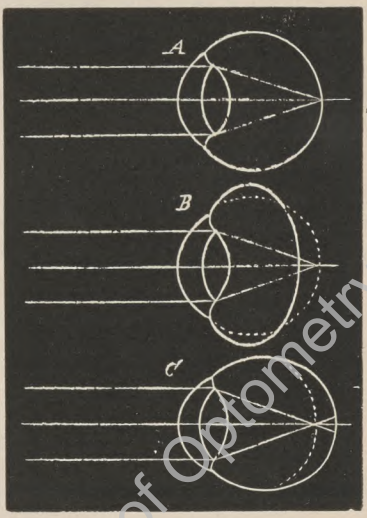

FIG. 27.

Ametropia may result from shortening or lengthening of the visual axis, from defect or excess in refractive power, or from want of regularity in the curves or the substance of the refractive media. Various combinations may occur, as will be seen. Among them we have the conditions known as *hypermetropia, myopia* and *astigmatism* as subdivisions of *ametropia.*

In hypermetropia (hyperopia, H) the image from a distant object falls behind the retina; in myopia (M) it falls in front of the retina; the place of the image in astigmatism will require special explanation. If we confine ourselves to ametropia due to alteration of the length of the visual axis, we see it indicated in Fig. 27. A, B and C represent respectively the em-



FIG. 28.

metropic, the hypermetropic and the myopic eyes. In the next figure a simple biconvex lens is substituted for the eye and if E be

Digitized by Illinois College of Optometry

its principal focus, H gives hypermetropia and M gives myopia. At E parallel rays are focussed, while at H they have not yet crossed, and at M they are already diverging. With both H and M vision is imperfect, because in each the retina does not receive a picture formed of accurate points of light, but formed of circles of dispersion; hence it is blurred. It is assumed that there is no effort of accommodation.

Diagnosis of Refractive Errors.—We ordinarily assume that correct visual acuity precludes refractive error. It does preclude myopia, but it does not preclude a certain degree of hypermetropia, nor of astigmatism. We have already stated (see pp. 22–25), that visual acuity based upon an angle of 5′ is merely an average. For fine determinations acuity should be placed as high as $\frac{20}{xv}$ instead of $\frac{20}{xx}$, making the visual angle 4′. The age of the subject, the degree of light, the whiteness of the paper, etc., must all be considered.

In all such examinations objective methods which are independent of a patient's assertions are to be added to those which are subjective.

Examinations by test types and spectacles may be called subjective,—examinations by the ophthalmoscope, by Javal's ophthalmometer, and by the so-called shadow test, and by Thomson's modification of Scheiner's experiment are objective.

We always test each eye by itself, and for distant vision first. There is often both greater visual acuity and slight change in the glass preferred, when both eyes are used than each eye alone. A stronger convex and a weaker concave will often be accepted when both are corrected.

If visual acuity is made perfect by convex glasses, we may be sure there is hyperopia; if it is made perfect by concave glasses and these are higher than −2 D, we may justly think there is myopia, although astigmatism in either of the above cases is not excluded. If no spherical glass will give perfect vision, we try cylindric glasses, and must not only know whether to choose plus or minus, but must also know in what position the axis is to be placed.

If, combining spherical and cylindric glasses, we still fail to obtain perfect sight, we must look for irregularities in refraction, opacities, and for deficient perceptive power in the retina or optic nerve.

The chief obstacle to a correct result by subjective examination is the patient's accommodation. This may be set aside by atropia, but in practice one will resort to it only when its use is clearly indicated; as for example, when there is severe pain, when contradictory results are obtained after patient trial, when subjective and objective methods give opposite findings, when one sees by the ophthalmoscope that spasm of accommodation exists. With children we resort to atropia more often than with adults. The more we

Digitized by Internet Archive

can rely on objective methods the better, and increasing skill will indispose one to subject patients to the inconveniences of prolonged mydriasis by atropia. Some advocate homatropia, gr. xx. ad ʒ i. as a sufficient substitute for atropia and preferable because the effect is less prolonged. In this practice I have little experience (see p. 68). To dilate the pupil, cocaine is better than homatropine, while to paralyze accommodation where there is reason for doing it, we have no substitute for atropia. Duboisia may be left out of view in this statement, because it is even more potent than atropia.

After a preliminary effort with the test types and spectacle box we take the ophthalmoscope. The indirect method may give information as to the refraction, by using the instrument which Schmidt-Rimpler has suggested, but it is not the most natural and requires special apparatus. We rely on the direct method and while some claim higher accuracy, it is usually easy to come within 1 D of the true state of the refraction. Illumination from a distance of twelve to twenty inches will discover high degrees of error in the display of such retinal vessels as may lie across the pupil. They appear with a hyperopic eye in a virtual image, and as the observer moves his head they go in the same sense. With a myopic eye they appear in a real and inverted image, and as the observer moves, they travel in the contrary sense. Coming as close as possible, the observer with both eyes open to aid in perfect relaxation of his own accommodation, must also know and allow for any errors in his own refraction. Decided myopia on the part of the observer is a disadvantage, because the lens required for correcting a patient's myopia, added to that which the observer uses, will sometimes be so strong as to make inspection extremely unsatisfactory. As between observer and patient, errors of a like kind must be added to each other, errors of an opposite kind are to be subtracted from each other. An observer with myopia 3 D examining a patient with M 5 D will need − 8 D. If the patient have hyperopia 5 D, the same observer will see with + 2 D. If the patient have hyperopia 3 D the supposed myopic observer will see without any glass. On the other hand the hyperopic observer will add the glass to correct his error to that of the hyperopic patient, and will subtract it from that of the myopic. An astigmatic observer should have his correction placed upon his ophthalmoscope. Some modification of the above statements will presently be made.

What is to be taken as evidence of a proper correction? Usually the very fine vessels are so regarded, but besides them one should have a clear sight of the granular look which belongs to the pigment epithelium in the region of the macula. If no glass can give this effect, suspect astigmatism, or haziness of the media. The former will have to be ascertained, and a cylinder placed behind the mirror should clear the fundus. If it does not, the media are hazy,

and this will be proved by a strong convex lens, say 15 D, with feeble light and viewing the eye from a point two to four inches away.

We first bring the optic nerve to view and turn on the *strongest convex* or *weakest concave* glass which will clearly display the fundus. In doing this, it is a decided advantage not to be obliged to remove the instrument as one makes changes in the glasses. A hyperopic patient may betray efforts of accommodation, in the variation of the clearness which a vessel exhibits while viewed by the same glass. This may compel resort to atropia. On the other hand, when inspecting myopia the observer is tempted to use a glass which is too strong and thereby bring into play his own accommodation. Finally, after patient trial, the fundus is clearly seen; the glass may be + 4 D. Is this correct for the patient's use supposing the observer to be emmetropic? It will prove to be too weak by the distance at which the observer holds it in front of the eye and the place at which the patient will wear his glass. Suppose the glass is − 8 D. This will be too strong and by the same difference. With weak glasses the difference is unimportant, with stronger glasses, and especially with concave glasses, it must be considered. For instance, if the observer's glass is 1½ inches from the patient's cornea, and the latter wear spectacles at ½ inch from his eye, 1 inch must be added to the focal length of the glass. For instance, − 8 D is a glass of 5 inches negative focus; to 5 add 1, making 6. Thus the fraction $\frac{40}{6}$ gives − 6.66 D as the glass required. So if the glass by the ophthalmoscope be − 15 D: reduce this to focal length, viz.: $\frac{40}{15}$ =2.66. To this add 1 inch, making 3.66. To find the glass in dioptries $\frac{40}{3.66}$ = −11 D. The difference becomes large. Hyperopia seldom becomes as high as myopia, even after extraction of cataract. If, however, the glass by the ophthalmoscope be + 5 D, this in focal length is + 8. From it subtract 1 inch, making 7. Then $\frac{40}{7}$ = 5.7 D, which will be the proper glass.

With hyperopic eyes the illumination is brighter, and the magnifying power less than in emmetropia. With myopic eyes the illumination is feebler, the magnifying power greater and the field smaller than in emmetropia. Hence with extreme myopia, say of 13 D and higher, examination by the upright image is difficult and not satisfactory. In such cases one may take advantage of the fact that an inverted image of the fundus is formed in front of the eye at its own far-point and may inspect it with a convex glass. For example, if the eye be myopic 13 D there will be an inverted image at about 3 inches in front of the cornea, which may be examined by a plus lens of 6 or 8 inches focus. The field will be small but the image bright, and the degree of myopia can be approximated by measuring the distance between the observer and the patient and subtracting the focal length of the convex glass.

Digitized by Google

The foregoing statements apply to anomalies of refraction correctible by spherical glasses. If now we have to do with astigmatism, we may not only discover the fact ophthalmoscopically, but can, within certain limits, estimate its degree by spherical glasses; it is not practicable to have a series of cylindric glasses attached to the ophthalmoscope. The essential quality of astigmatism is that the degree of refraction in a given meridian is greater or less than in a meridian diametrically opposite; the difference between these meridians is the amount of astigmatism.

It follows that we have to discover which are the principal meridians of refraction, viz.: the least and the greatest, and each must be studied by itself.

Now, in examining the fundus by the direct method, if we find that fine vessels in the horizontal meridian need no glass for distinct perception, while fine vessels in the vertical meridian need a plus glass, we have simple hyperopic astigmatism. If we need a plus glass for any vessels and a stronger glass for other vessels, this betokens compound hyperopic astigmatism. In the same way we recognize simple myopic and compound myopic astigmatism. The degree is the difference between the two meridians. The rule in examining hyperopic eyes, is to use the strongest convex glass which is available, and, in examining myopic eyes, to use the weakest concave glass. Now, in eyes having a decided amount of astigmatism, viz., 2 D, a streaky appearance is produced, and the streaks will run in the axis of the greatest ametropia; of course the least ametropia will be at right angles. Moreover, it will be impossible by any spherical glasses to gain a clear view of the fundus. So noticeable is this fact that one is incited to examine for haziness of the vitreous, or erroneously led to think that the retina is infiltrated with inflammatory effusion. Such an error is obviated by finding that visual acuity by proper correction is satisfactory, and if the proper cylindric glass can be attached to the ophthalmoscope out of the trial-box, obfuscation of the fundus vanishes. I have provided the means of doing this in the ophthalmoscope figured on page 45, and gain the advantages of learning, first, that the deep ocular structures are or are not healthy; and, second, that the finding by the trial-glasses is or is not correct. Another feature in astigmatic eyes is that the optic disc is no longer circular; it is elongated in the direction of greatest ametropia, and therefore is oval. The nerve may be misshapen anatomically, presenting a distinct oval, the long axis usually more or less vertical. In such a case the retinal vessels will show no difference of distinctness caused by their various directions.

By the inverted image the streakiness of the fundus can well be seen in high degrees of As, but the lines run in directions opposite

Digitized by Illinois College of Optometry

to their course when viewed by the upright image. So, too, the oval of the optic disc is reversed. But the objective lens must be held from the eye at a certain distance. It has already been said that in the upright image the optic disc is elongated in the direction of the meridian of greatest curvature, because the magnifying power is greater. With the inverted image the elongation corresponds to the weakest meridian. With the emmetropic eye the size and form of the optic disc undergo no change in the inverted image when the objective lens is held nearer to or farther from the eye. With the hyperopic eye, when the objective approaches it the optic disc becomes smaller, and grows larger as the objective recedes. With the myopic eye, when the objective approaches it, the optic disc becomes larger and grows smaller as the objective is held farther away. In both H and M the shape of the disc remains round or oval, whatever the distance of the objective. But with astigmatism the location of the objective changes the size and the shape of the disc. If with the lens near to the eye the disc be vertically oval, the disc becomes circular if the lens be held from the eye a distance equal to its focal length, plus the distance of the anterior focus, viz., half an inch. If it be drawn farther away beyond its focal length, the direction of the axis of the oval is reversed. These phenomena have been elaborately studied by Javal and by Giraud-Teulon, and can be utilized in diagnosis, but the upright image is by far the most available and instructive.

The principles now presented have other applications and they may here be stated.

Certain important pathological conditions are revealed by the employment of the ophthalmoscope as an optometer. We are enabled to measure the depth or height of an object by knowing the number and nature of the glass with which we can view it. Such, for instance, is the depth of excavation of the nerve in glaucoma, the height of a tumor, the elevation of a detached retina, the position of a body floating in the vitreous. For instance, we find the edge of a glaucomatous cup is to be seen with + 24 (+ 1.50 D); its bottom requires − 16 (−2.50 D), the depth of the pit is $\frac{1}{24} + \frac{1}{16} = \frac{5}{48} = \frac{1}{10}$, or 1.50 D + 2.50 D = 4 D. By referring to the table on pages 89 and 90, we find that H $\frac{1}{24}$ (or + 1.50 D) means shortening of axis of 0.47 mm., while myopia $\frac{1}{10}$ or − 4 D means lengthening of axis of 1.37. The depth of the cup then equals 0.47 + 1.37 = 1.84 mm. On the other hand, swelling of the optic nerve in neuritis may permit + 8 for its summit, and the eye be emmetropic. A shortening of the visual axis of $\frac{1}{8}$ = 1.50 mm. which measures the amount of swelling. The same principle applies to all other cases above cited, and by it we are able to give precise data in the facts and progress of a case. An interesting case was one of myopia of − 7 D ($-\frac{1}{6}$), which gives

elongation of axis of 2.13 mm. In the eye there was detached retina, whose conspicuous part or summit was seen by + 7 D or + $\frac{1}{6}$, which means shortening of axis of 1.76. The true elevation of the retina therefore was 14 D: equivalent to 3.89 mm.

In cases of this kind the inverted image has some value; if we move the objective lens from side to side, the parts of the object which are highest and those which are lowest will not move to an equal degree; in other words, their parallax will be unlike, and they will appear to be displaced unequally. The top of a swollen nerve is nearer than its bottom, and the motion of the objective lens causes its image to have less excursion at the top than at its bottom. The same thing, to a less degree, can be exhibited in the direct image

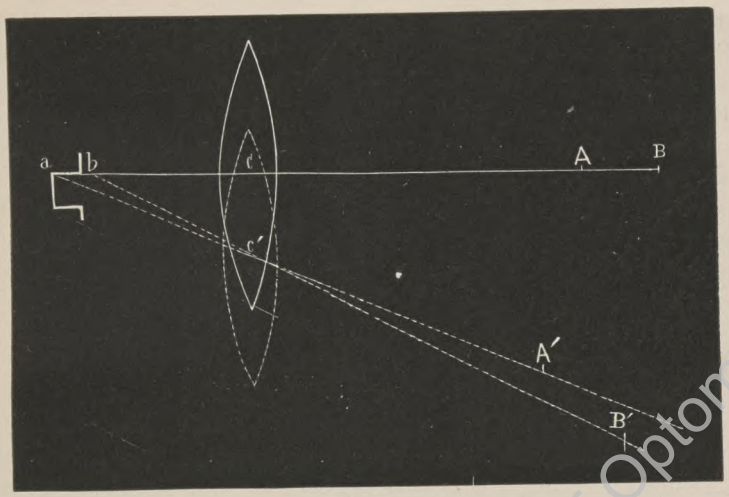

FIG. 29.

by moving one's head. So too, with a glaucomatous nerve, the vessels on the edge of the disc, as the lens is moved up and down, move in front of and faster than do those at the bottom of the nerve. For explanation, see the diagram (Fig. 29) from Abadie. Let *b* be the edge of the excavation, and *a* lie at its bottom, and the images of these points along the axis of the lens will be at B and A respectively; *c*A is of course shorter than *c*B. When the lens is moved down, the points A and B are displaced to A′ and B′ as seen in the figure. They are no longer in the same line, because the surface of the excavation, *a*, *b*, presents itself differently to the lens. The point B′ moves faster and farther than the point A′, and passes in front of it, because *c*′ A′ and *c*′ B′ become, as it were, radii of arcs of circles.

A special modification of the *indirect method* has been made

Digitized by the College of Optometry

by Schmidt-Rimpler[1] for determining the state of refraction. It is not difficult, and is moderately accurate, and the observer is not compelled to relax his accommodation; yet its being a rather cumbersome apparatus has prevented its general acceptance. Recently Warlomont and Loiseau have constructed another instrument based on the same method.

Yet another objective method of ascertaining the state of refraction is to be mentioned which was prominently brought forward by Cuignet in 1873 and which has gained considerable currency in England, and is growing into use elsewhere. Cuignet called it keratoscopy, under a false idea of what the method really is, and various names have been given to it, viz.: pupiloscopy, retinoscopy, skiascopy, etc. The most common name and in a certain way suitable, although not truly correct, is the

Shadow Test.—When the eye is illuminated by the ophthalmoscope, only a small part of the fundus is covered by the light, while all the rest is obscure. If the mirror is turned at various angles the illuminated surface correspondingly shifts and we may see in the pupil a portion both of the luminous and of the non-luminous surface. The latter is spoken of as a shadow, which is physically incorrect, but is a term convenient for use. Its formation is illustrated by casting upon a screen the image of a gas flame by a 2-inch convex lens. The image is bright, but there surrounds it a dark circle which has nearly the diameter of the lens. This non-luminous or dark circle corresponds to the "shadow" in the test we are considering. The lens has deflected the rays to form the image and the surrounding space is in darkness. If now in illuminating the eye we turn the mirror in oblique positions, the shadow appearing in the pupil will have certain peculiarities which depend upon the quality of the mirror and upon the refractive state of the eye.

The mirror may be plane or concave. Because of its greater simplicity we will assume the *mirror to be plane.* The observer sits in front of the patient at three or four feet (say one metre) distance, the light will most conveniently be above his head, and the pupil must be moderately large; a mydriatic is frequently required. If the mirror is rotated upon a vertical axis, the shadow moves transversely across the pupil presenting a vertical edge and tests the refractive quality of the transverse meridian. With emmetropia, hyperopia and slight myopia the shadow moves in the same sense as the mirror, or "with" the mirror. With myopia higher than 1 D the movement of the shadow is opposite to the expected effect or is "against the mirror." To understand the phenomena see Fig. 29,

[1] "Augenheilkunde und Ophthalmoskopie," Braunschweig, 1884.

Digitized by the Internet Archive

from Nettleship. Let L be the light and M the plane mirror. The virtual source of light is an erect image of the flame situated as far behind the mirror as the flame is in front of it, viz.: four to six feet. An image of the flame is formed upon the retina at I. If the mirror be turned to the position of M′ the retinal image shifts to I′, and the shadow will appear from the left hand side as the movement of the mirror would suggest, and coincide with its motion, providing the eye is either emmetropic or hyperopic. If, however, the eye is myopic (see 2 in Fig. 30), the image of the flame is formed in front of the retina and the rays cross; and emerging from the eye they form a real and inverted image between the eye and the mirror which moves in a sense opposite to the rotation of

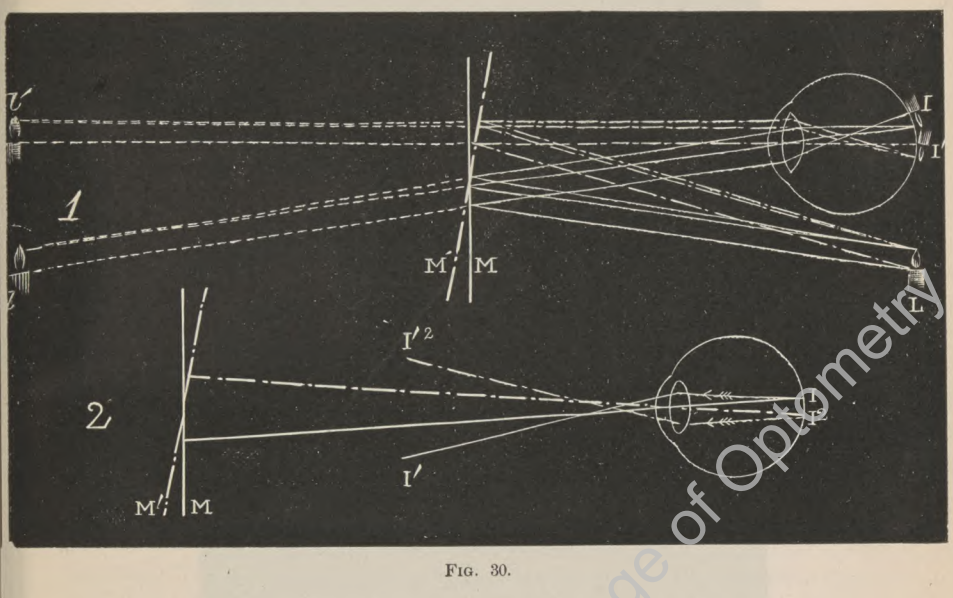

FIG. 30.

the mirror because the rays now cross before reaching the observer; the shadow is therefore *against* the mirror. If the myopia be so feeble that the inverted image of the luminous area of the retina falls beyond the mirror, the shadow will move with the mirror. The retinal vessels will appear, but are disregarded.

Suppose we use a concave mirror of 7 or 8 inches or 20 centimetres focus (see Fig. 31, from Nettleship). The virtual source of light is the inverted image of the flame L found at I, and a second image again inverted is formed at I′ in the eye. This image will be distinct and bright if the far-point of the eye is at I, but otherwise it will be out of focus and the luminous area will be less bright. We will suppose the eye to be myopic (No. 2, Fig. 31). It forms a

Digitized by the College of Optometry

real image of the illuminated surface I′ at I″. If the mirror be turned, I′ will move to I′² and the image will shift to I″². That is, the image seen by the observer moves in the same direction with the mirror.

If the eye be hypermetropic or emmetropic, the rays coming

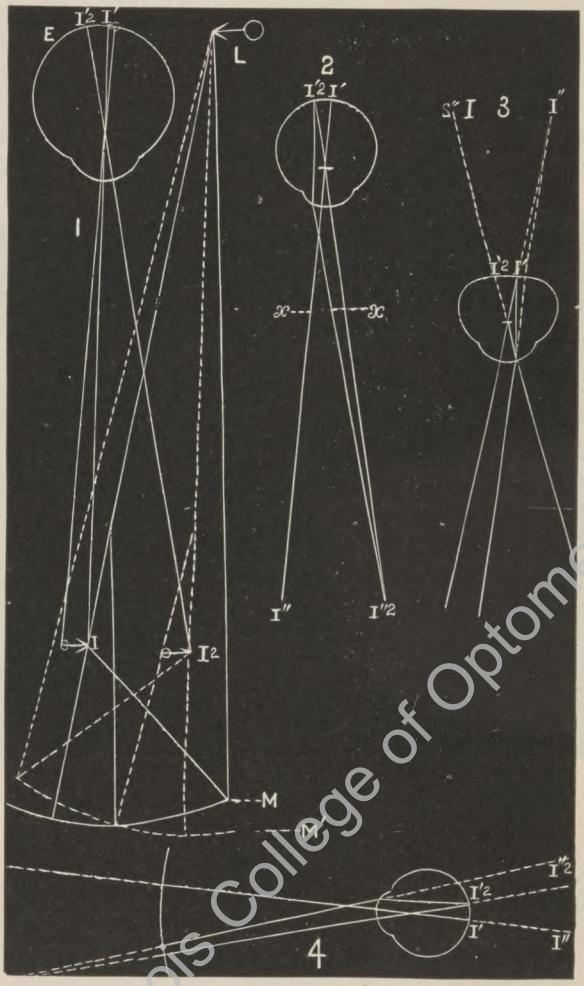

Fig. 31.

from the eye being divergent or parallel will not be brought to a focus, and the observer will see a virtual erect image at I″ (No. 3) the virtual focus of I′ and see its movements as they actually occur, *i.e.*, in the same direction as the movements of the real image I′ or I′² and therefore "against" the movements of the mirror. If the

Digitized by Illinois College of Optometry

myopia be of low degree, viz.: about 1 D, the rays emerging from the pupil are focussed at about one metre and if the observer intercept them before they meet (No. 4) he will refer them to I″ and I″^{2} and obtain an erect virtual image of I′ the movements of which will be the same as in H or E (No. 3), viz.: against the mirror.

To sum up: with a *plane* mirror the shadow in emmetropia, hyperopia and low myopia will move *with* the mirror. In myopia greater than 1 D, the shadow moves *against* the mirror. With a *concave* mirror the shadow in emmetropia, hyperopia and low myopia moves *against* the mirror. In myopia greater than 1 D it moves *with* the mirror.

In practical work a spectacle frame is put on the patient or a disc bearing glasses is rotated in front of the patient's eye (Brailey) and various glasses are tried until one is found which just reverses the movement of the shadow, or which causes the shadow and the illumination to behave as in emmetropia. This lens is very nearly the desired glass. In hypermetropia we must subtract about 1 D from the lowest plus lens which reverses the shadow; and in myopia 1 D must be added to the lowest minus lens which reverses the shadow, because the reversal of movement will not occur until a slight excess in the strength of the glass has been produced.

The higher the ametropia, the less luminous will be the pupil, and the less distinct the shadow. We may give attention to some other points besides the direction in which the image or the shadow moves, viz.: to its brightness, to its rate of movement and to the form, straight or crescentic, of its border. If the eye be emmetropic, or nearly so, the image will be most correctly focussed and hence at its brightest, whereas, if notably out of focus the rays are more dispersed. For the same reason the border of the image will in emmetropia be best defined and straighter because the flame has nearly vertical borders—if out of focus the image has a more rounded and blurry outline. The movement of the image is most rapid in emmetropia.

The detection of astigmatism becomes easy by varying the movement of the mirror about different axes—vertical, horizontal or oblique. If, for example, the reversal of the movement of the shadow is secured when the movement is transversely across the pupil and ametropia still remains in the opposite meridian when the mirror is moved in that direction, another lens must be found which will correct the latter error. Of course the difference between the two lenses thus found is the degree of astigmatism. Both the kind and degree of astigmatism are thus made known. Irregular refraction or opacities in the cornea and lens will also be brought to view. Nettleship says: "for the quick discovery

of very slight astigmatism and of the direction of the chief meridian in astigmatism of all degrees, retinoscopy probably excels all other methods."

In his further observations the writer fully concurs: that accurate retinoscopy (skiascopy) is not quicker than measurement by the direct ophthalmoscopic method and that in fact the latter is decidedly the more rapid if one have a good instrument. "I cannot help thinking," says Mr. N., "that the importance of retinoscopy has been somewhat overrated, and that though in some difficult cases it will remain our best objective test, we shall do well generally to use it as an auxiliary, rather than as a substitute for other methods." The ability to employ the shadow test well is worth possessing, but it can never attain the value of direct ophthalmoscopic examination of the fundus, because it teaches nothing of the actual condition of the structures.

By the methods discussed we are enabled to diagnosticate the kind of refractive error present, and we next have to correct it. We resort to trial glasses. We examine at the distance of six metres or as near to that as may be feasible, and endeavor to bring vision up to normal standard by the strongest convex, or weakest concave glasses which will be accepted. Some assistance is gained by noting the distance at which the patient can read fine print. If decidedly myopic, he must hold it near, say inside of ten inches, but he will do the same if greatly hyperopic, and also amblyopic, or if astigmatic, or if there be insufficiency of the recti externi muscles. If to read print it must be held very near, and distant sight be very bad, try a concave glass, whose focal length is about the distance at which the book is held from the face; this should greatly improve distant vision if there be myopia, while it will be rejected in most other kinds of refractive error. Should the book in reading be held at a distance beyond fourteen inches there may be hyperopia, but the probabilities are that the fault is principally in the accommodation. Special details in choosing glasses will be given under the special kinds of error to be treated.

It must be remarked that special instruments to take the place of the box of trial glasses have been contrived, called optometers. Some are based on the principle of the Galilean telescope, viz.: those of Graefe, of Perrin and Mascart, of Snellen; some have a single convex lens (Burow, Badal, Sous, etc.), and test types are contained within the tube of the instrument; some have two convex lenses placed a distance from each other equal to the sum of their principal foci (Hirschberg, Plehn), and in using them the types are hung upside down across the room. In some instruments the focus of the lens coincides with the patient's nodal point as recommended by Nagel (Hirschberg, Plehn), the object is to avoid, as

Digitized by Google

much as possible, magnifying the print. Without discussing these apparatus in detail (see article by Plehn [1]), it may be remarked that they are useful when a large number of examinations must be made rapidly, as among recruits in military service, but they are apt to provoke efforts of accommodation and they do not serve for reading. There is also an instrument based on wholly different principles, called the prismoptometer, to which the same objections apply.

Still another mode of testing vision subjectively is based upon the experiment of Scheiner, viz.: looking through two small holes about three or four millimetres apart in an opaque disc. The effect of this contrivance is seen in Fig. 32. If the emmetropic eye E be focussed for the object O, it will form a sharp image, notwithstanding the splitting of the beam of light into two small pencils, because each will fall upon the fovea. For the hyperopic eye H

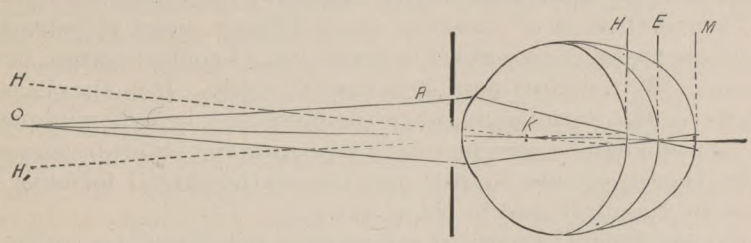

FIG. 32.

whose retina is nearer the nodal point, the small pencils will each make a separate confused image upon it. The same will be true of the myopic eye whose retina is too far from the nodal point, viz.: that each pencil will make its own circle of dispersion. Both the hyperopic eye and the myopic will therefore see the object doubled: it being supposed that the hyperopic makes no effort of accommodation. This device was employed by Porterfield many years ago, but has lately been made practical by Dr. Thomson, as follows: If across the upper hole of the screen a red glass be placed, and the object be at twenty feet and be a very small gas flame, or a small dot of light, then ametropic eyes will not only see two lights, but one will be red and the other white. For the hyperopic eye it will be seen by the dotted lines going through the nodal point *k* (see Fig. 32), that the projection of the spot which is uppermost on the retina is below the axis, and if the red glass be on the upper hole of the screen that image is red. It therefore follows that when the red image appears to the side of the axis opposite to the side where the red glass is placed, this diagnosticates hyperopia. On the other hand, if the red image be on the same side of the axis with the glass, this declares myopia.

[1] Archives of Opth., xvii., 1, 74, 1888.

Digitized by the College of Optometry

It is further evident that the greater the ametropia the wider apart will be the two images. It follows that the kind of diplopia and the interval between the images give both the kind and approximately the power of the correcting glass. To make the estimate of the power of the glass fairly accurate, Dr. Thomson has so arranged two small gas flames upon a measured bar that each being doubled, one is moved from the other until instead of four flames, three only are seen by the coincidence of two. This distance is read off upon the rod, which is divided into centimetres, and the refraction is deduced. Still more simply the refraction is given by putting in front of the screen the convex or concave glass which causes the images to approach until they coalesce. The objection to this is that myopics will be likely to use accommodation and get glasses too strong and hyperopics to get glasses too weak. Dr. Thomson's use of two flames obviates this liability.[1]

This method is of value in some difficult cases of refraction where the media are irregular in curve, viz., in conical cornea, or are opaque. With dilated pupil it is easy to apply. It is always most effective with a large pupil, when the holes may be four millimetres asunder and can be used in a dark room and for illiterate persons.

The theory of this method and the mathematical formulæ are given by Nagel, G. and S., VI. p. 412.

For the general theory of optometers, see Nagel, l. c., p. 315 et seq.

We now take up special refractive errors in detail.

Hypermetropia.

Hyperopia—H.—Hypermetropia is the condition in which, with suspended accommodation, a person requires a convex glass to get his best acuity of sight for distance. It is essential to put aside the accommodation, because up to a certain age and for small degrees it overcomes and conceals the hyperopia. But it is not to be expected that all cases of high degrees of H will with glasses gain $V = \frac{20}{20}$.

Many who need + 10 (¼ D) or stronger glasses, have $V = \frac{20}{30}$ or $\frac{20}{40}$. In fact, the greater number of strongly hyperopic persons do not have normal acuity of sight.

It is the optical result of a shortened visual axis or of want of the crystalline. It also appears in later life, after sixty, by flattening of the crystalline, being the outcome of advancing presbyopia. Flattening of the cornea may also cause it through distention of the globe, as ensues in glaucoma. The usual cause is shortening of

[1] See Trans. Am. Opth. Soc., 1870, p. 93, and 1873, p. 83.

Digitized by the College of Optometry

the visual axis. It is a congenital condition. At birth it is almost universal, viz., in 92.4%; up to the fifth year we find 84%; among children in elementary schools 76%; among pupils in higher schools 56%. The degree of H at the second year of life averaged in 300 cases 2 D. For a summary of all recorded investigations of refraction by different observers, amounting to 22,743 cases see Randall, Bericht Int. Ophth. Congress, Heidelberg, 1888, p. 511; also *Am. Journal Medical Sciences*, July, 1885.

Anatomical Characteristics.—In his classical treatise which is the foundation of the knowledge of the present day on this subject, Donders portrays many features which characterize the physiognomy of hyperopics. That they often have narrow faces and shallow orbits and eyes deep set, is true, but no conclusive deductions can be drawn from such appearances. It is evident that the axis of the eye increases in higher ratio during the early years of growth than do the optical parts.

Hyperopia necessitates an effort of accommodation proportionate to its degree, and the result is, that if great, the ciliary muscle becomes enlarged and in adults its size and contour have a well-marked and conspicuous character. This has been exhibited by Iwanoff. If hyperopia is less than 3 D or 4 D vision generally is normal, if higher it is rarely normal. The explanation is found probably in the want of development of the retina and optic nerve. The supposition that the same number of rods and cones as in emmetropia are condensed into a smaller space is inherently improbable. Donders pointed out that the macula lutea is farther to the temporal side than in emmetropia, and Landolt and Dobrowlsky proved that the distance between the papilla and the macula is greater than in normal eyes. The cornea is more decidedly decentered than in emmetropia and the angles gamma and alpha are usually very large. With the higher degrees of H the eyeball is evidently small and proclaims its imperfect development not only in this fact, but even in imperfect vigor of the ciliary muscle and of the motor muscles. The optic nerve in marked degrees of H often shows indistinctness of tissue, it may be deep red or grayish, its edges are often striated and ill defined, especially on the nasal side. It may be, and in high degrees it usually is, intensely red, and because of such signs some have regarded the condition inflammatory. This, however, can hardly be sustained by clinical experience. What is known as the choroidal crescent, viz.: the interval between the edge of the choroidal and the scleral openings is not infrequently observed, and it is usually on the temporal side. Sometimes the nerve is anatomically oval, while the oval shape due to astigmatism is also frequent. Even the retina in the neighborhood of the nerve sometimes is hazy and seems thick.

While these appearances belong to higher degrees of H, we shall find in all hyperopic persons having symptoms of asthenopia, that the nerve is red, perhaps very deeply, and the veins are large—indicating reflex irritation of the papillary circulation.

Symptoms.—In using their eyes, hyperopes of moderate degree, or rather such as have adequate accommodation and good muscles, exhibit no difference ordinarily from emmetropes. If examined by glasses they may not accept them. In such persons the whole error is latent. On the other hand, they may see equally well at six metres with and without a given glass. The glass which they accept represents the "manifest H." Under atropine such a person would show a higher degree and accept a stronger glass; the repressed amount is the "latent H." The "total H" is of course the sum of the manifest and the latent. It is also possible that a hyperope requires a weak glass to give him the best vision and will also see equally well with a stronger one. Suppose he needs + 1.5 D for vision $\frac{6}{6}$ and will accept + 3 D. It is evident that his manifest H = 3 D. Of this he is able to correct 1.5 D voluntarily, and this part of the "manifest H" Donders calls "facultative." The total H can be usually seen by the ophthalmoscope, and can be elicited by using atropine in full dose. But my own experience agrees with Schweigger's ("Handbuch der Augenheilkunde," p. 49, 1880) that exceptional cases occur which do not yield up their total H to the ophthalmoscope. See also article by Weiss (Graefe's *Archiv für Ophthal.*, XXIV. ii., 90), one by Agnew (Trans. Am. Oph. Soc.).

I observed one such person, a lady aged 32, for three months and could not make out an error which finally under atropia proved to be 2.5 D. Persons with high degrees of H, especially if they be notably amblyopic, will bring print and work very close. They will behave as if near-sighted. They will seek a strong light, will see badly in the evening. They often have small pupils. They apply for relief either because distant vision is indistinct, or when they have symptoms of asthenopia. Distant vision fails when the accommodation can no longer correct the error. It is evident that with parallel axes, the hypertrope has been accustomed to exert an undue degree of accommodation. As this faculty declines with years, he finds himself obliged at an early age to seek the aid of convex glasses, and he also is apt to find that a weak convex glass improves and restores to him his former acute distant sight. This is what usually transpires with moderate H in healthy and vigorous persons. An attack of sickness, especially of diphtheria, chronic ill health, notably uterine diseases, and extreme taxation of sight, may cause the same results before the usual decline of accommodation would develop them. Bnt it is more common under the influence of such causes for the subject to suffer, not from defective

Digitized by the Internet Archive

sight either for near or far, but from pain in close eye-work. This is called *accommodative asthenopia.* The symptoms are that after working for a certain period the person must stop because the sight is blurred, there is pain in and about the eyes and sometimes remote reflex symptoms, such as headache, pain down the spine, sickness of stomach, etc., etc. The ability to resume work after rest, to work better under stimulus, that the periods of ability to work grow shorter:—these are characteristics of this condition. Many more touches might be given to this picture, but they would serve no good purpose. It may, however, be added that palpebral irritation, chalazia, styes, blepharitis marginalis, and hyperæmia of the palpebral conjunctiva are frequently seen. The inflammations of the border of the lid occur most often in young subjects and frequently without any complaint of distressful sight. This is a well established fact and was noted by Roosa and Schirmer and has long been familiar to the writer. Palpebral conjunctivitis is almost always present when asthenopic symptoms exist, and explains the sensations of smarting, dryness, heat and the inclination to press upon the globe—as well as the comfort gained by applications of lukewarm water and soothing lotions.

Hypermetropia makes its appearance in the order of nature beyond sixty or seventy years of age, and then dimness of sight for distance, correctible by a weak convex glass, is the symptom observed. Usually there is no asthenopia.

Another class of cases exhibit the effects of their error in disturbances of the muscles; they are either inclined to *converging strabismus* or it becomes fully established.

We have spoken of the intimate relation which in emmetropia subsists between accommodation and convergence. For a given number of dioptries of accommodation, say 4 D, an equal number of metric angles must be brought into use, *i.e.*, 4. With hypermetropia the law is not the same. On the contrary, with no convergence the subject must put forth as many dioptries of accommodation as will equal his total error. If hyperopia = 4 D and he accommodate for 250 mm., he uses 4 + 4 D = 8 D of accommodation for 4 metric angles of convergence. At once a disproportion appears, which may easily be converted into a complete disturbance of binocular vision, if for any cause there be difficulty in distinct vision or in convergence. The two functions are in a state of unstable equilibrium and are easily disassociated. It has never been shown how large is the proportion of hypermetropes who acquire strabismus, but Donders showed that about two-thirds of the cases of strabismus convergens were hypermetropic. The latitude which exists in the amplitude of convergence for a definite amount of A, and the variation in relative A for given degrees of convergence, explain why so

Digitized by the Internet Archive of Optometry

large a proportion of hyperopic subjects never fall into strabismus. But that they are subject to this tendency is evident. It must also be remarked that other refractive complications are frequent in H, viz.: astigmatism and unequal refraction of the two eyes (anisometropia). To this must be added that often there is unequal visual power in the two eyes and inferior visual acuity of one or both forces the adoption of a distance for near work, closer than the degree of H would demand. It is not found that hyperopic persons choose a working point more removed than emmetropes; on the contrary, their inclination is to adopt a closer near-point, until the failure of accommodation brings on premature presbyopia.

The occurrence of strabismus is evidently determined by a variety of factors and among the most potent is the actual power of the muscles of adduction and abduction. Efforts of accommodation stimulate the interni and the effect is reciprocal. It is a subject worth investigating on a large scale what is the adduction and abduction of hypermetropes who do not squint. (See "Die Aetiologie der Strab. conv. hypermet." von Dr. Richard Ulrich, 1881.) The subject will be referred to again under the head of strabismus.

Complications.—It has been said that amblyopia, astigmatism, inequality of the eyes both as to refraction and vision, strabismus, spasm of accommodation and asthenopia may coexist with hyperopia. It is recognized to be a frequent concomitant of glaucoma and is regarded as predisposing to it, while that it may predispose to idiopathtic retinitis (Dobrowlski) is not probable.

Diagnosis.—The acceptance of a convex glass for *distant* vision and that by it vision is not impaired or may be improved, is conclusive of hypermetropia. Its non-acceptance does not disprove it. If accommodation is fully paralyzed by atropine non-acceptance of the glass disproves it. With this must be combined objective examination, viz.: by ophthalmoscopy, by Cuignet's method (shadow test), and for decided proof it must be possible to eliminate accommodation both from the observer and the patient. In most cases the upright ophthalmoscopic image will settle the matter easily, by showing that a convex glass permits clear vision of the fine retinal vessels near the macula, or of the retinal epithelium (the granular look). For H less than 1 D good observers may be in doubt with objective methods, but if needful, atropia will determine the point.

Prognosis.—The error is not curable, but is correctible. The degree of vision will not be impaired, but as the accommodative power becomes exhausted, stronger glasses will be needed, and in higher degrees of H one pair will be required for distance, and a second for the near-point. The endurance of hyperopic eyes usually falls below the normal amount, and as they come to use high glasses for work, this disability is liable to increase. They often feel the

Digitized by Microsoft Corporation

necessity of constantly wearing glasses to be a grievous burden, but the prognosis is relatively good.

Treatment.—We have no occasion to deal with these persons until some of the above-mentioned subjective symptoms cause them to ask for relief. So long as their accommodation can without conscious strain overcome their error, they need no aid.

1st. In the simplest cases the first call for help is when they find near vision indistinct or tiresome, *i.e.*, when A is not large enough to easily overbalance H. We usually meet this in persons from 25 to 40 years of age. They may accept a weak glass for distant vision, but without it may have V = $\frac{6}{6}$. It is in reading, etc., that they find the print blur and the light seem bad and the eyes grow tired. We always test each eye separately and cover the other by a screen. The convex glass which makes reading comfortable, whether .75 D, or 1 D or 1.5 D, is all that they need. This they may use at discretion, and there is no occasion for a distant glass and atropine need not be used in the examination. Let the same person grow older and find distant vision a little hazy, then he may take the convex glass which restores its sharpness and at the same time he will need a stronger working glass and will have to make habitual use of it. The glass for distant sight he may use at his pleasure for looking at pictures or at persons in an audience, etc. In time it may come to pass that without a glass, distant sight is unpleasantly obscure and then the person will gladly take refuge in its continuous employment. His occupation may require sharp vision at moderate distances, say at 10 feet, and he may even need a series of three glasses to meet all his requirements. Portrait painters find themselves sometimes in this predicament. It is convenient for them to have a glass ground with double foci. Formerly such glasses were made in two pieces (Franklin's glasses), now separate foci can be ground upon the same piece of glass. The stronger should be below and it should occupy less area than the upper. At the dividing line prismatic distortion occurs, but generally the person can soon habituate himself to the glasses. They must be larger than the ordinary form. Sometimes a slip of glass is stuck to the lower portion of the weaker one by Canada balsam.

2d. The person complains of asthenopic symptoms, and they may arise either when at work, or be constant. In such cases the error may be small and the distress be due to feeble health, overwork, astigmatism, feeble muscles, etc., or the error may be large, and there may be notable amblyopia. The mode of dealing with such a case will depend upon the age, the general condition of health and upon the intensity of the asthenopic symptoms. It is in this class of cases that we are confronted with the question,

Digitized by Illinois College of Optometry

Is atropine necessary? The case is to be looked upon as one of *accommodative asthenopia*, and all the elements which enter into this morbid complex, must be taken into account. A real attempt must be made to correctly estimate all these elements *without* resorting to atropine. First, one must test distant vision and find the strongest convex spherical glass which will be accepted. If visual acuity remains below the normal, the next inquiry is for astigmatism, which will be hereafter discussed. If sufficient success is not attained in bringing up the visual acuity, try the objective examination by direct ophthalmoscopy or by the shadow test, to see what glass, or combination of glasses, is indicated. Let the patient use these for distant vision. He may or may not gain better or correct acuity. Perhaps he now accepts a stronger glass than at first. This means that accommodative tension is abating. He may not consent to the stronger or the objectively ascertained combination. His answers may be contradictory, he may evidently feel uncertain what he sees, and may say that the type swims, or comes and goes. The glass, objectively ascertained, may be much stronger or be very unlike the glass which he is willing to take. These symptoms betoken accommodative strain. If after a little patience in pressing upon him glasses, which approximate to the degree of error objectively ascertained, he accept them and acuity becomes $\frac{6}{9}$ or $\frac{6}{6}$, let him take these and read with them for half an hour, provided he be a person under 25 years. Usually these glasses, if found satisfactory in reading, will serve the purpose and a mydriatic need not be employed. Such a proceeding will take considerable time and patience, and it is assumed that the examiner has an unlimited supply of the latter. It will be justifiable to give the patient these glasses with the proviso, that he be told that they may possibly not serve, and that if they cause trouble or fail of relief he must come again. In other cases the examination may be repeated the next day and then the patient is likely to be better able to control his eyes and faculties. Glasses selected in this way necessarily leave uncorrected what may be called the *normally latent* error. The age and health of the subject have a controlling influence over the amount of this fraction, which may be called the physiologically latent error, and it necessarily varies with the degree of H. To young and vigorous subjects whose subjective symptoms are not severe and for whom visual acuity $\frac{6}{9}$ or $\frac{6}{6}$ can be obtained, it is proper to prescribe glasses without resort to a mydriatic. Whether the glasses are to be used only in near work or at all times, depends on the degree of error, on the vision without them, and on the amount of discomfort previously existing. If constantly worn they sometimes become thereafter indispensable, or in other cases, they in a little time bring about relief, and may

Digitized by Google

be laid aside for distance and used only for the working point (*punctum agendi*).

3d. But another possibility presents itself: we have not attained satisfactory visual acuity, or the difference between the glasses objectively found, and subjectively approved is too great, and the patient's answers show that his accommodation is under severe strain, or his subjective symptoms are severe. Further evidence of serious spasm of accommodation is found in the variable sharpness of the fundus under the ophthalmoscope, as various glasses are employed. Under these conditions a mydriatic must be used. Oftentimes the prolonged mydriasis of sulph. atropia, which will extend to seven or ten days, is a serious inconvenience, at other times it must be regarded as a therapeutic measure, as well as needful for diagnosis. Then sol. sulph. atropia, gr. iv. ad ℥ i., will be dropped into the eyes from three to ten times within one to three days according to the susceptibility of the patient; constitutional symptoms are liable to occur, and warning must be given accordingly. With milder subjective symptoms hydrobromate of homatropine, gr. xx. ad ℥ i., may be dropped in, every ten minutes until relaxation occurs, and its effects will pass in twenty-four or thirty-six hours. Sulphate of duboisia is our most active agent, but has no special advantages. Muriate of cocaine 4% solution has much less effect on accommodation than on the pupil.

With suspended accommodation the full amount of hyperopia will be discovered, astigmatism will be sought for, and while with dilated pupil, *acuity may not reach the normal*, an ophthalmoscopic examination by the upright image with the full correction both by spherical and cylindric glasses will show whether defect of vision is due to a real amblyopia. Further evidence of amblyopia will be had by testing for a small central color scotoma, which is some times found in one eye of hyperopes who have never squinted.

If the degree of H be important, $\frac{1}{12}$ or greater, it will very frequently be advisable to give the glass which fully corrects H. In most cases it will be best to wear it continuously. Under what circumstances should convex glasses be constantly worn? Some people answer for themselves by finding that they are wholly uncomfortable without them, even though the degree is not strong The comfort of the individual is of necessity the fundamental reason for constant use, and that only in this way can it be secured, is not always to be anticipated. That such use is likely to be needful will be probable of cases of high degrees, viz., $\frac{1}{12}$ and more, whether in young or old subjects; the more advanced in age the person, the more likely is he to require constant help. Again, the same advice is to be given to very sensitive persons whose eyes give them much pain. Under this head will come a large class of

semi-invalids and impressible and neuralgic persons. On the other hand, the dull and torpid and unobservant will often be quite indifferent to the aid of glasses for distance, even though they have a marked degree of error. Furthermore, something has to be conceded to the sense of what is becoming to their personal appearance in persons of both sexes, and, while a physician will not modify his deliberate opinion and advice in deference to what may suit his patient's whim, there are doubtful cases in which his abstract views must be modified by the patient's preference. For persons with marked H there can be no doubt of the advantage gained by constant use of glasses, because the range of accommodation is brought within the physiological limits, and the continued strain on the ciliary muscle is removed. Moreover, it is a frequent observation that in this way acuity of vision decidedly improves in the nigher degrees of H. This is not simply the effect of enlargement of retinal images, but of improved health of the retina.

If the requisite glass is as high as 4 D it often causes discomfort when first worn, because one's estimate of distances is disturbed and more light is gathered into the pupil. Special care must be taken with the frames that the centres of the glasses coincide with the visual axes. If decentered in either direction a noticeable prismatic deflection occurs ; this may or may not be desirable. With high degrees of H an increase of power in the glasses required for reading is usually needful at an early age. A serious disadvantage belonging to strong glasses is that they greatly restrict the range within which reading is comfortable. The book must be held at a certain and almost fixed distance. As an instance of extreme hyperopia, I may mention a boy ten years old who required a glass $\frac{5}{6}$ of an inch focus or 33 D. To find hyperopia of 10 D or 12 D is not excessively rare.

On page 83 some remarks were made on the prevalence of H in early life. The results belong to examinations for the total H. Among adults who were largely students and soldiers and after eliminating the statistics whose value appeared to be doubtful Randall finds in 22,743 examinations, Em. 23.8%, M. 21.4% and H 51.9%.

Admitting that more than half the young adults of the community may, as these figures indicate, be hypermetropic, it by no means follows that a large proportion will suffer inconvenience if the error remains uncorrected. The state of health, the vigor of accommodation, the mode of life, and the exigencies of eye-work must all be taken into account. Donders, in 1864, "Accommodation and Refraction," p. 174, said: "In an absolutely mathematical sense no single eye is perhaps to be called emmetropic." Randall, in 1888, makes the same observation (*loc. cit.*), and adds: "Approximate emmetropia (Am. $< \pm 0.5$) is infrequent at all ages, probably at no epoch exceeding 10%." Happily the human race is not compelled to attain mathe-

matical perfection, to enjoy a reasonable degree of felicity. It would be as hard to find an individual perfectly healthy in body as to find an absolutely emmetropic eye. A limited departure from a perfect standard must be admitted to be consistent with a normal eye.

The rigid scrutiny which reduces emmetropia to 23.8% and makes hypermetropia 51.9% conveys a wrong impression of the relative proportion of what their experience shows to be the number of persons with normal eyes. The definition of such an eye may be stated to be one that has acuity $\frac{20}{xx}$ or $\frac{20}{xv}$ without glasses and that can perform all necessary work without pain or fatigue. It would be a serious error to insist on the possession of a mathematically faultless instrument before we could accept a standard normal eye. In a practical sense small errors of hyperopia or astigmatism whether in the cornea or in the lens must be disregarded. Donders placed these insignificant errors between $\frac{1}{100}$ and $\frac{1}{40}$. At the present time the allowable limit would be somewhat less. But the tendency now is toward what seems to me to be a needless degree of exactness. More will be said on this point in the chapter on asthenopia. The examinations of Seggel in the soldiers of the Bavarian army are admitted to be exact and trustworthy, and he reports on 3,052 eyes with the result of E. 46.7%, H. 40.6%, M. 11.4%, and astigmatic and diseased eyes 1.3%. These were young and healthy adults who had not been given to exacting eye-work. *Graefe's Archiv,* Bd. XXX., 11., p 111, 1884.

The degree of shortening of the optic axis which corresponds to a given amount of H is given in the subjoined table from Landolt:

TABLE OF AXIAL HYPEROPIA.

Degree of H.	Amount of shortening.	Total length of Axis.	Degree of H.	Amount of shortening.	Total length of Axis.
	mm.	mm.		mm.	mm.
0	0	22.824 (normal).	8.	2.28	20.54
0.5	0.16	22.67	8.5	2.41	20.41
1.	0.31	22.51	9.	2.53	20.29
1.5	0.47	22.35	9.5	2.66	20.16
2.	0.62	22.20	10.	2.78	20.04
2.5	0.77	22.05	10.5	2.90	19.92
3.	0.92	21.90	11.	3.02	19.80
3.5	1.06	21.76	12.	3.25	19.57
4.	1.21	21.61	13.	3.47	19.35
4.5	1.35	21.47	14.	3.69	19.13
5.	1.50	21.32	15.	3.91	18.91
5.5	1.62	21.20	16.	4.11	18.71
6.	1.76	21.06	17.	4.32	18.50
6.5	1.90	20.92	18.	4.52	18.30
7.	2.03	20.80	19.	4.71	18.11
7.5	2.16	20.66	20.	4.90	17.92

It will be seen in the table that the axial shortening for each D is about 0.3 mm. up to 7 D, but that for higher errors the abatement in axis sufficient to cause 1 D becomes less and less.

Digitized by Illinois College of Optometry

MYOPIA. M.

There are two kinds of myopia. In one the refractive power of the media is excessive, while the optic axis is of normal length. In the other and common form, undue elongation of the optic axis is the essence of the error. The amount of actual increase in length of axis may in general be stated for the lower degrees, to be about 0.3 mm. for each D. Unlike hyperopia, the increase of axis to make one additional dioptry of myopia becomes larger as myopia increases. Beginning for 1 D at 0.32 mm., between — 5 D and — 10 D the average increment for a single D is 0.41 mm. Between — 10 D and — 15 D the average increment for a single D is 0.51 mm. Between — 15 D and — 20 D the average increment for a single D is 0.60 mm. Exceptionally it has been shown that

TABLE OF AXIAL MYOPIA.

Degree of M.	Amount of lengthening.	Total length of Axis.	Degree of M.	Amount of lengthening.	Total length of Axis.
	mm.	mm.		mm.	mm.
0	0	22.824 (normal).	8.	2.93	25.75
0.5	0.16	22.98	8.5	3.14	25.96
1.	0.32	23.14	9.	3.35	26.17
1.5	0.49	23.31	9.5	3.58	26.40
2.	0.66	23.48	10.	3.80	26.62
2.5	0.83	23.65	10.5	4.03	26.85
3.	1.01	23.83	11.	4.26	27.08
3.5	1.19	24.01	12.	4.73	27.55
4.	1.37	24.19	13.	5.23	28.05
4.5	1.55	24.37	14.	5.74	28.56
5.	1.74	24.56	15.	6.28	29.10
5.5	1.93	24.75	16.	6.83	29.65
6.	2.13	24.95	17.	7.41	30.23
6.5	2.32	25.14	18.	8.03	30.85
7.	2.52	25.34	19.	8.65	31.47
7.5	2.73	25.55	20.	9.31	32.13

eyes whose axis comes within the usual limits of 22 to 25 mm. may be myopic. Stilling measured two eyes with axes of 26 and 25 mm. respectively, in each of which the myopia had during life been determined to be exactly 5 D. It is not found that the curve of the cornea has any regular relation to myopia. I have found the radius both shorter and longer than normal. As to the refractive index and curves of the crystalline we know nothing. It has been shown that a few cases of myopia are congenital,[1] and often the subjects belong to the poorer classes of society, while the vast majority of cases exhibit the condition after eight years of age. Its beginning may date from the twelfth or fifteenth year of life, or even perhaps later. The period of most rapid development is

[1] Tscherning, "Studien über die Aetiologie der Myopie." Graefe's Archiv, xxix., 1, 201.

Digitized by Illinois College of Optometry

between the ages of twelve and eighteen. The proportion of myopes in the community is estimated by Tscherning (Copenhagen) at 8%. Great attention has been given to the production of myopia in children, and as the result of the labors of many observers we have statistics of over 70,000 cases.

We have seen that the normal condition of the eye at birth is hyperopia, and that increase in length of the axis brings about emmetropia, while a further advance will occasion myopia. It is of great importance to discriminate between the moderate degrees of M which are simply an inconvenience with some compensating advantages, and the higher grades which are eminently serious and often dangerous. Donders pronounced every myopic eye a diseased eye. Every highly myopic eye is diseased, but within late years it has been shown that the remark conveys a false meaning respecting a large number, and these the moderately myopic eyes. It will be admitted that up to 3 D the cases are seldom serious, it being generally possible to give perfect vision by proper glasses. Above 6 D we do not expect to procure correct vision, and look for various pathological lesions and often there is great peril to sight. Blindness, as the effect of detachment of the retina, of intra-ocular hemorrhage, etc., is too often the outcome of myopia. The cases between 3 D and 6 D may or may not be of serious character.

Myopic persons whose error is moderate recognize distant objects tolerably well, notwithstanding when tested by the usual methods vision may be less than $\frac{20}{100}$. Even in this respect great differences will be observed. I have noted with the same optical error uncorrected, say 1 D or 2 D, differences of vision varying between $\frac{20}{40}$ and $\frac{20}{100}$. Their habit is to half shut the lids, to reduce the pupillary aperture, and they rely upon their familiarity with accessory conditions of form, color, brightness, contrast, etc. For work near at hand, reading, sewing, etc., they have the advantage of less effort of accommodation and get larger images by a close near-point. At the usual age of presbyopia they are not obliged to use glasses, and there may be an abatement in myopia and improved distant sight. This advantage will not be available where M is greater than 3 D or 4 D.

Causes.—Occurring ordinarily during school life, it has naturally been inferred that unfavorable conditions in the school room as to light, the attitude of the head, the distance of the book or paper, the hygienic conditions, the duration of study have an important bearing on the production of myopia. Cohn, Fuchs, Horner and others have diligently labored to correct in their respective countries the faults to be found in school construction and arrangements. There has been room and need for the improvement which

has been brought about. It now appears that under the better conditions of certain modern institutions in Germany, an abatement in the number of cases of myopia has been realized, amounting to 6% (von Hippel). This is not a large gain and it may be put alongside the fact established by Dr. H. Derby that a course of study in such an institution as Harvard University in this country, where the hygienic conditions cannot be impugned, results in the development and increase of myopia. The subjects were between the ages of seventeen and twenty-five. Fixing upon objects at short range, say, less than 12 inches, implies strong efforts both of accommodation and convergence. Let the sclera be relatively weak, and the back of the globe begins to stretch. Nor is this result limited to the juvenile stage of life. I have seen it begin in an apparently robust student of twenty, during his third year in college.

Habitual occupation with small objects near the eye, as when children first take to books, either for pleasure or study, or when learning to draw or to sew, or they are kept at a piano in a dark corner, or the school-room has not the full quota of light which is each child's right, or the benches and desks are so contrived that the child sits crouched or crooked, or a heavy lexicon compels a stooping posture, or the text is badly printed, or is in a language whose characters are intricate and unfamiliar, like Greek, or German, or Hebrew: such are some of the occasions of myopia.

It has been shown that accommodation alone has little effect in causing myopia, but being associated with convergence the two are considered together. The evils of convergence are manifestly due to excessive pressure. Now strabismus occurs mostly with hypermetropia, and the apparent contradiction is explained by calling to mind that the short axis eye will rotate easily, while the long axis eye of myopia presents proportionate difficulty in rotation. Moreover, the most hurtful conditions appear when antagonistic forces oppose each other, which no longer arises when a weak muscle has surrendered, as in strabismus. It is a recognized fact that opposing muscles aggravate myopia, certainly in causing asthenopia, and probably in contributing to extension of the visual axis. The following are the factors which have been dwelt upon as effective: 1. The internal and external recti cause compression under high angles of convergence, by which the externi are stretched and the insertion of the optic nerve is dragged upon. 2. Stilling[1] lays chief importance upon the influence of the superior oblique, which he finds to be extremely variable in its direction and extent, and which, when the visual lines converge, aids in adduction. If, as he sometimes finds, its course is quite transverse and its fibres inserted near the optic entrance, it adds materially to the compres-

[1] "Untersuchungen über die Entstehung der Kurzsichtigkeit," Wiesbaden, 1887. Seggel, Graefe's Archiv, xxvi., 2, s. 1, 1891.

sive action during convergence, and also drags upon the optic nerve entrance. He adduces autopsies of 102 eyes in support of his theory (p. 32, l. c.) and also takes into account the shape of the orbit in so far as thereby the pulley is placed higher or lower and permits the muscle to lie more or less closely in contact with the globe. 3. Arlt attributes to the inferior oblique and external rectus an indirect effect by pressure on the venæ vorticosæ which promotes choroidal stasis. 4. The same congestive tendency results from bending forward of the head and neck. 5. Subacute inflammation of the choroid and sclera, which Graefe designated under the name of sclerotico-choroiditis posterior and by which he explained the choroidal crescent adjacent to the papilla, was formerly much dwelt upon. In this view he was, to a considerable degree, in error, while that in some cases such an inflammatory process occurs, is admitted. It is now accepted that both mechanical and inflammatory or degenerative processes go on simultaneously. In some cases the latter seem to be primary, while the former are by far the most common, and always co-operate with the latter. It is easy to believe that there may in some cases be a lack of resistance in the posterior part of the sclera, yet anatomically this is difficult of proof. Clinical experience has shown that suspension of accommodation has very slight influence in abating myopia.

Stilling thinks that movement of the eyes up and down in reading is an important provoking circumstance, the effect of the obliqui being then greater. He remarks that among watchmakers myopia is rare, while very common among instrumental musicians. Stilling calls attention to the prevalence of a low-roofed orbit among myopes, and many have entered on this inquiry, which seems to have a basis of fact, although opinions vary. The effect is to make the action of the superior oblique more compressive.

But while mechanical action explains the usual cases of myopia, it does not explain certain exceptional forms, viz.: the congenital, such as occur among illiterate people, and those who use their eyes only for distance, and the cases where myopia suddenly and rapidly develops in adults or old persons. These are cases of inflammatory action akin to hydrophthalmus, and, as above remarked, many times both causes combine.

The effect of constitutional conditions in exciting or predisposing to myopia is forcibly presented by Dr. Batten (*Oph. Review*, January, 1892), and he lays stress on the tokens of general vascular lesion in young persons, as proven by, 1, spontaneous hemorrhages (epistaxis, menorrhagia, retinal hemorrhages); 2, capillary congestion; 3, cardio-vascular disease. He dwells on the full, soft pulse of young persons, an acute rheumatism as a frequent precursor of myopia, and that choroiditis may be both a cause and consequence of the lesion.

Digitized by Harvard College Library

We have thus an ordinary and an extraordinary type of myopia, sometimes called the benign and the malignant, also we are to distinguish between stationary and progressive conditions. Progressive myopia if occurring during the years of growth need not excite very serious concern, but if progress continue beyond the age of twenty or a sudden increase appear during adult life we have before us a grave condition. In making the distinction between these conditions, we must be guided by the degree of visual acuity which is obtainable by glasses, and by the ophthalmoscopic appearances. High degrees of myopia almost never have normal vision, and frequently we find lesions quite sufficient to account for it; even when we do not, stretching of the fibres of the optic nerve will explain it, or in rare cases it may be fair to assume that a congenital or precedent amblyopia compelling very close approximation of objects, has been the predisposing cause of the actual myopia. It becomes proper next to consider the

Functional Disturbances and Pathological Anatomy.— The error often becomes established without the consciousness of the subject; it may reach 3 or 4 D and not attract his attention. Frequently it is recognized by accident or by the questions of another. To accidentally find myopia in one eye and not in the other is not at all rare. On the other hand, the development may be with pain or weariness and photophobia and inability to study. Besides the indistinctness of distant objects there may be occasional blurrings of print and the eyes look irritable. When of moderate degree the myopic eye looks normal, but in the higher grades it becomes prominent, pushes the upper lid, and in its movements betrays its elongated form. The anterior chamber is deep, the pupil large and slow to act, the periphery of the iris is retracted. The myope has a vacant look and his face has little expression, he half shuts his lids and wrinkles his forehead. He is often abstracted, inattentive to his surroundings, perhaps easily embarrassed, or without meaning it has an air of effrontery, is more fond of books than of society, given to sedentary rather than to out-door and active pursuits.

To the ophthalmoscope the eye will in moderate cases show no lesion, but in most cases we find a whitish crescent on the outer side of the optic disc. This is called the choroidal crescent and by Jaeger the conus (see Fig. 33). It is found in a few cases of hyperopia and emmetropia, but it is almost distinctive of myopia. Fig. 33*a* shows in section the elongation and atrophy of the choroid at the back of the eye. Loring (Trans. Internat. Med. Congress, 1876) found in 2,265 eyes that the crescent existed among emmetropics in 3.33%, among hyperopics in 3.49%, among myopics in 20.56%. Schnabel[1] among 135 cases having the crescent found

[1] Graefe's Archiv für Oph., xx., 2, p. 1.

Digitized by Google

73% myopic, 13% hyperopic and 13% emmetropic. When high degrees of myopia are examined the crescent becomes still more frequent. Graefe put it at 90%. Much discussion has been held upon the significance and origin of this lesion. We have at length, thanks to the observation of Nagel[1] and the anatomical examinations of Weiss[2] and Herzog Carl Theodor,[3] facts which determine its character and mode of formation. In 1861 Jaeger[4] when describing the crescent, spoke of a peculiar look of the disc on the nasal side, and said that such eyes anatomically examined presented a peculiar bending of the optic nerve fibres toward the crescent. These remarks did not excite attention. In 1880 Nagel brought to notice a later observation of Jaeger in 1866, that the pigment epithelium of the retina in certain cases of myopia is

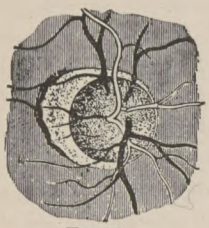

FIG. 33.

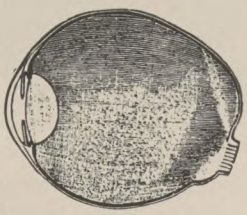

FIG. 33*a*.

dragged over the nasal edge of the disc, and he announced that in many cases he had by the ophthalmoscope perceived that both the retina and the choroid were thus drawn over (see Jaeger, pp. 66, 67 and Figs. 29, 30), while on the temporal side the membranes had been pulled away from the nerve edge and in this way occasioned the crescent. Two years later Weiss examined two eyes one of which had M 5 D and the other a little less, and in which the so-called supratraction of the choroid had been observed during life. He subsequently examined three others and Herzog Carl Theodor has examined another.

We will first give attention to the ophthalmoscopic appearances. We may have a simple crescent of small size attached to the temporal side of the nerve and marked by a pigmented edge (see Fig. 33). This may grow larger, and still larger (Fig. 34). When equal to more than half the disc we may often see specks of pigment or choroidal vessels upon the surface. The crescent may not only extend temporal-wise, but up and down. It may surround the whole nerve. In extreme cases the whole posterior region of the fundus

[1] "Mittheilungen aus der Ophthalmiatrischen Klinik in Tübingen," 1880, Hft. 1, p. 231.

[2] Ibid., Bd. i., Hft. 3, p. 62.

[3] Ibid., Bd. ii., Hft. 1, p. 56.

[4] "Ueber die Einstellung des dioptrischen Apparates im menschlichen Auge," p. 61.

Digitized by Internet Archive for Ophthalmology

shows thinning of the choroid and rarefaction of the pigment. Figure 34 indicates some of these conditions.

What has been found in a slight case of myopia where the globe was $24\frac{2}{3}$ mm. long and the M probably not more than 3 or 4 D, is figured in the cut taken from Weiss's paper, Fig. 35 ("Mittheilungen," 1884, Taf. 11, Fig. 1). The condition may be described as a dragging of the papilla to the temporal side in which the retina, choroid, nerve fibres and sclera, the lamina cribrosa and vessels participate. The conspicuous element is the displacement of the choroid. At the edge of the opening for the passage of the optic nerve, it is attached both to the sclera and to the lamina cribrosa. In fact the fibres of the latter belong in great measure to the choroid. The choroidal opening is elongated in the direction of the crescent and made oval; its nasal border reaches over the papilla and carries with it the retina. The supratraction may reach the middle of the disc. On the temporal side the choroidal edge is dragged

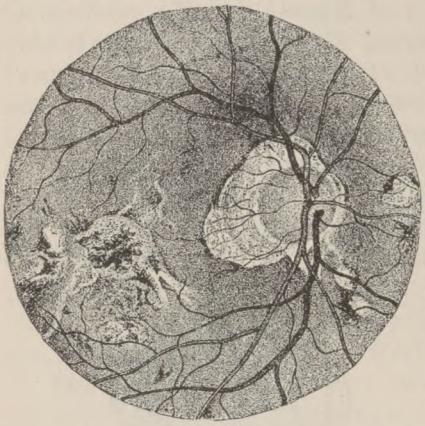

FIG. 34.

FIG. 35.

away from the disc, drawing with it the nerve fibres and fibres of the lamina cribrosa; the edge of the sclera becomes oblique and its inner surface is exposed, in proportion to the extent to which the choroid is retracted. Thus the crescent is formed partly by re-

Digitized by Illinois College of Optometry

traction and thinning of the choroid, and partly by a perspective view of the scleral canal, and upon it we have the commingled fibres of the optic nerve and lamina cribrosa. In moderate degrees of the crescent or conus, we simply have the opening out laterally of the scleral canal and there may be more or less pigment brought to view. But in higher grades there is real atrophy of the choroid with irregular islands of pigment, atrophy of vessels, some of which may remain or everything may have disappeared, except the elastic layer. The retina also suffers on both sides of the disc. The inner granule layer and layers interior to it, will be intact, while the layers external to it are deficient. The bacillary layer is destroyed both on the supratracted and on the crescent side, and this explains the enlargement of the blind spot which characterizes such cases. It is seen in Fig. 35 from Weiss that on the nasal side the retinal pigment has been drawn over the edge and turned up; this will be seen by the ophthalmoscope as a dark border. On the temporal side the choroidal edge where it becomes more normal, also shows some increase of pigment, and the damage to the outer layers of the retina is usually more extensive than this limit. Figs. 36 and 37 from Jaeger show the same changes with less detail and are instructive.

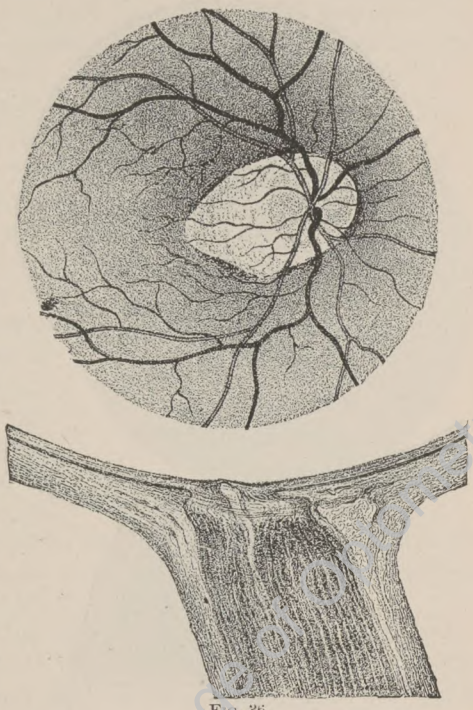

FIG. 36.

In advanced cases where a crescent has been converted into a ring of atrophy, though no traces of it can be seen by the unaided eye, the microscope shows the presence of supra- and also re-traction, or that the papilla has been pulled in all directions. Stilling explains the variations in the direction of the crescent, by the traction of the fibres of the superior oblique when its tendon happens to reach more or less to certain parts of the circumference of the nerve. It is of course understood that a bulging of the sclera occurs at the posterior pole which may be either broad or sharply defined. While the mechanical displacement with textural atrophy

Digitized by Google Library of Congress

is going on, changes occur both in the sheath of the nerve and in the adjoining parts of the choroid. The intervaginal space is greatly distended and chiefly upon the nasal side (see Figs. 36, 37). To this Donders called attention. The sclera becomes thin and the pigment of the choroid is absorbed. Added to this is degeneration of the vitreous; it becomes liquefied, either so as to form larger or smaller cavities in its substance, or it will be separated from the retina by a layer of fluid. The hyaloid membrane may be split into two or more layers and the membrana limitans of the retina becomes brittle and easily separated from the deeper layers. Fibres and cells and detritus float in the fluid vitreous and cause the shadows called *muscæ volitantes*, of which myopes so constantly complain. In its anterior part, the retina in severe cases is found to have become, as it is called, œdematous, *i.e.*, the layer of inner granules has been distended into spaces which are filled with a coagulable fluid.

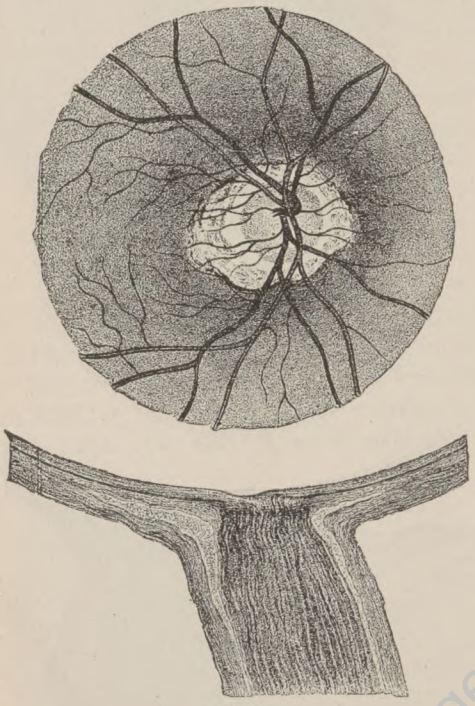

FIG. 37.

The ciliary muscle of the myopic eye is characterized by the fewness of its circular fibres, while the meridional are in large number and reach far backward even beyond the ora serrata. Herzog Carl Theodor says that in some myopic eyes the circular fibres are in reality not wanting, but are pushed aside and crowded together into a small space and for this reason may be overlooked.

In this sketch are embraced most of the points of the real pathology of myopia. The explanation of the mode of occurrence of the crescent, assigns to it an entirely mechanical and not an inflammatory origin; the evidence that the phenomena are the result of pressure enables us to impute the real cause to the extrinsic muscles of the globe. The part which can be played by the ciliary muscle is evidently nothing more than resistance to the stretching at the posterior pole, while itself becomes elongated and is really more a passive than an active agent.

Digitized by Illinois College of Optometry

Besides degeneration of the vitreous to which allusion has been made, we have in advanced cases, cataract, beginning by preference at the posterior pole of the lens and evidently due to imperfect nutrition. The whole of the choroid may take part in the atrophy in extreme cases, the pigment cells becoming emptied of pigment, the chorio-capillaris and the middle layer of vessels becoming partially obliterated.

More damaging is the occurrence of choroidal changes at the region of the posterior pole and even in the macula itself, where sometimes a distinct spot or group of spots of atrophy appears (Fig. 38). The effect upon vision is generally disastrous, causing a central scotoma. Even when very faint traces of choroidal lesion exist, or perhaps none can be seen, the cones in the macula may become separated and deranged so as to cause straight lines to appear crooked—*metamorphopsia.* Hemorrhages are not infrequent in advanced myopia and too often in the region of the macula. The most deplorable occurrence, and which affects myopic eyes more than any other is sub-retinal effusion, or detachment of the retina. This destroys vision over an extensive part of the field, or perhaps *in toto* and is rarely amenable to treatment. It will be considered when speaking of diseases of the retina.

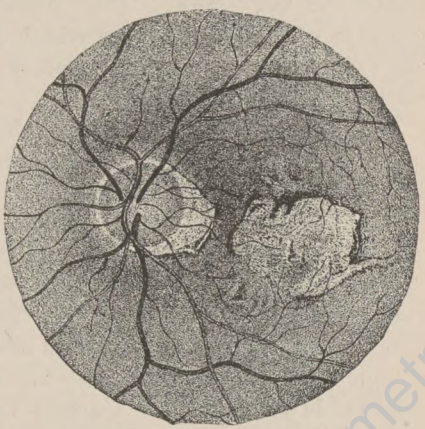

FIG. 38.

Besides the troubles within the eyeball, there are to be mentioned, the frequent troubles of the muscles, inequality of the eyes (*anisometropia*), and astigmatism. As to muscular incapacity, it is the rule to find it in high degrees of myopia. It is the result of being obliged to converge to a point too near for the muscles to permanently maintain the effort. The longer the axis the more difficult does it become to turn the eyeball inward. The interni must contract extremely, the externi are stretched and wrap around the globe and even the optic nerve in extreme convergence must suffer traction on the outer side of its sheath. The result of these hindrances is that insufficiency of the recti interni and positive diverging strabismus are frequent complications. On the other hand we also meet with strong degrees of converging strabismus in the higher grades of M. It is possible often for myopes to direct one eye up and another down, as shown by their unusual power of counteracting the diplopia caused by putting a

Digitized by the Internet Archive of the College of Optometry

vertical prism before one eye. Their grasp upon binocular vision is much feebler than that of other persons. When the globe is much lengthened as, for instance, to 28 or even 30 mm., such an ellipsoid manifestly rotates with difficulty in a cavity whose shape is somewhat similar. The centre of motion is displaced and in most cases is farther from the posterior surface of the sclera than in the emmetropic (Donders, p. 404).

These troubles will be again adverted to. An apparent strabismus convergens is often seen in myopes, because the line of fixation is from the shape of the cornea liable to fall to the outer side of its axis. In other words the angle gamma is either negative, or if positive is very small. (See page 14.) Weiss presents this in a diagram of one of the eyes which he examined. In great myopia the radius of the cornea becomes longer than usual, in harmony with the general distension.

In the last degree of myopic change the lens becomes partially or wholly cataractous, and, because of fluidity of the vitreous, is liable to be luxated backward or downward. Intraocular hemorrhages are prone to occur. In extreme cases the distention of the eye attains the condition called hydrophthalmus, and it may be difficult to say what part of the result is to be ascribed to a genuine irido-choroiditis, and what to the processes of simple myopia. Enucleation may then become a necessity. In external appearance myopic eyes often attract attention by their prominence and their observable ovoid form. Usually the pupils are large and inactive, but in all these particulars the contrary conditions may be true. The strictly congenital cases do not differ in essence from those which reach a high development in later life, and we need make no special reference to them beyond what has been said.

Prognosis.—For practical purposes we may divide cases of myopia into classes according to their degree and their progress—into the moderate and the extreme—into the stationary and the progressive. The acutely progressive are by some described as malignant myopia, a name which seems for several reasons objectionable. We can recognize M amounting to 0.5 D, and as the far-point is then at 80 inches there is a manifest lack of clear distant vision. Even up to 3 D the error may be called slight. From 3 D to 6 D it may be called of medium degree, while all above 6 D are to be counted extreme and therefore serious. Horner well says, great myopia is the more dangerous the younger is the subject. Every practitioner can substantiate this; and he also says that the dangers of high myopia are most threatening in the later part of life, *i.e.*, after 50 years of age. Then come vitreous degeneration, cataract, and subretinal effusion.

For myopia below 4 D which has reached its maximum and is

stationary, there need be no anxiety as to the welfare of the eye, and both acuity and working power are often admirable. If it become stationary between 4 D and 8 D acuity is often slightly deficient, viz.: $\frac{2}{3}$ or $\frac{1}{2}$, and the working power may be good or otherwise. Muscular troubles and astigmatism are apt to be present, but prognosis is not serious. When above 8 D the case is grave and the future will be influenced greatly by the health of the person, his surroundings and the extent to which he uses his eyes. In his statistics of blindness Cohn sets down 10% as due directly or indirectly to myopia. He includes cases in which one eye only is blind.

Diagnosis.—Remarks very similar to those in discussing hypermetropia might be repeated. We test for distance by glasses and found the diagnosis *conditionally* upon the fact that concave glasses give normal acuity. It is not proven by this test, because with defective acuity there may be great myopia, and with perfect acuity thus procured, there may be no myopia. We must resort to the objective tests; the direct ophthalmoscopic method, or to Cuignet's method. Spasm of accommodation simulates M, and, as said before, while it usually disappears in the dark room, in special cases it still persists. When a doubt exists, one may more willingly resort to atropia than is admissible in either H or E.

The occurrence of myopia from excessive curvature of the cornea is not to be forgotten, and will be especially mentioned under conical cornea. The refraction is always irregular, and the error will betray itself by the shadow test, and with absolute certainty by the ophthalmometer of Javal and Schiotz; under oblique illumination and by direct ophthalmoscopy it will usually be discovered.

Prophylaxis.—Because myopia is for the most part an acquired anomaly and dependent, as has been shown, on excessive use of the eyes during the tender years of life, it is imperative to set forth the methods which can be employed to prevent or restrain it. Efforts in this direction are sometimes met by the objection that the error is hereditary and therefore the attempt is useless. Loring[1] ably discusses this point; Tscherning and Landolt review what others have written. It is very difficult to get statistics of real value, but this may be said, that the *predisposition* may be hereditary, but that the *determining causes* are *acquired* and largely *preventible.* The cases which are congenital, and they are generally those of high degree, are very seldom hereditary. With the clear evidence that the error is brought about by improper modes of life and of use of the eyes, preventive measures become imperative. The first thing is to promote a vigorous state of health, and in this all that relates to home hygiene, to food, air, sleep, and exercise, are to be regarded. Second, the arrangements in schools and the hours of

[1] Transactions of International Med. Cong., Phil., 1876.

study, the light, the air space, the height of benches and desks, the distribution of study hours and play, the print of books, attitude in reading and writing,—all these are potent in their influence. On these points, Cohn and Fuchs, Berlin and Javal have written elaborate monographs and Cohn[1] gives the literature of the subject. In the United States there is need of attention to the conditions of school life in many particulars, although our school houses are free from many of the evils complained of in continental Europe. As regards the hours of study and of play respectively, we are not so much at fault as are the Germans, but the tendency is to over taxation and therefore myopia. Frequent intervals of rest are most important, and children can naturally be better cared for in small than in large classes. Imposing long study hours out of school is another hurtful practice. Reading by dim light at home, by firelight, at twilight, sewing and embroidery, are things to be prevented. Certain trades and occupations have a mischievous effect. The most conspicuous are the type setters, whose ratio of myopia is nearly as high as that of the higher students. Watchmakers and jewellers have been shown to be little subject to the error because they work so much with a magnifying lens and without convergence and without much movement of their eyes.

The great factor in preventing myopia is cultivation of out-door life and its consequent promotion of health and use of eyes upon distant objects. It is known that the English have a lower percentage of myopia than exists on the Continent, and it is fair to connect their exemption with their fondness for out-door sports. Among us as Americans the same tastes exist, and not only for this reason, but because of our better conditions of existence, we should have less of the evil. In our cities we have little advantage above other nations, although the native population in the cities is less prone to myopia than the children of Germans (Loring).

Dürr's[2] examinations found spasm of accommodation among only 11 out of 133 myopes; *i.e.*, 7.3%. Latent A more than 1.66 D he reckons as spasm. In 30% there were choroidal changes. He lays the greatest stress on the undue proportion of working hours exacted from children. He lays, as does Von Hippel, less stress on imperfect arrangements in the school buildings, than upon simple overtaxation whether at home or at school. He compares the total number of school hours demanded of children between the ages of 10 and 19 years in England, France and Germany; they are 16,500, 19,000, 20,000. Hours of recreation, are, in England, 4,500; in France, 1,300; in Germany, 650. It is also shown by a curious table, p. 145, that the more gifted scholars, compared to their less brilliant comrades, are near-sighted in the ratio of 32 to 38.

[1] Lehrbuch der Hygiene des Auges, 1891–92. [2] L. c., p. 141.

Digitized by Harvard College Library

Digitized by Illinois College of Optometry



Digitized by Ohio College of Optometry

In describing the ophthalmoscopic appearance of the optic nerve in myopia, the situation of the choroidal atrophic crescent has been described. We may now call attention to certain less frequent anomalous conditions which resemble this lesion, yet must be discriminated from it. They are most frequently associated with myopia, and in many instances with myopic astigmatism and hence may here be introduced. That we sometimes find an apparent crescent on the lower side of the nerve has been referred to. A close inspection of these cases shows that the crescent may sometimes be divided into two parts, of which the upper part is gray and the lower whitish. It is easy to recognize in many cases that the crescent is an oblique surface or pit. In fact these cases are spoken of as coloboma of the sheath, that is of the scleral canal of the optic nerve. To this may be added a real choroidal crescentic atrophy. The lesion is essentially congenital. It is usually associated with amblyopia. One eye only may be affected. Of the illustrations on Plate I. instances of this type are Nos. 2, 3, 4, 5, 6, 8, 9, 10. In No. 1, a physiological excavation is unusually situated, viz., at the lower edge of the disc, and we also have the crescent below. In No. 7 the lower and outer half of the disc is much flattened and merges into the crescent.

Besides the anomalies mentioned, others are to be noticed, viz., that in No. 1 the vessels emerge in a direction contrary to the usual fashion, *i.e.*, toward the nasal side instead of toward the temporal side. In R. No. 6, the trunk comes out as three branches instead of two. In Nos. 8 and 9 the vessels are peculiar. In 12 is a large choroidal atrophy and the refractive state of different localities is designated. This evidences distinct local staphyloma. In No. 11 is depicted a coloboma of the macula lutea: viz., the large central white surface upon which are pigment spots. Near it are two small circular patches of choroidal atrophy. Beneath the disc is a crescent. A case of this type I have never seen. Loring[1] has figured a case, and refers to several. It will always be difficult to decide between an acquired and a congenital lesion of this kind. Coloboma of the optic sheath was first described by Liebreich:[2] see also Nieden.[3]

In No. 13 is presented the very rare anomaly of a mass of connective tissue covering the principal part of the papilla. The above illustrations are taken from a paper by Prof. Fuchs, Graefe's *Archiv für Ophth.*, Bd. XXVIII., Abth. 1, S. 139, 1882.

---

[1] Loring: "Text-book of Ophthalmoscopy," p. 94.
[2] "Atlas d. Ophthalmoscopie," Taf. xii., figs. 1, 2.
[3] Knapp's Archives of Ophthalmology, vol. viii., p. 501.

Digitized by Harvard College Library

Treatment.—This divides itself into (1) the hygienic, (2) the optical, and (3) the therapeutic. What has been said about prophylaxis includes the hygienic measures to be adopted when myopia has begun. There must be such a reduction in the hours of study and of close application as shall tend to diminish the rate of progress. Entire abstention might be necessary, but can seldom be enforced. The inclination to read for amusement must be checked and everything to promote health be resorted to. If there be a delicate or strumous constitution, especial pains must be taken by food and habits and appropriate medication to build up the tissues. It is by no means always possible even with the most careful management to prevent the increase of the error during the years of juvenility. I have followed a number of such cases and not been able to prevent the increase, but have probably been of service in restraining it. If the wisest efforts can only partly control the progress of the error we are not therefore to cease to attempt its control. Upon students in colleges and high schools advice should be inculcated, and they must be convinced of its importance. Occasional seasons of rest are of importance, say for two or three weeks. They give time for the intraocular circulation to become regulated and for the muscles to gain repose. Much stress has been laid upon the value of atropine in checking myopia. But this remedy has now few supporters and the most that can be claimed for it is that under its use the degree abates about 1 D. This will not be a permanent decrease, the ordinary tension soon returns. It gives a good opportunity for examination, because it helps to enforce abstention from use, and if the far-point be inside of 20 inches, it is no great annoyance, and I not infrequently use it. Abandonment of near work is the essence of the benefit, not suspension of accommodation.

The corrective treatment is in the selection of glasses. If with unaided eye any letters on the card are read at 20 feet, the degree is not great. If no letters are read, an approximate idea is gotten by noting at what distance the person holds the book in reading Snellen 2. Begin with trying, on one eye at a time, the weaker numbers. If strong glasses are being used, viz., above — 6 D, and the vision is nearly corrected, try whether sight is helped by holding the glass nearer or farther away. If the former, it is too weak; if the latter, it is too strong. Myopes are often sensitive to an interval of $\frac{1}{60}$ or less. With too strong a glass they complain of being dazzled, and shrink from the unwonted brightness of objects. Much respect is to be paid to their impressions; but, when they have been wearing inadequate glasses, they are liable to mistake the surprising distinctness conferred by a proper glass, for a strain of over-correction. It is often impossible to give them $V=\frac{20}{xx}$; but,

Digitized by Google

before admitting this, careful inquiry is to be made for astigmatism, and the state of the fundus minutely explored by the ophthalmoscope—especially the region of the yellow spot. Moreover, in doubtful cases the patient should have the benefit of atropia—using a solution gr. iv. ad ℥ i. (1 to 120) several times. In seeking the best correction the danger is of getting too strong a glass, which will excite tension of the ciliary muscle. To this, as a rule, myopes are very sensitive.

Among children who chose their own glasses it has been found that in from 19% to 37% (Erisman, Cohn) they were too strong. The same is not infrequent among adults. Many circumstances are to be considered in giving concave glasses. 1st. The degree of error. 2d. The quality of sight. 3d. The occupation and necessities of the person; the age, the sex. 4th. The state of the muscles. 5th. Whether the eyes have equal value. 6th. The condition of the interior of the eye, which is, perhaps, included in quality of sight. With persons whose error is small, glasses are usually wanted only on special occasions, and none for near work; they care only for eye-glasses. Even with — 5 D some myopes care little for them, and if they do use them, complain that the habit of using them disqualifies them for as good discernment without them as they possessed before. This is simply an alteration in mental habits and not in sight. As a rule, however, persons having between 4 and 10 D gladly avail themselves of glasses for uninterrupted use. But when glasses are above 6 D some complain of fatigue from their continuous wear. This may be due to muscular fatigue, to anisometry or simply to the continuity of attention which sharp sight induces. The value of this factor can hardly be appreciated by the emmetrope. To the myope taking off the glasses is sometimes like going out of the blazing sun into the shade. A large latitude must be allowed for idiosyncrasy. Where the very high grades are reached, viz.: above 10 D, generally the person wants the full correction. Of course we must be governed by the state of the interior of the eye and the acuity of vision. But even when there may be a large crescent and other choroidal lesions, if the process be *substantially stationary* or *slowly* progressive, I have found it best to give the full correction. There is less effort with the glasses than without them. One may often wisely impart a blue tint to the glasses, because from a large crescent or a patch of choroidal atrophy, light is reflected and diffused within the eye, the effects of which the blue color somewhat assuages.

It need only be added that one should always be vigilant to discover astigmatism complicating myopia, because it often makes a great difference in the acuity of sight. A glass may easily be chosen

too strong because of an undetected astigmatism. The concurrence of the two errors is very frequent.

In regard to giving concave glasses to children some special remarks are proper. They rarely need them for near work; for distance they require them to see maps and the blackboard in school and for such purposes. If the error be below 2 D they may get along by coming to the front, but when above that they should have spectacles and wear them most of the time. If the error is above 4 D the glasses should be worn constantly when the subject is 13 or 14 years old. They have an important influence in mental habits and character; they do not, in my judgment, when well chosen and with no special contra-indications, hasten the progress of myopia. They keep the working point at a suitable distance and by developing the power of accommodation assimilate the person to the emmetrope. It is, of course, assumed that there must be no tendency to unnatural approximation of the work permitted.

For most myopes it is necessary to gradually become habituated to glasses. They may wear them for short periods until they become accustomed to them.

What has been said applies for the most part to distant vision. We are sometimes obliged to order a special glass for near vision. This happens in persons whose accommodation is feeble either from want of use or from age, or whose myopia is high. It may be for playing the piano, for writing, especially with book-keepers who must cast their eyes over two or three large account books. How shall the glass be selected? A simple calculation will determine. Take the distant glass as a basis. Let it be 6 D, which we will call 7″. The working point is to be at 20″ = 2 D. We have 6−2 = 4 D. A glass 4 D will bring the near-point to 20″ and will meet the need. Or, if the working point is to be at 1 foot which is $\frac{40}{12}$ = $3\frac{1}{3}$ D we may give 3 D. The middle-aged myope and likewise the younger will do near work without glasses provided the near-point is not inconveniently close. It can happen with slight M that after middle life, a convex glass is required for near work, and myopes of higher grades reduce the strength of their glasses or abandon them when the time for presbyopia arrives. But distant vision does not of necessity become improved.

Myopes suffer much from muscular asthenopia and especially from insufficiency of the internal recti. With many who have large error no attempt is made to maintain binocular vision for the near. They put off their glasses and use one eye only, while the other is allowed to diverge. In this way, despite the inconvenience of holding a book very near, many read for hours in comfort. But with others there is an attempt at binocular vision which cannot be maintained. Hence they have pain and asthenopic irritation. Fre-

Digitized by Harvard College Library

quently this can be completely relieved by choosing a weaker glass suited to the working point. In other cases additional relief can be had by decentering the glasses from the median line. Sometimes a combination of abductive prisms and concave glasses can be happily made. Prisms can seldom be made stronger than 5° or 7° because they become too heavy. It is important to examine when asthenopic symptoms exist whether there be any tendency to deviation of one eye in a *vertical* direction. This can be told by a candle at 20 feet with a red glass over one eye and a strong abductive prism over the other, held accurately in the horizontal position. If the two flames are not on the same level, use a prism to correct the deviation, and this prism should be incorporated in the glasses to be worn. I have known an error of 2° make a patient extremely uncomfortable.

But if the muscular error be of a certain amount, resort must be had to an operation, *i.e.*, tenotomy of the antagonist, for its relief. To this reference will be made later. Here it is proper to say, that the only indication which to me is sufficient for this operation is asthenopia of marked type and which other proceedings, faithfully tested, have not relieved or seem wholly unlikely to relieve. Tenotomy as a means of diminishing or arresting myopia has been practised, but it has no warrant in the results which it produces. It can do much harm and has done little, if any, good.

Many times the choice of glasses for a myope is an intricate problem, demanding not only technical skill and knowledge of pathology, but also good sense and general wisdom.

More active measures will be in order when a sudden increase appears, and with it symptoms of retinal irritation with congestion of the nerve, with floating bodies in the vitreous and a retraction of the choroid which by its size and the elongated look of the vessels on one side and their crookedness on the other shows the posterior staphyloma to be increasing, and a subacute inflammatory condition to be in progress or impending. Then prolonged abstinence from work, say for six weeks or longer must be enforced. The artificial leech, or in lieu of this two ordinary leeches, may be applied to the temples at intervals of four to six days. This cannot be often repeated. The milder saline purgatives, especially the mineral waters, may be used, and as an especially efficacious agent pilocarpine may be given. Care must be taken with the last mentioned, if subcutaneously injected, not to give a dose too large. One-sixth of a grain of the muriate of pilocarpine will generally do no harm to an adult, but it has been known to cause great prostration by reducing the heart's action. The value of iodide of potassium and of corrosive sublimate will be in the ratio of visible exudations in the fundus or may be decided by the acuity of vision.

If the vitreous be very hazy and perhaps at the same time the lens, this implies a more acute inflammatory process and might have been mentioned above. For this Horner recommends paracentesis of the anterior chamber, but this remedy is to be used with caution, because the sudden abatement of intraocular pressure is followed by a prolonged increase of congestion. The clinical acuteness of Prof. Horner makes the mention of the proceeding justifiable.

A course of treatment thus outlined will have to be modified by the age and health of the person. If weak and young, drastic measures would only aggravate the case. Then the use of smoked glasses, employment of atropine to insure the greatest rest of the eyes, dry cups to the temples and general hygiene will be all that may be possible, without confinement to a dark room. It is also important that persons in whom myopia makes *rapid* advance should be examined every three months and if needful undergo a series of suspensions from eye work for a month at a time. In some cases of this kind a long sea voyage has proved eminently useful. The cases of high myopia in very early life, especially when it cannot be attributed to overwork, are the least susceptible to treatment and often there are no rational indications of treatment except of the hygienic kind. The stage of inflammation may have given place to that of atrophy, and often we see these deplorable subjects only in this period. At this epoch there is very little value in medication.

A patient highly myopic and knowing something of the perils of his position is often extremely excitable and takes alarm at trifling symptoms—a slight conjunctival swelling, or a more than usually distinct vitreous shadow, brings them in terror for advice. Tact and gentle handling and inoffensive applications, a weak lotion of borax, a mild stimulating liniment to the forehead, and *placebos* generally are the soothing influences which are suitable.

Should a spot of hemorrhage occur, perhaps in the macula, it is rather an index of weakness of the vessels than of undue determination of blood. It is most likely to occur in the cases of disseminated choroidal atrophy or general thinning of the membrane, and in which there are pigment deposits intermingled with atrophic spots. Treatment is chiefly rest and avoidance of light, with very mild derivative remedies. The blood is absorbed slowly, requiring weeks, and afterward there will remain a white spot. Scotoma occurred at the onset of the mishap and this may grow smaller, but will not wholly disappear, and even if it should, metamorphopsia is likely to ensue.

Of detachment of the retina it is not now necessary to speak in detail. Such treatment as can avail has been related when

Digitized by Internet Archive

speaking of the antiphlogistic proceedings. Evacuation of the fluid by puncture of the sclera has questionable benefit. See chapter on this subject, p. 630.

The inequality between the two eyes which in myopia is not infrequent, is often a source of trouble. Sometimes a sufficient acuity can be given to each eye by its proper glass to enable both to work in harmony; at other times one is so amblyopic as to take little part in vision, and its error may be so high as to render correction valueless. An essential consideration is to carry the working point farther off.

To some myopes strong light is a distress, and their glasses may be tinted a light blue. To some the constant observation of objects is a weariness—they prefer to take off glasses and remain in ignorance of what is about them until their eyes are rested. Many are sensitive to the form of the frames, their weight and adjustment, and the eyelashes must not touch the glass. All these points deserve attention. Some persons affect the wearing of a single glass which they have learned to hold in place by nipping it with the brow. If such have two equally good eyes, which generally is not the case, such a practice is no less damaging to the eye than offensive as a mannerism.

The above description of the possible lesions of myopia is calculated perhaps to make the picture of near-sightedness too gloomy, because so many woeful conditions are grouped together. The very large proportion of myopes escape all such disastrous occurrences; but it is highly important to convey the impression that myopia may be more than a mere inconvenience or trifling defect, because it does embrace such sad possibilities.

ASTIGMATISM. As.

When the refraction is such that rays emanating from a single point cannot be brought again to a focus as a point, on the retina, this state is astigmatism; of this there are two kinds, the regular and the irregular. The latter is caused by opacity of the cornea or lens, and does not admit of satisfactory correction, although it can sometimes be mitigated. The former is chiefly dependent on abnormal curve of the cornea or lens, or want of homogeneousness in the lens, and is correctible by cylindric or spherico-cylindric glasses. The defect may be acquired or congenital; irregular astigmatism in the cornea is an acquired error, and some rare cases of regular corneal astigmatism are acquired; but, as a rule, the regular astigmatism of the cornea is congenital. Acquired astigmatism in the cornea, where no opacity exists, comes from conicity of the membrane, or happens after tenotomy of muscles, or after wounds of

Digitized by the College of Optometry

the cornea, iridectomy and extraction of cataract. But these cases are a minority of the whole. Of correctible astigmatism the greater portion are congenital cases. Objection is sometimes made to this statement because the error does not always announce itself until middle life. The explanation is that the accommodation can conceal a considerable degree of error until its vigor begins seriously to decline. It is also to be said that a small degree is natural to almost every one, varying from 0.25 D to 0.75 D, and because the radius of the vertical meridian of the cornea is shorter than that of the horizontal.

We have occasion now to treat only of regular astigmatism and without regard to its locality in the lens or in the cornea. Consisting as it does in a want of uniformity in the radii of the meridians of the media, this error manifestly may complicate either emmetropia, hypermetropia, or myopia. For this reason we have simple astigmatism, either hyperopic or myopic; and compound astigmatism, both hyperopic and myopic; and lastly, there may be mixed astigmatism, in which either hyperopia or myopia may predominate. The symbols of these several conditions are as follows, as they have been given to us by Donders. To him we owe the systematic study and development of this subject, which he made with as much completeness as did Helmholtz the theory of the ophthalmoscope. We have: 1st, myopic astigmatism, Am; and compound myopic astigmatism, M + Am; 2d, hyperopic astigmatism, Ah, and compound hyperopic astigmatism, H + Ah; 3d, mixed astigmatism, with prevalent M, viz., Amh, and with prevalent H, Ahm, or both M and H may be alike.

Whatever may be the length of the optic axis, it is evident that the refraction cannot be homocentric, *i.e.*, from a luminous point the rays cannot again be brought to a point. On the contrary, the focus, instead of being in one plane, is stretched over a certain length which is called the focal interval.

This may be understood by the diagram Fig. 39 taken from Fick, in which CD and AB represent the vertical and horizontal meridians of an asymmetric cornea viewed in perspective from an oblique position. The vertical meridian comes to a focus upon the axis at *o* and thence the rays diverge. The horizontal meridian reaches its focus less quickly, viz.: at *o'* and thence its rays diverge. The space between *o* and *o'* is called the focal interval. The form of this portion of the bundle of rays cannot be a cone, but forms a skew surface. There is no place within it where a punctate focus is formed, but there are linear foci, one at *o* and the other at *o'*. These, however, are not mathematical lines, because at both these places there are other rays which do not join with them. It is impossible to indicate in a diagram the form of the bundle. If, how-

ever, we place a screen across it at the points marked 1, 2, 3, 4, 5, 6, 7, perpendicular to the axis, we shall get the following series of luminous surfaces as shown on Fig. 40—beginning with a vertical oval, 1, 2, then converted to a vertical line, 3, where the rays are focussed which belong to the vertical meridian; then again comes a vertical oval because the vertical rays are going apart; then quickly comes a place where each meridian has equal separation from the axis and the figure is a circle, 5; then comes a horizontal oval; and, lastly, a horizontal line where the rays in the horizontal meridian cross. All this is easily illustrated by using a spherical lens + 6″ focus and adding to it a + cylinder 12 inches focus with which to throw the image of a flame or of a luminous round disc of

FIG. 39.



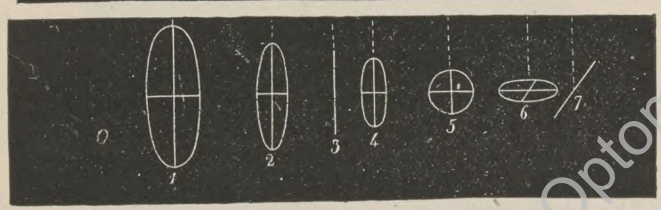

FIG. 40.

ground glass on a screen—all the above changes will be verified if the axis of the cylinder is placed horizontal. The mathematical theory of this condition is intricate, and was developed by Sturm and has been further discussed by Knapp, and very lately by Mathiessen, who modifies slightly Sturm's theory. Knapp has made a model with silk threads of different colors which illustrates very admirably the phenomena. Becker has also done the same by letting fall a beam of light upon a spherico-cylindrical lens set in a glass tank filled with water rendered milky by nitrate of silver. The luminous track is displayed as a pencil of light appears in a dark chamber reflected from the floating particles of dust. The form of the beam can be studied at leisure and all the sections shown which have been described. On a large scale the visual phenomena of astigmatism may be perfectly shown with the

Digitized by the Internet Archive of Optometry

magic lantern by adding a very weak cylinder to the objective, viz., + 1 D, or + 0.75 D.

It has been said that differences in the radii of the vertical and horizontal meridians of the refractive surfaces are the chief causes of regular astigmatism. To this must be added the want of exactness in the centering or collimation of the refracting media. This affects both the cornea and the lens. The geometrical axis of the cornea forms with the visual line the angle alpha, and moreover, as the line of fixation causes the eye to deviate still further from the visual line, the angle gamma (see page 14, Fig. 7) increases the asymmetry of the several surfaces. This want of collimation occasions astigmatism. It is exceptionally the case that the shortest focus of the media is through the horizontal meridian. This is sometimes spoken of as astigmatism against the rule. Slight deviations from the vertical are very common. Astigmatism of the lens may increase or diminish that of the cornea. Javal[1] has shown that a very small fraction of the total astigmatism is due to the lens; he has also shown that by accommodation the lens may partly or wholly neutralize asymmetry of the cornea. He, and before him Dobrowlsky, attributes this to unequal contraction of the ciliary muscle. In some cases of pretty high degree he finds about all the astigmatism in the cornea; what may usually be ascribed to the lens is not more than 1.5 D. He has revived attention to the control which young subjects have over astigmatism, citing himself as an example, that with astigmatism = −2.5 D he could at 24 years of age see the stars correctly as others do. It is a frequent observation that slight degrees of the error first come to light during middle life.

Latent and manifest astigmatism of course refer to the influence of the accommodation in concealing or modifying the error. Like hyperopia this distinction is of most importance in its slight degrees and chiefly among young subjects.

Simple astigmatism affects the emmetropic eye and may be simple myopic or simple hyperopic, Am or Ah. In Am one meridian is emmetropic, the opposite is myopic. In Ah one meridian is emmetropic, the opposite is hyperopic. (See Figs. 41, 42.) The conditions are illustrated in the diagrams.

Compound astigmatism belongs to the ametropic eye; if myopic, both principal meridians will be myopic, but one to a greater degree than the other, *i.e.*, the radius in that meridian will be shorter. If the eye be hyperopic, both principal meridians will be hyperopic, but one to a greater degree than the other; *i.e.*, its radius will be longer than that of the other. We have then, M + Am and H + Ah. (See Figs. 43, 44.)

[1] See Annales d'Oculistique, 1881, ii., 14.

Mixed astigmatism exists in an eye whose axis is normal, but in one meridian myopia exists, while in the opposite hyperopia exists. In other words, in one meridian the radius of curve is shorter than normal, in the opposite meridian it is longer than normal. According as myopia or hyperopia predominate, the cases may be desig-



FIG. 41.—Simple Hyperopic Astigmatism, Ah.



FIG. 42.—Simple Myopic Astigmatism, Am.

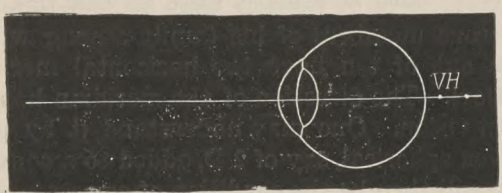

FIG. 43.—Compound Hyperopic Astigmatism, H + Ah.

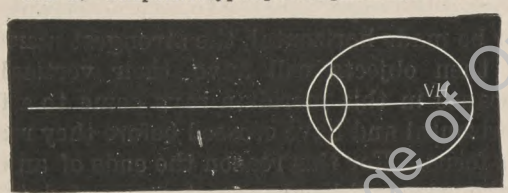

FIG. 44.—Compound Myopic Astigmatism, M + Am.



FIG. 45.—Mixed Astigmatism, H and M equal.

nated as Amh and Ahm. In Figs. 43 and 44 the form of the eye is made myopic and hyperopic—as compared to the remaining figures which are supposed to be emmetropic.

The above are the subdivisions originally made by Donders and they are what we practically have to observe. In the figures H

Digitized by Illinois College of Optometry

stands for the horizontal and V for the vertical meridians. The position of letters and of the dots in relation to the retina indicates the kind of error; in eyes having compound astigmatism one is represented as hyperopic (Fig. 43), the other as myopic (Fig. 44); in each case the vertical meridian has the shorter radius. In mixed astigmatism the axis is represented as emmetropic, while in the eye the myopic meridian, which is the vertical, has an equal error with the hyperopic; equality of H and M is less frequent than marked inequality. Instead of speaking of a shorter radius, it might be perhaps better for the present to speak of the shorter and longer foci, as these are what the diagrams represent. Inasmuch, however, as the principal error resides in the cornea, the terms may be used indiscriminately. It is at the same time clear that ametropia and astigmatism are two distinct conditions, although they may coexist.

It has been remarked that the meridian of shortest focus or of shortest radius is usually vertical. To this rule there are numerous exceptions, not only in obliquity of the principal meridians, but in complete reversal of the rule, so that the horizontal may be the strongest. Javal says of himself that he has this condition and that in numerous members of his family among whom the error prevails, nine out of ten have the horizontal meridian stronger than the vertical. The direction of the meridian has an important influence upon vision. One may understand it by putting before his eye a convex spherical, say of 2 D, added to a convex cylindrical of 3 D; there will then be the condition of compound myopic astigmatism, supposing the experimenter to be emmetropic. If the axis of the cylinder be made horizontal, the strongest meridian becomes the vertical; then objects will have their vertical dimensions lengthened because in this meridian rays come to a focus quicker than in the horizontal and have crossed before they reach the plane of the latter's focus. For this reason the ends of an object will be fringy, while the sides will be sharp. A series of dots in a vertical row will run into each other and make a solid line with blurry ends. If the axes be reversed to the horizontal, objects will seem broadened; the top and bottom will be well defined, the sides blurry. The dots remain separated, but extend laterally into brushes. With the axis in an oblique position, an elongation takes place in the *direction of the strongest meridian or opposite to the axis.* If glasses of an opposite type, viz., concave, are employed by which hyperopia is induced, the phenomena will not be so distinct because the accommodation will modify them; they will at the same time become reversed in reference to the axis of the cylinder. With the axis horizontal the strongest meridian also becomes horizontal, and if one accommodate for this meridian the dots will be stretched in

a horizontal direction, and if for the opposite meridian they will be merged into a vertical line.

From these experiments we can appreciate the *symptoms* of astigmatism. There is usually indistinct vision, acuity being reduced in accordance with the degree of error. If spherical glasses improve it, there will not be much difference in the value of two or three nearly equal numbers. The person may say that he has noticed a difference in the distinctness of objects according to their form. A boy who required in one eye a cylinder + 6″ axis 90° and in the other + 8″ c. axis 90°, told me that he could see the telegraph wire farther than he could see the pole on which it was stretched. The masts and spars of a ship show similar differences to some persons. Some people have noticed that they found trouble in telling time when the hands of a watch were in certain positions. Such patients for the same reason find difficulty in reading certain letters. For instance, O on the card seems to be H, because with a strong vertical meridian the top and bottom are hazy and the sides black. With a reverse meridian of maximum refraction a C is imagined to be Z or cannot be made out. Dr. Little, of Philadelphia, has put into a card the letters which he calls confusion letters for astigmatics, and he has given the words FOOL and NULLIFIED, which are special stumbling blocks. In the test types such errors are to be heeded as significant. Similar to these mistakes is the difficulty which such persons have in reading Greek and Hebrew, because the characters are difficult for them to decipher. It is also characteristic that they hold books very close and their near-point is close for all kinds of work. They complain sometimes of confusion, but ignorant of the nature of their trouble and seldom analyzing their perceptions, they cannot describe exactly how objects appear, but they often complain of headache. In this respect astigmatics suffer greatly and so common is it, that an inquiry into the refraction in cases of obstinate headache has become a routine question. Dr. Weir Mitchell[1] called attention to this as a neurologist in 1874–76. It was known to oculists long before. Want of quick perception is also characteristic, and this is the necessary result of their blurred retinal images. If they have chosen glasses, especially concave glasses, they wear them often tilted forward, by which means their sight is improved. By doing this their confusion ellipses are converted into lines, and the change is favorable to vision. The degree and kind of subjective symptoms will depend much upon the peculiarities of the person, and if the temperament be nervous and excitable the reflex and attendant phenomena are sometimes extraordinary. Many papers have been written on this text and elaboration is unnecessary.

[1] American Journ. of Med. Sciences, April, 1876, p. 363.

Digitized by Google

The name astigmatism was given by Dr. Thomas Young, who carefully studied the subject and invented tests to detect and exhibit it, in 1793. If two convex cylinders be combined with their axes parallel they increase each other's power as cylinders. If they be combined with their axes transverse they neutralize each other as cylinders and compose in effect the equivalent of a spherical lens (not, however, in a mathematical sense). Such a combination gives a flatter field than a bi-spherical lens. A convex and concave cylinder of the same radius, if combined with parallel axes, neutralize each other and become the equivalent of a plate of plane glass. If they be combined with axes transverse they add to each other's power as a cylinder. Such a combination of a convex and concave cylinder has been employed under the name of Stokes' lens. When the axes cross obliquely the degree of astigmatism is between zero and the maximum of the two combined, and it increases as the obliquity passes into the transverse direction. The combination in reality is equivalent to a mixture of a spherical and a cylindrical glass in every position save when the axes are either parallel or transverse.

Cylindric and spherical lenses may be combined, so that we have concave spherico-cylindric and convex spherico-cylindric. Occasionally a bi-cylindric lens is ordered, as in some cases of conical cornea, but as a rule spherico-cylindric or plano-cylindric lenses serve the needed purpose.

Diagnosis.—We have to ascertain the fact of astigmatism, its kind, its degree, and the direction of the principal meridians. We may or may not employ a mydriatic, and we resort to both subjective and objective methods as for other kinds of refractive error. We try the acuity of vision, and prove how much may be gained by concave or convex spherical glasses. The deficit is not apt to be large, because high degrees of astigmatism are rare. We note whether the patient stumbles at certain letters such as O or F, or L or N; and if vision reach $\frac{20}{40}$ and cannot be carried beyond, a weak cylinder of 1. or 1.5 D may be put before the spherical and rotated to see if at some point vision notably improves. This would prove the presence of astigmatism. But it is better to adopt a more systematic method to elicit and analyze the error. The best tests are those of Dr. Green, of St. Louis. Upon a diagram of a clock dial he places discs traced with lines and dots of various widths and arrangements. Each disc is centred upon a pivot and can be revolved in any direction. Out of a great variety of patterns I have learned to confine myself to two or three. The space between each hour is of course 30°. Put before the patient the one denoted in Fig. 46 and give the patient the *weakest spherical concave* glass or the *strongest spherical con-*

Digitized by Illinois College of Optometry

vex glass which he will accept, and ask him to say whether he sees all the lines of the figure with equal distinctness. One must urge him to give close attention and must also increase the convex or diminish the concave glass, so as to bring out the meridian of strongest refraction. This antagonizes his accommodation. If he have astigmatism he will state that along a certain diameter the lines are more conspicuous or stand out as the only ones of the figure. There may be two or three, or there may be five or six. The fewer and more prominent the greater the astigmatism. Let him point out between what figures on the dial (hours) the lines are found. Say they run between XII. and VI. This indicates the meridian of strongest refraction with the glass. Substitute for this disc another, like Fig. 47 and set the lines in the direction which the

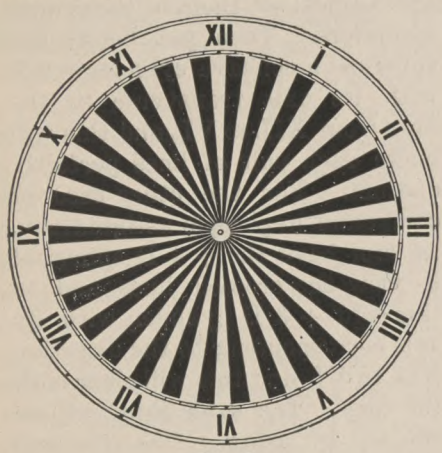

FIG. 46.

FIG. 47.

patient indicates. The lines are wide at their extremities and narrow at the centre. If the glass he wears is suited to this meridian the patient should trace the white interval almost to the centre. If he do not, move the disc lightly in either direction. If this do not separate the lines more perfectly, modify the glass a little until the lines become well defined and separated within an inch or less of the centre. This determines the glass for this meridian, and it is to be noted. Between every hour on a clock are 30 degrees, and we have found the principal meridian to be exactly upon the vertical. Now turn the disc 90° and bring the lines to run from IX. to III. They are indistinct, light in color, ill-defined, not separated and the white interspace is short or invisible. Now diminish the convex spherical or increase the concave spherical until the pair of lines are made as distinct as before.

Suppose in the direction from XII. to VI. the glass was — 3 D, and now from IX. to III. it is — 5 D. The difference between them is, —

Digitized by the Internet Archive of Optometry

2 D, and this is the astigmatism. Suppose the glass at first had been + 7 D and now we have + 4 D, the difference is + 3 D, and this is the astigmatism. In the former case it is compound myopic, in the latter case compound hyperopic. It may have been that from XII. to VI. the glass was −2 D, and when the line is reversed no glass is accepted or uncertain answers indicate that the patient is not sure—this is likely to be simple myopic astigmatism. There is great liability to think that a simple myopic astigmatism exists with the axis *horizontal* when in truth the error is simple hyperopic astigmatism with the axis *vertical*. Such a mistake is often made and the only assurance against it is in the use of atropine. We have found, we will say, −2 D astigmatism. Let the patient have −3 D spherical and give him another test card like Fig. 48 where 2 pairs of lines cross at right angles; set them in the proper diameters. Then put before the spherical a concave cylinder − 2 D with its axis transverse to the lines from XII. to VI., and this will make each pair of lines perfectly distinct. For the other case of compound hyperopic astigmatism, let him have the + 4 D spherical to view the crossed lines and to this add + 3 D cylinder with its axis corresponding to the direction XII. to VI., and this will clear both the lines. The same thing will be effected by using + 7 D spherical and to it adding − 3 D cylindric with axis *transverse* to the diameter XII. to VI. Now with the combined spherical and cylindrical glasses let the patient try the test letters. A smile lights up his face as he runs glibly over what he had painfully failed to see. There is no more satisfactory experience than to witness the success of one's efforts in a case of astigmatism.

Fig. 48.

If the examination proceed as described, the diagnosis is determined and also the glass required, but such is not always the fact. Satisfactory vision is not always easily gained, and we must multiply the tests or resort to atropia, or what is better, employ objective methods. Mr. Bowman (see Donders, p. 490) found illumination of the eye by the mirror at two feet distance with rapid variation of its inclination, sometimes lead him to the discovery of regular astigmatism.

What are the indications for the use of atropine? In myopic astigmatism, both simple and compound, it is rarely necessary. In marked compound hyperopic astigmatism it may often be dispensed

Digitized by the Internet Archive in 2010

with. In simple hyperopic astigmatism it will often be necessary, and the same remark applies to mixed astigmatism. Practically the point in a given case, is to find out to which of these classes it belongs. Javal strongly insists that to use atropine and to correct the whole error is wrong practice. I cannot fully concur in this opinion. The degree of asthenopia and the visual acuity must be taken into account. In young subjects who enjoy good accommodation and who have not complained of severe symptoms the partial correction may suffice. But the presumption is not so much in favor of this decision as in the case of simple hyperopia. One must call to his aid the objective methods, and observe what may be the difference between the results according to them and according to the subjective test. If the difference be great, I have no hesitation in using atropia to full paralysis. It is true that the correction thus obtained is likely to be too strong for the patient to accept. But at the end of a week the subjective test may again be made and a glass selected which will be satisfactory. The suspension of accommodation is, in my experience, a valuable therapeutic measure in many cases of astigmatism. The enforced rest is serviceable and they are prepared to use their eyes and their glasses with greater comfort.

There are other subjective tests which it is proper to mention. A most useful one is the letters of Dr. Pray. They are capitals composed of strokes which run in different directions for each letter. A patient points out the letter which is most black and clear, and the direction of the lines composing the letter indicates the direction of the meridians. Becker gives a set of parallel lines in triplets and placed in various meridians; also concentric circles which will exhibit a sector of distinctness contrasted with remaining indistinctness. There are many other ingenious test diagrams whose character is similar. (See one by Dr. Oliver in *Medical News*, Oct. 6, 1883, p. 373.)

Scheiner's method of determining refraction as modified by Dr. Thomson is also to be considered, and it has value in the cases which are decidedly amblyopic, whether from conicity of the cornea or slight haziness of it, or from true amblyopia. Reference has been made to it on page 81. Consideration of cases in which visual acuity can at the best be only very imperfect, will be deferred to a later page.

Objective examinations are made by inspecting the fundus by the direct method of ophthalmoscopy, by Cuignet's method or the shadow test, and by ophthalmometry. The first is most available, the second has an approximative value, the third is extremely rapid and exact so far as corneal error is concerned and would doubtless be much used if the instrument of Javal and Schiötz were not ex-

Digitized by the University of Illinois College of Optometry

pensive. To detect astigmatism by the ophthalmoscope we simply take for an object a fine vessel running in the direction of one principal meridian and choose the glass, whether plus or minus, which makes it distinct, and then take another fine vessel running in the opposite meridian and find the glass suitable for that. Great care must be taken not to let accommodation either of subject or observer interfere. The difference between the glasses gives the astigmatism. Now set a cylinder before the patient which corrects the astigmatism, placing the axis in the proper manner, and in the ophthalmoscope make up the remainder of the refractive error by turning on spherical glasses and again examine the fundus. Now there should be a perfectly clear and bright image if the media are transparent. And this contrasts strongly with what was possible when only spherical lenses were employed. (It is easy to arrange a spring clip behind the mirror to carry a cylinder from the trial box, and this is provided in my ophthalmoscope. See Fig. 21, page 45).

One can thus satisfy one's self not only of the accuracy of the refractive correction, but of the integrity of the membranes, which is very important in high degrees, both of compound myopic and of hyperopic astigmatism. If the error be high, the fundus before the suitable glass is found will have a smeared and streaky look, as if a brush of paint had been swept over it. The nerve will be pulled out into an oval form and the ends of the ellipse be fringy with the vessels drawn in the same direction; there can be no distinctness in the detail of the surface. If the error be over-corrected, the disc will be elongated slightly in the opposite direction and the lines of distortion will be reversed. Not until the cylinder is introduced will the view be satisfactory. It is also useful to employ the inverted image to corroborate the diagnosis. By it, if the nerve were by the direct method oval, with the long axis vertical, the long axis becomes now horizontal. For this phenomenon to be well seen, the objective must be not less than 3″ focus and it must be held at its own focal length distant. If nearer to the eye or farther from it, the inverted image will be less elliptical. The lens must be held exactly vertical and without any turning on its axis, else this will cause the disc to seem oval.

To distinguish between an optic disc which is oval anatomically, from one which seems oval by reason of astigmatism, one must note its edges at the extremities of the oval. If they are sharp and well-defined, the shape is anatomical; if they are blurry or fringy, astigmatism is the cause.

The shadow test (employing a concave mirror) shows astigmatism in the following way: If the shadow move up and down in the same way as the mirror and with a certain rapidity, and when

Digitized by Google

moved transversely the shadow goes in a similar way with less rapidity, this indicates myopia in both meridians, but a greater degree in the vertical. If the shadow move "against" the mirror in one meridian, and with greater rapidity than the movement "against" the mirror in another meridian, this proves hyperopic astigmatism. In other words, if in meridians at right angles to each other the reflex and shadow move in different directions or with different degrees of rapidity, there is astigmatism. A very bright reflex and a shadow difficult to detect, but nearly linear and traversing the pupil very rapidly and in a direction contrary to the motion of the mirror indicates E in that meridian. The *slower* the movement the *higher* the ametropia; the more rapid the movement the nearer to E. If there be mixed astigmatism, the shadow will in one meridian move with the mirror and in the opposite meridian against it. A motion opposite to the mirror indicates either E, H, or weak M. To decide which of these is present, set a glass + 1 D in the trial frame before the eye. If the refraction be emmetropic, this glass causes myopia and the shadow should move *with* the mirror; if such be not the fact, the eye has H; if the shadow does now move with the mirror, the patient has either E or M. A glass +.5 D will decide whether there be E or M, and a stronger + glass will give an idea of the degree of H, until a glass is found which makes the shadow go opposite the movement of the mirror. Cylindric glasses may be put before the eye as spherical usually are until the phenomena are made to resemble those of emmetropia. See paper by Dr. Ferguson.[1]

Ophthalmometry, by the instrument of Javal[2] and Schiötz, is the quickest and usually most reliable mode of examination. An experience of eight years has given me the greatest confidence in it. The model now made differs from the original figured in the text, and in my judgment is less desirable. It has a large disc with so many lines and circles as to cause confusing reflections from the cornea. A plain black disc one foot in diameter is important and sufficient. Its essential parts are as follows. (See Fig. 49.)

Two very bright objects, one a complete parallelogram and the other a parallelogram of the same dimensions, but with its long side cut away in the form of steps, p. 125, are made to slide on a curved bar and are placed before the eye so that each shall be reflected from the cornea. These reflections are viewed by a small telescope, and are doubled by passing through a Nicol's prism. Four images are in view as with a stereoscope, but the outside ones are neglected, and attention given to the two central ones. The patient's face is placed in a frame and is steadied

[1] "Retinoscopy." American Practitioner, Dec., 1882.

[2] Annales d'Oculistique, lxxxvi., July and August, 1881, p. 5; ibid., lxxxvii., May and June, 1882, p. 212; ibid., lxxxviii., July and August, 1882, p. 33.

by a chin and forehead rest. The telescope stands upon a tripod which can be moved forward and backward to get the proper focus, and has a screw adjustment for slight variations in height. When the central images are sharply seen, the step-slider is moved until its bottom step comes into exact contact with the lower part of the parallelogram (see Fig. 50). The lower edges of the reflected images are brought into a straight continuous line by turning the bar which carries the sliders and which revolves around the body of the tele-

FIG. 49.—In this instrument electric lights are used, and a disc has been added to protect the observer. In other respects it is like Javal's model of 1882.

scope. Having accomplished this, the position of the bar is read off upon an index which will place it, we will suppose, at 180°. Then the bar is turned 90° and the relations of the two images noted. If they have not changed, either by overlapping or separating, the curve of the cornea is the same both horizontally and vertically; if the images overlap in the vertical meridian, the radius of curve is in this sense shorter and there is astigmatism (see Fig. 51). If the images separate with the bar vertical, this meridian has a longer radius than the horizontal, and again there is astigmatism. Each

Digitized by Illinois College of Optometry

step in the step-slider represents 1 D, and consequently the amount of astigmatism is easily read off, and can be estimated to .25 D. By the ordinary arrangements errors of 6 D are measured, while by special adjustments much higher degrees can be determined.

The portion of the cornea inspected is a central circle 5 mm. in diameter. It is assumed that the chief seat of astigmatism is in the cornea. Javal claims that between the total astigmatism as found by trial glasses and the corneal error the difference will not be greater than 1.5 D. It would be inadmissible to permit an error so great as this, while as a matter of fact so great or any important discrepancy very seldom arises. It is chiefly found among the lower degrees of error, *i.e.*, when less than 3 D. The axis of the principal meridian is quickly determined and will vary from that found by trial glasses by only a few degrees, usually not at all. We learn nothing as to the kind of ametropia nor do we know whether the cylinder should be plus or minus. Preliminary trial has already given an idea of the quality of error, and putting the

FIG. 50.



FIG. 51.

cylinder designated into the trial frame we add plus or minus spherical glasses until the visual acuity is raised to the normal degree. Before testing by trial glasses the indicated cylinder may be put behind the ophthalmoscope and the real refractive situation be objectively ascertained, and afterward the spectacle box will soon give us the requisite combination. A good illumination is essential, and diffused surrounding light is cut off. There should be a screen at the observer's end of the telescope to shield his eyes. The whole problem may often be solved at a single sitting and without atropia. For rapid work and especially in public institutions this instrument is invaluable. For the young, the confused, the dull, the amblyopic, it is most excellent.

It is not rare to discover, as Laqueur pointed out, that the curve of the cornea is not constant. It sometimes changes as we look at it, we note the images approach or separate instead of remaining still. They exhibit these oscillations under the action of the lids, and also if the upper lid is lifted off the globe, under the action of the motor muscles. Drawing on the lids at the outer angle will increase the corneal curves greatly. Hence we have an explanation of the un-

certain findings in some cases of astigmatism, apart from spasm of accommodation. The cornea is thin and cannot resist external pressure. The same explanation will account for variation or increase of astigmatism with lapse of years: in fact, herein lies the beginning or suggestion of conical cornea. The ophthalmometer unerringly detects opacities and distortions in the form of the cornea, and thereby explains why the attainment of perfect visual acuity may be impossible. It also shows that the principal meridians are sometimes not at right angles to each other, *e. g.*, one may be at 90° and another at 160°. The axis of the cylinder accepted by the patient will usually in such a case approximate the truly vertical or horizontal position. Acuity will usually be below standard.

A simple device which roughly points out these defects in the cornea is the so-called disc of Placido, which consists of a series of concentric circles painted on a disc about 10 inches in diameter in black and white. (See Fig. 52.) It is held close to the cornea and the reflex viewed through a central hole with a lens 4″ focus. Javal has applied the same to his ophthalmometer.[1]

FIG. 52.

It has already been said that astigmatism exists in many persons who have normal visual acuity and make no complaints. Especially will this be true of the young and vigorous and sometimes with high degrees of error. Low degrees are often unrecognized until presbyopia approaches.

Moreover, if the error be hyperopic or myopic, with axis nearly horizontal, in both which cases lines nearly perpendicular are most distinctly seen, persons with notable error get on moderately well, because most objects with which we deal have greater height than breadth. Such is the case with type (Roman letters), and with trees, men, buildings, and the majority of objects. True, objects are exaggerated in height, but of this the person is unaware. But if the axis is in the contrary direction, or if it be oblique, or if the two eyes are unsymmetrical, trouble announces

[1] Annales d'Oculist., Jan., Feb., 1883, p. 5; also Landolt, English ed., p. 328.

Digitized by Illinois College of Optometry

itself early. An attack of illness, chronic uterine disease, excessive eye-work, great grief, etc., will reveal astigmatic error, previously unsuspected. I have also seen astigmatism, which severe uterine disease had brought to view, retire into obscurity and unconsciousness when by an operation the uterine lesion was cured. The glasses which the patient had with extreme reluctance consented to, were put away and satisfactory use of the eyes regained without them.

The more pronounced are the asthenopic symptoms, the more searching must be the quest for astigmatism and the more accurate its correction. Then even slight degrees, 0.5 D, must not be neglected. No fixed rule can be given about correcting the full amount of error, yet this will be done in the majority of cases. If there be no asthenopic symptoms, we need only correct the manifest error; with slight symptoms this may also be the general rule, with emphatic symptoms full correction is demanded. In young subjects, as has been said, more may be left to the accommodation than with persons above thirty. But an error more than 1 D should not, in my opinion, be permitted to remain, even in young subjects. When strong cylinders are first worn, the subject is often annoyed in growing accustomed to them, and as with high myopia may have to use them for short periods at first.

For near work it is especially necessary to have the correction, and whether the glasses be the same which are used for distance will depend on the age and refraction. For one who is becoming presbyopic an increase in refracting power may be needed. For a myope a weaker spherical concave glass may be required. The rules in this regard are easily deduced from the ordinary requirements of ametropia and presbyopia. In all cases, however, the same cylindric corrective will be demanded as for distant vision. In certain cases the glass for distance may be reversed for the near. For instance a person uses — 1.50cD with axis horizontal for distance and by presbyopia needs + 1.50s for reading. Instead of ordering + 1.50Ds ⊂ — 1.50 Dc, axis 180°, one may give + 1.50cD axis 90°, which meets the same need.

Formerly cylindric glasses were cut circular and large that errors in setting might be corrected. Such ungainly binocles belong to the time of unskilful opticians. It is wholly unnecessary to make a patient conspicuous by large and round glasses. They may be used either as spectacles or as nose glasses. Of course the former are more steady and trustworthy, but personal choice often decides this point. When used as eye-glasses they are apt to tip forward, and this makes a slight increase in the refraction in the vertical meridian. Sometimes this has to be taken into account.

Digitized by the College of Optometry

With strong cylinders patients are obliged to look straight forward through the middle of the glass. A sidewise look gives distortion and it cannot be avoided. Therefore they have a more restrained field of vision than ordinary ametropes.

It happens sometimes that astigmatics have very deficient accommodation. I have been obliged in some cases to order for near work a glass which represented the whole amount of A which was needed. This has occurred in persons whose error was not corrected until they had come to thirty-five years of age. In writing a formula for spherico-cylindric glasses the following notation is employed: say, − 3.0 s. ⊂ − 1.5 c., ax. 180°. The sign ⊂ meaning a combination of the spherical and cylindric surfaces. For mixed astigmatism we may have either a spherico-cylindric or a bi-cylindric combination, viz., for instance: 1.0 s. ⊂ +2.5 c., ax. 180°, which can also be expressed by − 1.0 c., ax. 90° ⊂ + 1.5 c., ax. 180°. The combination of cylinders of opposite qualities with axes at right angles gives a wider and flatter field than belongs to spherico-cylindric glasses. Hence such an arrangement is to be preferred in considerable degrees of error. Slight degrees of mixed astigmatism are not rare.

The above notation was suggested by Donders and is considerably used—nevertheless a printed form is to be preferred in which each kind of glass has a line for itself, as for example:

O. D. Spherical + 3 D.
Cylindrical + 2.5 D, axis 180°
Prism. base

O. S. Spherical + 2.5 D.
Cylindrical + 2.0 D, axis 170°
Prism. base

Space is given for inserting the use of a prism. The opticians print such blanks, and often a semicircle is added, laid out in degrees to assure accuracy. The inter-pupillary distance, and sometimes notes as to the height of the bridge and other details are provided for. These points are not too trivial for the oculist's attention, although he may place reliance on the skill and carefulness of his optician.

Anisometropia.

We are in the habit of examining each eye separately and choosing the glass which each requires. We meet cases of inequality of the eyes, and when a difference of 1 D exists, the name anisometry is employed. Differences far higher are met with. As, for example, with monocular aphakia and in myopia one eye may exceed the

Digitized by Illinois College of Optometry

other by many dioptries. I have records of many such cases. It can also happen that the eyes may have opposite kinds of refraction, viz.: one be hyperopic and the other be myopic; or E in one and H or M in the other. This I have called antimetropia.[1] The behavior of dissimilar eyes may be of three kinds: they may combine in binocular vision; one may be used for distance and the other for the near, or one only may always be used. If they combine in binocular vision; this may be true for distance and not for the near point. It is remarkable how great differences can sometimes be comfortably harmonized. With a difference, say of 3 D, there is necessarily a combination of one sharp and one very blurry image in the mental act. Yet, that this is possible in much higher differences, I have seen in persons who had binocular sight, after one eye had been operated on for cataract and the other was normal.

We meet with peculiar idiosyncrasies on this point and only general suggestions, not absolute rules, can be offered. If in myopia there be anisometropia of 3 D and vision in each eye good, usually each may take its own correction, and this difference is to be maintained both for near and far. For the near, a working point is to be chosen which will correspond to the capacity of the muscles in convergence, and the effort will be to carry it as far away as may be acceptable. One must also bear in mind the power of accommodation and by a simple calculation founded upon these two factors the correct working point can be chosen, and the glasses fitted accordingly. Testing the muscular power at six meters when ametropia is corrected and then again for the near will often explain the asthenopia which such persons suffer. It is difficult to give rules to apply to the great variety of cases which are possible, but as the practical difficulties arise at the working distance, it is here that special attention must be given. For instance, a lady who in one eye had E, and in the other M 3 D was made perfectly comfortable by using a plane glass on one eye and — 3 D on the other. She wore the glasses constantly for some weeks until she became accustomed to them and afterward she needed them only in reading. Yet, for distance she appreciated the better vision which they conferred. She was about thirty years of age and could easily bring into play the required accommodation. In other cases for the more erroneous eye an incomplete correction must be chosen, because the difference is otherwise too great in the size of the respective images. It can also happen that for the near-point one eye may need a weak convex and the other a concave glass; this is not, however, very common. It is usually unavailing to try to usurp the function of accommodation unless the person is beyond middle life. The degree of accommodative effort to be allowed to the individual is a matter for the exercise of judgment.

[1] Report of 5th Internat. Ophth. Congress, p. 165, 1877.

Digitized by Internet Archive in 2010

In hypermetropia similar problems present themselves, but not so often do we have large differences in refraction with nearly equal visual acuity, as in myopia. More often do we have great difference in acuity as well as in refraction, and then there is seldom a strong impulse to binocular vision; out of such cases a large contingent of converging strabismus is derived.

It is frequent for one eye to have, and the other to be free from astigmatism. If vision be thereby impaired in one eye or if asthenopic symptoms exist, each eye will require its own correction. It is not seldom to find astigmatism different in the respective eyes and a difference in direction of meridians is very common. Sometimes a strain is experienced in combining the eyes and such modifications may be needed in the axes of the glasses as the comfort of the patient requires. For the patients who have binocular vision for distance and monocular for near, usually exhibiting diverging strabismus in the act of reading, the rule of conduct will be derived from the acuity of the eyes, the degree of divergence, the age, sex and muscular conditions. If we are asked to relieve pain, the method will be to carry the working point farther away by concave glasses adapted to the desired distance, and if this do not suffice, prisms can sometimes be used, or more frequently tenotomy of the muscles can be employed.

For patients who use one eye for distance and the other for near, there being extreme difference between them, it is best usually to do nothing. It is not likely that they can acquire binocular vision. It is not rare to meet with such persons, and in some instances the optical difference is not extreme, but there may be an impairment in one or more muscles, or one eye may be astigmatic and the other not. The want of binocular vision is the important circumstance and underlying this is often not only an optical hindrance but a cerebral inaptitude. I have sometimes spent a long time in vainly trying to elicit from such persons evidence of binocular vision, when each eye had adequate acuity and apparently each was capable of fixation upon the desired point. Evidently the images fall upon parts of the retina very nearly correspondent, but there was no cerebral impulse to binocular vision. For such cases usually only one eye is to be corrected.

For the class of patients whose ocular discrepancies are so great that they always use only one eye, nothing is to be done save to aid as perfectly as possible the working member in case it needs assistance. The other is to be left to purely ornamental functions.

Digitized by Illinois College of Optometry

Incidental Effects of Glasses.

It has been previously remarked that glasses worn at the anterior focal distance (13 mm. in front of the eye) do not alter the visual angle. But nevertheless the linear dimensions of the image are greater with a convex glass, and less with a concave glass. Moreover, if a convex glass be held farther from the eye its magnifying power is augmented. This is true of distant objects and also obtains for near objects, provided the eye is adapted to a point whose distance is greater than double the focal length of the glass. (Landolt, l. c., p. 358.) Dropping the glass to the tip of the nose, provided the glass be moderately strong, increases its power. Removing concave glasses from the eye diminishes their power. Convex glasses limit the range of accommodation—concave glasses increase it. The estimation of distances is changed. Convex glasses make objects seem nearer and they alter the sense of relief or perspective. Concave glasses make objects seem more remote. For these reasons persons are often made dizzy on first wearing glasses or on taking them off. They have difficulty in walking or in reaching objects. With very strong convex glasses the field of vision is limited and there is a zone which is determined by the diameter of the glass, where absolutely nothing can be seen (Berlin). This constitutes one of the sources of annoyance to patients wearing cataract glasses. Looking obliquely through strong glasses and especially if they be cylindric, gives distorted images—hence persons wearing them always turn their heads to see an object. Glasses always disturb the relations between convergence and accommodation. When first used for presbyopia, the previous coincidence between these functions in reading gives place to diminished accommodation with unabated convergence, and the stronger the glasses the greater the disharmony. A myope who uses his distance glasses for reading brings accommodation into unwonted activity with diminished convergence. These perturbations require time for adjustment, and while as a rule, discomfort soon ceases, sometimes it continues until special adjustments are made, which will be considered under the head of asthenopia.

Digitized by Illinois College of Optometry

CHAPTER VIII.

BINOCULAR VISION AND ITS DISTURBANCES.

UNDER this head are to be considered such troubles as muscular asthenopia, or insufficiencies of muscles, strabismus, paralysis of muscles, nystagmus, and conjugate deviation. Preliminarily it will be proper to consider the anatomy and physiology of the muscles, and the physiological properties of binocular vision.

Anatomy and Physiology of the Ocular Muscles.—Each eye has six muscles. They are combined in pairs, and both eyes are co-ordinated in particular ways. In each eye we have the internal and external, the superior and inferior recti, and the superior and inferior obliqui. All the recti muscles take origin from the apex of the orbit around the foramen opticum, and come forward to be inserted into the sclera in front of the equator oculi, about 7 mm. behind the rim of the cornea, by flat and ribbon-like tendons. The superior oblique or trochlearis also originates at this place; but, inasmuch as it passes over a pulley at the supero-internal angle of the front of the orbit, this becomes its functional place of origin and assimilates its action to that of the inferior oblique, which arises from the inner part of the inferior edge of the front of the orbit. Both muscles then pass obliquely outward and backward to wrap around the globe in thin, fan-like tendons, the superior going over the upper part of the globe beneath the superior rectus, and the inferior going over the inferior part of the globe beneath the inferior rectus. The two obliqui hold the globe, as it were, in a sling, which is entirely to the outer side of the optic nerve. The recti, combined in action, retract the globe into the orbit; the obliqui, combined in acton, draw it forward. While the recti in combination have a simple kind of action, the obliqui draw the globe forward and turn the cornea outward. The rectus internus (called by Merkel, rectus medialis) and the rectus externus, move the globe about an axis which is vertical. The rectus superior and the rectus inferior move it about an axis which is transverse to the vertical plane, but which is also inclined so that its outer end is more posterior, making an angle of 67° with the antero-posterior axis of the globe. The axis about which the obliqui rotate the globe passes from before backward and inward on a horizontal

Digitized by the Internet Archive

plane at 35° with the antero-posterior axis of the globe (see Fig. 53). The obliqui thus acquire an action which moves the eyeball so that the rim of the cornea turns like a wheel. Taken singly, the muscles act as follows: the rectus internus turns the cornea inward on the horizontal plane; the rectus externus turns the cornea outward on the horizontal plane; the rectus superior turns the cornea upward and slightly inward; the rectus inferior turns the cornea downward and slightly inward; the obliquus superior turns the cornea downward and outward, and rotates it from above downward. The obliquus inferior turns the cornea upward and

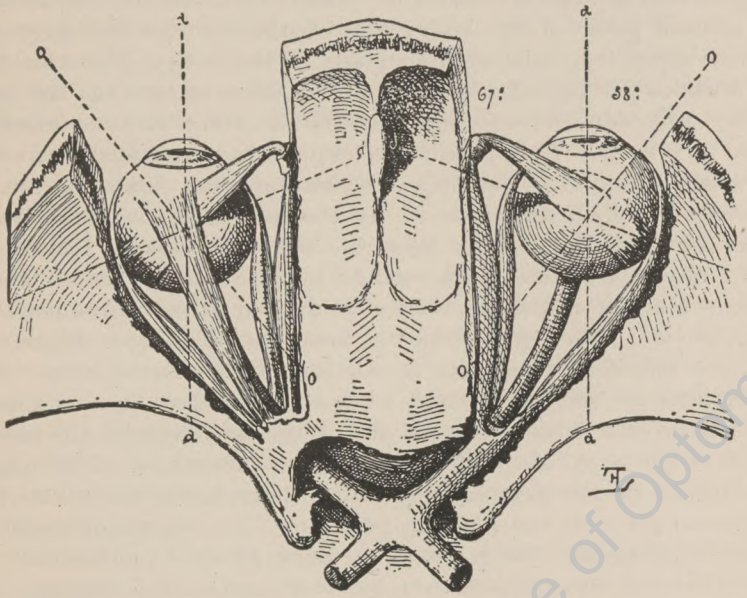

FIG. 53.

outward, and rotates it from below upward. In effecting the movements of the eyeball all the muscles co-operate: while some predominate, the rest antagonize them to give steadiness to the action.

The *nerves* for the muscles are the sixth or abducens for the rectus externus, the fourth or trochlearis for the superior oblique, and all the rest are supplied by the oculo-motor or third. The blood-vessels are branches of the ophthalmic.

The following schedule indicates how the muscles co-operate in effecting certain principal movements. For *motion inward, i.e.*, adduction, the effective muscles are, R. interni and R. sup. and R. inf., antagonized by R. externi and Obl. sup. and Obl. inf.

Motion Outward.—Abductors: R. externi, Obliq. sup., and Obliq. inf., antagonized by R. int., R. sup., and R. inf.

Digitized by the Ohio College of Optometry

Motion Upward.—R. sup., Obl. inf., and when the cornea passes a given point, the upper fibres of R. int. and R. ext. add to the effect. The antagonists are R. inf. and Obl. sup.

Motion Downward.—R. inf. and Obl. sup., while, when the cornea gets below a given point, the lower fibres of R. int. and R. ext. come into play. In motions upon a horizontal axis the R. sup. and inf. incline the top of the vertical meridian respectively inward and outward, which tendency is counterbalanced by the Obl. inferior acting with the R. sup. and by the Obl. sup. acting with the R. inf., which perform the needful rotatory or wheel movement.

Taking, now, the concomitant action of the eyes, we arrange the muscles into groups of *adductors*, which turn the corneæ toward the median plane of the body; and of *abductors*, which turn the corneæ away from the median plane of the body. We also find the muscles pairing off in other combinations in turning the eyes to the right side and left side respectively, and in the various diagonal directions. The eyeballs are capable of accomplishing, within a limited range, all possible combinations, but there are certain restrictions which are imposed by the necessity that each must direct its visual line exactly upon the object observed. Hence, for a near object, whether on the median plane or away from it, there must be a slight adduction, as well as an aim suited to the position of the object. For remote objects there will be a degree of abduction, but never to transcend parallelism of the visual lines. We are habitually more concerned with objects below the horizontal plane than with those above it; and in the discussion of the movements of the eyes, Meissner has taken an inclination of 15° below the horizon as the primary position; others, however, assume the horizontal plane as the primary position. The degree of mobility of the emmetropic eye in young persons about a vertical axis is from 42° to 51° inward, and from 44° to 49° outward (Donders). In myopia this is much restricted.

The *horopter* is a line which represents the curve along which both eyes can join in sight, and it is formed in this way: as the eyes fix upon a given object far to the left side, and move far to the right at the same inclination of the visual lines, they form a triangle whose apex, as it passes from left to right, forms the horopter curve for this plane. If the movement be in any other plane, vertical or oblique, the horopter will be formed in the same way for that plane. In its simplest form, as explained by Johannes Mueller, it is a circle which passes through the centres of rotation of each eye and through the apex of the point of fixation of the visual lines. This statement is not strictly correct, but will suffice for our purposes.

Physiology.—The fundamental and imperative law which gov-

Digitized by Illinois College of Optometry

erns the muscles of the eyeballs is that the fovea centralis retinæ of each eye must be fixed upon the object observed. When this is done, all objects lying in the same horopter will form images upon the respective retinæ which will lie at equal distances from the foveæ, and will, therefore, be appreciated as single, giving what is called binocular vision. But objects beyond the horopter or inside the horopter, will cast images on parts of the retinæ not equally distant from the foveæ, and will therefore not be appreciated as single, but create the impression of two objects, giving rise to double vision. The maintenance of correct binocular vision is the necessity which dominates the ocular muscles. If the back of the eyeballs be divided into quadrants by vertical and horizontal planes whose intersection shall be at the fovea centralis, and parallel to these lines we mark points one-tenth of a millimetre asunder, and then suppose the two retinæ to be superimposed upon each other so that the vertical and horizontal lines shall exactly coincide, the points which we have imagined will of course also coincide. These coincident points, which are equidistant from the centre, are spoken of as correspondent points of the two retinæ, and there are of course as many of them as there are percipient points, *i.e.*, bacilli in the two retinæ. They are functionally homologated together according to the scheme just imagined. By virtue of this arrangement binocular vision is rendered possible. It follows, of course, that the nasal half of the left retina is linked with the temporal half of the right retina; the nasal half of the right retina with the temporal half of the left retina; the superior halves of both retinæ are linked together, and the same is true of the inferior halves. This corresponds with the decussation of the optic tracts in the chiasm.

Binocular vision is primarily conditioned by the supremacy in acuteness of the fovea centralis above other parts of the retina. But this condition is not the only factor in the function, because experience shows that the brain must possess a certain competency, which sometimes seems to be the quality deficient.

For all objects on which we do not fix the foveæ, and which consequently are not in the horopter, we have diplopia. If, for instance, in one hand a pin is held at sixteen inches, and in the other another is held at eight inches, and upon the same line, when we look at the distant pin the nearer is seen double, and *vice versa*. We are not disturbed by double vision of objects on which we are not fixing attention; the mind ignores the impression of the things with which it does not concern itself. This is common experience in shooting, in using the microscope, when the unused eye may be wide open and nothing be known of what it sees. Diplopia follows certain laws. For instance, if the left eye fix on an object and the

Digitized by the Internet Archive of Ophthalmology

axis of the right cross that of the other at a point inside the object —in other words, if there be excessive convergence, the image which in the left falls in the fovea, and whose position in space is projected along the visual line, will in the right eye fall to the inner side of its fovea. Now, the position of the object in space is decided by what the left eye sees, and the right eye has an image which, if it were directed aright, would belong to an object situated to the outer side of its visual line, viz., on its right-hand side. This image is recognized, and is mentally located as if it were on the right side of the object seen by the left eye. In other words, if there be excessive convergence of the visual lines, there

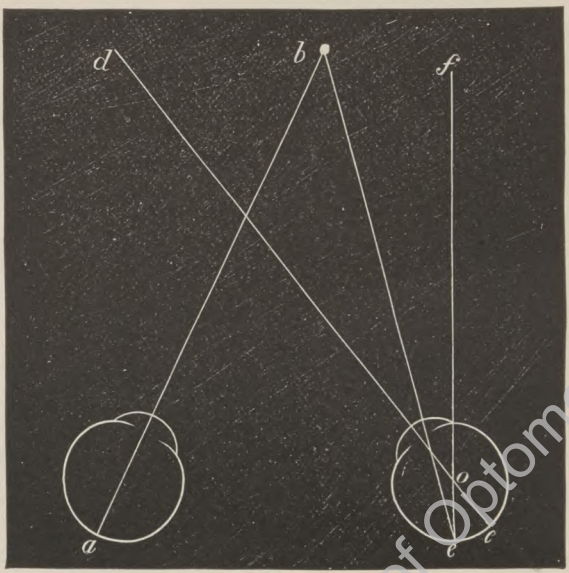

FIG. 54.—Convergence with Homonymous Images.

will be diplopia with correspondent or homonymous images (see Fig. 54).

If, now, while the left eye fixes an object, the visual line of the right diverge, the image will, in the latter, fall to the outer side of its fovea, and will be projected mentally as coming from an object on the left side of the visual axis. Hence, for divergence of the visual axes we have crossed or heteronymous double images (see Fig. 55). If the left eye fix an object, and the right eye be directed downward, the image in the right will fall below its fovea, and be mentally projected above the image seen by the other eye. If the left eye fix and the right eye be turned upward, the image will fall above its fovea, and the projection of the image will be downward below the true place of the object. A candle-flame is usually the

Digitized by the Illinois College of Optometry

object chosen, and a red glass is put before the fixing eye so as readily to distinguish the presence and place of double images. If the visual lines form a wide angle with each other, in the deviating eye the image will fall at a great distance from the fovea, and the result will be that the image is less distinctly perceived because it impinges on a less sensitive part of the retina, and it will also be projected to a greater distance from the true place of the object. For these two reasons, the patient is then less likely to be aware of double images. It also happens that persons may fix with either eye and ignore the image of the other. It is also true that in many persons, and by some it is asserted that in all persons, one eye pre-

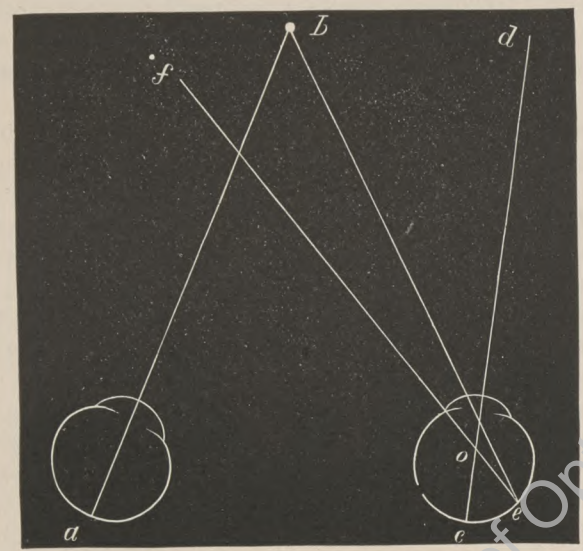

FIG. 55.—Divergence with Crossed (Heteronymous) Images.

vails over the other, just as one hand is more depended on, than the other.

The possession of two eyes confers a quality of sight which is not only more effective than with one only, but is also of a different kind. With two eyes not only does the brain receive a double impression, but each eye views an object from a different point and receives a slightly different image. The interpupillary distance varies in adults between 50 and 75 mm. The average may be taken at 64 mm. If an object be within a moderate distance and of suitable size, say a cube a foot square, at 10 feet each eye sees it under a different perspective, and while its form is evident to each alone, the combination of the two images gives what is called the sense of relief or depth. For moderate distance, viz., with the objects on a table, we realize this impression very strongly and unconsciously

Digitized by the New England College of Optometry

form our judgment of the solidity of objects by the dissimilarity of the images portrayed on the respective retinæ. We are also aided in this judgment by the projection of objects against parts behind them, and by running the eye along their outlines and from one object to another. The movements which the eyes make are regulated with extreme nicety and are capable of very fine adjustments.

The acquisition of binocular vision belongs to the first months of life. Young infants roll their eyes about in the most inconsequential fashion, and when their visual vagaries give place to binocular fixation, an important step has been gained in ocular and cerebral development. In some subjects this function is never acquired, in others it may be lost after having been presumably acquired. All cases of permanent strabismus are instances of suppressed, or of lost, or of undeveloped binocular vision.

The limitations of binocular vision evidently exclude those motions by which the visual lines are not directed in proper harmony with each other. That is, one eye may not look up and the other at the same time look down, and the same is true of diagonal movements—they must be harmonious. But in the horizontal, or nearly horizontal plane, the motions of adduction and abduction can be pushed to an extent which shall disharmonize the visual lines. Thus, we may turn the eyes inward so that the visual lines cross by excessive convergence, and we may turn them by abduction so that they fall into divergence. Excessive adduction is possible without artificial aid to a marked degree, excessive abduction is never great, and cannot usually be effected without the aid of prisms. Done by their help, the movement is made to prevent double sight. Thus, if we look at a candle-flame twenty feet away, and put before one eye a prism of five degrees angle, with its base inward, there will for a moment seem to be two candles, but presently they move toward each other and fuse into one. The eyeballs go asunder by a movement of abduction to bring the fovea of one eye inward to the spot on which the prism has deflected the candle-flame. This power of abduction beyond parallelism reaches to a prism of from six degrees to eight degrees in most persons, while adduction for distant objects, say at twenty feet, extends to thirty degrees or to fifty degrees, and by cultivation may go higher.

It has already been mentioned (page 19) that with different angles of convergence there will be variations in the possible amount of accommodation, and this is known as the relative accommodation. It is determined by employing convex and concave spherical glasses for particular angles of convergence. We also have for given amounts of accommodation variable degrees of convergence possible, as can be shown by prisms placed with bases

Digitized by Microsoft Corporation

inward or outward. In emmetropia the relation of the functions of accommodation and convergence is very different from what we find in myopia and in hyperopia. In myopia with less accommodation, convergence is greater, in hyperopia with more accommodation, convergence is less. We also find great differences among individuals both by natural endowment and from disturbing causes. Not only is an adequate amount of accommodative power essential to comfort in near work, but equally so is a proper proportion of adductive and abductive power. In fact, for all visual functions a correctly adjusted and adequate muscular apparatus is indispensable to comfort and efficiency. We do not yet possess sufficient data to state precisely the necessary physiological conditions in the power of the muscles, but failure in this respect brings on serious functional troubles, which are classed under the name of *asthenopia* and under this head we shall discuss the matter.

PARALYSIS OF MUSCLES.

We may have paralysis, either complete or incomplete (paresis), affecting one muscle or many, in one eye or in both. Symptoms are:

1st. Limitation or irregularity of motion:

2d. False position of the visual axis causing squint when motions in certain directions are attempted. The squint affects at first only one eye, but soon extends to both, by secondary contraction of opposing or associated muscles. For example, if the left rectus externus be paralyzed, not only will the left rectus internus, by reason of the diminished resistance, turn the eye unduly inward, but the rectus internus of the right (opposite) eye will undergo contraction, and if the left eye look straight forward, the right eye will squint inward. This is because the right rectus internus is associated, in all movements to the left, with the left rectus externus. Moreover the secondary deviation will exceed the primary; *i. e.*, if the right eye fix on the finger at one foot, the turning inward of the left will be less in angle, than will be that of the right when the left fixes on the finger. In other words, contraction of the right internus exceeds that of the left internus.

3d. Double Images.—This is the usual consequence of disturbance of the pre-existing normal co-ordination. In partial paralysis some persons have a singular capacity for correcting the diplopia. This power depends upon the instinct for binocular vision, and is called the capacity for fusion. With the same degree of deviation, so far as can be estimated by prisms, the extent over which fusion of double images is achieved will be much greater in some persons than in others. Von Graefe pointed out that, apart from errors of refraction or accommodation, or amblyopia, the capacity for fusion

Digitized by Internet Archive

is far less in cerebral paralysis than in orbital or basilar paralysis. The reason is that binocular vision is essentially a cerebral function.

4th. Incorrect projection of the field of vision.—Because of our habitual reliance on the muscular sense we suppose that the effort we make is followed by the effect to which we are accustomed, but find that our assumption of the position of objects in the field of vision is wrong. For instance, if the left rectus externus is paralyzed, especially if only partially paralyzed, and the left eye attempt to see an object to the left side, the effort of movement is so much greater than is usually made, that the mind believes the object to lie much farther to the left than it really does, and the hand, in attempting to seize an object or to put the finger on the point of a pencil, strikes to the left side of the true position, *i.e.*, the projection of the field is too far on the side of the action of the muscle.

5th. Dizziness, nausea, and such cerebral symptoms are often present, and may after a time pass away. They are caused by the confusion of images and by the dissociation which is produced between the conscious effort of the muscles and the instability and falsity of the projected field. Objects are made unsteady, the ground does not seem level, going up and down stairs becomes difficult, movements of the hands are ill directed, and from all these phenomena mental confusion and vertigo result, until further experience corrects the judgment.

If one eye only be involved, the inclination is to close it.

6th. Another effect is a peculiar attitude which the head assumes to obviate double images. The inclination of the head, when this occurs, will be such as to favor the lamed muscle, and will be in its line of action and toward its virtual or anatomical origin. For a paralyzed rectus externus of the left eye, the head will turn on a vertical axis to the left. For a paralyzed rectus superior of the left eye, the head will turn on a horizontal axis upward and a little to the right. For the obliquus inferior the tendency will be the same, both being levators of the cornea, and the head thrown back diminishes the effort in looking upward. Sometimes *pain* is a prominent symptom and very often it is absent.

Diagnosis.—We meet in practice with the most complex combinations, and sometimes it is indeed a puzzle to tell what muscles are at fault. We place most reliance on the character and position of the double images, but to a clear analysis it is necessary to have an intelligent patient with two good eyes each of which shall be quick to observe the image it receives. To complicate the problem, secondary contractions and involuntary compensations by other muscles, may come in to disturb the regular scheme which ought theoretically to be observed in the behavior of the double images, and we are left in the lurch. But in many recent cases we can tell,

Digitized by Illinois College of Optometry

without analysis of double images, what muscle is affected. The eye refuses to move to the proper degree in the direction of the movement of the impaired muscle, and goes too far to the opposite side; its movements are often partial and jerky. If many muscles are paralyzed, the situation of the globe in the orbit may be altered, *i.e.*, exophthalmus may occur.

To comprehend the value of double images for diagnosis of ocular paralysis, a few illustrations are employed, which are borrowed from Zehender ("Handbuch der Augenheilkunde," 1874, p. 317) and somewhat modified. It has already been stated that two images on the same level, of which the right belongs to the right eye and the left to the left eye, are called homonymous or correspondent. Images on the same level, and of which the right belongs to the left eye and the left to the right eye, are called crossed or heteronymous. The former implies impaired power of abduction, *i.e.*, the eyes are convergent; and the latter implies impaired power of adduction, that is, the axes are divergent. We have also to study differences in height, *i.e.*, vertical diplopia; and the higher image belongs, as before said, to the eye which points too low, and means impaired power of lifting the cornea, *i.e.*, the levators are at fault. The lower image belongs to the other eye. Again, we are to note whether the images are parallel to each other, and for this we use as a test a long candle or a stick about a foot long. The images may converge or diverge at the top. The cause will lie in deflections of the vertical meridians. We always speak only of the top of the vertical meridian. If now these meridians diverge, the images will incline inward; if they converge, the images will diverge. The obliqui are thus submitted to proof, while to a less degree the same phenomena belong to the recti superiores and recti inferiores.

The images are figured as they are seen by the patient. The white candle denotes the image seen by the sound eye, the dark candle that seen by the paralyzed eye. (In practice it is better to put a red glass over the eye which fixes, and which is generally the sound eye, so that the image seen indirectly and by the paralyzed eye may be relatively more distinct. This suggestion is not observed in the diagrams.) It is supposed that the candle is carried to the several positions represented across the field and the shaded part of the diagram indicates the region in which double images arise—viz., right or left, above or below.

Fig. 56 shows the double images in, 1st, paralysis of the rectus externus oculi sinistri, and likewise those in, 2d, paralysis of the rectus internus oculi dextri—the one being the counterpart of the other, except that in the former the images are homonymous, in the latter they are crossed. If the same figure were looked at

through the paper from its back side, or were looked at as reflected from a mirror, it would be reversed, and then would represent, as seen in Fig. 57, 3d, paralysis of the rectus externus oculi dextri, or 4th, paralysis of the rectus internus oculi sinistri. In the third case the images are homonymous; in the fourth, they are crossed. The images viewed on the horizon are vertical and parallel, while

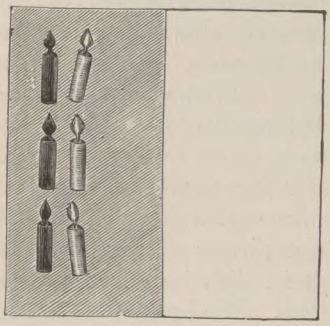

FIG. 56.



FIG. 57.

the eyes turned up cause them to diverge at the top, and, if turned down, to converge at the top to a slight and physiological degree. In looking upward the rectus superior predominates and causes the vertical meridian to converge—hence, divergence of the images; and vice versa, in looking down, the action of the rectus inferior causes the images to converge.

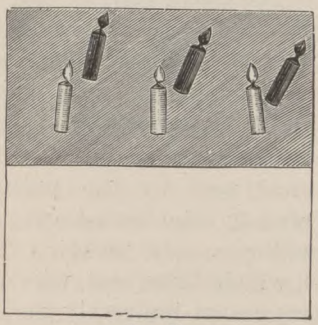

FIG. 58.



FIG. 59.

Fig. 58 gives the situation and relation of the images in, 5th, paralysis of the rectus superior oculi sinistri, and its reverse in Fig. 59 exhibits, 6th, paralysis of the rectus superior oculi dextri. It is noticed that difference in height (Fig. 58) increases toward the left, and obliquity increases toward the right, the reverse occurring in Fig. 59. In both cases the images are crossed.

In Fig. 60 we have the images seen in 7th, paralysis of the rectus inferior oculi sinistri, and reversed in Fig. 61 of, 8th, paralysis of rectus inferior oculi dextri.

Digitized by Illinois College of Optometry

In this figure again the images are crossed, and they diverge more widely toward the side of the affected muscle, and the obliquity diminishes toward the same side. The figures give the diplopia only in the extreme upper and lower parts of the field, where the difference in height is greatest; on the median line it will be less, and at the opposite part of the field there will be single vision.



FIG. 60.

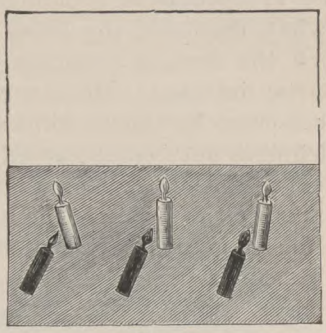

FIG. 61.

In Fig. 62 are represented the double images found in, 9th, paralysis of the obliquus superior oculi sinistri, where they are homonymous; and if reversed, as in Fig. 63, we have, 10th, paralysis of obliquus superior oculi dextri.

In these cases the notable thing is that, besides being homonymous, there is difference in height and remarkable obliquity.

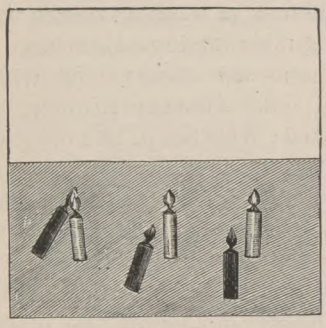

FIG. 62.



FIG. 63.

The vertical separation increases on the side of the sound eye, while the obliquity increases on the side of the impaired eye. Paralysis of the inferior oblique, which is rare, gives double images in the *upper* part of the field, and with difference in height as well as lateral displacement, the images being crossed, which is the fact in the case of the writer who has this affection, but by most authorities they are called homonymous (see Trans. Am. Oph. Soc., 1879, p. 551) and diverging at the top.

Digitized by Illinois College of Optometry

Not infrequently one image seems to be farther removed than the other. To aid a patient in describing what he sees, it will be well to let him have a stick in each hand, and with them to imitate the position of the images. To determine which is the true and which is the false image is generally easy, because the patient will naturally fix with the sound eye. We shall also be guided by other symptoms in deciding upon the faulty eye. By observing in what direction the least displacement occurs and the line in which the images separate most widely, the erroneous eye will soon be detected. Moreover, while a patient fixes on an object, if the screen be quickly shifted from one eye to the other, the eye which does not remain steady, but makes a slight movement of adjustment, is the affected one. Patients can by their own sensations often tell which is the injured eye.

For isolated paralyses and for some cases of multiple paralysis there will be no great difficulty in deciding which are the faulty muscles. When all the twigs of the third nerve are thrown out of function, we readily recognize it, because only the rectus externus and superior oblique remain intact, and the pupil is moderately dilated and there is ptosis. There will often be slight exophthalmus. We also sometimes have all the muscles of one eye paralyzed, and it then stands immovably at the middle of the orbit and the upper lid drops, while the globe has a tendency to exophthalmus. We also have various combinations which are sometimes impossible to unravel, and compensatory effects are sometimes added to the original complications. The above schemes of double images will often fail to be realized and are simply guides for investigation.

Having discussed the ocular phenomena and ascertained what muscles are at fault, we are confronted with another problem in diagnosis, viz., where the lesion is situated: whether in the orbit or within the cranium. The sphenoidal fissure is a favorite site of paralytic lesions. This opening, closed by a dense fibrous membrane, is chiefly occupied by the cavernous sinus, on whose wall at its medial side is a fibrous canal by which the nerves enter in a bundle, viz., the three motor and the ophthalmic branch of the trigeminus, while the ophthalmic vein passes out below the oculomotorius. An intra-cranial lesion may affect the nerves at the base of the skull, or within the cerebrum. We find the trunks as they enter the brain subdivided into fasciculi or rootlets, which terminate in nuclei located in the mid-brain, and from these nuclei connecting fibres proceed to the cortex. We thus subdivide intracranial paralyses into, 1, basal; 2, fascicular; 3, nuclear; 4, subcortical; and 5, cortical. We must have a critical knowledge of anatomy to be qualified to understand or investigate the intricate problems of pathology which now challenge our study.

Digitized by Illinois College of Optometry

Leaving the sphenoidal fissure, the motor nerves pass backward alongside the sella turcica, and we find them ranged in the following order from the median line outward: The 3d, the 4th, the 6th, and to the outside, the trunk of the 5th, with the ganglion of Gasser lying on the anterior face of the *pars petrosa.*

It would be unsuitable to enter deeply into details in a treatise on ophthalmology, but we want at least an approximate knowledge of the place of the lesion if it be located within the cranium. We therefore present the following anatomical summary—relying largely on illustrations.

A transverse section through the frontal bone just behind the apices of the orbits discloses an instructive view of the cranial cavity, as seen in Fig. 64 from Henle. It gives a section of the cavernous sinuses and of the internal carotid arteries; the tentorium being preserved, we are reminded of the importance of the dura mater, both in supporting the occipital lobes, in determining the cause of exudations and abscesses, and also its influence, when inflamed, upon the nerves and brain tissue because of its large enveloping surface and penetrating septa. We see also the large cerebral sinuses. Another important elementary fact of which we may be reminded is the arterial supply of the base of the brain. The vertebrals unite at the posterior edge of the pons to form the basilar artery, and this bifurcates upon the crura cerebri (peduncles) to enclose within the circle of Willis the corpora albicantia (mammillaria) and the optic chiasm, alongside of which come up the internal carotids after their sinuous twisting; and in front of the chiasm the circle of Willis is completed by the anterior communicating artery.

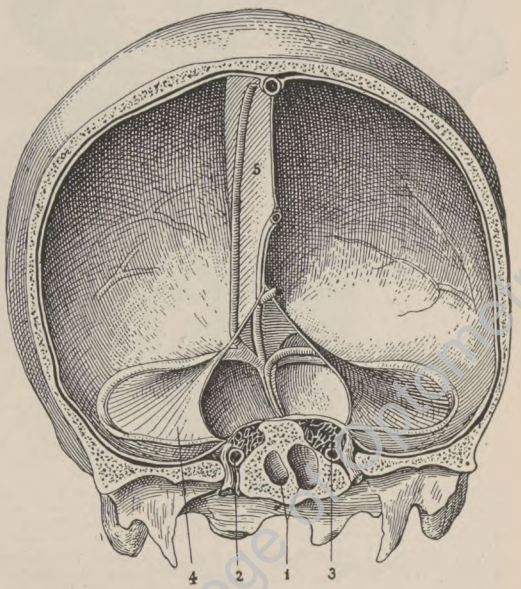

FIG. 64.—1, Sphenoid sinuses; 2, internal carotid artery; 3, inferior maxillary nerve; 4, tentorium cerebelli; 5, falx cerebri.

Leaving out of view the hemispheres we limit our study chiefly to the parts about and caudad the third ventricle. A ventral view (see Fig. 65) displays the cranial nerves and the various organs along the median line as far as the decussation of the pyramids. It will be remembered that the pons Varolii lies upon the basilar process and that along its median line is a furrow for the basilar artery. Fig. 66, from which parts have been excised, may be placed alongside Fig. 65 to complete the mental picture. We may simply call attention to the optic tracts which part from each other at the chiasm and pass laterally and caudad to twine around the crura cerebri and lose themselves in the brain substance. We note the two geniculate bodies *i*

Digitized by Illinois College of Optometry

and *e*, of which only the external (lateral) has any connection with vision (Fig. 65). At the heel of the optic thalamus, *Th*, is a nidus of gray matter called the pulvinar (Fig. 66), which, like its neighbor the external geniculate body, is a primary visual ganglion. The cross × between the crura (Fig. 65) denotes the posterior perforated space, a lamina of gray matter pierced by small arteries, which is the floor of the third ventricle.

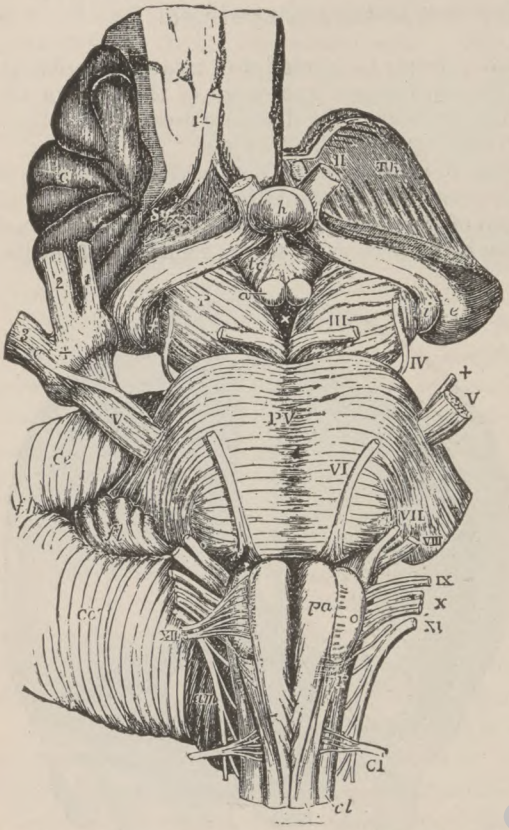

FIG. 65.—Base of the Brain and Cranial Nerves, Pons and Medulla. I to XII, The cranial nerves; *Th*, optic thalamus; *h*, pituitary body; *tc*, tuber cinereum; *a*, corpora albicantia (mammillaria); *P*, pes pedunculi; *i*, internal geniculate body; *e*, external geniculate body; *PV*, pons Varolii; *pa*, anterior pyramid of medulla; *o*, olive; *d*, decussation of anterior pyramids; *ca*, anterior column of spinal cord; *cl*, lateral column of spinal cord; *Ce*, cerebellum; *fl*, flocculus of cerebellum; ×, locus perforatus posticus; + (on the left side), ganglion of Gasser; + (on the right side), motor root of trigeminus.

In Fig. 67 from Henle, we have an alcoholic specimen, showing the third ventricle and the beginning of the crura: the section is presented a little obliquely and the tractus opticus II' is turned aside. The crus cerebri appears near the optic thalamus and is cut off just above the pons. In the crus we distinguish the ventral portion B, basis or crusta, and the dorsal portion T or tegmentum. Between is a thin ganglionic layer, *Sn*, the substantia nigra, or ganglion of Soemmering. In the basis of the crus are gathered the fibres forming the internal capsule which have come down from the cortex, and which are chiefly motor. In the tegmentum the fibres are mostly sensory, besides nuclei and gray matter. It includes very dissimilar structures, and extends from the thalamus to the crossing of the pyramids. It is merely a convenient topographical term, viz., the roof of the basis of the crus. Dorsad to the tegmentum is the canal of Sylvius, and the roof of the latter is made by the corpora quadrigemina and the velum medullare anticum (valve of Vieussens). The substantia nigra, and cephalad to it the corpus subthalamicum (Luy's body), and caudad the red nucleus of the tegmentum are a series of ganglia located between the crusta and the tegmentum, to which we merely allude. The crura, as seen in Fig. 65, diverge from the pons to the thalami optici, have a slightly fluted and twisted appearance, and enclose a triangular area called the posterior perforated space. At the apex of this triangle we have the emergence of the third nerves.

Digitized by Google

Our business is chiefly with the ocular nerves, and it would be natural to enter at once upon a description of their course and relations in the medulla. We cannot appreciate their characteristics and the events which may happen when lesions attack them, without acquaintance with their environment and the functions, so far as known, of the organs amid which they are placed. We shall therefore not go astray if we sketch broadly the features of the medulla and the pons. For an accurate study see the article on "Brain: histology," by Spitzka, "Reference Handbook Med. Sciences" (Wm. Wood & Co., 1887). The translations of Obersteiner[1] and Edinger[2] will be freely used. Dr. M. A. Starr has treated the subject in a most lucid manner in an article[3] in the "Reference Handbook of the Medical Sciences." Dr. Starr traces the several tracts which go through the medulla and enumerates four: 1st, The tracts connecting the cerebrum and cerebellum. They are the outer and inner thirds of each pes, and they are to a large extent lost upon the masses of gray matter which are intermingled with them and with the transverse fibres of the pons. They also make up the superior

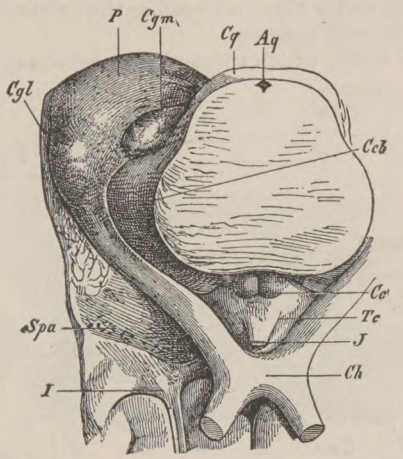

FIG. 66.—Base of the Brain to show the Emergence of the Optic Nerves. The cerebral hemispheres have been removed to show the posterior portion of the optic thalamus. The peduncles have been divided behind the corpora quadrigemina. *Cgm*, Corpus geniculatum mediale; *Cgl*, corpus geniculatum laterale; *P*, pulvinar of the thalamus; *Ch*, chiasma nervorum opticorum; *Cq*, corpora quadrigemina; *Aq*, aqueductus Sylvii; *Ccb*, pedunculus cerebri; *Cc*, corpora candicantia (mammillaria); *Tc*, tuber cinereum; *J*, infundibulum; *I*, tractus olfactorius separating into its middle and lateral roots; *Spa*, substantia perforata anterior.

and middle peduncles of the cerebellum. The inferior peduncle of the cerebellum is continuous with the columns of the cord. We also have in the pons, fibres passing from one hemisphere of the cerebellum to the other. The longitudinal fibres grow less numerous as we proceed caudad, being reduced to about one-fifth in volume. Lesions in the superior and middle peduncles of the cerebellum are not easily recognized, giving rise, like those due to cerebellar disturbance, to loss of equilibrium.

In the 2d division we have the middle third of the fibres of the pes or crusta which compose the great motor tracts coming from the motor areas of the cortex. Those for the arm and leg cross at the pyramids at the lower end of the medulla and form the lateral columns of the cord; that is, about

[1] "Central Nervous Organs," Phil., 1890.

[2] "Structure of the Central Nervous System," Phil., 1891.

[3] "Pons Varolii and Medulla Oblongata, Diagnosis of Local Lesions in," vol. v., p. 773.

Digitized by the College of Optometry

four-fifths of the fibres decussate, and the remainder continue straight down the anterior columns. Besides the above fibres we have in the pons special nuclei for the facial (seventh) and hypoglossal (twelfth) nerves, and the fibres from them also decussate, but at higher levels than the pyramids. Hence various combinations of paralysis of face, tongue, and extremities are possible according to the place of lesion. The figures from Starr illustrate these possibilities (Figs. 68, 69).

The 3d set of fibres is the tract for muscular sense, called the fillet or lemniscus, and when in the medulla called interolivary tract. It conveys sensation upward, and for this reason we trace it in this direction. The columns of Goll and Burdach in the dorsal surface of the spinal cord terminate at the nuclei gracilis and cuneatus. The fillet starts from these nuclei, and as it goes cephalad the two bands decussate at a point above the pyramids (sensory crossing of Wernicke) and enter the pons. It becomes ribbon-like, and later assumes an L shape, lying beneath the deep transverse bundles of the pons, in front of the formatio reticularis. In the tegmentum it lies mainly to the outer side and reaches the cortex, passing through the caudal part of the internal capsule.

4th. The sensory tract, which transmits sensations of touch, temperature,

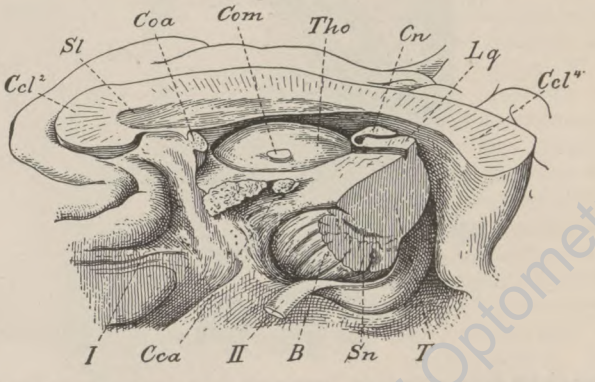

FIG. 67 (Henle).—Right Half of Brain turned obliquely upward—the peduncle *T* divided near its entrance into the thalamus *Tho; II*, the optic tract turned back. *I*, Olfactory nerve; Ccl^2, knee of the corpus callosum; *Sl*, septum lucidum; *Coa*, *Com*, commissura anterior and media; *Cn*, conarium (pineal gland); *Lq*, lamina of corpora quadrigemina; Ccl^4, splenium of the corpus callosum; *Sn*, substantia nigra; *B*, basis; *Cca*, peduncle of the corpora mammillaria.

and pain through the medulla and pons, is in the formatio reticularis. This portion of the medulla and pons lies just beneath the gray matter of the floor of the fourth ventricle, behind the tracts hitherto described. It is made up of nerve-fibres passing in three directions: *a*, transversely, the commissural fibres of the cranial nerve nuclei; *b*, from the nuclei ventrad, the fibres of the cranial nerve-roots and arciform fibres; *c*, longitudinally, the sensory tract. The longitudinal fibres can be traced from the gray matter and various columns of the spinal cord, through the formatio reticularis to its upper level in the tegmentum of the crus, whence they issue to enter the posterior part of the internal capsule. In the medulla the formatio reticularis of each side is divided into two parts by the line of exit of the nerve-roots of the twelfth. The inner part, near the median line, contains the continuation of the anterior and antero-lateral columns of the spinal cord, and the interolivary tract or lemniscus already described. The outer part contains the sensory tract now under consideration. In the inner two-thirds of this outer part the fibres pass which convey impressions of

Digitized by the College of Optometry

touch, temperature, and pain from the opposite half of the trunk and limbs. In the outer third of this part is found a column of peculiar structure resembling the substantia gelatinosa of the posterior horn of the spinal cord, and in this column terminate the fibres of the sensory part of the trigeminal nerve which turn downward after entering the pons Varolii, and terminate at different levels in the pons and medulla (see Fig. 69). Thus the outer position of the formatio reticularis contains the sensory tract from the face of the same side. It is evident from the diagram that a lesion which involves one-half of the formatio reticularis in the pons and medulla will produce an alternating anæsthesia, *i.e.*, loss of sensation on one side of the body and on the other side of the face and head (lesion at B, Fig. 69). Alternating anæsthesia is as characteristic a symptom of lesions of the formatio reticularis of the pons and medulla, as alternating paralysis is of lesions in the motor tract of the pons. In the upper part of the pons the sensory tract from the face crosses the median line, and hence

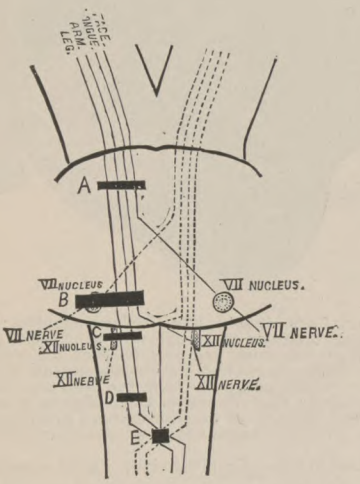

FIG. 68.

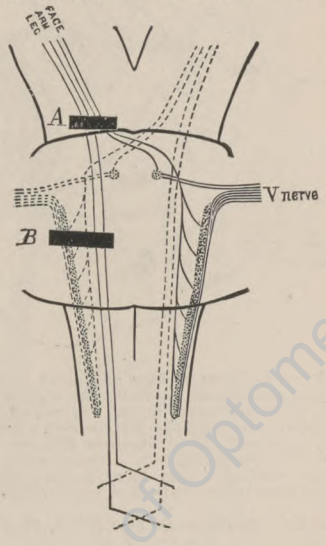

FIG. 69.

FIG. 68.—Lesion of Pons, with Alternating Motor Paralysis. Lesion at *A* causes hemiplegia of side opposite to lesion; lesion at *B* causes alternating paralysis, viz., body on right side, face on left side; lesion at *C* causes paralysis of tongue on side of lesion and of extremities of opposite side; lesion at *D* causes paralysis of extremities of opposite side; lesion at *E* causes paralysis of extremities of both sides.

FIG. 69.—Lesion of Pons, with Alternating Anæsthesia. The course of the sensory tract in pons and medulla. *A*, Lesion in tegmentum cruris cerebri, or upper quarter of pons, producing hemianæsthesia of the opposite side; *B*, lesion in formatio reticularis of pons or medulla, producing alternating anæsthesia.

a lesion in the formatio reticularis in the upper third of the pons, or in the crus cerebri, will produce a unilateral anæsthesia (lesion at A, Fig. 69). A lesion involving both halves of the formatio reticularis will produce bilateral sensory symptoms.

It is evident that a lesion of any extent, either in the pons or medulla, will inevitably destroy one or more of these four tracts, and consequently will produce serious symptoms of wide extent and of considerable diversity (Starr).

If now we make a section normal to the axis of the pons through the width of the anterior corpora quadrigemina (Fig. 70), we shall have a view

Digitized by Illinois College of Optometry

of the rootlets of the third nerve as they gather together to form its stem. We see that they traverse and surround a rounded mass of reticular substance called the red nucleus of the tegmentum. This body extends cephalad to the optic thalamus and receives fibres from the fasciculus retroflexus (Meynert's bundle), and also connects with the cerebellum by its superior peduncle. It has nothing to do with the oculo-motor nerve. Below and laterally is the substantia nigra of Soemmering, into which run fibres from the lenticular nucleus (see Fig. 67), and below that the crusta of the pes. On the median line at *M* is a decussation of fibres, spoken of above, named after Meynert, and below this another decussation named after Forel, *F*. At

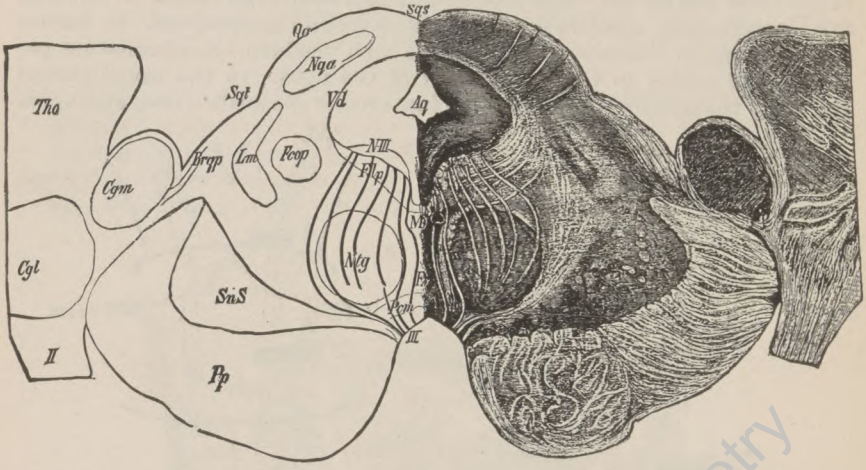

FIG. 70.—Cross Section at Caudal Edge of Ant. Corp. Quad. *Tho*, Thalamus opticus; *Cgm*, corpus geniculatum mediale; *Cgl*, corpus geniculatum laterale; *II*, tractus opticus; *Pp*, pes pedunculi; *SnS*, substantia nigra; *Ntg*, red nucleus of the tegmentum; *III*, root fibres of the oculo-motor nerve; *Pcm*, pedunculus corporis mammillaris; *M*, Meynert's fountain-like tegmentum crossing; *Lm*, lemniscus; *Fcop*, fibres in formatio reticularis which have come from the posterior commissure; *Vd*, descending root of trigeminus; *Aq*, aqueduct; *Flp*, fasciculus longitudinalis posterior; *Brqp*, brachium from corpora quadrigemina; *Nqa*, nucleus of anterior corpora quadrigemina; *Sqt*, sulcus transversus; *Sqs*, sulcus longitudinalis; *F*, Forel's ventral decussation of tegmentum.

Lm is a portion of the fillet, the tract for muscular sensation, and mesial to it *Fcop* indicates a spot where fibres stream from the posterior commissure in the roof of the aqueduct into the tegmentum. This locality is made up of fine arcuate fibres giving it the name already used of formatio reticularis tegmenti, area reticularis, etc. At the extreme lateral side of the figure we have a portion of the thalamus and of the two geniculate bodies *Cgl*, *Cgm*, and below is the optic tract. Below at the middle of the figure in the sulcus is a bundle of fibres coming down from the mammillary bodies. Mesially next the middle geniculate body is a section of the posterior commissure or brachium conjunctivæ of the corpora quadrigemina, and at *Nqa* is its nucleus designated by *Qa*. Cephalad of the region displayed in this section are other ganglionic masses, the corpus subthalamicum (nucleus of Luys, etc.), the ganglion habenulæ, the mammillary bodies, and these structures must be left out of consideration, as well as various bundles of fibres which have been isolated and described. Lastly, it must be stated that the walls of the third ventricle, of the aqueduct and the floor of the fourth ventricle are covered by a layer of gray matter, which has important functions. It is conjectured that this substance in the third ventricle has influence upon sleep; we know that lesion of the floor of the fourth ventricle is a cause of diabetes mellitus. The respiratory centre in the vagus nucleus will not be forgotten.

Digitized by the Internet Archive of Optometry

The remarkable complexity of this region renders its pathological phenomena exceedingly difficult to analyze.

Dismissing the parts which are only accessory to the main object of the

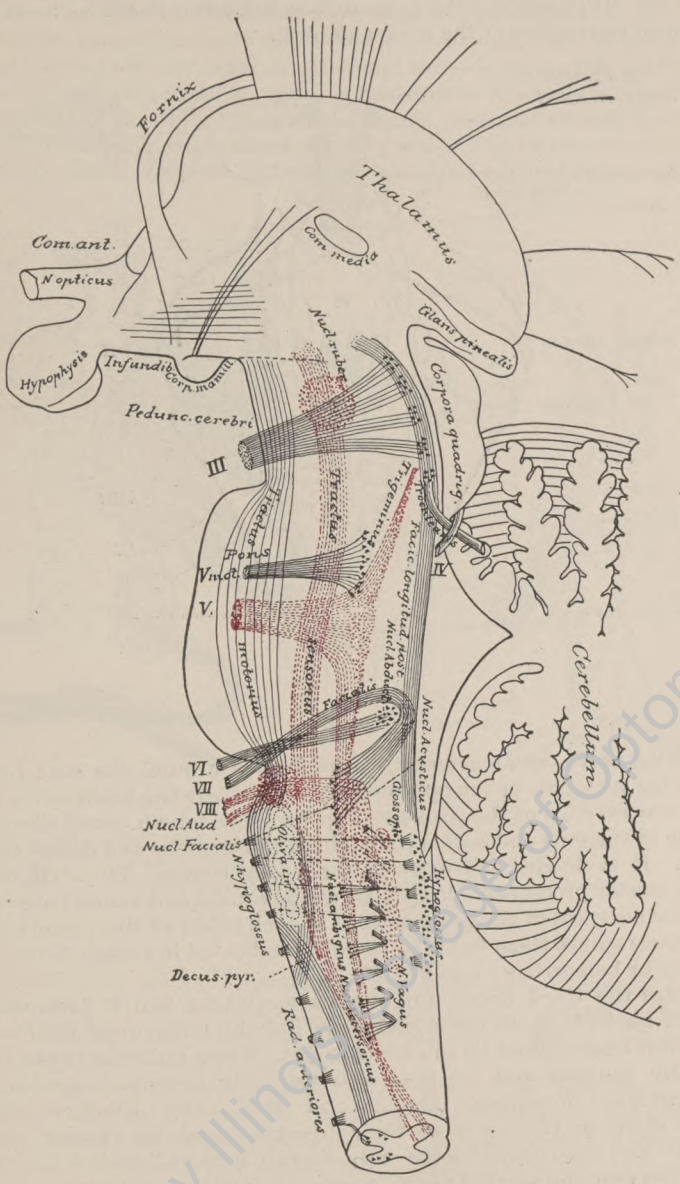

FIG. 71.

present study, we take up the nuclear origin of the ocular and associated nerves.

We here introduce a composite (Fig. 71) from Edinger to show on a sagittal

Digitized by Illinois College of Optometry

section the relations of the parts under consideration. The black lines denote motor structures, the red lines sensitive structures. The lettering explains the figure, and we shall frequently refer to it.

Another cut presenting the parts in face will serve to aid in locating the relations of the origins of the nerves (Knies).

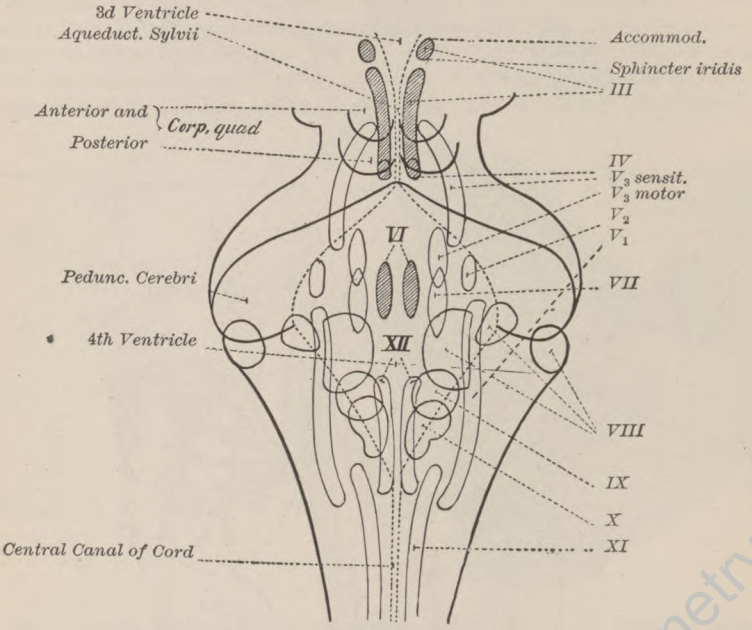

FIG. 72.

The third nerve, *oculo-motorius*, turns inward around the crus cerebri, approaching its fellow of the opposite side, and enters the brain at the cephalic and ventral edge of the pons (see Fig. 71). The fourth nerve climbs the outer side of the crus and enters the brain at the cephalic and dorsal edge of the pons. It is slender and exposed for a long course. The sixth follows down the basilar process and disappears at the caudal and ventral edge of the pons. The nearness of the oculo-motorii to each other at the posterior perforated space makes them liable to be both implicated in a single lesion, such as a tumor or hemorrhage (see Fig. 65).

We trace the third nerve into the brain, and we find it terminate in a group of nuclei beneath the aqueduct of Sylvius lying upon the fibres of the posterior longitudinal bundle (see Fig. 71). These nuclei have been most successfully studied and we possess a probably accurate knowledge of their individual functions. Kahler and Pick,[1] and afterward Starr,[2] arranged them in the order of their function, and the recent studies of Perlia[3] and Siemerling[4] have only slightly modified their order. The nuclei of the two oculo-motor nerves combine to form an almost regular tri-

[1] Zeitschrift für Heilkunde, 1881.

[2] Journal of Nervous and Mental Diseases, May, 1888.

[3] Graefe's Archives Ophth., xxxv., iv., 287, 1889.

[4] Archiv f. Psychiatrie und Nerven krankheiten, xxii., Supple. heft, 1891.

Digitized by Illinois College of Optometry

angle of broad base, its sagittal length about 10 mm., and it lies between the caudal portion of the third ventricle above the mammillary bodies and the region of the posterior corpora quadrigemina, occupying the whole of the floor of the iter e tertio ad quartem ventriculum (aqueduct).

There are, according to Perlia, seven clusters which can be more or less perfectly isolated and arranged in pairs, and there is one on the median line common to each side, making eight nuclei for each third nerve (see Fig. 73). Of the paired nuclei, two in front are separated distinctly from those behind, which are more closely approximated. Of the caudal pairs two are above (dorsal) and two below (ventral). The most caudal, which is also ventral comes

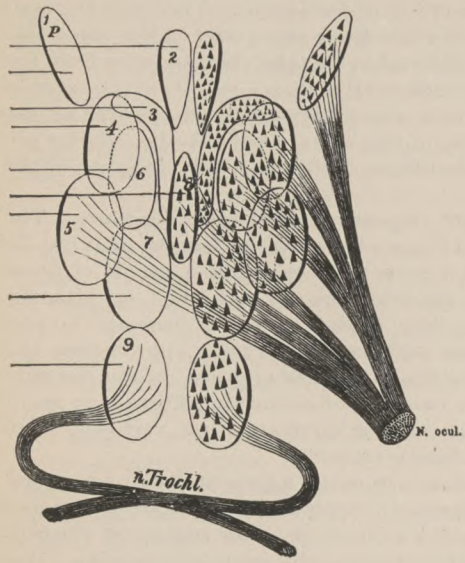

FIG. 73.

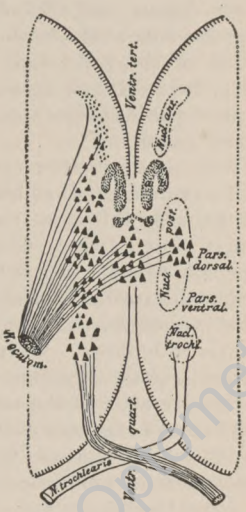

FIG. 74.

1 Sphincter iridis.	2 Levator palp. sup.	8 Convergence.	2 Levator palp. sup.	1 Sphincter iridis.
4 Rect. sup.	3 Mus. ciliaris.		3 Mus. ciliaris.	4 Rect. sup.
5 Obliq. inf.	6 Rect. intern.		6 Rectus internus.	5 Obliq. inf.
	7 Rect. inf.		7 Rectum inf.	
	9 Trochlearis.		9 Trochlearis.	

close to the nucleus for the trochlearis. The figure from Perlia (72) is numbered according to the scheme of Knies,[1] and the nuclei may be placed in two rows, of which the dorsal are also lateral, viz., 4 and 5. See also cut of same nuclei from Edinger (Fig. 74).

This arrangement differs from that of Kahler and Pick[2] (see Starr, l. c.) in placing the levator palp. nearer the median line and cephalad, and places on the median line the nucleus for convergence. The close vicinity of the levator palp. to the rect. superior is not disturbed, a relation abundantly confirmed by clinical experience. Other parts remain the same. The dorsal nuclei are for the rectus superior and the obliquus inferior. The ventral are for the rectus internus and rectus inferior. It is seen that a very natural collocation exists;

[1] Archiv f. Augenheilkunde, xxiii., 44, 1891.

[2] Zeitschrift für Heilkunde, 1881.

Digitized by the College of Optometry

that the group of adductors, R. int. (6), R. inf. (7) (both ventral), and R. sup. (4) dorsal and overlapping, lie closely grouped and in contact with the common nucleus (8) for convergence. The levators, R. sup. (4) obliq. inf. (5) and the depressors, R. inf. (7) and trochlearis (9) also lie in series. The muscles for the pupil and for accommodation are together, although a little apart from others, while accommodation and convergence take their closely related positions. Decussation of fibres of the nuclei had been noted by Gudden and others, but Knies happily points out that the more accurate description of Perlia authorizes us to say that the decussating fibres belong to the nucleus for the obl. inferior (5), and put it in harmony with the nucleus of the trochlearis of the same side whose roots have long been known to cross in the velum medullare anterius (valve of Vieussens). Therefore the recti muscles of the right side get their impulse from the nuclei of the same side of the brain, but the obliqui of the right side take their impulse from the opposite side of the brain, and *vice versa*. Hence, if a lesion involve all the nuclei of the right half of the brain, the paralyzed muscles will be all the recti, the pupil and accommodation on the same side, but the inferior oblique of the opposite side. The trochlearis of the other side might or might not be paralyzed.

Something further must be said respecting the connecting fibres. The nuclei are situated, as has been said, upon the posterior longitudinal bundle (see Fig. 71, Edinger), and Perlia (l. c., p. 302) signalizes a tangle of fibres which hangs like a web above the whole group and spins out laterally into the nuclei. Near the raphè they incline ventrally beneath the posterior longitudinal bundle and turn cephalad in curves. Approaching the third ventricle they bend around the peduncles and are lost in the substantia reticularis. We thus have two sets of connecting fibres, one sagittal and coarse (Spitzka) and a finer set coming more or less vertically from the gray matter of the wall of the fourth ventricle.

Perlia also calls attention to offshoots from the interpeduncular transverse commissure of Hall and Gudden, leaving the optic tract in the anterior corpora quadrigemina and descending to wind around the outer surface of the crus to enter the base of the brain a little in front of the oculo-motor nerve. One branch of this bundle goes to the nuclei of the anterior root of the 3d nerve, and another branch traverses the middle of the nuclear group to gain the nuclei of the trochlearis (l. c., p. 307). These connections establish relations between the optic tract, the tubercula quadrigemina anteriora, and the nuclei of the ocular muscles. Such an arrangement explains Graefe's case (1856) in which, with paralysis of all the extrinsic muscles of the globe, the reaction of the pupil to light was destroyed, but its reaction to convergence and accommodation remained. The recognition of a special centre for convergence (8) and the existence of longitudinal fibres on the floor of the fourth ventricle which connect the nuclei of the third (Edinger, Spitzka), make it clear why contraction of the pupil may fail to occur under feeble stimulus of impaired optic nerve fibres, but may occur with convergence ; and that convergence is a more efficient agent than accommodation, as can be experimentally proved.

Just behind the oculo-motor nest of nuclei is found that for the *trochlearis*. Its root fibres unlike those of the third mount upward, enter the velum medullare (valve of Vieussens) and decussate almost if not quite completely, so that the nucleus for the right superior oblique muscle lies on the left side of the median plane and *vice versa*. We thus have the origin of each oblique muscle, both inferior and superior, located across the median line of the eye designated—a singular harmony.

The nucleus of the sixth, the *abducens*, lies beneath the floor of the ventricle at about its middle, and the fibres go down through the body of the pons to appear at its caudal edge (see Figs. 65 and 71). Between the abducens nucleus and that for the internal rectus is a connecting bundle of fibres which Siemerling claims has not been anatomically demonstrated, but which on clinical evidence indisputably exists.

Besides the relations now described we take note of another important fact, viz., that the abducens nucleus is included in a bend of the fibres of the facial nerve at the point called the knee (Fig. 71). Indeed by some the facial is said to have a nucleus of origin at or near the nucleus of the abducens, while Spitzka says it receives an accession of fibres from the posterior fasciculus (the longitudinal bundle). The place of this remarkable relationship is denoted by a slight bulge on the floor of the ventricle, the eminentia teres. At this point originate those fibres of the facial which supply the orbicularis and frontal muscles, and we are enabled to understand how sometimes only the lower facial branches may be injured, as happens in bulbar palsy, because only the lower (caudad) nucleus is involved—while the orbicularis is spared. On the other hand Birdsall[1] observed ophthalmoplegia externa in which the excitability of the orbicularis and frontal muscles was impaired. This tallies with the remark of Spitzka as to the accession of fibres "aberrant from the oculo-motor nidus" to the facial from the posterior fasciculus, and with Mendel's[2] experiments, who located the ocular facial nucleus in the posterior part of the third nucleus; in this he coincides with Bechterew, 1883. This interesting relation teaches us the impulse to the act of winking. We must also bear in mind the *sensory* reflex for the action of the orbicularis, as shown in winking and blepharospasm, which brings us to the fifth or *trigeminus*.

The fifth nerve is both motor and sensory, but we are chiefly interested in its sensory portion. Its nuclear origin is very extensive, particularly in the sensory portion, and its origins are both widely separated and remote from the roots of other nerves; the nearest being those of the fourth and sixth. Tracing it from the surface of the pons, which it enters at about its middle and remote from the median line, its sensory root passes backward and inward to some small groups of cells lying beneath the floor of the fourth ventricle known as the middle nucleus. The majority of the fibres, however, turn downward through the pons and medulla under the name of the ascending root, being described as starting from all levels above the cervical spinal cord as low as the second cervical nerve, and terminating in a long column of gray matter which is continuous with the gelatinous substance of the posterior horn (the gray tubercle of Rolando). Another portion of the sensory root (descending) may be traced upward from the level of the middle nucleus as high as the upper part of the corpora quadrigemina, where they arise from large round nerve-cells. They lie external to the aqueduct of Sylvius and are arranged in the form of a crescent (see Fig. 71). These fibres may be implicated in affections involving the ocular nuclei. The majority of the fibres of the motor root arise from a nucleus near to and inside of the middle sensory nucleus (see Figs. 71 and 72). Spitzka gives six roots to the trigeminus, while Magnus indicates four.[3]

Following the special purposes of an ophthalmic inquiry, we touch inci-

---

[1] Journal of Nervous and Mental Disease, Feb., 1887, p. 65.

[2] Berlin. Klin. Wochen., 1887, p. 913.

[3] See Edinger, p. 209, Am. Ed., also Obersteiner, p. 292, Am. Ed.

dentally on the close relations of the facial (7th) and the hypoglossus (12th) because their root fibres lie close together under the floor of the fourth ventricle (see Fig. 71). The principal nucleus of the twelfth lies far down the medulla and its origin is extensively distributed (see Fig. 72). It is usually with paralysis of the lower face that deflection of the tongue is linked and then the lesion will be low down; but it may concur with impairment of the orbicularis and then the lesion is high up near the eminentia teres and may compromise eye muscles, abducens, etc. Some singular cases in which the open-

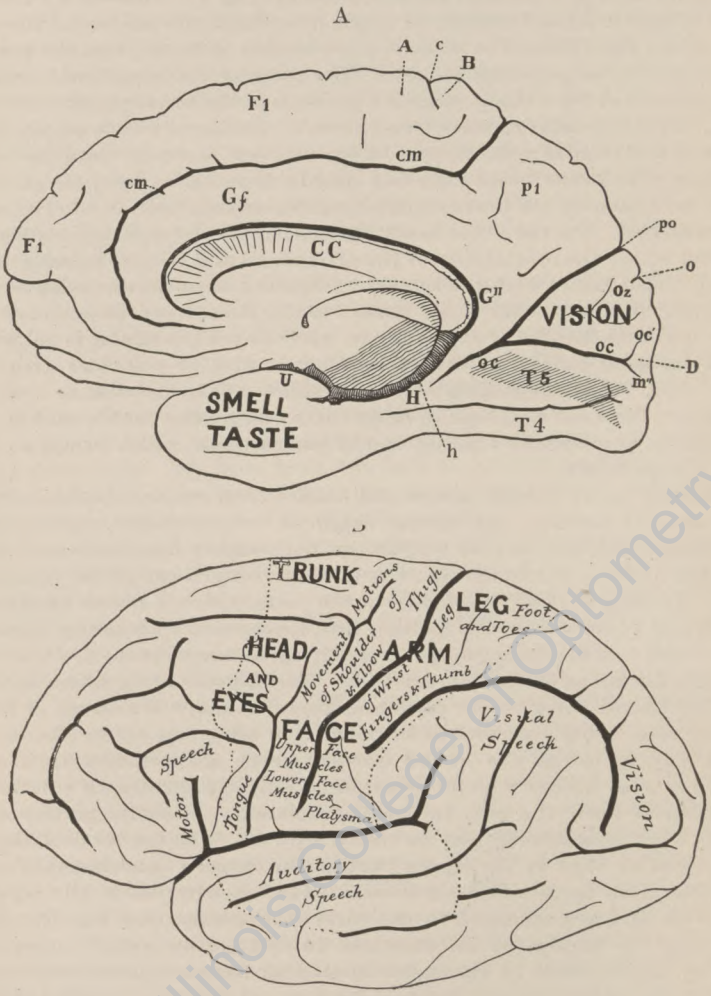

FIG. 75.

ing of the mouth causes movement of the upper lid[1] are accounted for by assuming an abnormal connection between the facial nucleus, the upper nucleus of the hypoglossus, and the motor oculi at the spot referred to.

[1] See Michel, Jahresbericht, 1892, p. 354—and Hubbel, Arch. of Ophthal.

Digitized by Illinois College of Optometry

We may dwell no longer upon the pons and medulla, but now state what is held as to the *cortical* representation of the ocular motor nerves. On this point our knowledge is not precise. Experimenters have reached different conclusions. Mills[1] gives a minute diagram of the separate subdivisions of the motor region founded chiefly on the conclusions of Horsley and Schaefer. They decide upon the second frontal convolution as the area for movement of the head and eyes. Ferrier concurs with this view and also adds the angular gyrus and superior temporo-sphenoidal convolution as capable of the same effect. For details see Mills, l. c., p. 236. Others quoted by Knies[2] fix upon the lower part of the parietal lobe, also upon the visual area of the occipital lobe, etc. It is clear that irritation of a large portion of the cortex will excite ocular movements. And this is what we might expect, knowing that noises, a touch, a flash of light, will make us turn our eyes to the expected point. It is to be noted that all cortical stimulation gives rise to conjugate or associate movements of the eyes, *i.e.*, to binocular visual direction, never to isolated movements of one eye. For the levator palpebræ a special area is claimed at the lower part of the parietal convolution, near the upper facial and the hypoglossal, and that it controls the opposite eye. But we cannot set apart any definite area of the cortex as dominating eye movements as we can for the hand or thumb, etc. Knies (l. c.) very ably discusses all the known facts and concludes that we must assign to the visual area the directing power for all intentional or voluntary movements of the eyes, while to the nuclei come fibres from almost all parts of the cortex, exciting purely reflex movements. Fig. 75 (Starr) gives the latest arrangement in condensed form.

FIG. 76.

Sub-cortical lesions are, of course, possible, and we have somewhat more definite knowledge about them. In Forster's diagram (Fig. 76), giving a horizontal section just dorsad of the third ventricle, we have a spot cephalad the knee of the internal capsule marked *eye*, at which lesions will affect eye movements. Again *OP* marks the place where the optic radiation comes in from the occipital lobe; here is the spot where hemianopsia may be produced. Coming farther down the tract, in the peduncle we come upon a spot where a lesion will cause hemiplegia of the opposite side, and paralysis of the oculo-motor nerve of the side of the lesion. This point is one to be specially noted.

If the oculo-motor paralysis does not include the pupil and the ciliary muscle, the lesion will be in the peduncle and rather small. If these nuclei are included, the lesion will be at the base, or so large as to affect the third ventricle, where the pupillary and ciliary nuclei are found. One case is given where right hemiplegia, paralysis of face and tongue, and total paralysis of

---

[1] "Cerebral Localization," Trans. Congress Am. Physicians and Surgeons, vol. i., p. 219, 1888.

[2] Archiv f. Augenheilkunde, xxiii., 1, 22, 1891.

Digitized by the College of Optometry

the left oculo-motor occurred from a small lesion at the very end of the peduncle (Mauthner[1]).

Diagnosis.—By what has been set forth in anatomy and physiology much has been done to aid in making a clinical diagnosis, and we may now consider the question from this standpoint. *Orbital* paralysis will be fairly assumed in the presence of tumors, injuries, abscesses, or periostitis in the orbit. The same is true of tenonitis and hemorrhage. The eyeball may, of course, be prominent, and pain in pushing it back is an important sign. Should the inferior oblique escape while all other muscles are paralyzed, this is explained by its anatomical origin. On the other hand, paralysis of the inferior oblique with paralysis of the sphincter pupillæ and of accommodation is explained by a lesion of the motor root of the ophthalmic ganglion (radix brevis), which supplies the parts enumerated. Congenital absence of muscles has been reported; while most congenital paralyses are nuclear. A peripheral or rheumatic paralysis is difficult to prove, yet we cannot always make a better diagnosis. We have already spoken of lesions at the sphenoidal fissure which may impair all the nerves here passing and may even involve both eyes. Symmetrical paralyzing lesions in both orbits are recorded. Graefe, 1864, reported schirrus in each orbit, Scott[2] grummata in each orbit of a child five years old. How the optic nerve may escape when the nerves at the sphenoidal fissure are perhaps all implicated is explained by the separation between their respective foramina, the former above the clinoid process of the sphenoidal wing, the latter lying under it and covered by the edge of the tentorial portion of the dura mater, as it surrounds the crura.

Basal Paralysis.—To make such a diagnosis probable, we must have all the branches of the third implicated, because integrity of the pupil and accommodation transfers the lesion to the nuclear variety. Again, the loss of the sense of smell is in favor of a basal lesion, although not with certainty, because that too may be nuclear. Optic neuritis has about the same relative value; its origin may be both basal and cerebral. *Recurrent* paralysis, especially of all the third nerve, is almost certainly basal. It happens most frequently among young subjects. The periods may be within a few weeks, or months, or at longer intervals. It took place five times in a girl five years of age who was under my care. The duration of each attack may be for a few days or for weeks.

[1] "Die ursächlichen Momente der Augenmuskel-Lähmungen," Wiesbaden, 1866, p. 393.

[2] Archiv für Augenheilkunde, vii., 94, 1878.

Digitized by Illinois College of Optometry

In most cases there is headache (migraine). The two cases where an autopsy was made disclosed in one an exudation and in the other tubercular deposit about the stem of the oculo-motor. Both sides may be involved, and Graefe reported five cases of paralysis of all the eye muscles of both sides with complete recovery; he believed them to be basal and from cold, but about this localization there may be a doubt. An enumeration of the causes of basal paralysis will throw some light on its diagnosis. Their enumeration is borrowed from Mauthner,[1] whose treatise on this topic is the most complete in existence and summarizes what is known at the present time. They are, (1) hemorrhages; (2) circumscribed pachymeningitis about the nerve trunks; (3) meningitis, both simple and tubercular, and this often in children, sometimes getting well and at other times ending fatally; it may also be of traumatic origin, and the prognosis in all cases is serious; (4) abscesses, especially of otitic origin; (5) aneurisms; (6) arteritis obliterans, which impairs the nutrition of the nerves, and is often syphilitic; (7) neoplasms, including specific growths compressing the nerves, and sometimes filling their foramina; (8) idiopathic lesions of the trunks, viz., *a*, interstitial neuritis and perineuritis of tubercular or gummatous character; *b*, lymphomatous swellings in cases of lymphomatous disease, and *c*, gray degeneration consequent upon nuclear disease.

We must study collateral symptoms carefully to form a probable judgment, such as variations in temperature and other signs of inflammation—the history personal and hereditary—not only the presence, but the absence of other cerebral disturbances. For example, tumor in the brain may cause nerve trunk lesions as well as if at the base, either by stoppage of the ventricles and internal hydrocephalus, or by pressure reaching to the base, *e.g.*, paralysis of right sixth reported by Nothnagel from tumor in left hemisphere. But crossed paralysis of the third with hemiplegia, or with hemianopsia, brings us to the crus, and if the other oculo-motor is subsequently paralyzed, we may be sure that the lesion is in the vicinity of the crura as the third nerves enter the pons.[2] Anæsthesia or irritation of the fifth is not a distinctive sign, it may be basal or pontine. But anæsthesia may come from a lesion higher up, viz., in the internal capsule at its caudal part.

It is impossible within suitable limits to elaborate this topic; we can only call attention to the tokens from the olfactory nerve, the optic nerve, the auditory, the facial nerve, and to careful analysis, not only of what muscles are at fault, but of all other symptoms,

---

[1] "Die ursächlichen Momente der Augenmuskel-Lähmungen," 1886.

[2] See analysis of one hundred and fifty cases of brain syphilis with eye lesions, and autopsies, by W. Uhthoff—Graefe, Archiv f. Oph., B. xxxix., Abth. 1, S. 1–182.

Digitized by Illinois College of Optometry

whether general or cerebral, which may be used as clues. The rapidity of onset, spasms, the degree and location of pain, will all be considered. Neoplasms usually cause slowly progressive symptoms. Yet this is not always true, because time may be required to develop disturbance, and periods of repose and aggravation may occur. Hemorrhages, embolism, and softening have their own features.

Nuclear paralysis has certain characteristics. It is sometimes sudden, is usually slow in attack, and affects successive muscles; they may for a time act well and give out as the examination proceeds; the affection is often incomplete; is apt to be worse at night or when fatigued; it may be unilateral or bilateral; usually there is no pain, yet pain may be severe. A very significant symptom is somnolence, and a most important sign is *non-recognition* of *double images.* Affection of the extrinsic muscles is called ophthalmoplegia externa; of the intrinsic muscles, the pupil and accommodation being paralyzed, is ophthalmoplegia interna. The dilatation of the pupil may be moderate. If one muscle after another fall a prey to paralysis we may consider the cause basal by certain correlative symptoms, but it may also be nuclear, and if, for example, the muscles animated by the oculo-motor on one side are involved at the same time with the trochlearis of the other eye, we know this is nuclear. There may be double ptosis of nuclear origin; single ptosis may be cortical, fascicular, or nuclear. See Gowers.[1] Pflüger[2] reports a case of double trochlearis paralysis with partial paralysis of both oculo-motors, due to influenza or grip. Among oculo-motor nerves, the right inferior oblique, myosis of both sides—abated pupillary action both to light and convergence, paresis of accommodation both sides—these lesions must be nuclear. Paralysis of convergence without impairment of associated movement to the right and left is reported by Straub.[3] I have recently had one such case. Seggel[4] reports mydriasis of one eye, there being no response to light, but contraction upon convergence and accommodation, and no impairment of sight. Defect of levatores palpebrarum and of both superior recti of congenital type must be referred to the nuclei (see Gowers, l. c.). Graefe[5] reported a case of a man with paralysis of the six external muscles of each eye, with good accommodation and normal pupils; this, of course, was nuclear. Paralysis of either the third, sixth, or seventh with crossed hemiplegia signifies hemorrhage into the pons.

---

[1] "Diseases of the Nervous System," Am. ed., p. 620, 1888.

[2] Graefe's Archives, xxxvi., 4, 71, 1891.

[3] Archiv für Augenheilkunde, xxiii., 3 and 4, S. 271. I have seen one case.

[4] Archiv für Augenheilkunde, xxiv., 3, S. 234.

[5] Archiv für Ophth., ii., 2, 299.

Digitized by Illinois College of Optometry

If the lesions be in the upper half of the pons facial palsy may be on the same side with body palsy. The facial and sixth are sometimes affected together on the side opposite to the limbs. The face and limbs palsied on the same side and the third on the opposite side points to the crus. There may be a lesion so small that the nerves escape.[1]

Lesion of the abducens nucleus with or without hemiplegia damages not only the corresponding rectus externus but also the associated rectus internus of the other eye, causing *conjugate deviation.* This subject will be dealt with more at length when speaking of cortical lesions, which also cause this symptom.

Gowers relates paralysis of elevators of both eyes by a tumor on the middle line of the fourth ventricle just behind the velum (see Fig. 73 from Perlia showing the vicinity of the superior recti and inferior oblique nuclei).

A case seen by Dr. Starr[2] and later by myself is instructive. The symptoms were temporary conjugate deviation to the left side, analgesia of left face and of right half of body; ataxia of right limbs without paralysis; he staggered in walking, had to be very cautious in going down steps; contraction of left pupil, paralysis of left trochlearis, anæsthesia of left cornea and beginning damage to its epithelium; urine sp. gr. 1040 and contained sugar. These signs placed the lesion in the left side of the tegmentum where the superior peduncle of the cerebellum comes in and near the trophic centre of the fifth nerve, very dorsad and extremely small (see Figs. 69 and 71). It touches the trochlearis nerve after its crossing and for a time stimulated the left abducens, thereby exciting, through its connection with the opposite rectus internus, conjugate deviation to the left. The irritation of the pupillary nucleus had persisted on the left side. The diagrams show the various possibilities of sensory disturbances due to the peculiar and interesting course taken by the various sensory tracts. Small hemorrhages and very limited lesions are possible in this region because the arteries are small, they supply very small territories, and do not inosculate with each other. They are technically "terminal" vessels. A fact of importance is, that the nuclei for the ciliary muscle and for the iris are supplied by a special arterial branch which has no relation with the region in which the other nuclei are found. In this fact lies an explanation of some cases of isolated paralysis of these groups.

Mauthner collects a series of instructive cases (l. c. pp. 311–328). See also Gowers' Lectures, 1887, Manual, 1888.

[1] For illustration of such lesions with autopsies, see Uhthoff—Graefe, Arch., l. c.

[2] Reported in full by Dr. Starr in N. Y. Medical Record, Feb. 11th, 1893.

Digitized by Internet Archive

The complications may be loss of smell, which is rare; loss of sight due to optic atrophy and often syphilitic; both the motor and the sensory portion of the trigeminus may suffer, most frequently the latter; facial or hypoglossal palsy; bulbar paralysis, progressive muscular atrophy, deafness may co-exist. The sufferings of the poet Heine belonged to nuclear palsy. Graefe called attention to anæsthesia of the face, while on the other hand extreme neuralgia may co-exist, and insanity sometimes occurs. Locomotor ataxy, hemiplegia, hemiataxia, hemianæsthesia, and general paresis may take place.

Galezowski and Duchenne have seen cases of bilateral paralysis of the third and of the sixth in spinal disease. Lesion of the sixth is the most common. Unilateral lesions are common. In spinal cases the paralysis is likely to be incomplete and not to be permanent. No other sign of spinal-cord disease may occur for a long time, and the eye symptoms, while unsupported by others, will remain of doubtful significance. The motor nerves of the eye often become implicated at a late stage of spinal disease, and then the lesion is not transitory, but permanent. Implication of the optic nerve may be either an early or late symptom. In some autopsies (Leube), the trunks of the motores oculorum and of the sixth have been transformed into gray, thick, and hard cords.

The Argyll-Robertson symptom of early ataxy, that the pupils contract feebly to light and quickly to convergence and accommodation, is explained by the most recent author[1] as due, not to a nuclear lesion of the pupillary centre, but of the communicating fibres between the optic tract and the pupillary nucleus. He quotes four cases of this symptom confined to one eye, and says that the lesion which then causes reflex pupillary immobility on one side, with retention of the consensual reflex, merely blocks the passage of the direct fibres from the optic tract to the oculo-motor nucleus on the same side; while that which produces both direct and consensual immobility of the pupil on one side (assuming that there is only one lesion) occupies a position which blocks both the direct and the crossed system of fibres, *i.e.*, in the sphere of the centre of the sphincter iridis. A lesion in the same region is usually extensive enough to implicate the above-mentioned fibres on both sides of the median line, *i.e.*, the direct and the crossing, and hence the Argyll-Robertson pupil commonly affects both eyes.

Fontan (see Mauthner) describes nicotine paralysis in which the extrinsic muscles are incapable of function and the pupil and ciliary muscle irritated (myosis and spasm of A).

[1] Turner: "On the Diagnostic Value of the Loss of the Pupillary Light Reaction, with a Note on the Oculo-Facial Muscular Group."—Ophth. Hosp. Reports, vol. xiii., part iii., 328, Dec., 1892.

Digitized by Microsoft®

Near the seventh cervical vertebra is the cilio-spinal centre which controls the vessels of the iris by the sympathetic nerve fibres. When they become paretic the iris vessels lose tone, dilate, and myosis ensues—the corresponding half of the face blushes and perspires.

Orbital paralysis arises from inflammation of the connective tissue or from periostitis, from tumors, from wounds and injuries. Pain, tenderness on pressure or on percussion, are important signs. One must push the finger deeply under the rim of the orbit all around. The case will often have to be observed for some time before a conclusion can be reached. Finally, *rheumatic* or *peripheral* paralysis may occur, as from sitting in a draught, and the sixth nerve is oftenest concerned.

Drs. Collins and L. Wilde (*Am. Journal Med. Sciences*, Nov., 1891) have examined and tabulated 120 cases of ophthalmoplegia from which much valuable information can be gained as to their clinical histories and events. A useful summary of the possible causes and varieties of these cases is stated in their classification, which closely resembles that of Mauthner, v. s.

Concluding now this imperfect sketch of causes and etiology, it remains to be said that fully one-half of all cases of ocular paralysis are due to syphilis and especially to the late forms. A study of Uhthoff's paper, l. c., shows the special lesions to include gummy tumors and infiltrations; thickening of the meninges or periosteum; exostoses; degeneration of vessels, with consequent softening of brain substance, and also atrophy of the nerve trunks or nuclei; thrombosis, partial or complete; hemorrhages. The lesions may be single or multiple. At least two cases are given in which no lesion was found at the autopsy; which is perhaps not surprising unless the microscope was used, and the same writer, Howard, reports two cases complicated by exophthalmic goitre, which recovered.[1]

In addition the following etiological conditions may be found: cerebral hemorrhages, circumscribed pachymeningitis, meningitis on the convexity of the hemispheres, both ordinary and tubercular, abscesses at the base frequently arising from aural disease, enlargement of arteries, aneurisms, arteritis obliterans, tumors including gummata, idiopathic diseases of the trunks of the nerves at the base, such as neuritis, gummy degeneration, tubercular degeneration, lymphomata, gray degeneration. We have also paralysis from diphtheria, from grip, from diabetes mellitus, from nicotine, from lead, and from injuries. Schoeler, out of 70 cases observed a long time, could determine the cause in only 64%.

The chronic cases, which are the more frequent, arise from epen-

[1] "Bilateral Ophthalmoplegia," etc., Am. Journal Med. Sciences, p. 238, March, 1889.

Digitized by the Boston Medical Library

dymitis with secondary affection of the gray matter of the ventricle (polio-encephalitis superior) multiple sclerosis, and atrophy of the nuclei. Ocular paralysis in spinal cord disease may disappear and return. Pell[1] reports the third nerve to have been affected seven times.

Acute cases arise from inflammation of the gray matter of the third and fourth ventricles (polio-encephalitis superior of Wernicke) or from hemorrhage. As would be expected, diabetes not infrequently exists. In acute cases, Wernicke has seen acute double optic neuritis. In chronic cases, the optic nerves may be atrophied or impaired or intact. Acute cases may be suddenly fatal, while a case of Etters, 1882, involving a series of nerves from the second to the eighth with profound paralyses, recovered almost entirely after seven weeks. Finally, this lesion is sometimes congenital, although some congenital defects in the eye muscles are due, not to paralysis, but to absence of muscles or their incorrect insertion or imperfect development.

Fuchs[2] describes cases of isolated double ptosis which he attributes to atrophy of the levatores muscles—*i.e.*, a peripheral lesion; but he evidently has not weighed the reasons for assigning the nuclei of these muscles to the leading cephalic position which Knies has given them, else he would have been more likely to regard the pathology as nuclear in at least some of the cases.

If disease involve the anterior quadrigeminal[3] bodies there is amaurosis; in some cases the ophthalmoscope reveals absolutely nothing. In tumors we may have choked disc or atrophy of the optic nerve, etc. Generally the pupil does not react either way. Naturally we would look for lesion of the trochlearis muscles and probably of neighboring nuclei. Hemiataxia is very prone to occur, and simulates hemiplegia, but will be easily discriminated by testing the muscular force. It arises from interference with the superior cerebellar peduncles and with the crossing fibres of the pons and possibly with the vestibular nucleus of the auditory nerve.

We have yet to consider *cortical* and *sub-cortical* paralysis of ocular muscles. (See Fig. 75.) We have stated that this form of paralysis is always conjugate—*i.e.*, associated movements of the eyes are disturbed, and of course both eyes are affected. We have remarked, without dwelling on the point, that such lesions also take origin in the pons and can then be quite accurately localized. But we are far less able to determine the place affected when a lesion is cortical. The experimenters are not in agreement as to the cortical area. Horsley and Schaefer select a space in the frontal lobe, and

[1] Berlin. klin. Wochenschrift, 1890, 1.
[2] Graefe, Archiv f. Oph., xxxvi., 1, 234.
[3] See Goldzieher, Centralblatt f. Augenheilk., Feb., 1893.

Digitized by the Boston Public Library

Ferrier chooses a somewhat less extensive area in the same region, in front of the head area, which gives rise when irritated to opening of the eyes, dilation of the pupils, and turning of the head to the opposite side, with conjugate deviation to the same side. In this view Mills concurs, 1888. Stimulation of the region just in front of and including the angular gyrus causes conjugate deviation to the opposite side. Wernicke thinks a lesion of the lower parietal region of the opposite side is denoted by conjugate deviation when it remains permanent. Temporary deviation occurs from stimulation almost anywhere in the cortex. It is a frequent phenomenon at the onset of cerebral apoplexy. The rule is formulated as first given by Prevost, that irritation of one hemisphere causes the eyes to turn to the opposite side, an active effect—while paralysis of one hemisphere causes deviation to the same side, a passive result, because the opposite hemisphere excels in power. Usually the deviation lasts only a few hours or perhaps weeks. It often prevails during the comatose period and disappears as consciousness returns. A few cases of permanent deviation are recorded from lesion of the thalamus, but we cannot establish any connection between the symptom and any definite cortical or subcortical region. It is very interesting that experiments on animals by Munk and Schaefer with weak induction currents have shown that irritation of the anterior part of the visual area produces movement of both eyes downward, and of the posterior part of the visual area movement upward. If the macula region of the visual area be stimulated no movement occurs, because it then seems as if the irritation proceeded from the point of fixation of the visual lines, and no change of direction ensues (Obrigia[1]). The farther from the macula region of the cortex (cuneus) is the part stimulated the more decided the movement of the visual axes and to the opposite side.

Conjugate deviation from pontine lesion presents some variations of type and may be either acute or chronic, temporary or permanent. It is not admissible to enter at length into its discussion. There is a large literature on the subject, and a very full compilation is given at the close of an excellent article on eye paralysis by the late Dr. J. A. Jeffries.[2] The thesis of Prevost, 1868, and a treatise by Hunnius, 1881, are valuable contributions, while Ross and Gowers treat of it at some length in their works on nervous diseases. See also Swanzy, Trans. Oph. Soc. United Kingdom, 1889, p. 6. Drs. Collins and L. Wilde[3] have collected and classified 120 cases of ophthalmoplegia, and their arrangement of them corre-

[1] Archiv f. Anat. und Phys., 1890, S. 260.
[2] Boston Med. and Surg. Journal, Oct. 20th and 27th, 1892.
[3] Am. Journal Med. Sciences, Nov., 1891.

Digitized by the Internet Archive

sponds closely to that of Mauthner. Dufour[1] has compiled a large number without closely analyzing them.

Prognosis must always be guarded. Recovery is frequent, but the possibility of progressive disease in the brain and spinal cord is not to be overlooked. There may be a long period of exemption from other trouble, but in the end mental disease, cerebral tumor, progressive paralysis, or locomotor ataxy may develop. If syphilis can be made out, treatment is more likely to be effective, yet not always. In the 120 cases collected by Collins and Wilde (l. c.) the recoveries were 24%; marked improvement 16%; death 24%. A diagnosis of the seat of the lesion, as well as its quality, is the most important element in prognosis, and justifies the elaborate discussion entered into on this point.

Treatment.—We must necessarily take into account the probable cause and localization of the disease, and when this is doubtful we fall back on general principles of therapeutics. A patient in the early stage of his trouble, who has double images, will close one eye, or wear over it a screen. It is well for short periods to put the screen over the sound eye, to keep the muscles of the other in practice. Soon after the lesion there may be headache or symptoms which suggest leeches or cupping, but not often is depletion proper. Blisters by cantharidal collodion, of small extent, over the temples or forehead, are useful as peripheral stimulants. Iodide of potassium would be given in small doses in non-syphilitic cases, and in large doses in syphilitic cases according to the stage and peculiarity of the constitutional disease. Electricity may be applied by the faradic current or by the interrupted galvanic current, the former preferably—one pole upon the temple or behind the ear, and the other by a small sponge upon the globe. Its efficacy is, to say the least, very doubtful. Neurologists have recently been placing reliance on hydrotherapy in nervous affections, and this will have its application to patients in whom there may be ocular complications.[2] It needs skilful management by well-contrived appliances and methods.

We also use strychnia in moderate doses after a few weeks have elapsed. We chiefly rely on spontaneous absorption of the mischievous exudation or hemorrhage or thickening. In case of tumors or of organic cerebral or spinal-cord disease, our attention is necessarily chiefly given to them. Michel has proposed mechanical exercise of the affected muscle by pulling the eye forcibly to the side toward which it cannot turn, by fixation forceps, having first instilled a solution of cocaine. This may be done once daily or once in two days. Bull has found good results from the proceeding.

---

[1] Annales d'Oculist.

[2] "Hydrotherapy in the Treatment of Nervous and Mental Diseases," by Frederick Peterson. Am. Journal Med. Sciences, Feb., 1893.

Digitized by Illinois College of Optometry

When, however, no improvement takes place after the lapse of two or three months, we have little right to expect it; but in most cases, a degree of amendment or entire cure will have occurred. For stationary conditions when double images are not too wide apart, we may employ prisms. It is sometimes possible to wear prisms as high as 8° to 10°, but beyond this they become too clumsy to be ordinarily tolerated. In adopting them, this rule is to be remembered: *Put the base of the prism toward the image which is to be influenced.* The total number of degrees required may be divided between the two eyes.

The eye which deviates the most, or which is weaker in power or in vision, will wear the stronger prism, in case, as may happen, a difference is to be made. Frequently the muscles undergo changes, and require corresponding alterations of the prisms. The permanent use of prisms is in fact a rarity, and pertains more especially to cases of vertical diplopia. Double vision beginning 10° or less above, and for all the field below the horizontal meridian, or which concerns the median region of fixation, is the most distressing, and calls loudly for aid. The utility of prisms is usually confined to these regions, viz., on the median line and for parts on or below the horizon. In fact, to extend their influence over the whole field is impossible, because the relations of the double images become entirely different in its various parts, and it is impracticable to adapt prisms to these changes. Prisms, like crutches, may be greatly acceptable; but they are imperfect substitutes for sound muscles.

When, however, a case has existed for months, and is beyond the utility of prisms, and does not improve, an operation will often serve an admirable purpose. Operative proceedings are twofold: 1st, simple tenotomy of one or more muscles; 2d, advancement of the impaired muscles.

For such a case, for example, as imperfect paralysis of the sixth, or sometimes when it is wholly paralyzed, a tenotomy of one or both interni may be indicated and give a useful result. Both must generally be divided, because in the opposite eye the internus has undergone secondary contraction by co-ordinated function, and the internus of the impaired eye, by being unopposed, has passed into a similar condition. The greatest stress in such an operation is to be laid on the internus of the sound eye, because undue freedom in loosening the internus of the injured eye will tend to exophthalmus, to sinking of the caruncle, and to render the globe incapable of sufficient movement in any direction. On the injured eye, if any such tendency appear, a suture must at once be deeply entered, and drawn tight to prevent undue slipping back of the tendon. The effect on the muscles is to be measured by using a lighted candle, a red glass and prisms, and single vision must, if possible, be secured to a point far within the functional range of the paralyzed muscle.

Digitized by the College of Optometry

The ultimate effect will be less than the immediate. If any power remains to the damaged muscle, it gains increase of function by being less seriously overmastered. In fact, this principle has been applied to the advantage of a paralyzed muscle, to prevent both the degeneration of its own tissue and extreme secondary contraction in the co-ordinated muscle, by performing tenotomy on a secondarily contracted muscle within a brief time, say two or three weeks after the onset of the paralysis. I have seen Dr. E. G. Loring perform such an operation, and he declared himself satisfied with its effect. I have had no such experience, and do not know that such practice is pursued by any one else. The degree to which the muscle is loosened is very carefully measured and restrained, because the tenotomy is intended to have a preventive effect, and also to aid in the recovery of function.

For cases of marked and permanent limitation of motion, the proper proceeding is combined *advancement of the paralyzed muscle* and setting back of one or more of its opponents.

For a correct understanding of this proceeding some remarks on the anatomy of the oculo-orbital fascia are proper. This tissue is also known as the capsule of Tenon. If the upper and lower lids be divided in the middle down to the fornix and the flaps be forcibly drawn back, it will be seen, by lifting the conjunctiva on a probe or a strabismus-hook, that there is a distinct layer of connective tissue going forward under it to the margin of the cornea. It is also noted that the ends of the muscles, as they reach the globe, protrude through it and are clearly displayed. Pressure with the convexity of the hook between the eyeball and the margin of the orbit demonstrates that something shuts off the parts behind, and forms a layer which adheres on the one side to the globe, and on the other to the margin of the orbit. The structure which is thus demonstrated is the oculo-orbital fascia. If the globe be enucleated, the tendons and the stump of the optic nerve will be seen to stick out through a layer of smooth fibrous membrane, which forms the cup in which the globe rotates, and which is part of the same fascia. The same structure enters into the eyelids and enwraps all the muscles as they advance toward the globe. It thus appears clear that a tendon may be entirely loosened from the globe, and if its lateral and immediate relations with the fascia are not torn up, it still remains in connection with the eye, and can exert an active, although reduced influence upon its movements. If, however, in detaching the tendon, cuts be freely made in the lateral regions, the muscle will lose its control over the globe, because it slips back into the orbit; and if any connection remains, it will be through the medium of some band of tissue which has escaped disruption. Motais has also shown that, after tenotomy, the reattachment of the muscle is more by the medium of the conjunctiva and capsule

PLATE II.

FIG. 1.

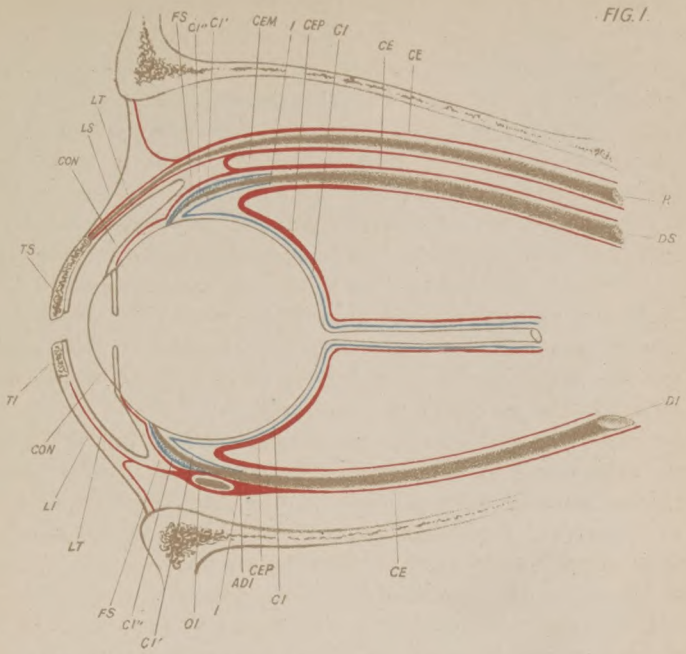

FIG. 2.

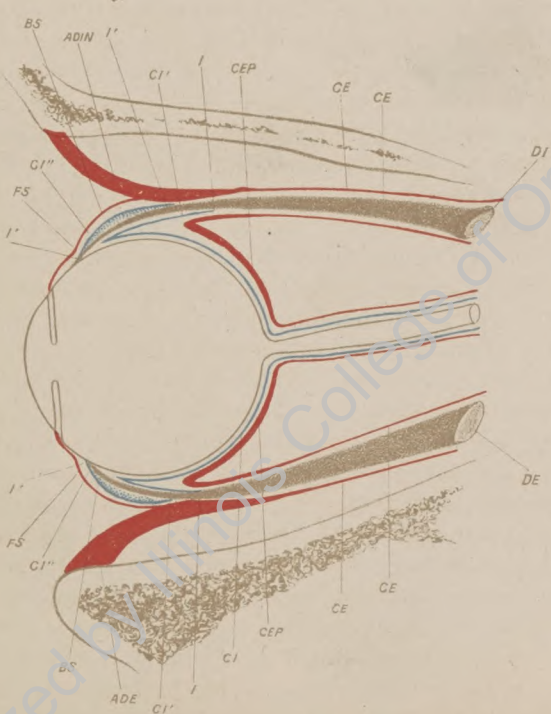

Digitized by Illinois College of Optometry

LINDNER, REDDY & CLARKE, LITH., N. Y.

Digitized by Illinois College of Optometry

EXPLANATION OF PLATE No. II.

FIG. 1.—Arrangement of capsule of Tenon in man. Vertical section passing through the superior and inferior recti.

CE, CE, CE (red), aponeurosis or external capsule forming sheath of muscles. CEP, CEP, deep layer of the sheath of the muscles folded backward upon itself to cover the posterior hemisphere of the globe. CEM, superficial layer of the sheath of the superior rectus muscle folded to form the sheath of the levator palpebræ. LT, LT, terminal layers of the aponeurosis going to the orbit, and tarsal cartilages. FS, FS, subconjunctival fascia.

CI, CI (blue), bulbar or internal capsule, serous membrane of the eye. CI′, internal capsule folded beneath the deep surface of the tendon and muscle which it covers to the point I, where the external capsule leaves the muscle. C″I, internal capsule in front of the tendon and anterior extremity of the muscle surrounding a serous bursa indicated by a dotted blue line. It stops behind just where the external capsule leaves that muscle to go to the orbit; anteriorly it is inserted into the sclerotic with the tendon and does not reach the border of the cornea as does the subconjunctival fascia FS.

ADI, aponeurotic offshoot of the inferior rectus muscle DI, split to envelop the inferior oblique muscle OI. DS, Superior rectus muscle. R, levator palpebræ. LS, superior tarso-orbital ligament. LI, inferior tarso-orbital ligament. TS, superior tarsus. TI, inferior tarsus. CON, CON, subconjunctival space.

FIG. 2.—Arrangement of capsule of Tenon in man. Horizontal section passing through the internal and external recti.

CE, CE, CE, CE (red), aponeurosis or external capsule forming sheath of muscles. CEP, CEP, deep layer of the sheath of the muscles folded backward upon itself to cover the posterior hemisphere. ADE, external ligamentous offshoot. ADIN, internal ligamentous offshoot. FS, FS, subconjunctival fascia.

CI (blue), internal capsule. CI′, internal capsule folded beneath the tendon and muscle to the point I. CI″, CI‴, internal capsule in front of the tendon and muscle which it covers up to the point I, where the offshoot leaves it; surrounding a serous bursa BS, BS, indicated by a blue dotted line; it then terminates anteriorly at the tendinous insertion I′.

DF, external rectus muscle. DI, internal rectus muscle.

Digitized by the College of Optometry

Digitized by Illinois College of Optometry

of Tenon than by the tendon, and that both in retro-placement and advancement of the muscle the most important factor is the fascia and especially its lateral prolongations.

The oculo-orbital fascia does not admit of a clear demonstration as a membrane; it is too complex in its ramifications, and too delicate in structure, besides being perforated by a multitude of organs. It ensheaths to a greater or less degree all the organs, muscles, vessels, nerves, etc., which pass through it. For example, the external sheath of the optic nerve is continuous with it, and it also adheres to the margin of the optic foramen. The periosteum of the orbit is continuous with it, and is sometimes spoken of as its parietal portion. But the analogy of the pleura in its visceral and pulmonary parts cannot be strictly maintained, although it is suggested. For practical purposes we are to bear in mind three facts: 1st, that the fascia serves as a cup, like the acetabulum, in which the globe revolves and makes enucleation possible without opening the deep parts of the orbit; 2d, that it prevents effusions in the orbit from easily finding their way into the lid, and beneath the ocular conjunctiva; 3d, that it constitutes a secondary attachment for the ocular muscles, renders their combined action more perfect, and makes it possible to sever their tendinous insertions without annulling their influence over the globe. A further remark is that the caruncle and semilunar fold are intimately connected with the fascia; and so is the tendon of the muscle of Horner, at the inner canthus, while at the outer canthus the external lateral ligament may be called a process thrown out from the periosteum. Gerlach further calls attention to the check which certain fibres exert over the action of the muscles, and at the inner side of the orbit the figure which he gives shows how firm is the connection between the fascia and the bony wall. Motais more clearly demonstrates and emphasizes these restraining bands, especially at the inner and outer margins of the orbit (see Plate II.). It is always somewhat difficult to lift the caruncle in a dissection, and if this is done at an operation it is liable to retract and cause an unpleasant appearance. This has a practical bearing on the operation for converging squint.

Advancement of the ocular muscles is called for in three different groups of cases—viz., when the duration of the optic axes is due, 1st, to an injury or an operation; 2d, to spontaneous dissociation from loss of sight in one or both eyes; 3d, to paralysis. In the first two the muscles retain a degree of contractility, in the last group there may be none at all.

Up to the present time I have made trial of many modes of operating, viz., those proposed by Critchett, by Agnew, by Weber, by Wecker, by Prince; and have modified them as circumstances demanded. I have finally come to a method which has nothing but

Digitized by Illinois College of Optometry

its simplicity to commend it and with which I am entirely contented. It is attended by very little reaction, which is far from being true of some other methods; it is exact and is capable of being graduated to a desired effect, whether this be large or small. The necessary instruments are a wire speculum, two pairs of strong fixation forceps, a good pair of scissors (Stevens pattern is the best), two strabismus hooks, a speculum, and three sutures of fine black strong silk with a curved needle at each end, and a needle-holder. The important thing is to have the needles fine, "half-curved," about ¾ inch long, and ground so sharp that they can as easily penetrate the cornea as a discission needle. On the fineness, sharpness, temper, and curve of the needles, success chiefly depends. Suppose the right rectus internus is to be advanced. The right rectus externus is first divided; then seize the insertion of the rectus internus with fixation forceps, taking a deep bite to include all that can be lifted; sever the insertion freely and cut above and below into the conjunctiva to the extent of 10 to 15 mm.; leave the forceps fast to the tissues by shutting the spring catch, lay it aside, and then remove a vertical oval of conjunctiva in front of the insertion, leaving a strip 6 mm. wide next the cornea (this step may be deferred to a later period, in some cases depending on the laxity of the conjunctiva). Lift the muscle and pass a curved needle from within outward at its middle and as far back as the proposed effect will demand. With the needle in place cut off superfluous material lying in front of it; then draw it through. Insert another needle in a similar way, and before drawing it through cut away superfluous material. Do the same with the third needle and cut off needless material as before. The object of cutting off redundant substance in successive parts as the needles are inserted is, to be certain not to sever the sutures. We now have three threads through muscle and fascia and conjunctiva. The needles at the other end of the threads are next to be passed forward beneath the remaining conjunctival strip, taking hold of the outer layer of the sclera so that the points emerge at the limbus corneæ; the middle one must first be fixed *in situ*. To get them through without breaking, they must be seized at the middle and pushed without any lever action. If the globe tends to rotate it may be steadied by a bident. I have seen the points sometimes appear in the anterior chamber, but this is of course too deep. What is essential is to have firm hold on the sclera. In tightening the threads begin with the middle, and care must be used not to pull too hard and to act first on one and then on another, deferring the second knot until each has been pulled up as far as it will bear without breaking. If there is much crumpling of tissue it must be cut away and the parts be left smooth—perhaps some additional and superficial stitches will be needed. I know of nothing more

Digitized by Google

simple than this proceeding. Its effectiveness depends on the firm hold obtained by piercing the sclera close to the cornea, and to this end the needles must be adapted. The stitches will remain from four to seven days. When the utmost effect is desired the externus of the fellow eye must be divided. A bandage is applied for twenty-four or forty-eight hours, and afterward cold-water compresses employed. It is rare to have chemosis or any important reaction. The degree of effect must be in excess of what will be ultimately required, because the eye will slip around some 5 or 10 degrees.

In case we have to do with an eye which has had a too liberal tenotomy as the cause of the deviation—the dissection of the muscle is more difficult, but the method is the same—I find no need of the hitching thread of Dr. Agnew, nor of the clamp forceps of Wecker, nor of the anchoring thread of Prince. The ordinary fixation forceps, aided sometimes by a second one, each having a spring catch, gives perfect control of the muscle. The operation on the rectus externus is much easier of execution than on the rectus internus. Strabismus hooks are used in exploration and as accessories, not as essential implements.

This mode of operating is especially, but not exclusively, suited to strabismus paralyticus, and hence is now described. Still other proceedings will be referred to, adapted to ordinary kinds of strabismus. Advancement does not confer contractility upon a totally paralyzed muscle, but simply gives the globe a more pleasing position. It may give rise to annoying diplopia, but this is usually temporary.

Congenital paralysis of ocular muscles sometimes demands relief, and its most frequent form involves the levator palpebræ superioris and the rectus superior together, causing ptosis and dropping of the eyes. I have seen excessive contraction of the inferior rectus drawing the axis of one eye far below the position of its fellow, while in both the above-mentioned paralysis existed. Usually both eyes are symmetrically affected. I have also seen congenital paralysis with contraction drawing one eye downward and outward, while the other was normal. Some cases are doubtless nuclear, while it has been shown that in some the muscles are not properly developed. Surgical relief is in some cases possible, in other cases quite unsatisfactory. If, as I have seen, the superior recti and the levatores palpebrarum are wholly incapable of action, only slight improvement and that of little value may be possible. If some power remains to the muscles there will be more encouragement.

SPASMS OF OCULAR MUSCLES, NYSTAGMUS.

An oscillatory movement of both eyes, quick and jerky, greater at some times and in some positions than in others, is the characteristic of this disease. In very rare cases one eye alone is affected.

Digitized by Harvard University

Such a case was reported by Dr. St. John to the New York Ophthalmological Society, in December, 1882. The condition is usually congenital. It is almost always associated with amblyopia, while it of necessity much impairs the available acuity of sight. We often find it with congenital cataract, both partial and total, also after ophthalmia neonatorum with central opacity of the corneæ; it is almost invariable in albinoes, and we see it in cases of extreme hyperopia, and sometimes with congenital choroiditis at the macula. Frequently there is convergent strabismus. The movement may be lateral, vertical, or rotatory, or all combined. I saw, by the kindness of Dr. H. W. Williams, of Boston, a man who had acquired the power of voluntary nystagmus after having been for some eye trouble confined for several weeks in a dark room. A form of nystagmus, lately noticed, affects individuals among high mountains, and especially those who work in mines. It comes in adult life, is most noticeable toward night, is periodic or paroxysmal, is induced by looking in certain directions, and apt to be attended with vertigo. Nystagmus among the English miners has been described by Oglesby, and is attributed to their unhealthy surroundings and the awkward posture of the head and the straining of their eyes upward as they work. By refraining from work some seem to get well, only to relapse on returning to the mines. Commonly the patients are not aware of the oscillations, except by the effect upon sight. The movement ceases during sleep. Rarely there is movement of the upper lid synchronous with the eye: this happens usually with vertical nystagmus. Some persons, despite this trouble, have highly useful vision. They are apt to be myopic, and distant vision is below the standard, but near work may be prosecuted with great success. In New York I have known two notable cases—one a distinguished musical composer and teacher, and the other a well-known practical chemist. Both of them were albinoes.

This condition is sometimes dependent on brain-lesions of recent occurrence. For example, it has been seen to follow blows on the head, also apoplexies, but with no definite localization, and in softening, as well as in hemorrhagic pachymeningitis. In some chronic brain diseases it has been noted, and the matter has been summed up by Robin ("Des Troubles Oculaires dans les Malad. de l'Encéphale," 1880). "Nystagmus, unilateral or double, permanent or temporary, exhibiting itself with other convulsive or with paralytic symptoms, indicates an encephalic lesion. In general this will be at the base or on the convexity behind the fissure of Sylvius (region of the angular gyrus). In the former case, it will often be complicated with paralysis of the motor nerves of the eye or of the optic; in the latter case (when on the convexity), there will be

Digitized by Boston College Library

epileptic attacks, hemiplegia, etc., but we cannot venture on any exact localization." Irritation of the peduncles has caused this symptom in experiments by Schiff. It occurs among the insane and the neurotic. It is very frequent in disseminated sclerosis of the brain and cord. With locomotor ataxy it is very rare. A not infrequent picture in a case of brain disease of the kind now noted, is the concurrence of rotation of the head, conjugate deviation of the eyes, and nystagmus; these phenomena evidently point to irritation of the region of the third and fourth ventricles. Nystagmus may be seen in cases of aphasia and of labio-glosso-laryngeal paralysis.

It thus becomes evident that, while most cases exhibit a complex causation, consisting both of defective sight and of irregular innervation of the muscles, other cases depend alone upon lesion of innervation of central origin. As to the former class of cases, it cannot be doubted that the irregular movements are, in very many, due simply to the want of motive for correct binocular fixation, *i.e.*, to lack of predominance of the macula lutea.

Treatment of these cases is of little service. For some the correction of optical errors, so far as it can be accomplished under the difficulties of the examination, is valuable. For those with strabismus convergens, tenotomy of one or both interni is advisable. I have done tenotomy of the interni when no strabismus existed, but because the lateral movements were excessive, and found benefit ensue. The degree of tremor was abated; but, as a rule, an operation is not fitting. Albinotic patients wear dark glasses, and preferably those with side-pieces to cut off the glare of light; and all nystagmic patients hold fine objects close, and have some choice position of the head in which their trouble is less annoying. Excitement greatly aggravates the tremor, and it usually remains unaltered through life. For an exhaustive study of nystagmus, see an article by Raehlmann: *Arch. für Oph.*, XXIV., 4, pp. 237–317. His conclusions tend to locate the cause of the disease in the brain, but at what region is undetermined. Another elaborate article is by R. P. Oglesby: *Brain*, vol. ii., July, 1880. (See Gowers, "Diseases of the Nervous System," 1888.)

A paper by Alfred Graefe (Bericht Siebenter Internat. Ophthalmologen Congress, 1888, Wiesbaden, p. 30) discusses cases of palsy of lateral movements with unimpaired convergence; that is, only the associated movements of interni and externi are abolished.

I have seen two cases of the affection of a chronic type; one was for four and a half months under observation. It seemed to point to a growth in the vicinity of the left abducens nucleus.

1882, May 6th. Henry R., aged 17, Brooklyn, ship carpenter; came to New York Eye and Ear Infirmary. Father living and healthy, mother died of cancer eighteen months ago. General health good, denies and has no signs of syphilis; never had much headache. Seven weeks ago, had diplopia on

median line and more noticeably on left side. Was treated by iodide of potassium and electricity. Now cannot bring either eye to median line, each turns to the right and stops about 10° to right of it: the head turned a little to right. On the left side has homonymous images, which implies that left externus is more faulty than right internus. It is found that right internus turns farther toward median line with effort of accommodation. On June 16th did tenotomy of right externus; this improved position to slight degree. On June 26th tenotomy of left internus, but eyes could not be moved beyond median line. Meanwhile electricity and full doses of iodide of potassium were kept up. Vision from the beginning normal in O.D. and $\frac{20}{30}$ in O.S. The temporal halves of each nerve look suspiciously white. July 7th, upper lid of left eye does not readily shut (suggests indication of facial nucleus which is near nucleus of sixth nerve) and sleep became bad; no headache. Begins to be light-headed; walks well with closed lids. On July 14th was sick at stomach after drinking ice water; after a week again felt perfectly well. Sept. 15th has almost complete facial palsy of left side; movement of left eye up and down is free, but lateral movement outward extremely limited. Right eye moves well, up and down, but cannot reach median line, and excursion to its temporal side is limited. Head trembles, gait frequently unsteady; sometimes is dizzy; no other symptom. Not seen after this date. Diagnosis is tumor in left side of pons, involving nucleus of sixth and later of seventh nerves. Patient was seen by Dr. Allan McLane Hamilton, who concurred in this opinion.

I have seen a child 2½ years old with somewhat similar conditions. In the beginning, after fever and vomiting, the eyes were turned upward for two days and then settled down to the lateral dextral deviation and were parallel, although capable of convergence. She had enlarged lymphatic glands in the neck and face. I saw her for only a short time and know nothing of the ultimate issue.

I witnessed the autopsy of a man 40 years old who had this symptom and who was under care of Dr. Janeway. He entered Bellevue Hospital unconscious; both eyes and the head were turned to the right. He was humpbacked. At the autopsy the lesions found were abundant small tubercular deposits over the whole surface of the brain and more numerous at its base; acute meningitis of orbital surfaces of both frontal lobes and each in equal degree. Tubercles numerous on under surface of cerebellum and along spinal cord; the bodies of the vertebræ absorbed. Brain congested and œdematous, not soft, no apoplexies, nothing in ventricles nor in pons or in fourth ventricle. All the lesions were on the surface and mostly basal and anterior. During life no choked discs. Such a case resembles more the epileptoid cases than those with distinct focal lesions.

Digitized by Illinois College of Optometry

CHAPTER IX.

STRABISMUS CONCOMITANS.

THIS term denotes a condition in which either eye can fix upon an object in all parts of the field, but binocular fixation fails. The defect is not in the motility of each eye singly, but in the lack of co-ordinating power with its fellow. Associated movements are performed, but the deviation between the visual lines is always maintained, although its degree may vary according to the distance and position of the object. Sometimes binocular fixation is possible for extreme distance, but is lost when the object approaches. In strabismus paralyticus the essence of the lesion is loss of power, while in strabismus concomitans the muscular activity is perverted, not materially diminished. Again double vision is exceptional in strabismus, and is the rule in paralysis for certain parts of the field.

Strabismus is either permanent or occasional; it sometimes is truly intermittent. It increases as the object approaches, that is, with efforts of accommodation, and, as said, it may only then appear. This is always characteristic of converging strabismus, while with diverging strabismus the rule does not always hold good.

According to the direction of the deviation we have S. convergens, S. divergens, S. sursum-vergens (upward), S. deorsum-vergens (downward). With converging squint the eye often turns up as well as inward. The affection is usually bilateral (concomitant), sometimes it is confined to one eye and is monolateral. Sometimes with bilateral squint the person will fix indifferently with either eye; more frequently one is preferred to the other, and it may even be impossible to employ the eye which habitually deviates, for more than a few minutes. Of course with monolateral squint the deviating eye never voluntarily fixes and often cannot fix accurately and centrally.

To decide between monolateral and alternating squint, a screen or the hand is placed obliquely over one eye, and while the other looks at the finger held near it, we note the behavior of the covered eye; by trying each eye in succession we discover whether one or both is distorted. Frequently the angle of deviation is greater in one than in the other. It must be admitted that in ordinary squint, especially converging, there will be some limitation in mobility, but this is far less considerable than in paralysis. Patients are often distressingly conscious of paralysis, usually they give little attention to subjective symptoms in strabismus.

Digitized by Illinois College of Optometry

Measurement of the degree of strabismus has been made by instruments which give the amount of turning in millimeters or lines along the border of the lower lid. This is of course very inexact, and the only correct method is in terms of angles. To do this with precision one may, as Landolt suggests, use the perimeter. Place the squinting eye in front of the centre of the arc, let the other fix an object at ten or more feet distance nearly on the line of the centre of the arc—then carry a small flame along the arc until it shall be reflected from the summit of the deviating cornea and read off the angle on the perimeter. If the eye deviates so far inward as to be behind the nose, a prism with angle inward may be interposed and half of its angle added to the number of degrees given by the perimeter.

Another and simpler way given by Hirschberg is that the observer sit facing the patient and hold a lighted candle about one foot in front of him, screening his own eye from the light. From each eye is seen the reflex of the flame on the cornea. The eye at the centre of whose pupil the reflex appears is the one which fixes —on the other cornea the reflex is eccentric. Its place may vary as the patient gazes at the candle or afar off. The point at which the reflex appears will give a measure of the angle of the squint, and five degrees may be distinguished if the pupil be supposed to be 3.5 mm. in diameter. If the reflex be only a little way removed from the centre, *i.e.*, about half way to the pupillary edge, the deviation will be less than 10° (varying with the angle alpha as will be explained). If at the pupillary edge, the angle will be 12° to 15°. If at a point about midway between the pupillary edge and limbus, the deviation will be about 25°. If at the edge of the cornea, the quantity will be 45° to 50°. If outside the cornea, the reflex will be blurred or multiple and the angle may reach 60° to 80°.

With normal fixation of both eyes, there may seem to be divergence, if the corneal axes lie to the outer side of the visual lines—that is, if the angle gamma is large (see page 15) and positive. On the other hand, if the corneal axis lie to the inner side of the visual line, which occurs in high degrees of myopia, there will be an appearance of convergence. In these cases the angle (gamma) is unusually large and in the first instance is positive, in the second is negative.

(The angle in question is really formed between the *axis of the cornea* and the *line of fixation*, which passes through the centre of rotation of the globe and is not identical with the visual line. This is the angle gamma. The angle formed between the *axis of the cornea* and the *visual line* is the angle alpha. Donders speaks of the latter and when his treatise was written the above distinction was not made.—Woinow.)

Digitized by Illinois College of Optometry

To determine the error in terms of angles both Hirchberg and Landolt have constructed diagrams to be hung on the wall, in which vertical and horizontal lines are drawn at the distances corresponding to the tangents of angles from 5° to 60°.

Priestley Smith achieves the same result by the ophthalmoscopic mirror and a tape measure. The light is put above the patient's head. He holds one end of a tape line one metre long against the cheek below the sound eye. The observer sits in front and the tape is held tense by a ring through which is slipped the handle of the ophthalmoscope. The good eye fixes on the mirror and the observer notes the position of the corneal reflex, which should be near the centre of the pupil. The light is shifted to the other eye and the position of the reflex on its cornea noted. The patient is directed to follow the finger of the observer's free hand as it passes outward until the corneal reflex on the squinting eye occupies the same position in the pupil that it did on the fixing eye when it looked at the mirror. The distance between mirror and finger is the tangent of the angle of deviation, and is denoted by figures on another tape of which one end is fast to the ring on the handle of the ophthalmoscope and which slips through the fingers of the moving hand.

A tolerably precise mode of detecting deviations of the ocular axes, or lack of fixation by one eye, is furnished by the ophthalmoscopic mirror. Priestley Smith draws attention to it (*Ophthalmic Review*, Feb., 1892), but most experienced observers have probably employed it. The patient looks at the mirror or at the observer's forehead; the place of the corneal reflex within the illuminated pupil is noted; without any change of the position of the observer or of the patient, the mirror is rotated to the other eye, and the place occupied by the reflex within that pupillary area is noted; the light is quickly flashed from one eye to the other, and a comparison of the relative situations of the corneal reflex will soon determine whether both eyes are fixing on the same point. Normally the reflex is a little nearer the inner edge of the pupil than the outer edge, because the line of fixation does not coincide with the axis of the cornea (*vide supra*). A markedly non-symmetrical position of the two reflexes denotes failure to fix on the same point. If the discrepancy remains always the same and affects each eye alternately we may conclude that while both eyes do not fix on the same point each has the power of fixation, but fusion is absent. If however one eye fixes correctly when the patient is told to look at the light, and the other persistently deviates in spite of the urgency to fix the light, we conclude that there is extremely defective sight in the wandering eye (probably a central scotoma) and that binocular correct fixation will be impossible, even by operation and other means.

Etiology.—It has already been remarked that we are to look for the effective cause of functional strabismus, in errors of sight and not primarily in lesion of the muscles. The errors are those both of refraction and of perception. That the muscles themselves have a part to perform in causation must also be recognized. Their influence was formerly exaggerated, it has until lately been unduly depreciated.

That hypermetropia is found in three-fourths of the cases of strabismus convergens, was one of the brilliant facts made known by Donders. He set forth what is now so well understood, that increased convergence makes augmentation of accommodation more easy. If in a case of hypermetropia the renunciation of binocular

sight were a lesser ill, than the strain on the accommodation with binocular sight, then converging squint would follow. This would take place when the two eyes differed greatly in refraction, if one were highly astigmatic, or if in one there were opacity of the cornea or lens, or if in one there were great amblyopia. Again Donders took into the category of causes decided weakness of the recti externi. Such are some of the conditions which caused him to say that hypermetropia is the dominant and sufficient cause of strabismus convergens. On the other hand he also showed that strabismus divergens is in the large proportion of cases associated with myopia. The cause here lies in the inability to maintain the needful convergence for a very near point, and such is largely the true explanation.

That hypermetropia does stand related to strabismus convergens in a most intimate way is indubitable. That the connection is so simple as Donders' theory makes it, is not now accepted. The difficulty lies in the fact that a large number of hypermetropes, even when their eyes are unequally erroneous, do not squint. The number of those who do not squint is far higher than of those who do. Still more must we study the question with care when it is remembered that converging strabismus belongs chiefly to the early age of life, and that at this time it is almost the absolute rule to have hypermetropia. It is also true that hyperopics learn to accommodate with small effort of convergence. Why in some of them convergence should so far go ahead of accommodation, remains to be explained. It is admitted that the strabismic cases are not found chiefly among the strongly hyperopic, but among those who have medium and slight degrees. Donders assumed that the greatly hyperopic patients see so badly that they give up the effort to improve their vision. But we do find them converging very strongly in trying to see as well as possible.

Defects of perception have been mentioned. Monocular amblyopia is very common in strabismus convergens and not infrequent in S. divergens. This may or may not be associated with high degrees of hyperopia or with astigmatism, possibly irregular. We meet with it where the degree of ametropia differs little from that of the eye with good vision, and in a very large proportion, perhaps in the majority of cases, no lesion can be found with the ophthalmoscope. On this point it is important to bestow careful attention. No small number of cases exhibit what are evidently congenital abnormities in the papilla. In my records are such conditions as follows: An extraordinary amount of pigment deposit along the border; the presence of connective tissue on edge of nerve and running along the vessels (not to be confounded with opaque nerve fibres); a dull or slaty-colored and opaque disc with hazy edges; extreme hyperæmia both of capillaries and veins; the nerve swollen as in papillitis,

Digitized by Google

a dark gray or slaty spot upon the disc and the rest of the surface an opaque white; coloboma of the sheath of the nerve or a very deep and irregular excavation which was so interpreted. Besides, one must carefully scrutinize the macula and it must be done with dilated pupil. Not rarely will one find minute specks, white, yellow or glistening, clustered here, which indicate lesion either of the choroid or retina. There may be one or more marked pigment specks which will denote a previous inflammatory lesion. A notable number of cases, and the majority, will not reveal any visible lesion. In the examination of the visual field we are often prevented from attaining exact knowledge by the extreme youth of the subjects. When, however, they are sufficiently intelligent, we frequently find that the amblyopia is central and a defined scotoma for red may be sometimes mapped out, provided a small card 5 mm. square and dim light be employed. The scotoma may be very small and will be better discovered on a dark plane surface than by the perimeter. It may often be detected by the fact that out of a row of letters at 20′, say the line O H S U E or 0.3, the S pointed out by the physician's finger is less clearly seen than the adjacent letters on either side. Sometimes a patient will say that over a small space, not the blind spot of Mariotte, a small candle flame is not perceived. This means a small absolute scotoma. In one case I found nasal (medial) amblyopia with the line of demarcation vertical. It was not difficult to show the decided difference in perceptive power of the respective halves of the retina—this might be called hemiamblyopia. It was of course natural for this patient to have converging strabismus because then the better half of the retina was put to use.

The amblyopia of strabismus has been attributed to non-employment of the squinting eye, and amblyopia ex anopsia is often set down as a sufficient statement of the facts. The exclusive use of one eye does not in monocular cataract nor in extreme monocular astigmatism bring about amblyopia. Neither could disuse occasion a central or localized scotoma, neither could a clearly defined hemiamblyopia which corresponded exactly to the fasciculus non-cruciatus of the optic tract, be caused merely by disuse. In truth this assumption rests upon no evidence. On the other hand, congenital amblyopia is not at all rare; witness its frequency in congenital cataract. Neither is congenital monocular amblyopia rare. On this point Schweigger's[1] statistics are eminently forcible, page 91. He collected ninety-eight cases of congenital amblyopia who did not squint. There were all possible refractive errors in every possible combination; in some, one eye was normal, and the other amblyopic. Out of them 47% were hypermetropic —yet none of these patients squinted. On the other hand (pp.

[1] "Klinische Untersuchungen über das Schielen." Berlin. 1881.

Digitized by the Internet Archive of Ophthalmology

99, 100 l. c.), out of 247 cases of strabismus both converging and a few of diverging, which were at the same time hyperopic, he sets apart as amblyopic, those whose vision is less than $\frac{1}{7}$ and they are 87, that is, 35.2% of the whole. He also divides these cases of hyperopic squint into two classes, viz.: those in whom H is less than $\frac{1}{14} = 1.77$, and those in whom it is above $\frac{1}{13}$, *i.e.*, 3 D = 70. In these two classes the chosen degree of amblyopia, viz., v = $\frac{1}{7}$ and less, exists in the first in 31.6% and in the second in 44.2%. This increase in the ratio of amblyopia with the increase of the degree of hyperopia points unerringly to the dependence of amblyopia upon congenital defect and not upon disuse.

My own attention has been carefully given to this question and I have on record a very large number of hyperopics who have monocular amblyopia and have never had squint. They at the same time have adequate muscles and binocular vision. The same is true of astigmatics, and my conviction is settled, that amblyopia is, with very few exceptions, precedent to squint and is not its effect.[1]

In a limited sense disuse operates unfavorably upon visual acuity. The power of fixation is much impaired, there is imperfect control of the accommodation (I have the record of one unmistakable case of severe monocular spasm of accommodation in converging squint) and the retina is easily fatigued. Perhaps the temporary scotomata and limitations which Wilbrand describes in asthenopia (l. c.) also occur. These conditions are readily admitted and they account for some of the feebleness and for the variability in the visual acuity. Beyond this degree, amblyopia ex anopsia has no proof to rest upon and it cannot be accepted as an explanation. With this opinion, which Schweigger first forcibly enunciated, agree Alfred Graefe, Ulrich, Segger, Landolt, Wadsworth and others. It therefore follows that amblyopia congenita is entitled to a place alongside of hypermetropia in the production of converging squint. But while the proportion of H in squint is about 75% excluding those less than 2 D, the remaining 25% must be accounted for by other causes. And we have seen that the great number of hyperopics do not squint, hence still another factor besides refractive error and amblyopia must be found. This evidently lies in the condition of the muscles. To this point Schell,[2] Ulrich[3] and Segger[4] have given attention. Schell studied the ratio of abduction to adduction in a

[1] See Wadsworth, "The Amblyopia of Squint," Boston Medical and Surgical Journal, Jan. 20, 1887.

[2] "Cause and Prevention of Squint." Amer. Journ. Med. Sci., Oct., 1878, p. 418.

[3] "Zur Aetiologie des Strabismus convergens." Klin. Monatsblätter, xviii., 156. 1880. "Die Aetiologie des Strabismus convergens hypermetropicus," Kassel, 1881.

[4] "Statistischer und Casuistischer Beitrag zur Aetiologie des Strab. convers." Klin. Monatsblätter, xviii., 439, 1880.

Digitized by the Internet Archive

small number of cases of emmetropia and hypermetropia. For 20 cases of E he found abduction was to adduction in the ratio of 28 to 100; while in 16 cases of H he found the ratio to be 48 to 100. The hyperopic cases did not squint. And the reason which Schell assigned was the relatively high capacity for abduction which they possessed. The contrary condition he assumed would favor the production of squint. Ulrich and Segger agree in the same view. Ulrich (l. c., p. 26) puts the ratio between abduction for 10 inches (M. 0.25) and abduction for 6 M. (parallelism) in E at 1 : 5.7, in hyperopia at 1 :.3 That is in hyperopia, abduction in the relations in which he compares it, is nearly twice as strong as in emmetropia, among those who do not squint. The results of Schell and Ulrich correspond with sufficient accuracy. With these three factors, viz., hyperopia, amblyopia and inadequate abduction, we have the combination which suffices to explain the larger number of cases of strabismus convergens. We may also include among them the cases of monocular ametropia, or opacity of the cornea and monocular cataract. Even when the vision of each eye is good we meet with converging squint, and in these cases we may assume that the abduction has been abnormally weak. Such for instance is the explanation of many cases in whom we are told that the error came after scarlet fever, measles, or diphtheria, etc., or after an attack of acute inflammation of the eyes with blepharospasm. The assumption that it was produced by imitation of a squinting person, or by looking at a bright light, or a hanging lock of hair, etc., is of doubtful value, but need not be rejected as absolutely worthless provided other conditions concurred.

Something must be said as to the phenomena of vision in persons who squint. That they do not complain of double images is not surprising when there is decided monolateral amblyopia—neither is it surprising after the full establishment of the deviation, even when both eyes have tolerably good vision, say better than $\frac{1}{3}$. But it is not true that in converging squint they make no use of the deviating eye in conjunction with the other. Schweigger showed that they can always perceive the light of a candle if reflected into it by a small mirror placed beside the nose; a slip of plane glass will suffice. While ordinary binocular vision is of course impossible, there is by help of the faulty eye enlargement of the field, and in some cases it is proven that a real co-ordination between the two eyes is established by which the macula of the sound eye is coupled with some other spot of the retina of the deviating eye, which takes on the usual functions of the macula. In these cases prisms with the angle vertical, placed over the squinting eye cause diplopia, by the stereoscope the two figures are combined, and if by tenotomy the deviation be corrected, there may be crossed diplopia notwithstand-

Digitized by Illinois College of Optometry

ing the ocular axes are in correct position. These are very puzzling facts in the physiology of vision. On the other hand if vision of the two eyes be nearly equal, the beginning of strabismus is attended with diplopia or there is a conflict in the impression of the two eyes which leads to the mental suppression of one image. This act of mental exclusion is familiar to microscopists and watchmakers, and it can be more or less perfectly realized in strabismus. This is the only explanation which can be offered of certain cases and it is not inconsistent with remarks before made, to assume that the mental impression of one eye becomes habitually weakened and in this sense vision may be said to be impaired by disuse. Some strabismic patients have double images when they give attention to both eyes. In most, it is very difficult to excite them. An oblique posture of the head is common with converging squint and it may persist after an operation. Some persons who use each eye alternately will employ the right for objects on the left side, and the left eye for objects on the right side, and change the obliquity of the head correspondingly. In doing this they evidently favor the weak externi. A distinct tremor when the eye turns in the direction of the weak muscles is not uncommon, it may be a real nystagmus and it may be monolateral. It is not infrequent to find symptoms of asthenopia, and these may be of a pronounced type, in some cases attended by photophobia. Fatigue in eye work is very common. Many interesting questions arise in connection with the vision of persons having strabismus, and for their discussion the reader is referred to the authorities quoted by Alfred Graefe in Graefe and Saemisch, "Handbuch," B. VI., p. 242, and to authorities quoted by Landolt, article Strabismus, "Dictionnaire encyclopédique des sciences médicales," Dr. Dechambre, which is brought down to 1882. Von Graefe, Donders, Javal and Alfred Graefe have especially interested themselves in this matter.

Course of Strabismus.—Beginning usually at the time when steadfast application begins, it at first is occasional, and months, or years, generally elapse before it becomes permanent. It may show itself in rare cases at birth or under one year of age, generally it appears at two to six years. That it can occur in later life has been remarked. It may spontaneously disappear and this not exclusively in cases whose degree is small. Binocular vision is not established and critical examination may discover that there has been only a great abatement of the fault, not its complete disappearance. Usually the deviation lasts many years, and the rule is that when once established it permanently remains. We have no information upon the anatomical condition of the muscles in permanent strabismus and it is desirable to fill this void. That the contracted and the enfeebled muscles undergo organic changes of

Digitized by Harvard College Library

tissue is extremely likely. It is often found in operating that the muscles seem rigid as well as hypertrophied—but inasmuch as we come in relation only with the tendon we usually discover nothing of the status of the muscle itself.

The remarks hitherto made apply chiefly to strabismus convergens. Schweigger gives the following statistics as to the refraction. He classifies the cases according to the refraction of the fixing eye, and mentions, but does not specify, anisometropia among them.

	Permanent Strab. conv.	Periodic Strab. conv.	
Emmetropia,	85	13	
Myopia,	44	10	
Hyperopia,	196	98	
	325	121	446

	Permanent Strab. divergens.	Periodic Strab. divergens.	
Emmetropia,	37	28	
Myopia,	59	50	
Hyperopia,	4	5	
	100	83	183
			629

Out of Horner's clinic Isler[1] collected 369 cases of strabismus.

Strabismus convergens 236;		Strabismus divergens 133	
Emmetropia,	4	Emmetropia,	3
Myopia,	11	Myopia,	62
Antimetropia,	13	Antimetropia,	30
Hyperopia,	208	Hyperopia,	38
	236		133

In Isler's statistics the ratio of hyperopia is higher than in Schweigger's, because he not only takes in H less than 2 D which Schweigger excludes, but he comprises latent as well as manifest H. The discrepancy in regard to the ratio of E is partly explained by the fact that Schweigger's classification is based only on the fixing eye. He finds a higher ratio of myopia in converging squint than does Isler, viz., 8.6%, as against 4.6%. It is, however, very noteworthy that myopia takes the first rank in the causation of diverging strabismus. Schweigger gives 59.5% and Isler, when the cases of anisometropia of which one eye was myopic (l. c., p. 28) are added to those of myopia, viz., $22 + 62 = 84$, gives 63.1% to myopia. In the latter's

[1] "Studien über die Abhängigkeit des Strabismus von Refraction." Inaug. Dissert., Zurich, 1880, Walter Isler.

Digitized by the Internet Archive of Optometry

statistics an unusually high proportion of cases of hyperopia is found among diverging strabismus, viz., 28.6%. These are mostly of moderate degree, each eye usually had good vision, and the cause was found in weakness of the interni. In some cases this ensued after the occurrence of debilitating diseases, in other cases the weakness was inherent and original.

Another class of cases is those in which one eye is so nearly blind that it wanders outward simply in obedience to the tendency impressed upon it by the outward direction of the axis of the orbit. Here, too, there may be latent weakness of the interni. Divergent, begins at a later period of life than convergent squint—when the latter is connected with myopia it is usually of high degree. It may be alternating, but usually the patient gives the preference to one eye. Very often there is marked irregularity in vision or in refraction. The tendency of myopia to divergence is caused by the high degree of convergence required for near vision and by the absence of impulse to accommodation to aid it—a situation which is the exact reverse of what obtains in converging strabismus with hypermetropia. In both classes of cases there must coexist a lack of power in either the externi or the interni to render the deformity possible, while refractive conditions play a rôle which has been sufficiently explained.

Treatment.—In the incipient stage of converging strabismus we may sometimes prevent its establishment by employing the glasses needful for correcting ametropia. Serious amblyopia will be a hinderance to success and when the subjects are very young there are obvious objections to their use from the danger of accidents by breakage. But when in the house, young children can wear spectacles and, when at active out-door play there is less tendency to close convergence. It has been proposed to use eserine sulphate to assist the accommodation (Ulrich) and take off strain on the interni and to resort to this when glasses cannot be worn. On the other hand, the entire suspension of accommodation by atropia has been much recommended and employed from precisely the opposite indication, viz., to relieve the interni by abolishing the accommodation. A degree of benefit can be gained by this proceeding, but no permanent gain without using the needful correcting glasses. The resort to atropine from time to time as the tendency to squint becomes more pronounced, while the patient is habitually wearing correcting glasses will not seldom prevent the establishment of the error. It is decidedly worthy of trial because the externi are strengthened and the habit of binocular vision is promoted. When this is not feasible, and a patient shows a decided tendency to prefer one eye in fixation—this may for some hours daily be tied up (screening it by a shade will not serve the purpose)

Digitized by the College of Physicians of Philadelphia

in order to compel the use of the other. By so doing the muscles of that eye are kept in better training, although the covered eye continues to squint. The use of the poorer eye to improve its vision is a pious hope rather than an assured expectation—notwithstanding the contrary opinion largely prevails. Any other treatment than tenotomy is of little value after a permanent squint has been produced.

In diverging strabismus, associated with myopia, the greatest assistance is to be derived from proper concave glasses, to be employed both for near and distant work. They should be chosen with reference to the degree of myopia and to the accommodation of the subject and to the distance of the working point. Very often they will be one-half or one-third less strong than the glasses required for the far-point. The rules for this have already been discussed. The use of glasses by young myopic persons includes this very important advantage, that control over the recti interni is greatly aided. This suggestion is also applicable to cases of great dissimilarity in the degree of myopia of the two eyes even when one of them may not admit of the glass which its refraction indicates, and the correction is applied only to the better eye.

Atropine has less efficacy in these cases than in those previously considered. In incipient divergence not only are glasses to correct ametropia important, but they can often be usefully combined with prisms. Whatever relieves the strain on the interni at the near-point, is to be adopted. The subjects are usually old enough to permit a satisfactory examination, which with convergent squint is often impossible. In the large majority of cases of convergence and in many of divergence we must resort to an operation.

The operative treatment has in view not only the correction of deformity, but the improvement of the working ability of the eyes, and if possible the procurement of binocular vision. We practise tenotomy upon the contracted muscle to abate its power and we advance the insertion of the weaker muscle to increase its power. The former is the most frequently employed, while the latter is in certain cases combined with it. A practical question arises in converging squint, how early in life shall tenotomy be practised? If the deformity is not large it is better not to operate until five to seven years of age. But if the squint be pronounced, a tenotomy at an earlier age may be indicated to keep the muscles in better balance, but its effect will not be complete and it should not be done except as a palliative measure. At a latter period another operation is likely to be needful. Should one eye be operated on or both? Graefe taught the importance of dividing the effect between both eyes, but since his time some have advocated going back to the practice of early times and confining the proceeding to the eye

Digitized by the College of Physicians

which deviates most. As a matter of fact, in marked deviations the muscles of both eyes are at fault and I have no hesitation in saying that each eye should in such cases be operated on. For a deviation of 3 to 5 mm., 5° to 15°, only one eye is to be operated on; for 5 to 6 mm., 15° to 30°, both will require it, but there should be two weeks interval before the second operation; for squint of 10 mm., 30° to 45°, both may be dealt with at the same sitting. It may be assumed that one tenotomy will effect a change of about 3 mm., or about 15°. An absolute result cannot be predicted because the elasticity of the opponent is variable, and we find the ultimate position frequently not the same as that which appeared after the first week. Inasmuch as the patients especially seek an improvement in their personal appearance, the rule is to leave a slight degree of convergence rather than to risk the slightest amount of divergence. If there be fairly good vision in both eyes and if there be hyperopia of 3 D or more, we may put considerable confidence in the tendency of the eyes to a correct position. In such cases the effort is to establish binocular vision, and if there be a divergence of 1 or 2 mm. this will usually not be permanent. It is not, however, to be assumed that a free dissection of the tendon is to be allowed. This was the method at the first introduction of strabotomy by Dieffenbach, and from the unwise practice of that day came a large crop of cases who needed a subsequent and serious operation to correct the divergence. Such cases are occasionally met with at the present time.

The operation is as follows: For young subjects ether may have to be given, for older ones instillation of 4% solution of salicylate or hydrochlorate of cocaine three times within twenty minutes will suitably benumb the tissues. The local anæsthetic is much to be preferred, because we need the aid of the patient to enable us to decide how much has been accomplished. The lids are separated by the spring speculum; for converging squint the eye is *pushed* to the outer angle by a fixation forceps which seizes the conjunctiva near the outer border of the cornea and if the forceps be rather heavy it may be left to hang and its weight will keep the eye in position. Employ forceps with a stiff spring whose teeth project well forward, take up the conjunctiva and tendon at the latter's insertion and snip it with slender scissors whose points are a little rounded. The wound must be small and vertical and at the middle of the tendon. If an opening has been made through the tendon the slender scissors may be slipped astride the lower and upper portions of the tendon in succession and accomplish most of the cutting. The rest of the insertion may be caught up by the hooks and divided. If the tendon has not been opened, the forceps will be thrust through the conjunctival opening to seize it and be followed by the scissors. The sharp projecting teeth are designed for this

Digitized by the Internet Archive of Canada

purpose (see Fig. 78). Snip through the tendon and passing through the hole a small blunt hook catch the upper half of the insertion. Keep the scissors flat on the sclera and cut at the insertion. Keep hold of the tissues by the hook and insert a second hook under the undivided lower half of the tendon and cut it. Then examine above and below whether the whole insertion has been separated from the sclera. The cutting is partly subconjunctival and partly visible in the wound. A little barb on the blunt point of the hooks materially facilitates the search for undivided fibres and gives greater hold to the hook (Theobald) (see Fig. 77). The conjunctival wound will unavoidably be stretched by these manœuvres, and some blood will be effused beneath the tissues. It is a disadvantage to have a large thrombus because it increases the effect and renders the operation less certain. In putting the hook under the tendon carry the beak straight back and keep the tip upon the sclera as it is rotated either upward or downward. When it is well engaged the handle is carried across the root of the nose and the tendon pushed into view. Now the tendon is cut between the hook and the sclera and of course it is not shortened, but is only detached.

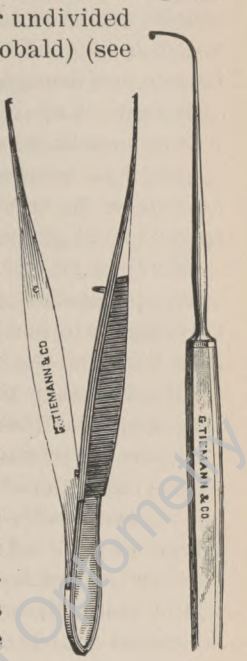

FIG. 77. FIG. 78.

There are other methods of operating. Some make the incision of the conjunctiva below and parallel to the edge of the muscle. Graefe advised making it close to the cornea. Arlt uses scissors alone to divide the muscle without the help of the hook. For myself the method described secures the complete division of the tendon with the least disturbance of the structures and through the smallest wounds. The conjunctival wound is always united by a stitch of very fine black silk. The bleeding is to be wiped away with absorbent cotton. Sponges are objectionable unless very fine and soaked in corrosive sublimate solution 1:2,000. It is better to use salicylated absorbent cotton. Before putting in the stitch the effect of the operation is to be ascertained. The associated movements should be well performed, and if the desired effect is apparently reached, the patient should be able to converge easily to a point five inches distant. If sufficient effect is not secured, incisions may be made above and below the insertion into the capsule of Tenon. To dissect the conjunctiva more freely away from the outer surface of the muscle by undermining the caruncle will also increase the effect, but at the expense of an unpleasant retraction of the caruncle.

Digitized by the College of Optometry

Another mode of increasing the effect is to gather up a fold of the conjunctiva on the other side of the globe in a large suture (Knapp). Better than this, is to attach a suture to the conjunctiva on the outer side of the globe near the cornea and carry both ends through the skin beyond the outer canthus and tie them over a bit of stick. Such a guy will put the globe into any desired position. The thread must not be left more than five or six hours and both eyes must be well bandaged to prevent pain. I have seldom resorted to these sutures. To restrain the operative effect, a stitch may be carried to a greater or less depth into the divided muscle and brought out near the cornea horizontally, or in an oblique direction. A change of 2 mm. is easily obtained. In rare cases when I have sought to slightly increase the effect and the conjunctival wound has been small I have altogether omitted the suture. To do this, is to risk undesirable retraction of the caruncle and the sprouting of granulations in the wound.

Sinking of the caruncle is liable to occur in slight degree even after operations carefully done. It comes as a gradual result of contraction of the cicatricial connective tissue, and depends upon the degree to which the oculo-orbital fascia has been invaded and loosened.

It is always proper to lay upon the usually squinting eye the larger effect of the operation. If the deviation is chiefly monolateral, one may combine tenotomy of the internus with advancement of the externus of the same eye. If this do not suffice, tenotomy of the internus of the other eye may be done at a later time. The advisability of advancement may be estimated by the capacity of the eye to turn toward the outer canthus. In marked monolateral squint this will be feeble and the externus will have been so much stretched that it cannot pull the eye around even when the internus is loosened. In one case of this kind where one eye had slight myopia and the other an extreme degree, notwithstanding a good position of the axes was obtained, it could only be held by wearing full correcting glasses and practising daily with prisms for three months. Wecker has recently advocated what he calls advancement of Tenon's capsule at the insertion of the antagonist, as an adjuvant to tenotomy. The operation consists in bringing forward the inclosing sheath and connective tissue as one would do in certain modes of advancement of the tendon (see chapter on Asthenopia), but the tendon is not loosened. A well and neatly conducted advancement seems to me is to be preferred. As a matter of fact the chief element in tenotomy as well as in advancement, is the altered tension and attachments of the sheath and capsule—combined with loosening the insertion of the muscle.

The ultimate result of an operation is apt to be greater than that which exists after two or three weeks.

Digitized by Microsoft Corporation

For ordinary cases very simple after treatment suffices, the eyes are bandaged for twelve hours and then cold or warm water applied as the patient prefers. The conjunctival stitch may be taken out in two days or, if left to itself, it will drop out in a week and it causes no appreciable irritation. Subconjunctival ecchymosis will remain for ten days. If granulation spring up, it must be cut off with scissors, not touched with caustic.

For diverging strabismus the mode of operating is essentially the same, but the tendon of the externus is 7 to 8 mm. from the cornea, while that of the internus is 6 mm. The effect of the tenotomy is usually adequate in simple cases of myopia, but in emmetropia and hyperopia it is less than ordinary. Advancement of one or both interni may be advisable in extreme cases, or a tenotomy may be done the second time. For a young lady on whom I had done two tenotomies of each external rectus without a perfect cure, the result was obtained by causing her to practise daily with adductive prisms to the utmost of her ability. She had good vision, and was emmetropic in each eye. She gradually improved in power of adduction and on one occasion felt something snap in one eye, after which she acquired a sufficient power of convergence and has always retained it. A suggestion of Dr. Gruening has proved of great value in considerable degrees of divergence when no paralysis exists. After dividing one or both externi, the two eyes are coupled together by a suture which is attached to the inner side of the globe and carried across the nose. It takes its hold on the conjunctiva vertically near the cornea, and when tied, both eyes are held immovable and in convergence. It is left *in situ* for twelve or twenty-four hours. Care must be used to get no more effect than is required. An excess of 10° or 15° convergence at the beginning is desirable, for this amount soon disappears. With extreme divergence Dr. G. shortens the tendons of the externi.

Hardly less important than a correct operation is the subsequent management of the eyes. As soon as the reaction has disappeared, say within four to six days, the propriety of using glasses must be decided.

If there be much hyperopia and the externi are weak, not only should glasses be worn, but possibly it will be needful to resort to atropine. In other cases only the manifest H will need correction. If there be tendency to over-effect, then no glasses are to be given. Of course, astigmatism is to be corrected. Sometimes practice with prisms and a candle flame, or the use of the stereoscope will aid in confirming correct attitude of the eyes. Very many patients can be made to see two images after an operation who found the greatest difficulty in doing it before, and they can be taught to closely approximate or to fuse them. Special test cards must be provided for practice with the stereoscope, viz.: on one side a vertical and on

the other a horizontal line, or on one side a dot and on the other dots in horizontal series which are to be numbered, or on one side a capital L and on the other a capital F, which combined make E (Green) or other similar devices by which it will be certain that each eye sees and takes a correct position. With the usual stereoscopic pictures there can be little assurance that proper vision is being practised. Of course such exercises require intelligence, the subject must not be too young and vision must have a certain acuity. Javal employs an ingenious reflecting stereoscope which admits of variation in the angle of reflection and consequently of convergence.

Mechanism of the Operation and its Ultimate Results.—There is a notable lack of accurate and well ascertained information on this subject. With patients the object sought is cosmetic, and if a passable result is obtained they are content and likewise too often is the surgeon. It has been claimed that decided improvement of vision is procured by the operation and also that binocular vision is a result frequently secured; v. Graefe and Knapp claim 50%. A good cosmetic result is rarely difficult of attainment, by combination of methods and by sometimes doing a series of operations. In cases of decidedly monolateral converging squint with great weakness of the externus and also in cases of divergent squint, where one eye has turned aside simply because of extreme defect of sight, both retirement of one tendon by tenotomy and advancement of the opponent is required. Such is also apt to be the case with divergence ensuing from marked debility of the interni in cases of E and H notwithstanding vision of each eye may be good. Here, as already said, simple tenotomy is apt not to suffice but must be combined with advancement. With ordinary convergence cosmetic success is secured by carefully avoiding unnecessary disturbance of the surroundings of the tendon, whether lateral or between it and the conjunctiva, and by not attempting to secure too much by one operation, whether upon one or upon two muscles. It must never be forgotten that the mechanism of the proceeding consists in letting the tendon slip back and take a new attachment to the globe behind its original insertion. For the degree of retirement which may be safely permitted we must take into account the length of the internus and the degree to which it is shortened. Its length including the tendon is about 40 mm. With a squint of 5 mm. it is reduced to 35 mm. when in the squinting position. The externus has a normal length of 49 mm. and this will be stretched to 54 mm. The internus in the normal position of the eye lies in contact with the globe for about 7 mm. This is of course shortened in the squinting position, by the degree to which the eye turns inward. Where the insertion is displaced backward, the muscle at

Digitized by the College of Optometry

its new hold still has a favorable position for action because this point is now turned outward and will permit the muscle to exert its force in a tangential direction. Evidently, however, if the insertion be pushed back beyond a certain extent, the action of the muscle becomes more and more embarrassed. Every tenotomy signifies a limitation in the mobility of the globe—this may within certain limits, in the case of antagonist muscles which have not become seriously degenerated, amount simply to a displacement of the arc of rotation. But in very many cases the arc of rotation is shortened, because the externus is incapable of carrying the eye outward to the degree by which the arc has been diminished on the inner side. In this statement lies the reason for the rule, that it is proper to let the muscles have time to adjust themselves to the new relations, provided one operation fails to procure the desired effect. The occurrence of relapses is also thus understood if it be found that the externi prove to be too feeble to maintain the advantage which tenotomy has given them. At the same time the absolute unwisdom (to use a mild phrase) of striving by free dissection to effect the purpose before a suitable adjustment of the muscular forces has been secured, is obvious. No surgeon, however careful, can claim absolutely immunity from the liability to slight over-effect in some cases, because it is impossible to control or acquaint ourselves with all the conditions of the problem. Divergence, amounting to 3 mm. or more when looking at a distance, is to be deplored, and such a degree of deformity reflects discredit upon the surgeon.

The value of the operation consists in improved appearance, in more comfort in using eyes, in enlarged binocular field, in the incidental correction by glasses of refractive errors, sometimes normal binocular vision is gained. That it *permanently* improves visual acuity is seldom true. An exceptionally good and permanent restoration of sight is given by Johnson, Trans. Am. Oph. Soc., 1893. In discussing this point we must choose patients whose age and intelligence enable them to give us trustworthy information. I have at hand the records of forty operations of which thirty-six were for strabismus conv. and four for strabismus div. Twenty-three patients who had convergence I regard as capable of giving reliable information—their ages are as follows:

From	6	to	10	years	= 6
"	11	"	15	"	= 5
"	16	"	20	"	= 5
"	21	"	42	"	= 7—23

From these, eight cases are taken out who had V = $\frac{20}{20}$ or $\frac{20}{30}$ in each eye both before and after the operation, some of them requiring

Digitized by Illinois College of Optometry

correcting glasses. In the remaining fifteen cases before the operation, vision in the poor eye was from $\frac{2}{100}$ to $\frac{1}{200}$. In three cases the ophthalmoscope showed defects which would necessarily prevent visual improvement. In the thirteen which are left, five showed absolutely no improvement in visual acuity. We are reduced then to seven which are fairly proper for investigating and testing the point. 1. A physician, æt. forty, had compound hyperopic astigmatism in the poor eye; when corrected vision improved from $\frac{2}{200}$ to $\frac{2}{40}$, but the operation had no share in the benefit. 2. A young lady, æt. sixteen, had astigmatism in both eyes; when corrected the poor eye had V = $\frac{2}{50}$. Six months after the operation, having been subjected to the use of atropine and having used glasses, and having also covered the good eye for certain periods so as to compel employment of the other, the vision of the poor eye remained $\frac{2}{50}$, and without a glass was $\frac{2}{100}$. 3. Young lady, æt. fourteen, before the operation the poor eye with + 3 D counted figures at three feet, after the operation counted figures at six feet. 4. Young lady, æt. seventeen, the poorer eye had with + 1.5 D V = $\frac{2}{40}$ and there was hemiopic amblyopia, but this vision six months later was $\frac{2}{100}$. 5. Male, æt. nine, in the poorer eye with + 6.s ⊂ − 0.75c 180° V = $\frac{2}{40}$. By tenotomy and optical treatment binocular vision was obtained, but in both eyes the vision remained the same for fourteen months. 6. Male, æt. eleven, with + 2.s V = $\frac{2}{50}$ before operation; after tenotomy and use of atropine and glasses with + 3.s V = $\frac{2}{50}$. Binocular vision was obtained, but no betterment of acuity was procured in the faulty eye. Numerous specks were visible about the macula. 7. Male æt. twenty-two, in poor eye V = $\frac{2}{50}$. Had an operation on both eyes ten years before I saw him. I did tenotomy on one and obtained binocular vision, which was known to remain for four months, but no improvement in acuity ensued in the amblyopic eye.

These few cases do not justify a broad generalization, but they correspond to my much more extended observations, and in the conclusion to which they point, my opinion is in accord with Schweigger's. It remains to consider how often we obtain binocular vision. On this point experience has taught me that the number of well-tested cases in which this can be proved, provided we demand the same kind of binocular vision of which normal eyes are capable, is excessively small. I have not gathered large statistics, but out of the small number of records at this moment at my disposition, viz.: thirty-six cases of convergence operated on, only four gained binocular vision, which is 11%. Out of the thirty-six there were ten who had in each eye better vision than $\frac{2}{30}$, of those only one gained binocular vision. Of the three others who secured it, the poor eye in all had V = $\frac{2}{50}$. It does not need large

Digitized by Illinois College of Optometry

statistics to show that if among ten patients in whom each eye has nearly normal sight and who by tenotomy and optical treatment are put in a position to acquire binocular vision, nine fail to do it, that there lies behind the ocular conditions, a something which constitutes an insurmountable obstacle. This is indeed the fact, and to it Hansen and Krenchel have especially called attention. It is the lack of that cerebral co-ordinating faculty which is the essence of binocular fusion. It would appear that when this faculty is once lost or perhaps has never been developed, it can rarely be acquired after the very early years of life. I do not assert that in only 11% of all cases can binocular vision be obtained. I have not studied all my records, but I am certain that the number is less than 20%. That a certain kind of co-ordination can occur between two previously strabismic eyes, which do not each direct its macula upon the object must be admitted. It is often possible after an operation to elicit double images when it was before not feasible. But this is a factitious and not genuine binocular vision. One who argues on these points must explain what kind of vision he claims to exist. A valuable kind of binocular vision exists in persons who have a high degree of anisometropia and in whom it is impossible for the images to be similar and who in reading will use only one eye. This occurs in persons who have had one eye operated on for cataract; while this gives sharp vision they cannot dispense with the assistance which the other unoperated and imperfectly cataractous eye gives them for purposes of general vision. This vision is really binocular. Yet there also arise cases of squint where vision is performed by one eye at the macula and by the other at a point many degrees aside from the macula. These persons will sometimes be found to have acquired a kind of binocular sight in which dissimilar parts of the two retinæ have learned to become associated. This kind of retinal incongruity does sometimes exist, and is not within the scope of our usual physiological explanation.

In conclusion I strongly urge the importance of exactness in the performance of the requisite operations and of care and perseverance in the subsequent optical treatment to secure the best result. The reaction after tenotomy is usually slight. In only three or four instances out of several hundred have I seen important inflammation occur, and this soon subsided. Once after tenotomy of both interni diphtheritic inflammation attacked the wounds, the patient having been allowed to go home. The eyes were saved, but excessive divergence eventuated. The operation for advancement has been discussed under the head of Strabismus paralyticus.

The treatment of periodic or as it may be termed incipient strabismus by selection of correcting glasses and persistence in using them will not infrequently cure the deformity and also bring about

Digitized by the Internet Archive

binocular vision. This point has obvious practical importance and its verity is proven by my records.

Intermittent strabismus is extremely rare. A case reported by Dr. Harlan in the Transactions of the American Ophthalmological Society, 1881, p. 277, may be referred to. A child three years old exhibited concomitant convergent squint every other day for one year, and it usually came, on awaking from sleep and would last during the day. It passed over into permanent squint. The refraction was emmetropic as decided by the ophthalmoscope. Nothing is said of the degree of vision or of the possibility of diplopia. When the strabismus was fully established it varied from time to time within very wide limits. It was under observation four years.

Strabismus Deorsum Vergens, or Sursum Vergens,

is to be treated by operating on the rectus inferior, or on the rectus superior. The obliqui are not suitable for interference. Landolt has devised a method of tenotomy for the inferior oblique; but the occasions for it are extremely rare.

It has lately been stated (Eperon[1]) that advancement of the weak muscle is to be preferred to tenotomy of the deflecting muscle. I think favorably of this statement, knowing that tenotomy of superior or inferior rectus is not as certain in results as of the external or internal rectus. Both proceedings may sometimes be combined.

Paralysis of superior oblique is best remedied by dividing the rectus inferior of the opposite eye, and subsequently, if needful, dividing the rectus internus of the affected eye and later the internus of the fellow-eye (Alfred Graefe). Each case will have its special features and careful estimate of the conditions will be demanded. Knapp has reported cases.

It is to be remembered that division of the superior rectus acts by association on the levator palpebræ superioris, and is followed, not only by a depression of the globe, but by lifting of the upper lid, by which an unusual amount of sclera will be exposed above the cornea. This fact may be utilized, if there be partial ptosis, both to aid the levator of the lid as well as the depressor of the globe. Correct vision below the horizon is of much greater value than above it. For strabismus convergens or divergens, with upward or downward deviation, it is proper to cut the adjacent tissues rather freely on that side of the vertical meridian to which the eye most deviates.

[1] Arch. d. Ophthal., March, April, 1889, p. 115. Condensed in Ophthalmic Review, July, 1889, p. 205.

Digitized by the College of Optometry

CHAPTER X.

ASTHENOPIA.

THIS term and its synonyms, *hebetudo visus, kopiopia, painful vision,* express the fact that exertion of the eyes is wearisome or painful, and there are often besides ocular, other symptoms, viz., headache, pain in the back, nausea, dizziness, as well as numerous remote disturbances. The term is convenient, but not definite. To give to it positive character, we must discover the error or condition on which it depends. The following subdivisions are clinically separable. Asthenopia from: 1, refractive errors, causing overtaxed accommodation; 2, from muscular errors; 3, from neurasthenia. To these has been added 4, asthenopia as a reflex effect from the nasal mucous membrane, from which arises often a decided and unusual degree of conjunctival irritation, and was noted by Schweigger. I have long recognized an intimate relation between nasal catarrh and chronic conjunctivitis, and that with it asthenopic symptoms are frequent. In a somewhat similar sense there are asthenopic symptoms with incipient cataract, with progressive myopia, with early presbyopia, but such cases need no consideration under this head. Neither is there need to refer to cases of pure neuralgia of twigs of the fifth nerve: the supra-orbital is most frequently at fault, and from malaria. Hyperæsthesia retinæ has been set down as a kind of asthenopia, but it is commonly only one of its symptoms, and has for its cause some of the conditions above mentioned.

Accommodative asthenopia need not detain us long. It is the subjective side of various refractive errors, such as hyperopia, astigmatism, anisometropia, etc. Upon this Donders laid special stress and thus set apart an important class of cases. If they have any typical subjective symptom, it is likely to be indistinctness of vision after prolonged work on near objects. Besides the blur of print, there will be pain in the eyes, and especially headache, either frontal or temporal or general; there may be dizziness, nausea, and other remote symptoms.

In investigating etiology we may meet large refractive errors, but it must be emphasized that in susceptible persons small errors, especially hyperopic astigmatism calling for a cylinder with axis nearly vertical, or even small degrees of hyperopia, demand exact

Digitized by Illinois College of Optometry

correction. As a fact we have often to deal with a susceptible organism, and because it is easily set ajar, we must remove even minute sources of disquietude. For this reason we are called upon to use atropia very often for such subjects. They may have notable photophobia, and this at the beginning may be aggravated by mydriasis, but perseverance until all spasmodic and painful accommodation is abolished will also remove photophobia. It sometimes happens among these subjects, that atropia causes headache, and it may be very severe.

If the case, as will in rare instances occur, be one of merely feeble power of accommodation, useful local treatment is to drop sol. muriate of pilocarpine, gr. ij. ad oz. i., into the eye once daily; or, sol. sulphate of eserine, gr. $\frac{1}{8}$ ad oz. i. But general tonics and rest of the eyes will be the chief reliance.

These cases may have other complications, and there are therapeutic suggestions to be made which will be referred to hereafter.

It is important at this point to discuss the *properties and uses of prisms* before entering upon the subject of the conditions for whose detection and relief they are employed, viz., errors of the ocular muscles. Their physical properties are extremely simple. A prism is a transparent substance included between two plane surfaces inclined to each other. The thin edge or angle is called the apex, the thick border is the base ; a line drawn from the

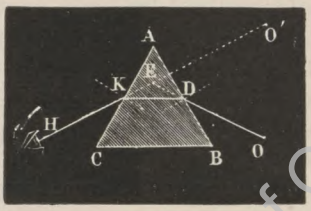

Fig. 79.

apex perpendicularly to the base is called the base-apex line. The position of a prism may be described by referring either to its apex or its base, but by custom we usually choose the base and say that the base is placed in one direction or another relatively to the eyes. Refraction through prisms is shown in Fig. 79. On the surface *AC* of a prism let fall a ray *HK;* it is deflected toward the perpendicular at *K*, emerges at *D*, is there deflected away from the perpendicular to *O*. The apex of the prism is *A*, its base is *CB*. The deflection of light is always toward the base. The rays which impinge at oblique angles are deflected more than those which strike vertically to the plane of incidence. Hence the so-called minimum deviation implies that rays fall vertically. Beyond a certain obliquity of incidence rays cannot escape from a prism, but undergo total reflection from the interior and opposite surface. The angle of total reflection varies with the refractive index. For spectacle glass (crown 1.53) it is 40° 49'. Except for purposes of examination only prisms of low angles (below 10°) are used in ophthalmic practice. There is no focus and they form no image. They de-

Digitized by the College of Optometry

compose light into its elements, and this property of "dispersion" gives them their value in spectrum analysis and is their disadvantage in physiological optics. They produce colored fringes on the edges of objects by this "chromatic aberration."

Objects viewed through a prism are seen in a false position; for example

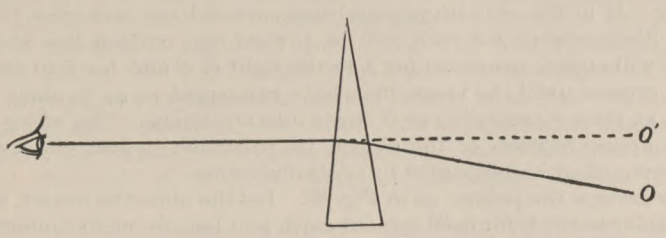

FIG. 80.

an object at *O* seen through the prism appears to be situated at another spot, viz., *O'*. The stronger the angle of the prism the greater the displacement, and for prisms of low angles the "deviating angle" is half the angle of the prism. The displacement of the object is always toward the apex. If a prism be placed before each eye and the base of each be to the right the

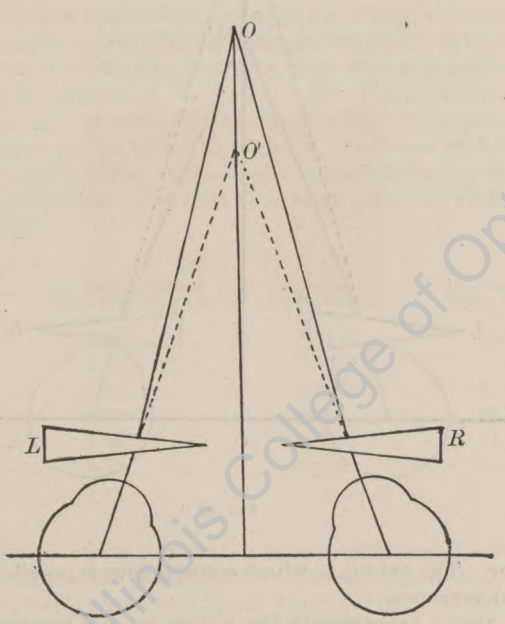

FIG. 81.

object will be displaced to the left, but the visual lines will not be altered in their angular relation. If, however, the prisms be placed with their bases the one to the right and the other to the left, or "outward," the object viewed by the right eye will be displaced to the left, and that viewed by the

Digitized by Illinois College of Optometry

left eye to the right, and diplopia (crossed) would ensue if the visual lines did not turn toward each other in convergence. Hence prisms with bases outward are called adducting. If now the bases be turned toward the median line the opposite effect follows—the object is displaced outward and again would diplopia (homonymous) occur, did not the visual lines make a corresponding divergence. Hence prisms with bases inward are termed abducting. If in Fig. 81 with prisms bases outward the eyes view the object *O*, the displacement for each will be toward the median line and double images will appear projected for *L* to the right of *O* and for *R* to the left of *O*, *i.e.*, crossed until the visual lines have converged so as to make the two images at their intersection at *O'* unite into one image. The effect is an apparent approximation of the object, its reduction in size, and a conscious converging effort accompanied by accommodation.

Now reverse the prisms, as in Fig. 82. Let the object be nearer, say at *O*. The displacement is for each eye outward, and homonymous diplopia occurs until the visual lines diverge far enough to intersect at the point *O'*. The effect is an apparent removal of the object and a conscious relaxation of convergence and accommodation. Still other effects occur which will be re-

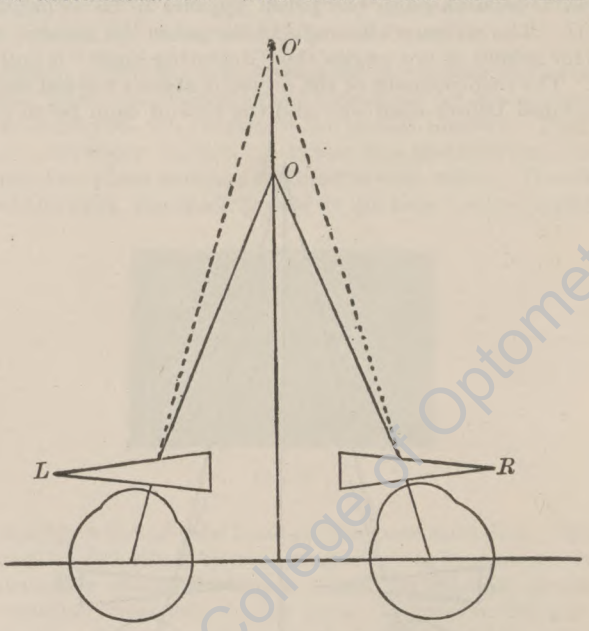

FIG. 82.

ferred to later. The extent to which convergence is possible greatly exceeds the possible divergence.

If in the above experiments the object be at 6 metres or at 20 feet distance (the visual lines practically parallel), they may by adductive prisms be forced into extreme convergence and by abductive prisms into a moderate amount of divergence.

It has been said that for spectacles only weak prisms are used, and that for them the deviating angle is about one-half the refracting angle. The demand for accuracy in ophthalmic methods has led to suggestions for a more

Digitized by Illinois College of Optometry

perfect system of notation. The reason is that as found in the shops prisms seldom conform precisely to the number marked as their angle, and it is also desired to make prisms conform to the principle now universal with other glasses, of numbering them by their power and not by a purely optical property, and in doing this to establish a simple and uniform ratio among them. Dr. Jackson proposed to number them by their deviating power in angles and to mark this number on the prism, using the letter *d* after the number, *e.g.*, for a prism of 4° angle, 2°*d* ; of 2° angle, 1°*d*. See Trans. Am. Oph. Soc., 1888, p. 150. Dr. Dennett proposes a new method based on a very modern conception in physics, the radian, which is an arc whose length equals its radius of curvature, viz., 57.295°, of which he would take the hundredth part, the centrad. For special description see Trans. Am. Oph. Soc., 1889, and comments on it by Dr. Burnett, *Ophthalmic Review*, January, 1891.

An optician, Mr. Prentice (*Arch. of Ophth.*, xix., Jan., 1890, April and July, 1890), has brought forward a nomenclature which is certainly simple, accurate, and in accord with our customary practice with other glasses. He proposes to measure prisms by their displacing effect measured on a plane (tangent) at 1 metre distant from the prism, and the unit to be a prism which shall at this distance cause a displacement of 1 centimetre. It happens very remarkably and fortunately that the prism of 1° and index 1.53 causes this quantity of displacement within a negligible fraction. This unit he calls the prism dioptry, *PD.* The value of any prism can be easily found by drawing upon a card placed at a convenient distance, say 6 metres, a series of parallel lines 6 centimetres apart, and looking through the prism to be examined, the number of spaces and fractions which a long line or a candle flame is displaced, denotes the number of the prism. Mr. Prentice remarks that the average deflection of our commercial prisms from 1° to 5° corresponds very closely to this scale up to the fifth division. It therefore follows that the terms are almost convertible, and our old nomenclature by degrees, differs little from prism dioptries. The following table gives the differences (taken from De Schweinitz):

Prism Dioptries PD.	Refracting Angle of Prism Required.	Prism Dioptries PD.	Refracting Angle of Prism Required.
1.	1.06°	8.0172	8.62
2.0001	2.16	9.0244	9.68
3.0013	3.24	10.0323	10.73
4.0028	4.32	15.114	16.1
5.0045	5.40	20.270	21.13
6.0063	6.47	42.288	39.0073
7.0115	7.54		

Prism dioptries are easily convertible into metric angles (see p. 188). By assuming the average adult interpupillary distance at 64 mm., one MA = 32 mm. deviation, which is about one-third of one PD (*i.e.*, 100 mm.). Therefore 1 PD = $\frac{1}{3}$ MA; or 1 MA = 3 PD; or 4 MA = 12 PD, or a prism 12.89° angle. Another point for consideration is the prismatic effect of decentering lenses. Mr. Prentice has shown that a lens decentered one centimetre gives a prismatic deviation of as many dioptries as there are dioptries in the lens. A lens + 4 D decentered one centimetre gives a displacement of 4 PD, and if decentered one-half a centimetre a displacement of 2 PD. Moreover,

Digitized by the Illinois College of Optometry

the centrad of Dr. Dennett and the prism dioptry are almost identical. It thus appears that the decentration of strong lenses is an important circumstance, while for lenses less than 2D the deviations are small and seldom important, except by extreme amounts of decentration. For example, a 2 D lens must be decentered one centimetre, or $\frac{2}{5}''$, to get the effect of a prism of 2°. A table elaborated to millimetres is given by Maddox, "Clinical Use of Prisms, etc.," Wm. Wood & Co., *Medical and Surgical Monographs*, vol. ix., No. 2, Feb., 1891, p. 291.

We shall permit ourselves to speak in the old nomenclature of designating prisms by their angles, because for those with which we shall chiefly deal the errors are small. Moreover, in muscular asthenopia not only do we use weak prisms, but their effect in a physiological sense is far higher than their optical values would suggest.

Muscular Asthenopia; Muscular Insufficiency; Dynamic Squint.

To the subject of muscular insufficiency and more particularly of the internal recti in myopic eyes, von Graefe was the first to call attention. See *Arch. f. Ophth.*, viii., Abth. 11, 314, 1861. He did not omit to mention its existence under other refractive conditions, but since his time the field of inquiry has greatly widened. We always take account of the refractive state, but while myopia undoubtedly carries with it many and serious conditions of muscular trouble, this fault is exceedingly common both in other forms of ametropia and in emmetropia. We have to do chiefly with disturbances of adduction and abduction, while a small number of cases exhibit errors in the movements upward and downward. We have referred to the intimate relation which subsists between accommodation and convergence, and we know how greatly this is modified by the refraction. Attention has been chiefly directed to muscular errors as they are developed at the working point, and it is here that the chief strain occurs, but it is found that their study at the far-point is more often of controlling importance. If the working point, as in myopia or amblyopia, be very close, the high angle of convergence aggravates the strain in rapidly increasing ratio. Whatever be the degree of adductive effort, it is needful to have a certain amount in reserve, and it is also needful to possess a sufficient abductive capacity to balance adduction.

Landolt declares that there must be converging power in reserve twice as great as that which is being employed, but this fails to take account of cases where defect of abductive power leaves adduction almost unchecked.

We employ prisms in measuring adduction and abduction, but another method has been introduced by Nagel, which has been adopted by Landolt

Digitized by Google

and to some extent by others, and which, because it is scientifically accurate, may be explained. It is founded upon a unit called by Nagel the metre-angle, which is analogous to the metre-lens or the dioptry, which was also introduced by Nagel. The metre-angle is the angle formed at one metre distance by the intersection of the visual line with the median plane. In Fig. 83, let the inter-ocular distance be represented by the base line EE. Let M be the centre and draw the line MH. Let EA represent the optic axis of the left eye when looking at a distance. It is then parallel to the median plane MH. Now let the eye E fix upon an object distant one metre and draw EM′ equal to one metre. The angle AEM′ is the deflection of the optic axis to the median line for the distance of one metre. This is the metric angle or angle of deflection or adduction for one metre. Let another point be taken calling for an additional and equal deflection; this will intersect the median line at M″; add a third equal angle of deflection and we meet the median plane at the point M‴. The distance from M′ to infinity is one metric angle, from M″ to infinity is 2 metric angles, and from M‴ is 3 metric angles. The effort of accommodation to M‴ is 3 D; to M″ is 2 D; to M′ is 1 D.

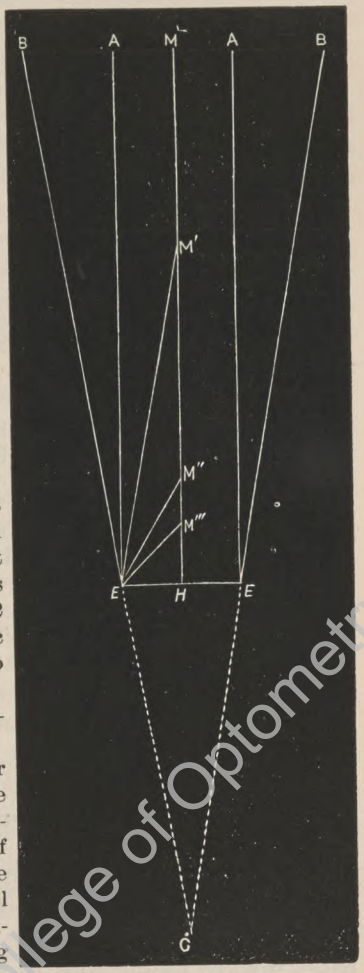

FIG. 83.

We see a perfect coincidence in the expression for the two functions.

The metric angle is manifestly larger when the base line is longer, *i.e.*, when the inter-ocular distance is greater. This distance we measure between the centres of the pupils, or, more correctly, between the centres of rotation of the globes. Nagel gives a table of the value of the metric angle for various inter-ocular distances going from 50 mm. to 75 mm. In children the distance may be assumed to be on an average 58 mm., and in adults 64 mm. For the former the metre-angle will be 1° 39′, 99′, or say 100′; for adults it will be 1° 50′ or 110′ (minutes). In measuring practically we may employ an arrangement of Landolt's, viz., a metric tape line upon which metre-angles are marked, one end of which is held to the temple and the other end is attached to a little lantern inclosing a candle and which is the object of fixation. The lantern has a hole in the side and the patient holds it as close to the eye as he can without seeing it double; this point read off on the tape gives the number of angles of convergence. To measure what can be done in divergence beyond parallel visual lines, prisms with the bases inward are required.

To translate the finding of prisms into metric angles we insert a table from Prentice (*Arch. of Ophth.*, xix., 1, 1890), where the sine, tangent, and

Digitized by the College of Optometry

angle are accepted as equal, showing the value of the angle of convergence when the interpupillary distance is taken at 64 mm.

Metric Angles.	Dioptries, PD.	Degrees of Arc, Sine.
1	3.2	1° 50′
2	6.4	3 40
3	9.6	5 30
4	12.8	7 20
5	16.	9 10
10	32.	18 20
20	64.	36 40

In this table the error up to 5 metric angles is unimportant, and we need not concern ourselves about higher degrees of disturbance, because for such cases prisms are never applicable. But for persons whose interpupillary distance is other than 64 mm. we need a rule for determining the metric angle and the corresponding prisms. Prentice gives the rule: "Read the interpupillary distance in centimetres, when half of it will indicate the prism dioptries required to substitute one metre-angle for each eye." For 60 mm. the base line is 30 mm., and the metric angle will be 3 PD. For 50 mm. the base line is 25 mm. and the MA = 2.5 PD. A reference back to p. 201 will give the actual angular equivalents of the prisms.

If now we add the number of metric angles for the near, to those obtained at a distance, we get the total so-called amplitude of convergence; which may be put into formulæ precisely as we discuss dioptries of accommodation.

Before discussing erroneous conditions we must have some standard of the normal status of the muscular apparatus. The total lack of binocular vision has been referred to under paralysis and strabismus; we now consider the conditions under which its maintenance is difficult. It has been shown that in all persons there exists a considerable power of forcing the visual lines beyond the point of binocular fixation, and that the possession of a certain surplus power is necessary to comfortable vision. If we fix on a small gas flame at 20 feet distance, we can preserve single vision, even though prisms with bases outward be interposed amounting to from 30° to 50°. We can also see a single flame if prisms with bases inward amounting to from 6° to 12° be interposed. In these performances the adducting and abducting muscles are forced to unusual effort, and the limit of their capacity is denoted by the prisms, which finally bring on uncontrollable double sight—we see two flames. In doing this we look forward on the median plane, and the effect consists in forced contraction of all ocular muscles with predominating effort of certain groups. We may say very broadly, admitting numerous exceptions, that normal adduction is 25° to 45° and normal abduction 6° to 8°. Abduction is more nearly constant than adduction. This may be expressed in metric angles if one please, but the facts are not altered. Deviations from the horizontal plane are physiologically more re-

Digitized by Harvard College Library

stricted; we can seldom do more than overcome a prism of 2° or 3° with base either upward or downward. If the head is turned laterally and the eyes are directed obliquely at the flame the co-ordination of the muscles is changed and the findings with "eyes front" will no longer hold good; both adduction and abduction will change and in diverse ways, not yet much investigated.

If now we attempt to determine the total adductive power we must not only bring an object close to the face but often resort to prisms with bases out to ascertain the totality. Many persons can squint inward to excess and beyond measure. It is of little value to learn the amount of this ability, and we therefore attempt to discover what flexibility, so to speak, there may be in the muscular power when we are at the ordinary working distance. This may be at from 6 to 20 inches according to the state of refraction and the habit and age of the person. But if we make proper correction by glasses, and if we permit certain persons to choose special distances according to their requirements, we may for the large multitude assume 13″ or one third of a metre as a convenient point for measurement, because it closely approximates 16″, the usual distance of reading, writing, sewing, etc. We have now in use 3 dioptries of accommodation and 3 metric angles of convergence, which may be represented by 9.6° PD for the average adult interpupillary distance of 64 mm. Each eye is inclined toward the median plane a quantity represented by a prism of about 10° angle, making a total of 20° for both eyes. What additional amount of adduction will now be possible? Here again we find great variations. It will reach from 10° to 50°. As to abduction, we would naturally count on at least 20° to establish parallelism of the visual lines, but we must remember that an accommodative effort of 3 D is being maintained, and that this hinders the free use of the abductive capacity. We find that the range is from 10° to 20°. For the *punctum agendi* the average capacity is: Adduction, 20° to 40°; abduction, 15° to 20°. We have at 13″ even less freedom in vertical planes than we have at a remote point.

In the above statements it is seen that we cannot apply the precise rules to which we are accustomed in refractive problems to the conditions now discussed, and for obvious reasons. The very essence of the organs is mobility and variable energy. To Graefe we owe a very ingenious device to attempt to discover what are the conditions of dynamic repose of the two eyes. Creating uncontrollable diplopia by a prism with its base-apex line vertical, he conceived that the eyes would adjust themselves to the status of repose and reveal either a normal or abnormal condition. Experience has proven the untrustworthiness of this test as a single reliance, but it does create a condition which gives valuable hints. Graefe's

Digitized by Illinois College of Optometry

large dot and fine vertical line are better substituted by a small white dot on a black card at 13″, while the vertical prism test requires for its distant object the same small flame at 20 feet. Under these tests the normal and usual results are for 20′ a position of the flames varying not more than 1° or 2° either way from the perpendicular, and for 13″ it is most common to have 5° of divergence from a perpendicular.

As already said, the statements now made about the usual behavior and capacity of the ocular muscles under the tests described must be taken as very general, and subject to very numerous exceptions. The departures from the status described are often very startling.

General Divisions and Considerations.—We are testing what is called the "capacity for fusion" of the separate retinal images. This is a cerebral function; it is capable of cultivation, it depends on a variety of factors. Some of them are, 1st, approximate equality in the refraction and perceptive function of the two eyes, or, in other words, the absence of high refractive errors or of marked defects in visual acuity. For these reasons cases of anisometropia, of muscular amblyopia, of loss or defect of sight in one eye, of decided myopia in each eye, of hyperopia, of visual obtuseness, always predispose to or present notable variations from a normal standard of fusion. Again, 2d, we find actual muscular anomalies, in spasm of certain muscles, or in weakness of muscles which may be due to faulty insertion, or to lack of muscular fibre. 3d. Doubtless variations in the density and arrangement of the oculo-orbital fascia give rise to greater or less degrees of effectiveness in the muscular contractions, because it holds them steady and makes an auxiliary insertion for their tendons. Especially is this true of the recti. The importance of this fibrous membrane has been too little considered both as a causative factor and in operations. 4th. The complexity of action of the twelve muscles concerned, the necessity for rapid, exact, and smooth performance, and that during waking hours or the maintenance of the visual act, they are perpetually on duty, and that their combinations must be adjusted to such variable distances, angles, and cover so wide a field, and that the mental consciousness relies so absolutely and instinctively on their work in its judgments respecting the external world—these considerations make it clear that their function is important, and that we ought to expect the same variations in their conduct which we are not surprised to find in what we call the temperament, the constitution, the idiosyncrasy of different individuals. 5th. We are brought by the last statement to consider the condition which more than all others is the presiding factor in muscular asthenopia. This is somewhat difficult to express, but may be called the quality

Digitized by Google

of nerve energy. The health of the efferent nerves, of their nuclei in the medulla oblongata, and of those portions of the cortex, with which they are associated, in fine the vigor and quality of the whole nervous system enter into the problem. This consideration explains why in some persons large muscular anomalies have little or no disturbing influence and in other persons small errors are most harassing. This explains why asthenopic symptoms appear after attacks of sickness, during debilitating conditions, as the consequence of grief, of shock, of worry, as the accompaniment of many chronic diseases having no direct connection with eyes or brain. 6th. Overwork and inadequate nutrition bring about muscular asthenopia. On this point we do not dwell. Lastly, if we have not catalogued all the conditions which account for the presence or absence of symptoms of muscular asthenopia, it is clear that among those mentioned numerous combinations of local and general causes can take place which will give rise to startling and perplexing and distressing situations. The judicious and skilful treatment of cases of muscular asthenopia with all the complications which may co-exist is the highest problem in ophthalmology.

We divide cases of muscular asthenopia into two broad classes, and these together make a third, which is naturally the largest. We have *the myotic* and *the neurotic*. Under the myotic are included those in which muscular anomalies are the great and predominating factor; the neurotic are such as exhibit such anomalies, but their influence is made potential by the dominating neurotic condition. In the first class, refractive errors may play a part by inducing muscular disturbances, and their elimination often completely removes the muscular troubles; in other words, the correction of astigmatism, of hyperopia, of anisometropia, will often leave no occasion for dealing with muscular faults because the strain on the muscles disappears. (It is pertinent to say that these errors express their hurtful influence through disturbances of a muscle, viz., the ciliary, and the intimate association of this with the motor muscles makes the concurrence natural.) On the other hand, a minority of cases of refractive error do not find relief by focalizing glasses, but demand substantial aid for complaining muscles in addition. These may furthermore be complicated by neurotic conditions which must have full recognition, or treatment will not, and perhaps cannot, bring relief.

Furthermore, numerous cases present themselves in whom the manifestly conspicuous feature is the neurotic disturbance; it may be excitability or intensity of action, or exhaustion from any cause. In these cases muscular defects are common, either in a greatly reduced power of fusion, feeble muscularity in all directions, or in spasm of convergence, or in the hurtful effect of minor errors

Digitized by the Internet Archive for Posterity

whether of one sort or another. It is of course frequent to find small refractive errors, and how marvellous may be the benefit gained by their correction, has been already noticed. It is here that the potency of the .25 D is observed. It is also among these people, mostly women, that the very weak prisms find their utility. To such a point (a vanishing point) has this prescription been carried, that a paper has been written on the value of the prism .25 P. D. Modern civilization, the exigencies and urgencies of social and business life, hereditary tendencies, and the American temperament with its stimulation of the mental faculties makes neurotic asthenopia in its various phases a disease widely prevalent in our community. How this general tendency in some cases reacts upon the retina will be mentioned later.

These general statements will, I trust, make it clear that my standpoint in viewing a case of muscular asthenopia is to regard the general condition of the patient as the controlling circumstance, and deal with the ocular conditions in subordination to that. I hold firmly to the necessity of rigid, complete, and exhaustive investigation of all refractive, muscular, and other functional errors, and apply the proper correction, but the purpose is to include these particulars in a judicious estimate of what relates to general health and temperament and surroundings. A corollary to this statement is that while with neurotic people small errors must receive unusual consideration, one must not forget with them the influence of mental impressions, and the cures wrought by suggestion, hypnotism, metallotherapy, electricity, etc. We may now particularize some of the usual *exciting causes.* We have to note overtaxation by reading on railway trains and in carriages; by reading when lying down, which convalescents and chronic invalids often find out too late; by attempting difficult work, such as embroidery, sewing on black, fine painting, decoration on china, etc.; bending over the work and bringing it too near the eyes; by the study of languages whose text is intricate, such as Greek, German, Hebrew, etc. Want of vigor, whether by congenital conditions of health, by too rapid growth, by malaria, by any debilitating causes, by shock, grief, etc., are to be duly considered; especially all forms of uterine disease, hemorrhage, fevers, chronic anæmia, instigate muscular asthenopia. It will often happen that the depressing agencies mentioned, are simply exciting causes of a disorder whose real progenitor is an essential muscular weakness, which may long have been latent, but is now made potential.

Some cases seem to have congestion at the base of the brain and there is tenderness over the middle and upper cervical vertebræ. Nasal catarrh is both a complication and a cause, while the same is true of chronic conjunctivitis of the lids and blepharitis.

Digitized by Google

Subjective Symptoms.—Pain in using or fixing the eyes is the conspicuous symptom. This appears in all kinds of near work, reading, writing, etc.; it may also exist in distant vision, in looking at a crowd, or at the stage in a theatre, looking out of a carriage or from the window of a railway car, etc. There may be great photophobia. Seldom is there blur of sight, while unsteadiness of letters or work, which is caused by a tendency to diplopia, resembles the blur of refractive error, and is sometimes thus spoken of. The pain is generally in the eyeballs and inclines the patient to press on them for relief; but it is often temporal, frontal, occipital, or at the vertex. In truth, not a small percentage of obstinate headaches, especially "sick headaches," originate in disorders of ocular muscles. A frequent symptom, and one not easy of explanation, is headache on first waking from sleep in the morning. Sometimes dizziness occurs. When the general health is feeble, or the subject neurotic, we may have the most erratic and intense remote symptoms: aphonia, palpitations of the heart, pain in the ovaries, diarrhœa, rectal irritation, etc. Asthenopia in some subjects is almost as protean as hysteria, and the two go hand in hand. It has been asserted that chorea is caused by this condition, but my observation has been that usually the order is otherwise, and that it is chorea which gives rise to debility and irregular action of ocular muscles as one of its manifestations. Epilepsy has been asserted to depend on this cause. I cannot deny that, in a few cases, eye strain may have been demonstrated to be an exciting cause or occasion, but there has been behind it a deeper lesion of the general nervous system. This statement is quite consistent with the disappearance of epileptic fits in case the muscular eye trouble is cured. Well-marked relief in a case of epilepsy took place in the practice of Dr. Ranney of which I had personal knowledge. The great relief, effected by tenotomies, was only partially maintained afterward, but the health improved and the frequency of the fits was much reduced as late as three years after the operations were begun. For further discussion on this point see Report of Committee.[1]

Objective Symptoms.—These are as follows: while both eyes within certain limits seem to move in harmony, for certain extreme positions to the right or left, or up or down, they become tremulous or one will deviate in the median line and at moderate distances there may seem to be no fault, but if an object be brought very close to the nose a deviation may occur. If no evidence is

[1] Journal of Nervous and Mental Disease, Nov., 1889, p. 657. On the subject of the general disturbances of the nervous system due to ocular derangements see Anstie, "Neuralgia," 1872, p. 169, the writings of Weir Mitchell, and "Functional Nervous Diseases," Stevens, New York, 1887.

Digitized by Harvard College Library

thus obtained, repeat the same experiments, bidding the patient regard the finger as it is carried to various extreme positions, and while he fixes upon it, put a card before one eye and note whether, when binocular sight is thus abolished, the covered eye may not deviate from its correct position. Especially useful is this test when searching for weakness of adductive muscles, the finger being brought within a few inches of the nose, and each eye alternately covered by the card. There are other ways of determining the so-called static condition of the eyes, but they only give hints and not measurements. The parallax test (Duane) is one, which shows a deviation in fixation by the difference in localizing the gas flame with each eye alternately, the other being screened.

Within a few years much has been written, in this country especially, on tests for muscular errors, and various refinements have been brought forward by Duane, *N. Y. Medical Journal*, Aug. 3, 1889; by Stevens, the stenopaic spherical lens, *Ophthalmic Record*, vol. i., 7 and 8, 1892, Nashville, Tenn.; by Maddox, the rod test, and the double prism test. Several instruments have been invented, viz., the phorometer, by Stevens; an apparatus by Risley, *Med. and Surg. Reporter*, Phil., Dec. 5, 1891; an apparatus by Gradle of Chicago, and other contrivances. Long practice in using simple contrivances and the habit of searching repeatedly and with much care have enabled me to accomplish so much that I have not cared to be cumbered with elaborate apparatus. The necessary appliances for my work are squared prisms about 1½ inches long on the side and varying from ½° to 15° and some twenty in number; prisms mounted in series or piles, two sets, one having even numbers from ½° to 20°, the other having odd numbers from 1° to 21°; a combination of prisms 5,° 15°, 10°; prisms mounted in spectacle frames of low degrees, 1° to 3°, with bases in or out; a Maddox rod mounted, a square double prism (Maddox), a disc of red glass. These serve for the examination at 20 feet. For the working distance I employ a simple prism holder shown in Fig. 86, which serves likewise for detecting spasm of accommodation, and will permit the use of correcting glasses as well. The test for the near ought never to be omitted. I discard instruments like the revolving double prism of Crètes because they tempt the patient to put forth efforts which are only temporary and misleading to the oculist. Hence in the piles of prisms the intervals are 2°, so as to learn more correctly what the patient can do. To keep the square prisms level is very easy, and I avoid in an examination the use of trial frames, or of anything placed on the face until high degrees of prisms are reached. The argument on behalf of Stevens' phorometer, that by being placed several inches from the patient it removes the liability to cause stimulation of muscular errors, in

Digitized by Google

my experience is not well founded. The phorometer is widely used, is a good piece of mechanism, but its tendency seems to me to be to develop and exaggerate small errors which are unimportant.

I need not remark that refractive errors are corrected by suitable glasses, and sometimes atropia is used. If refractive error be above 2 D the correction is always interposed; if less than 2 D I am not careful about it, because large and careful investigation has shown that small errors seldom make important modification of the muscle findings. In all muscular tests a red glass before one eye exaggerates the conditions observed, by diminishing the tendency to fusion.

The first test object will be the small gas flame at 20 feet, against a dark background. For errors of the oblique muscles a heavy black line, one foot long, on a white card is useful. A small gas jet may be put at the middle of a

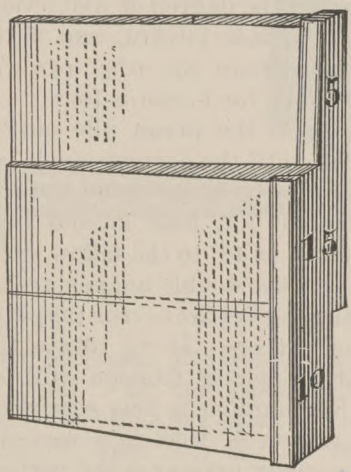

Fig. 84.

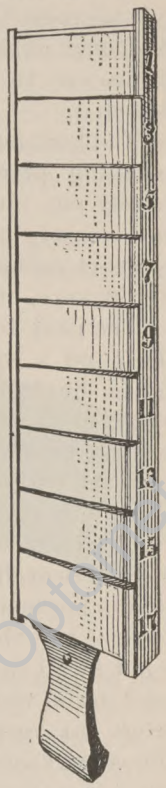

Fig. 85.

card on which are lines drawn parallel and 6 centimetres apart, and the card made to revolve, to permit comparison of the displacement caused at different positions of the prism.

The patient stands, the test box is at his right, the observer faces the box and the patient; he holds before the left eye a 5° or 8° prism with base upward; vertical diplopia ensues, which perhaps the patient does not immediately notice—the flame seen by the left eye is projected below. If the two images are not plumb, the pile of prisms (Fig. 85) is brought before the right eye with base on the side where the top image is said to stand, and moved up until the images are made plumb. A red glass will develop the error to a

Digitized by the Illinois College of Optometry

greater degree, whatever its character. Maddox' glass rod held horizontally before the left eye gives rise to a vertical (or perhaps oblique) streak of light on the level of the true flame, which it may intersect or lie either to the left (convergence), or to the right (divergence). The double prism of Maddox (advantageously modified by Savage) consists of two prisms, each of 4°, placed base to base, and the patient looks through them at their junction. One eye (always the left, unless this is highly amblyopic) sees two displaced images and between them the true flame. These three flames are to be brought in line by the pile of prisms above mentioned.

The test now made has decided value, but it does not measure anything precise or which has commanding importance; it is merely one factor among many. To speak of this finding as the measure of the so-called insufficiency is to fall into error. There is no exact measure of "insufficiency," and the term is one of general significance, not of precise notation.

The next test is to measure the degree of abduction. Hold in one hand a square prism of 5°, base inward, and if the light remains single put a prism pile before the other eye with base inward, until the extreme capacity for fusion is found. If the light become double, turn the base of the prism pile outward and reduce the effect of the 5° prism until the correct result is obtained.

At this stage another use may be made of the abductive prisms. Place before one eye a prism of 10°, base in, and if this be not enough to excite diplopia, add 5° or 10° to the fellow eye. Hold the prisms horizontal and inquire if the double images are on the same level; if not, there is a tendency to vertical error (hyperphoria). It is not at all rare to find small errors. If we rotate the patient's head on a vertical axis, the sidelong fixation will many times bring out vertical error. So common is this experience as to be almost physiological. The reason is, that in a movement to the left, for example, the left eye easily preserves the vertical meridian vertical, but the right eye under the influence of the superior and inferior recti as sinistral rotators must be exactly balanced by the superior and inferior oblique to keep its vertical meridian vertical, and this implies an equilibrium of forces very likely not possible. It must be remembered that the strong prisms have abolished the instinct for fusion, and the test object (the gas light) is so small as not to furnish such an inducement to fusion as would a larger one or as would a rod or line. In discovering vertical errors it is of the utmost value to make the patient move the head backward and forward as well as sidewise, while the prism induces homonymous images; the evidence is the fact that at certain positions there is a greater or less amount of displacement than in other

Digitized by Internet Archive

positions. An additional proceeding is to hold a 5° prism base up before one eye and then place it before the other, or reverse it before the same eye. If there be a notable discrepancy in the separation of the images, this marks hyperphoria. It will be noted that none of these experiments stimulate a tendency to vertical movement; they simply elicit the tendency to want of parallelism of the visual lines in the vertical plane.

The measure of the amount is made by placing before one eye a prism with base toward the image, until a level is established. This prism will vary from ½° to 3° or 5°, while I have corrected a case of 17° vertical error. In this kind of measurement (for hyperphoria) the phorometer of Dr. Stevens is exceedingly convenient and accurate. As to the practical value of the measurement, comment will be made hereafter.

The next step is measurement of the adductive power. We expect this to equal 25° to 60°. Most people will show less than 30°

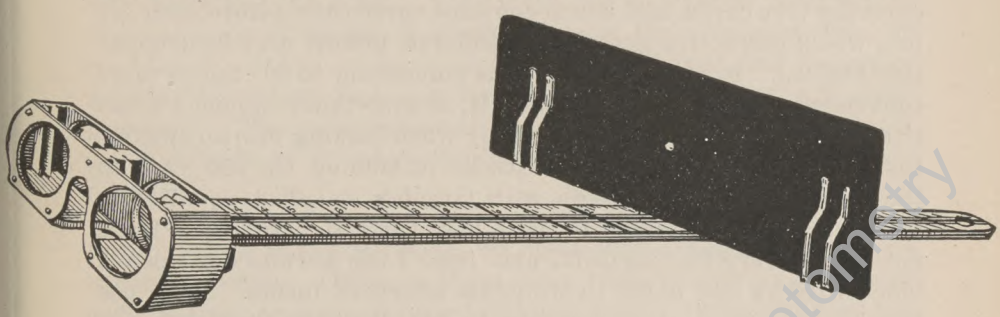

FIG. 86.

until educated to more. The compound prism, Fig. 84, may be held in the left hand with the base out. Employ the 5° next the 10° and before the other eye place one of the piles and carry it up to its maximum; then put the 15° before the left and again run through the pile until its bottom prism is reached, or until the patient "balks" and declares that he cannot unite the images. One must coax and urge and persuade and "chaff" the patient to do his best and never lose patience, and be ready to try, try again. If the adducting faculty is higher than 32° put on a pair of square prisms, each 10°, in spectacle frames, and begin again as before. It is a useful check test in some cases to try the adduction in side-long positions as well as with eyes front; it will always be lower in amount, and sometimes extraordinarily.

It is proper to make mention at this point of the nomenclature for latent muscular errors (called by Graefe dynamic squint) invented by Dr. G. T. Stevens (*Arch. of Ophthal.*, XVI., No. 2, 149, 1887), and which has gained extensive currency. The terms are convenient as general designations. But

Digitized by Illinois College of Optometry

the excessive elaboration which has been proposed, and the intensely symbolic writing which some have employed like a cipher code, mystifies and obscures the facts.

I. Generic Terms. *Orthophoria:* a tending of the visual lines to parallelism; *heterophoria:* a tending of these lines in some other way.

II. Specific Terms. Heterophoria may be divided into: (1) *esophoria:* a tending of the lines inward; (2) *exophoria:* a tending of the lines outward; (3) *hyperphoria:* a tending of the right or left visual line above its fellow. This term does not imply that the line to which it is referred is too high, but that it is higher than the other, without indicating which may be at fault.

III. Compound Terms. Tendencies in oblique directions may be expressed, as *hyperesophoria:* a tending upward and inward; or *hyperexophoria:* a tending upward and outward. The designation "right" or "left" must be applied to these terms.

We next examine the same functions at the patient's working distance, and to do this I have long found it convenient to use a holder which consists of a central stem about 0.5 metre long, graduated in inches or centimetres and metric angles, on which is a slider carrying test cards, and which contains three cells before each eye into which corrective glasses and squared prisms may be dropped (see Fig. 86). It will contain prisms amounting to 50°, and is more convenient than the trial frame. If, as sometimes happens, a patient cannot put forth his real energy when looking into an apparatus, let him make a few trials without it, holding the test card in the hand. We usually begin with Graefe's so-called equilibrium test, employing a prism of 10° with base vertical. He used a large dot upon a very fine perpendicular line; I use a white dot upon a black card as less liable to stimulate efforts of fusion. Some use fine letters. It is most common to find that the images do not stand vertical to each other, but that there is a deviation in the sense of divergence of about 5°; this cannot be called abnormal. More than this must be noted. A deviation in the sense of convergence is always abnormal, and directs suspicion upon the externi. Next try the abduction and the adduction by prisms suitably placed. It is best to begin with abduction. Often a patient will show only 6° or 8°, because of involuntary convergence; hold the finger between him and the test card and bid him follow it down to 13″; he gets single vision of the finger, and as this drops out of sight the dot is single. Add another prism, say 2°, and shift the prisms from one side to the other so as to make the increments small, usually by 2° or 3° at a time. Gradual coaxing will bring the abduction to its maximum. This device is extremely important in the numerous cases where vertical diplopia at 13″ displays marked esophoria. Another trick is to push the slider half-way up to the face and gradually withdraw it. It is absolutely necessary to give the patient every possible chance to exhibit all the abduction he possesses. In trying to find all the adductive power, we cannot do

Digitized by Illinois College of Optometry

so much to aid the patient as for abduction; nevertheless pushing up the slider and slowly withdrawing it will often help him do his best.

In assuming 13″ as the proving distance, allowance must be made for high refractive errors, especially myopia, and the distance may be modified to the requirements of the case. It is also obvious that the glass needed for the working distance must be provided; this applies to presbyopia as well as to all refractive errors. It will to many be a surprise to learn how low is the adductive power with presbyopic correction, and in how few instances inconvenience is felt. On the other hand the displacement of the relative accommodation explains the annoyance caused by using too strong glasses for presbyopia, and sometimes, when the glass is weak.

It is true, as is now generally recognized, that our findings at the working point are subordinate in importance to the conditions elicited at 20′, but they have no little significance in the general estimate which we make. Very often the indications corroborate the diagnosis of spasm of convergence in the strongest way, or they teach us that we have to do with overtaxed and incapable muscles for which rest and improved general energy are most necessary. The prescription of prisms or of tenotomy on the basis of what tests at 13″ show is seldom advantageous, or even permissible.

In cases where marked esophoria shows excessive convergence for the whole range of fusion, we must look closely for *spasm of accommodation.* Often in these cases there is mild hyperopia or astigmatism, or both; we want to know if they alone condition the muscular disturbance. Before using atropine, or even if it has been used and we want to find out if its work has been fully achieved, we may resort to a test on which I have relied for approximately accurate results for twenty years. I slip into the holder a pair of spherical prisms + 3 D ⊂ prisms 6° bases inward. An emmetrope ought theoretically to read S. 1 (the very fine capital letters N P R T V) at 13″ with + 3 D. But this will only be true with monocular vision and with relaxed interni, conditions seldom presented in the consulting room; hence we must cause relaxation of the interni by interposing abductive prisms. The convex glass and the prism combine to the same result. As a fact, with such a glass (an approximation to Brücke's dissecting spectacles) the point of fusion of the visual lines for the average inter-ocular distance of 64 mm. is not far from 2 M. A. In reality, as the conditions are various in different persons, the intersection of the visual lines is at 4′ to 6′ distance, while the accommodation is at 13″. Some enlargement of the image is caused by the glass. Reading S. 1 at 12″ is not to be regarded with suspicion, but when the point must be pushed to 10″

Digitized by Illinois College of Optometry

or 8″ we have to diagnosticate spasm or amblyopia, and act accordingly. If vision be feasible at 11½″ to 13″ we need not be concerned about atropine unless other evidence compels it, such as the ophthalmoscope, the shadow test, etc.

An indication of *vertical* error may often be found by the tipping of a patient's head; he carries it bent to the shoulder and perhaps a little rotated. Close inspection will often show asymmetry of the head and face—one ear will be higher than the other; the floors of the orbits are not horizontal; the cranium will be lopsided. In such cases, which are common enough, one will usually find hyperphoria, and sometimes, but by no means always, will it demand correction. Observations of this character have been recorded for many years among my notes. So decided are my convictions on this matter that I may cite instances of evident paresis of the superior oblique muscle examined and treated more than twenty years ago in which the best results were gained not by correcting the difference of the images in height, but on the working and the horizontal plane. The writer is himself an instance of the innocuousness of a vertical error when it develops itself 15° above the horizon; this he has from traumatic paresis of right obliquus inferior (see Trans. Am. Oph. Soc., 1877). It must, moreover, be emphasized that examinations at the working point should be made not on a horizontal but on a plane 15° below the horizon, for this is the physiological primary position of fixation (Aubert, G. and S.). It cannot, however, be denied that cases exist in which hyperphoria throws other sets of muscles into spasm and irregular action, giving incongruous findings with prisms, and relief is only gained upon removal of the discord in the muscles of elevation or depression (see Stevens, l. c., p. 165).

It may be well to remark here upon a special symptom seen rarely and in severe neurasthenic cases, viz., retinal anæsthesia. It consists in limitation of the visual field, rarely in hemianopsia, and still more rarely in general reduction of light perception. There are no abnormal appearances with the ophthalmoscope. Wilbrand[1] called attention to it, and Priestley Smith[2] has related cases. If the visual field be examined by the perimeter more than once, the field will be found smaller on each successive trial, and Priestley Smith therefore refers to this as a spiral limitation, and calls it a reflex amblyopia due to an impoverished state of the blood, and excitation of the vaso-motor nerves causing arterial contraction. I have observed a few cases, and clinically they differ from migraine in being caused by fatigue of the eyes. See case by Stewart.[3]

[1] Archives of Ophthalm., xii., 428, 1884.
[2] Ophthalmic Review, vol. iii., p. 140, 1884.
[3] American Journal of Ophthal., Vol. 7, 184, July, 1888.

Digitized by Internet Archive

Asthenopia associated with disorders of the nasal cavity deserves special mention—the connection between chronic palpebral conjunctivitis and nasal catarrh has been referred to, and for a long time it has been the occasion in my own practice for treating nasal catarrh to cure the palpebral disease. Within a few years several authors have written upon it (see Nieden[1]), but something less simple and obvious sometimes appears in the phenomena of pronounced asthenopia. To these cases Nieden refers in a brief paragraph (l. c., p. 419), and a very marked instance recently occurred in the person of a medical friend, which may be briefly described.

Dr. T. E. S., aged 44, a hard-working and distinguished practitioner of New York, given to microscopy and book making, found his eyes give out in 1886. He consulted a competent oculist, who gave him various glasses with incomplete success. He went away for a vacation and under advice of another able oculist he underwent the use of atropia for five weeks, and received a modified formula for glasses: viz., O.D. + 1.25s D⌒ + 0.25cD 90° visus $\frac{20}{20}$; O.S. + 1.25c D ⌒ + 0.50c 90° visus $\frac{20}{20}$. A note by the physician also stated that there was want of energy in the internal recti muscles, and excessive power in the superior rectus of the left; that headaches were due to excessive strain of accommodation. He wore glasses in accordance with the above formula with the addition of a prism $\frac{1}{2}$° base down for O. S. For reading + 0.75 D was added to the above. His distressing symptoms had continued two years, consisting of pains in the head, heat at the vertex, insomnia, inability to use his eyes and the effort would be followed by facial neuralgia. He had intense photophobia and had worn dark blue glasses for months. He had had much mental strain outside of his professional work, and his case was evidently a complex of local eye troubles, with refractive and muscular and general nerve exhaustion. A marked symptom was extreme palpebral congestion, and tendency to lachrymation on exposure to light and attempting eye work. So pre-eminent was this feature that I was led to inquire into the condition of the nasal cavity. I found the passages narrow with slight protuberance of the septum from undue thickening, decided congestion, tenderness on being touched, and anæsthesia by cocaine afforded relief in some measure to the eye symptoms.

Careful examination of refractive and muscular conditions showed that at 18′ adduction = 15°, abduction = 7°; the ophthalmometer gave astigmatism, O.D. 1.50 D 75° ± 165°; O.S. 1.25 D 90° ± 180°.[2] It was evident from the variability of his answers to the muscular and refractive tests that there was much spasm both of the extrinsic and ciliary muscles. Guided by his previous treatment and the present symptoms, I determined to attack the nasal disease and made several applications of spray. Relief was experienced, and on hearing that he suffered from asthmatic attacks, that his breathing at night was much embarrassed and must be done with open mouth, I determined to enlarge the nasal aperture, both to get rid of a hypersensitive surface and to afford more air space. I removed a projection of the septum on the left side with the saw. Marked improvement quickly took place. He took horseback exercise with enjoyment; within a month reported that he "felt young and frisky." The glasses were slightly modified—the photophobia soon abated and practically disappeared. Muscular spasm ceased, all headache and neuralgia vanished. Within four months he laid aside glasses, was restored to comfort, and is

[1] Arch. of Ophth., vol. xvi., No. 4, 1887, p. 416.

[2] The sign ± signifies either + or −, and denotes ophthalmometric measurement, by the instrument of Javal-Schiötz.

firmly convinced that the key to his symptoms was a neurosis proceeding from the nasal mucous membrane.

With the symptoms above detailed, it seems unnecessary to enlarge on this topic, and one may learn to give heed to nasal complications in certain asthenopic cases, and be ready to employ well-recognized methods of treatment.

With the above data before us, which will be conveniently put in tabular form, we are called upon to judge what is the real diagnosis. We must compare adduction with abduction, both for distance and for the near, must observe the findings of the equilibrium test in both regions. We meet with very various conditions and combinations. We have, for example, the following: 1, defective adduction both remote and near, *i.e.*, insufficiency of interni, especially with myopia; 2, defective abduction both remote and near, *i.e.*, insufficiency of externi; this is often really spasm of the interni, and there may be slight hyperopia or astigmatism; 3, defective adduction for the working point, but not at a distance—this commonly points to pure exhaustion and is to be so managed; 4, defective abduction greater for the working point than for distance, *i.e.*, insufficiency of externi greater at 13″ than at 20 feet; 5, defective abduction for distance and defective adduction at the working point, *i.e.*, insufficiency of externi for 20 feet and of interni for the near; 6, general muscular weakness for all distances.

We may find low abduction and adduction at 20 feet, viz., abd. = 3°, add. = 8°, and symptoms severe. The muscular relations for distance and near may be entirely reversed. We must, in such cases, look for vertical error and take great pains by darkening the room, using a red glass, rotating the head and moving it up and down as above described. In a limited number of cases we will be rewarded by finding that hyperphoria is the peccant cause. I do not habitually look for this error in the order which I have given in the description of the examination, because, having given careful attention to it after reading the statements of Stevens, l. c., p. 158, I found myself unable to agree with the impression made as to the frequent hurtful influence of this error. It must not, however, be forgotten. Many times have I seen all symptoms disappear when other errors of which hyperphoria was an accompaniment have been corrected.

We have symptoms of muscular asthenopia most often in cases where muscular groups are not properly balanced or proportioned. We may also have it when there is debility of the whole muscular apparatus, without special disproportion among the opposing groups. It is not, however, an invariable rule that general weakness of the eye muscles of necessity causes asthenopia. A large margin must be allowed for what may be called nervous excitability or activity. Those of quick and eager and vivid perceptions, whose

Digitized by Illinois College of Optometry

mental processes are always lively and ready, are the persons most liable to complain, and they generally have corresponding rapidity in all bodily movements. The more quiet or torpid or deliberate persons are less often sufferers from muscular asthenopia. It must be remarked that young subjects are by no means seldom affected by muscular asthenopia. I have treated many between seven and fifteen years of age and some by tenotomy.

It is in a just appreciation of the ocular symptoms and of the constitutional conditions and characteristics, that the wisdom and skill of the physician are put to the test. We deal with inconstant factors and must weigh probabilities. The neurasthenic complications are the chief source of embarrassmeut, both in diagnosis and treatment. One cannot too much emphasize the importance of keeping in mind the neurotic element, nor may one neglect or despise the advantage often possible by seemingly trivial optical corrections.

Treatment.—This is constitutional and rational, or local and optical, or both combined. Often it is a nice point to be settled, which is to predominate. It is of course never wrong to promote the general vigor and remove any organic or functional lesions which are acting as predisposing causes, and may be also the only effective causes. I need not emphasize this side of treatment, because it appeals to the good sense of every physician, and I heartily concur in its value and importance. In due order come all measures to stimulate the general welfare, bodily and mental, viz., exercise in the open air according to the capacity and situation of the person, sufficient sleep, proper diet, friction of the skin, or the Turkish bath, regulated massage, horseback riding, gymnastics under discreet supervision, etc. In many cases we must give general tonics, and especially strychnia, phosphorus, tonic bitters, iron, quinine, etc., and remedies to correct or improve digestion, etc.

Next, the special conditions of the eye are to be taken in hand. We search out and correct all errors of refraction, and do it in obstinate or severe cases most minutely, and often with the help of the full effect of atropine. We also include herewith troubles of accommodation. Pilocarpine muriate, gr. iv. ad ℥ i., will sometimes be useful, and weak solution of sulph. eserine may be tried as local remedies, but before resorting to these, all optical error must be eliminated. In case there be no refractive or accommodative error, and the muscular fault is general debility, rather than special disharmony, we may resort to systematic exercise of the eyes. According to the suggestion of Dr. E. Dyer (see Trans. Am. Oph. Soc., vol. i., p. 28, 1865), the patient is instructed to begin to read for three, five, or fifteen minutes once or twice daily; to do so after a meal and by good light. Sometimes

Digitized by the Internet Archive

a weak convex glass, or a weak prism 2° or 3° for each eye, with base inward, is given. Each day the period of reading is increased by one minute or by two minutes, and the most scrupulous exactness is insisted on. In place of reading, other work may be substituted, but the great matter is to regulate and systematize the eye work. Combined with this proceeding, the galvanic battery, either the constant or interrupted current for a few minutes, with one pole to the closed eyes and one pole on the temple, has some, yet small, value. Stimulating liniments to the forehead and temples of aconite, or of chloral and camphor, etc., are useful when there is neuralgia. The douche or spray of cold water, or mild lotions to the eyes, viz., borax and camphor-water, are all helpful. In some cases, notwithstanding refractive errors are slight, it is best to prescribe the wearing of glasses, especially if convex or cylindric, all the time. The behavior of the muscles, both with and without the glasses, will help to decide this point.

Another mode of invigorating the eye-muscles, and which is especially suited to the cases where all the muscles are feeble, is by using prisms as means of gymnastic training. Dyer's method deals with muscular action and accommodation together; by gymnastic prisms the extrinsic muscles alone are acted upon. The patient is provided with prisms of 2½°, 5°, two of 10°, and one of 15°, with squared outlines. He takes a candle-flame or door-knob at twenty feet for his object, and performs the efforts of adduction and abduction by means of these prisms. He begins, say with adduction, and at first holds the prism of 5° with base out, in front of one eye, then substitutes the 10°, then before the other eye, places 5°, making a total of 15°; then, if practicable, substitutes the other prism of 10° for the 5°, and so climbs up the ladder of adductive prisms by such steps as he can make. If the interval of 5° becomes too great, he may take that of 2½°. On the other hand, he will in a similar way train the abductive muscles by putting before one eye with its base inward, the prism of 2½°, then that of 5°, then one before each eye, and finally, may possibly reach the 10°. To reach an adductive power of 42½° and an abductive power of 10° will require sometimes several weeks, and when attained should be practised once or twice daily. The daily session need not occupy more than ten minutes, and need not be more frequent than twice. There are few cases to which this method is well suited, and one need not spend much time over it. Improvement in adduction is often gained, but seldom in abduction. Some special disharmony will usually be discovered. Sometimes it will be preferable for the physician to superintend the prism practice, both for its beneficial effect and to elucidate the diagnosis.

If muscular defect be combined with important refractive error,

Digitized by Illinois College of Optometry

we have most frequently myopia with insufficiency of the interni, which may be relieved either, 1st, by wearing the full optical correction continually; or, 2d, by using for near work a glass which pushes out the near-point to 8″, to 12″, or to 14″, and which may be of about half the power of the full correction; or, 3d, with the glass just mentioned a prism may be combined, or the glasses may perhaps be given an adequate prismatic quality by having them set in the frame with their centres outside the visual lines. This brings the inner thick edge of the glass into use, whereby it will have a low prismatic effect. For the rare cases of myopia with insufficiency of the externi, optical corrections alone are not often available. With hyperopia similar methods of proceeding may be adopted, but with such adjustment of prisms as the kind of muscular error calls for. With emmetropia one finds less certainty in the helpfulness of prisms to aid the performance of near work. They sometimes are utterly intolerable, even with decided muscular error.

In deciding how strong the prisms are to be, we first decide the proper working distance, and the correcting-glass, which for this point is required, and with it ascertain the muscular error. To give prisms equal to one-half the amount of error is usually sufficient. If we estimate the insufficiency at say 10°, we may order the prisms each 3°, one before each eye. It is only when error is decidedly more on one eye than on the other that the prisms are made unequal. But for quantities so large, tenotomy is preferable.

The cases of muscular asthenopia without any or any important refractive error are much more frequent than has been supposed. By far the largest quota present insufficiency of the external recti. To these cases my attention has been pointedly called within a few years;[1] and they become in my experience more and more conspicuous. They are recognized by the tests at a distance rather than by those for the near.

To form some idea of the refractive conditions in muscular asthenopia, one hundred consecutive cases for which prisms were deemed suitable are quoted. They are taken from my series of records of muscular error noted from C 826 to C 969, in all 144 cases. The 44 rejected were either not counted suitable for prisms or were not observed long enough to be valuable; some were purely neurotic cases, some exhibited weakness of all the ocular muscles, and some were operative cases. Emmetropia including those with H not exceeding + 0.50 D = 52; H from .75 D to 2.75 D = 24; Ash from + 0.75 D to + 2.00 D = 3; mixed astig. 4.50 = 1. Total, 100.

Of the 24 cases of H, 11 were of 0.75 D, giving 63 cases in which

[1] See paper "On the Tests for Muscular Asthenopia, and on Insufficiency of the External Recti Muscles." Trans. of Eighth Session of the International Medical Congress, Copenhagen, 1884.

Digitized by Harvard College Library

the amount of H was insignificant and was certainly not the important factor. Alongside of these may be placed 11 cases of Ash of + 0.75 D, although in them more stress is to be laid upon the refractive error than for simple H. Astigmatism of all kinds claims 21 cases; and myopia 3. A further interest attaches to the kind of muscular error, and herein my views published in 1884, and quoted in the 1st edition of this text-book, p. 201, 1890, are fully corroborated by additional experience. Insufficiency of recti externi = 73; insufficiency of recti interni = 26; vertical error = 1; total =100. The similarity of results is remarkable because in 1884 I found 74% of recti externi, and in 1892 I find 73% of the same. A further analysis giving the refractive conditions under the separate types of muscular error shows the following:

Insuf. externi,	E error not exceeding +.50	36
	H	19
	M	2
	Ash	13
	Asm	2
	Antimetropia	1
		73

Emmetropia, hyperopia, and hyperopic astigmatism include 68 cases, and while the refractive error was in most cases corrected, this alone did not give relief. It is quite admissible to suppose that spasm of the interni is more at fault than defect of the externi, and this is doubtless the true pathogenesis of most cases, and that the weakness of externi is secondary. The result of treatment in the abandonment of prisms after a certain time, often demonstrates this to be true. It might in some cases, perhaps, have been possible to break the morbid chain by prescribing atropine for three to six weeks, but *cui bono?* Prisms meet the indications.

Insuf. interni,	E error not exceeding + 0.50	16
	H	5
	Ash	4
	Asm	1
		26

Among these cases spasm is necessarily excluded, and they furnish a sufficient answer to the objection made against my views of these cases, that they represent simply minor degrees of uncorrected hyperopic error rather than real muscular faults. Among them emmetropia and hyperopia and hyperopic astigmatism

Digitized by Illinois College of Optometry

count for 25%. I need not press the logical value of these cases; they eliminate all that might be urged in opposition on the ground of personal bias. To complete the cases there was one of vertical error—giving this form of trouble (hyperphoria) the very modest showing of 1%. It is right to add that among the 44 rejected cases were 6 in which vertical error was noted, making out of 144 cases of all kinds of muscular trouble almost 5% of this type.

It is common to find that wearing prisms a little while increases the manifest amount of muscular weakness. I speak particularly of the externi, in other words the abductive power is less. The explanation simply is that the overtasked muscles give up the struggle and lean on the glasses. Hence it frequently follows that prisms are a prelude to tenotomy. This comes about when pain returns, in spite of prisms. I once increased the angle of adductive prisms for weak externi up to 7° for each eye in obedience to the demands of a patient, who refused tenotomy, but for whom it was finally done with most brilliant result.

That prisms so weak as $1\frac{1}{2}°$ are capable of producing positive and beneficial effects is not only attested abundantly by experience, but a sufficient reason is found in the degree of convergence which they induce. Instead of parallelism we have an abatement of one-half a metric angle for the interocular distance of 60 mm. And this is in reality one-sixth of the effort required at the assumed working point of $\frac{1}{3}$ metre or 3 metric angles. A constant abatement of abduction amounting to 16% of this requirement is certainly not insignificant.

If there be insufficiency of the interni for distance, we may uniformly expect the same at the working point. It may, however, not exist at the remote end, and exist at the proximal end of the binocular visual line. On the other hand, insufficiency of the externi may occur at the distal end and be greater at the proximal, or it may change to insufficiency of the interni. We may sometimes properly give prisms of different degrees for the respective positions, but we ought not to give adductive prisms for distance and abductive for near, until the full benefit of the former has been developed by wearing them many weeks. It may also be remarked that weak convex glasses sometimes take the place of adductive prisms for near work, but not often in subjects with vigorous accommodation. My conclusion from ample experience is strongly in favor of the helpfulness of weak prisms continuously worn, for moderate degrees of muscular error, and they have in my practice largely taken the place of Dyer's method, of gymnastic prisms and of the various palliative proceedings above referred to.

In giving prisms the rule may be formulated that the base should be placed toward the image whose position is to be corrected, and this corresponds to the weak muscle, provided the phy-

Digitized by Illinois College of Optometry

siological or functional action of the muscle is regarded. The apex of the prism like a knife edge indicates the muscle which should be weakened and the base denotes the muscle to be strengthened.

The resort to operation is next to be discussed. It was employed by French surgeons,[1] Bonnet, Guérin, Cunier, so long ago as 1841 for the cases now under consideration, but intelligent adaptation of it was first proposed by v. Graefe[2] in 1869. He especially developed its employment for deficient adduction in myopia. We have learned by large and ofttimes deplorable experience that very great discrimination must be used when we employ surgical means for a functional muscular error. We must clearly recognize the distinction already indicated between cases purely muscular, and cases where muscular errors are symptomatic of nervous disturbances. These latter are of obscure pathology and a simple mechanical correction may utterly fail of relief. It may be temporary or partial, or it may issue in diplopia excessively distressing, or in aggravation of previous sufferings. It is very difficult to formulate rules for these cases, because we meet with such diverse conditions.

The operations may have uncertain results, and must always be done without general anæsthesia; happily cocaine renders this entirely feasible. The effect must be measured immediately by prisms, and be controlled at least as soon as the following day, because it may be in excess or deficient. Generally complete tenotomy has been done; by some partial tenotomy has been employed (Alfred Graefe, Abadie, etc.), while Stevens employs "graduated tenotomy," which seems to be almost a full tenotomy, l. c., p. 173; but he also seems to practise frequent partial tenotomies at intervals of weeks or months, until the desired result is achieved. With complete tenotomy the effect depends upon the extent to which the oculo-orbital fascia is loosened (capsule of Tenon), and this tissue varies much in density in different persons. As supplementary to tenotomy, or as a substitute for it, Wecker has proposed advancement of the oculo-orbital fascia; while advancement of the tendon of the weak muscle is sometimes done.

The cases in which undoubted benefit is to be expected are those in which the fault, whether of adduction or abduction, is of the same quality both for distance and near, and in which there is a strong impulse to binocular vision. With decided myopia, with anisometropia, with monocular amblyopia, the latter condition is imperfectly fulfilled or is wanting. An operation *may* be advisable, but the result will be less certain. When, however, the cases are of the

[1] Annales d'Oculistique, tome v., p. 139, and tome vii., p. 73.
[2] Klinische Monatsblätter, 1869.

Digitized by the Internet Archive

suitable kind, the surprising result is often seen, that the amount gained by the weak muscles is greatly in excess of the amount subtracted from the robust muscles; particularly is this true with insufficiency of the externi. This proves that we deal with functional conditions, viz., spasm and not exclusively with mechanical data.

The effects of an operation may be satisfactory for some time and be followed by renewal of asthenopia and of the evidences of muscular error. It can also occur that the muscular discordances may after months be re-established, while no asthenopic symptoms have recurred.

Cases which show a marked abridgment of muscular power at both ends of the visual line are unsuited to an operation. For them, prisms, regulated exercise, and general tonic measures are all that can be safely tried and some of these patients are in a pitiable condition. For them, advancement of weak muscles has been proposed, and Landolt records some successes. He also narrates, with commendable candor, grievous failures.[1] There is always risk in advancement, of twisting the vertical meridian and introducing a new and most serious element of asthenopic disturbance. Yet by extremely careful operation and after-treatment this may be avoided.

The results of a tenotomy may be satisfactory both mechanically and functionally for months, and by gradual relaxation of the cicatrix, diplopia may at length ensue and great annoyance. The field of diplopia may be lateral, not nearer than 25° from the median plane, and yet occasion great discomfort. If concave or prismatic or other glasses are worn, the error may be partially or sometimes wholly obviated. If, however, the field of double vision come close to the median plane, great disturbance follows. Sometimes a patient learns to ignore the image of one eye, but the situation is regrettable.

It may be accepted as settled that tenotomy with free dissection of surrounding tissue is not fitting in muscular asthenopia; that with high degrees it is better to divide the operation between two eyes and at a considerable interval; the incision should be exactly at the implantation of the tendon and not in front of it. Graefe's rule of operating applied almost exclusively to cases of marked myopia, principally for insufficiency of the interni, and was to the effect that the eyes must be in equilibrium for a point about 20° on the side of the divided muscle, and on a plane 15° below the horizon. If for example, the left externus is divided, the patient, with a red

[1] "Refractive Accommodation of the Eye," translation, Edinburgh, 1886, p. 510.

Digitized by the College of Physicians Library

glass before one eye, should see a candle flame singly when held to the right 20° from the median plane of the face, and depressed about 15° below the horizon. A prism with base vertical is to be put in front of one eye, and the two flames must stand perpendicularly when the candle is put in the place of election above designated. An error of 3° in excess is to be corrected by a suture which shall include the conjunctiva and more or less of the tendon.

This proceeding is oftentimes too liberal and liable to leave diplopia, or such weakness of externi as to introduce another kind of asthenopia. He assumed that the muscle to be divided must always have a superfluity of energy, whereas experience shows that this may be far otherwise. It is safer to test the result of the operation on the median plane, and the weakened muscle must always be capable of exertion. In this position an excess of 2° or 3° is not serious, is often allowable, but the due preponderance of the interni must always be respected, and some abductive power, say 2° or 3°, should always remain.

The test by a vertical prism is to some degree fallacious. It does not always teach the true place of equilibrium and if it show remaining error, while tests of adduction and abduction are satisfactory, the evidence of the latter is to be preferred until future developments indicate what should be done.

My preference has been to perform complete tenotomy and control its effect by a suture. Partial[1] tenotomies have in my experience been extremely uncertain and usually ineffective. With their frequent repetition at intervals of one or several weeks, as done by Stevens, I have had no experience. In operating, use a 4% solution of cocaine. The wound is to be over the middle of the tendon and it is best to use forceps with projecting teeth which shall seize both tendon and conjunctiva. The scissors should be sharp-pointed and curved on the flat, the tendon is cut close at the sclera (a very useful scissors has been devised by Stevens, with blades made narrow for about one-third of an inch from the slightly blunted points; they are curved on the flat); carry under it a very small blunt hook, and cut off the insertion of the upper half of the tendon, one blade of the scissors being in front of, and one behind the insertion; put a second hook under the lower half of the tendon and similarly sever that. Keep close to the insertion and endeavor to avoid bleeding. Dr. Stevens' scissors with much reduced tips are well suited to making small wounds and may render the use of hooks unnecessary. Immediately test the effect by prisms and the candle, and modify the proceeding either for increase or diminution. Endeavor to make the wounds so small as not to need a suture, but if

[1] See Standish, Trans. Am. Oph. Soc., 1889, p. 386, who practised partial tenotomy, with good effect, but the amount divided was not small.

Digitized by Illinois College of Optometry

too much effect has ensued, it must be employed. A light bandage may or may not be used, and usually 10 to 20 grains of phenacetine will be needed in two hours. There will be in normal cases a reduction of effect during the next two weeks; sometimes this needs to be opposed by wearing prisms suitably placed. The immediate result of an operation will vary from 6° to 15°, and each case must be regulated according to its own peculiarities. It may happen that very little effect ensues, while on the contrary for apparently equal amounts of interference a large deviation may follow. This uncertainty depends both on the muscular power of the antagonist and on the density of the capsule of Tenon. Effects so small as 5° may easily be secured. Partial tenotomy may give effects varying from 0° to 3°. If it do good, as is alleged, the effect must largely depend on setting aside a state of muscular spasm, about whose existence I think, with Loring, there can be no doubt.—See Trans. Am. Oph. Soc.

If the interni are to be relieved in cases of myopia by division of the externi, it is wise not to have more than 3° convergence on the median line. This will after a few weeks permit of a second operation at which a closer correction can be secured. The ultimate result after six or twelve months is liable to be quite different, either by return of the original disproportion, or free tenotomy may eventuate in permanent homonymous diplopia. For this reason it is wise to proceed by careful steps as indications arise. Partial alleviation of symptoms is more frequent than complete cure.

In operating on the interni for relief of the externi, one may aim at an immediate abduction of 8° or 12° according to the power of adduction. The higher the adduction, say if 50° and more, the greater will be the permissible amount of abduction procured, even to 15°. But with adduction not above 30° caution must be used and the resulting abduction kept below 10°. Sometimes only a slight effect is immediately gained, which increases within four days. In other cases the maximum is at once attained. Increased effect can be secured by wearing appropriate prisms. In all cases close attention must be given to the daily progress of events, and when needful, interference promptly employed. If an excessive effect appear, a correcting stitch can be inserted on the second or third day, by opening the wound with a fine strabismus hook.

It is hard to resist the temptation to quote cases, but that would open too wide a gate. Without abating the general approval which is intended to be placed upon tenotomy for the relief of headache, eye-strain, and irritations, both local and general, and placing myself squarely among its staunch advocates, some results of experience which have been contrary to just expectations must be candidly mentioned. I have in three cases done tenotomy of the interni for extreme headache in persons who had marked de-

Digitized by Illinois College of Optometry

grees of insufficiency of the externi. They were highly neurotic. There ensued great relief of headache, but the capacity for eye work was deplorably abridged, although diplopia was not produced. Schweigger's small perimeter is the best instrument for ascertaining the lateral limits of binocular fixation. On the other hand my present attitude on this subject is justified by the case of a gentleman *having myopia and weak externi*, seen first in 1863, who was then forty years of age. He had myopic astigmatism $-\frac{1}{11}$s.⌒$-\frac{1}{20}$c. V$=\frac{20}{xxx}$. Always had headaches. Was treated by cups to temples, mustard footbaths, bichloride hyd., and gained no relief from headache by glasses or by treatment. In 1888 was found to have commencing sclerosis of lens in O. S. and vision very defective. In O. D. $-$ 4.50s.⌒$-$ 1.00c. 90°. V = 0.6. In 1890 O. D. about same; O. S., V = fingers at two feet. Continues to complain of headache, often waking with it in the morning; cannot wear distance glasses with comfort. Find that he has homonymous diplopia at 18′, both with and without glasses, requiring prism 9°. Ordered prisms O. D. 5°, O. S. 4°. In five days convergence increased to 15° at 18′, while without glasses at 10″ has 9° divergence; with $-$ 2D at 13″ has equilibrium. After wearing prisms sixteen days reported almost complete relief of headache. One week later found at 18′ convergence of 15° permanent with diplopia and did tenotomy of rectus internus O. S. The effect was at first controlled by stitches, but these were removed, and finally at 18′ a convergence of 7° was left. This on the next day was reduced to 3°. In four days the convergence at 18′ was 1°. For twelve days kept a patch over operated eye. For 18′ has equilibrium, but very little muscular flexibility, to which the extremely dim vision of O. S. (cataract) contributes. For the near point has crossed diplopia (divergence) of about 50°. By wearing full correction this is removed; with his glasses at 18′ abd. = 0°, add. = 8°. Has considerable difficulty in binocular vision for the near. Eight months after the operation reported that there had been great diminution in the frequency of headaches; they would sometimes come and were severe. Cannot use eyes any more than he did previous to the tenotomy. Still has some diplopia, but images at 18′ very close together. This case was a rare one of weak externi in myopic eyes. Not recognized when first seen in 1863, and not until twenty-seven years had passed, when patient had become sixty-nine years old. The nervous strain remained, the muscles were necessarily very weak, and the partial response to their relaxation by both prisms and tenotomy is a convincing argument in favor of the views presented. Perhaps a more careful tenotomy followed by another operation after a few months would have given better results.

Another case of exceptional type, but having the guarantee of success by tenotomy after eighteen years' experience, is one of hyperopia with insufficiency of interni. E. N. B., a boy, thirteen years, with O. D. $+\frac{1}{8}$, V$=\frac{20}{30}$; O. S. $+\frac{1}{8}$, V$=\frac{20}{40}$. Had severe pains and occasional diplopia. For six months wore $+\frac{1}{8}$⌒ prism 4° base inward. In January, 1869, did tenotomy of both externi at one sitting. The measurements of muscular error are not complete. It appears that with his glasses and vertical diplopia there was 6° divergence at 20′ and 14° divergence at 12″. Six weeks later had with glasses at 20′ add. 10°, abd. 3°. In 1873 was examined again, and vision had improved. O. D. $+\frac{1}{10}$, V$=\frac{20}{xx}$; O. S. $+\frac{1}{10}$s. $-\frac{1}{60}$c. 180°, V$=\frac{20}{xxx}$. With glasses at 20′ add. = 16, abd. = O, with v.d. 4° convergence; with glasses at 12″ v. d. 7° divergence. Is preparing for college and reads three to four hours daily without pain. In 1887 was informed that he is practising law in Ohio and eyes never give any trouble.

In 1865 a boy, fifteen years, with M$\frac{1}{8}$ and insufficiency of interni, had complained of pain and asthenopia for four years. Material relief was gained

by $-\frac{1}{12}\subset$ prisms 4° bases inward. The amount of error is given only for 12″, viz, 12° divergence with vertical prism. The rectus externus O. D. was divided. The consequent homonymous diplopia continued for a short time and gave place to normal motility. Symptoms disappeared. After two years, viz., in 1868, trouble again came on, bringing about the discovery and correction of an important amount of astigmatism. He was ordered:

O. D. $-\frac{1}{4}$s. $\subset\frac{1}{10}$c. 180°c. V $=\frac{20}{30}+$.
O. S. $-\frac{1}{5\frac{1}{2}}$s. $\subset\frac{1}{11}$c. 180°c. V $=\frac{20}{30}+$.

For reading:

O. D. $-\frac{1}{14}$s. $\subset-\frac{1}{10}$c. 180°.
O. S. $-\frac{1}{8}$s. $\subset\frac{1}{10}$c. 180°.

Up to 1889 the correcting glass remained almost unchanged and visual acuity was normal. He went through college, became a lawyer, always read prodigiously and rapidly. The muscular conditions then (1889) determined were:

At 18′ with glasses abd. = 5°, add. = 15°, with v. d.$\frac{\frown}{\frown}$.
At 13″ with glasses abd. = 15°, add. = 18°, with v. d. = 5° div.

In March, 1892, the record was substantially the same. He has never made any complaint about his eyes and continues to use them unsparingly. In his case the cause of trouble was the muscular disturbance. Later the astigmatism came to the front. The preservation of healthful and vigorous eyes with notable and unequal degrees of myopia throughout a period of twenty-seven years under observation is an encouraging and noteworthy fact. It is right to say that during twenty years he employed one pair of glasses for all work; that there has not been any choroidal crescent about the nerves; that in 1873 he had the power of overcoming a prism of 10° with base vertical.

My experience on this subject within ten years has been very large, and to cases within this period I make no reference. Examinations have been made more precise and interference has been ventured on in cases for which formerly nothing operative would have been done. The combination of prudence and boldness is absolutely essential in all these cases.

Reference has been made to errors in a vertical plane as well as in simple adduction and abduction. Dr. Stevens[1] finds these quite frequent and operates for them when not greater than 1° or 3°. I have sometimes corrected them by prisms and have in a few instances operated. I have found in most cases that correction of errors of adduction and abduction carried with it the adjustment of the error in the vertical meridian and that patients desired nothing more.

A few words may be said about advancement as contributory to better equilibrium of muscles. My experience with this proceeding for asthenopia is recent and limited. I have had to do it for the undue effects left after tenotomy done both by myself and others, and have also done it to reinforce tenotomy of antagonists. If one secures small curved needles, the so-called "quarter round," and has them sharpened as if they were meant to penetrate the cornea, there will be little difficulty in accurately dosing the effect of the

[1] Archives for Ophthal., xvi., 2, June, 1887, p. 149.

Digitized by University of Illinois College of Medicine

proceeding. A sufficient crescentic piece of conjunctiva must be excised right over the site of the insertion, the stitches must include the tendon and superjacent fascia, and the thread must have a needle at each end. To get a good anterior hold, the needle will go through the sclera easily and deeply enough, to answer all required traction, while the approximation of the wound will be done by forceps seizing the parts if there be much separation. One may use two or three sutures and I have found no puckering and very little reaction. In two instances I have taken a piece out of the tendon and stitched the distal part to a bit of the insertion left as a stump. Dr. Stevens practises an operation of this kind with very little dissection of tissues. Experience is as yet so limited, that one can only suggest rather than recommend.

The topic we have thus considered is one which is at the present time actively discussed among ophthalmologists. Opinions vary, and the writer, while frankly avowing his own views, founded on a large experience, has only stated what thoughtful and careful observation has taught him. Many things have been left unsaid, because in this field clinical experience is wonderfully diversified and more detail would hardly be suited to a text-book. Even the insertion of illustrative cases, to which there is strong temptation, would demand more space for adequate presentation of the varied phases of the conditions we meet than can be afforded.

See Burnett, "Contributions to the Study of Heterophoria," Trans. Am. Oph. Soc., 1891, p. 217—a well-digested statement of cases.

Digitized by Illinois College of Optometry

PART SECOND.

CHAPTER I.

GENERAL TREATMENT OF DISEASES OF THE EYE.

We first speak of its proper protection from hurtful influences, viz.: from dust, smoke, glaring light, and extreme heat, by colored or transparent glasses, by shades, by seeking another locality, by a bandage, by seclusion in a dark room or in bed. Protective glasses are known usually as coquilles, are shaped like a watch-glass, and tinted either London smoke or blue, in various shades, known by letters A, B, C, D, etc. Very dark shades are objectionable in most cases, because they so diminish the light that the eyes are strained in groping about. The neutral tint is generally better than the blue. Blue glasses improve the distinctness of sight to some degree, in certain conditions. Workmen exposed to injury by chips of metal may wear large glasses of mica, if they will, but they are seldom inclined to accept them. Eye-shades may be single or double; they should be shaped according to their purpose; if to cut off light from above, as in reading, they should flare like a cap-front; to cut off light in all directions, they should lie flat and come around well on the temple. To lie flat, they should have a notch for the nose, be three inches wide, come to the temples, and will be kept flat by having the strings fastened three-fourths of an inch below the corners; these must go twice around the head. A monocular shade to keep the lids closed, should be an oval whose length should be about two and one-half inches, and breadth one and three-fourths inches—the string fastened at the ends, and to go obliquely over the forehead and under the corresponding ear. If required, a packing of cotton may be put under it. A bandage should be made of thin flannel (*i.e.*, merino, which is a texture of both wool and cotton), be three and one-half yards long, and one and one-half inches wide, for an adult. In summer, muslin gauze may be substituted. The width will be less in some cases, and always less for children. It goes about the head like a figure eight, and presses

the eyeballs through a packing of absorbent cotton laid upon patches of muslin. To adjust a single or double bandage smoothly and firmly, requires a little practice. It is usually employed where some pressure is to be exerted on the eye. Some ophthalmic surgeons prefer silk plaster which may be white or black and is laid on in strips or in one patch. When patients are kept in dark rooms, it is important not to have streaks of bright light at the edges of the shades or in the shutters. It hardly need be said that a patient wearing a bandage need not be imprisoned in a dark room; the moral influence is bad, and the physical effect on his attendants equally bad. I have known delirium produced by no other cause, in old people, after cataract extraction. With dark rooms, unusual care must be given to ventilation and cleanliness. Many serious eye diseases require confinement to bed, and often it is difficult to make a patient submit to the hardship. The object is quietude of the whole body and absolute rest of the eyes, which a patient sitting in a chair or walking about under a bandage will not and cannot so perfectly maintain. I advocate this only during the active period of acute disease—never in case the general health suffers or is unfavorably influencing the eye trouble. Even photophobia, which is usually the symptom necessitating seclusion in darkness, is sometimes aggravated by such confinement, especially in hysterical persons, in weakly or scrofulous children, and when the fear of light has outlasted the cause which originally excited it. To this point Dr. Agnew has called especial attention. Such persons must be provided with smoked glasses, and sent outdoors to navigate for themselves. A proper understanding of hygiene and of the conditions of healthy nutrition in food, clothing, exercise, and air and occupation, is of the utmost importance in ophthalmic treatment. I shall have to emphasize this repeatedly.

Protection from contagion may be secured by mechanical means such as bandages, and other devices, but special regard is to be paid to asepsis and antisepsis both in ocular pathology and in ocular surgery. Besides the exposure to atmospheric germs which in tenement houses, asylums, hospitals, and barracks may become very grave, we always have bacteria and cocci of various kinds contained in the conjunctival secretion. They abound in the nasal cavity and with flagrant intensity in ozæna, and may be transmitted to the eye from the nasal discharges or by the lachrymal puncta. In the eyelashes, eyebrows, on the skin of the face, both with and without eruptive diseases, by the hands, by handkerchiefs, towels, rags, etc., we have ready means of contagion. It is needless to specify all that may be possible, one must inspect the whole body and know a patient's habits and surroundings to find and remove

all the sources of contagion. Complete and strict cleanliness of person, clothing, and surroundings is the first requirement in asepsis. Disinfection of rooms and wards, by vapor of burning sulphur (with attention to the free supply at the same time of watery vapor without which it is almost inert, but with which it is most efficacious (Squibb)), and the addition of carbolic acid or corrosive sublimate to the water used in scrubbing walls and floors, are important agents. In applications to the eye we are obliged to exclude some recognized agents or greatly dilute them, because the organ is too sensitive to bear them in effective strength. We therefore rely more on asepsis, of which cleanliness is the chief condition, than on antisepsis, when surgical operations are to be done, and reserve antiseptics for pathological conditions. We shall first speak of the latter. We employ them especially in diseases of the conjunctiva and cornea, and while the utility of some of them has long been empirically known, our better knowledge of their mode of action helps us to use them more intelligently. Carbolic acid is little employed, because it must be diluted to 1% or 2% solution. Boric acid, whose solubility is 4%, has wide application, because, while not really antiseptic, it is soothing and can therefore be employed freely to wash out morbid secretions. We separate the lids and lift them from the globe, perhaps by elevators or even a speculum, or by nipping the skin of the lid with the fingers, and wash out the conjunctival sac with a rubber bulb holding about two ounces; the whole cavity must be flooded. If there be much swelling of the lid or chemosis, this may not be feasible to the full extent. Solution of corrosive sublimate 1:10,000 does not irritate, and 1:5,000 is easily borne. In severe morbid conditions even 1:2,000 may be tolerated, but the quantity will be small and a dropper employed instead of a bulb. A normal eye will sometimes show unpleasant reaction to solution 1:10,000. A third agent, and which completes the list of those most in use and commonly resorted to as antiseptics is chlorine water, or, as usually dispensed, the liquor sodæ chlorinatæ (Labarraque's solution), 1 part to 7 or 10. This is used with a dropper. Next we mention the actual cautery employed often with signal success in suppurations and ulcers of the cornea, less frequently in trachoma, either as the thermo-cautery of Paquelin or as the galvano-cautery. It will be referred to again.

Hydrochinon and resorcin in 3% solution have been employed with no special superiority over the fluids above mentioned. Salicylic acid is not much used except upon dressings. It is combined sometimes with borax, viz., a mixture of the two, each in 5% solution. Benzoate of sodium, 5%, is counted antiseptic, and thymol, 1 : 1,200, yet they are rarely used in eye surgery.

Iodoform in very fine powder—a point to be insisted on—is by

some much esteemed, yet by others is scarcely employed. Its efficacy is slow, and it must therefore be kept in contact with the tissues for a long time. It may also be mixed with vaseline and a bandage applied. Used chiefly in corneal ulceration and suppuration, it has been also lauded in purulent conjunctivitis, especially by English practitioners. Aristol is equally effective and is free from objectionable odor. Pyoktanin or methyl violet, 1 to 500 or 1 to 5,000, has value but not to a remarkable degree. Nitrate of silver plays a great part in treating external diseases of the eye, and some of its potency is due to its antiseptic properties. Marpman says that in putrefying solutions of albumen, decomposition is arrested by solutions so weak as not to cause coagulation. These will be much less than one per cent.

We might enumerate other substances habitually resorted to, whose efficacy in fact resides in their antiseptic qualities, such as yellow oxide of mercury, acetate of lead, etc., but there is no need.

In operative work, of which extraction of cataract may be taken as the type, and in which the cornea and conjunctiva are presumably normal, the employment of antiseptics has become thoroughly established. Nevertheless the same rigor is not profitable as in general surgery. Spray is never used; solutions which are in vogue are: boric acid, 3% or 4%; corrosive sublimate, 1:5,000 or 1:10,000; and biniodide of mercury, 1:20,000 to which a little alcohol is added (Panas' solution), and boiled water. As to the need for them we may bear in mind the investigations of Fick,[1] that in 49 perfectly normal conjunctival sacs, he found only 12% without bacilli, and 36 affected with slight catarrh contained them. He found bacilli, cocci, and tetrades or masses of sarcini. He enumerates seven different bacilli, three kinds of cocci, including the staphylococcus aureus, the pyogenic form, and sarcini (p. 54, l.c.). But more notable are the experiments of Gayet, of Lyons, who after carefully disinfecting the conjunctival sacs of his cataract patients, found by cultivations that microbes remained in 75%, and from 213 test-tube cultures, he concludes that antiseptic or aseptic fluids have very little influence over germs in the conjunctiva. It follows that copious washing is an essential factor, and because mercurial salts coagulate secretions, and Panas' solution, viz., hydrargyri biniodidum 1 : 20,000 is entirely unirritating, these are to be preferred when slight catarrh exists. In other cases the fluid must simply be itself free from germs and, as already said, be freely used. Hence the utility of boiled water.

We have also to bear in mind that wounds and manipulations must be made with the least possible bruising and violence, and here lies the crowning importance of neat and skilful operat-

[1] "Ueber Micro-Organismen im Conjunctivalsack." Wiesbaden, 1887.

Digitized by the Internet Archive for Ophthalmology

ing. If there be failure here, the soil is prepared in which germs delight to multiply. We must also avoid furnishing the fruitful soil in another way, viz., we must not operate if we can help it, when the constitutional conditions are unfavorable, *i.e.*, in presence of rheumatism, syphilis, or any severe dyscrasiæ; or if the disease be incurable, like diabetes, we must select the most favorable time. For similar reasons, conditions especially promotive of germ growth, like trachoma, pterygium, lachrymal diseases, chronic catarrh, must be cured, if possible, before operating. The most scrupulous care about disinfecting instruments, sponges, cotton, dressings, the hands of all who have to do with the patient, and also the surface of the patient, his clothing, bedding, etc., must not be in the least remitted or abated. For the hands nothing equals soap and water applied with a stiff brush and with the addition of powdered borax to penetrate under the nails. For instruments, soaking for thirty minutes in 5% carbolic-acid solution; while boiling water, for scissors, specula, forceps, and all instruments having joints and teeth is the best. Flat porcelain trays can be had in which to soak instruments, and some may be well brushed. The cutting edges of knives are liable to be dulled by carbolic acid, and they may be wiped with a clean rag after short immersion and then inspected with a magnifying glass. Immersion in alcohol helps to insure cleanliness by removing grease, but it is not antiseptic. Careful wiping by a moist and then by a dry rag is most essential. No specks of rust or stains should be tolerated, any more than a dull edge. In testing the edge and point, put several thicknesses of fine leather shavings or of gold beater's skin on the drum—a click or creak is the signal for rejection. If a point be merely turned, it may perhaps be straightened on the thumb nail. Test scissors on wet paper or on fibres of cotton; be specially careful about their points, and the edges should glide smoothly as the blades close.

This introduces us to the operative treatment of the eye. It has always commanded great attention, and its scope has been largely extended. A better knowledge of pathology, the invention of new methods of operating, and higher skill in the manufacture and adaptation of instruments have conspired to make the operative surgery of the eye one of the most brilliant chapters in medicine.

Some general remarks are here in place. Shall anæsthetics be used?

Since 1884, when Dr. Carl Koller called attention to the anæsthetic effect of muriate of cocaine dropped upon the eyeball, general anæsthesia has been relegated to exceptional instances, in ophthalmic surgery. A summary of the effects of cocaine upon the eye is as follows: A 2% solution, of which several drops are used,

Digitized by Illinois College of Optometry

causes at first a slight burning and smarting, then the lids open to an unusual extent, anæsthesia appears in from ten to twenty minutes, the eye becomes pale by reduction of the size of the vessels, the pupil dilates moderately and the accommodation is slightly impaired. A 4% solution acts more speedily and affects the pupil and ciliary muscle more decidedly. The anæsthesia lasts about ten minutes. If the solution is dropped in again after three or four minutes, the effects are more speedy and last for fifteen to twenty minutes. Two or three instillations of 4% solution at intervals of ten minutes is commonly used for cataract operations. For strabismus the solution must also be dropped into the wound and will often sufficiently obviate pain. For enucleation the same has been done, but with less success, and deep injections have been practised into the orbital tissue of 2% solution, but some risk of toxic effect is incurred. For iridectomy, if the iris be prolapsed, or a drop injected into the anterior chamber, pain upon excision of the iris may be abolished; otherwise not, unless a full dilatation of the pupil has been obtained, which implies its absorption and more or less decided anæsthetic effect. Besides the above effects, tension of the globe is reduced in most instances. Contrary effects, viz., increase of tension, have been exceptionally noted when there was a tendency to glaucoma and the exaggeration has been caused by mydriasis. In almost all cases tension becomes subnormal.

Its effects are exerted on both the sensory and sympathetic nerve fibres and hence its constricting influence on the vessels, and reduction of intraocular tension. It also constricts the lymphatics and hence dries the cornea, and frequently causes exfoliations and slight erosions of its epithelium. Indeed the remarkable effect was seen by Dr. Gruening of the whole epithelial covering of the cornea being lifted in a bleb, by exosmosis of the aqueous in a case of glaucoma for which he ventured to use cocaine preparatory to iridectomy. For advanced chronic glaucoma it is inexpedient to use it; for glaucoma simplex and for acute glaucoma it is admissible. In operations on the lachrymal apparatus it has very limited effect and to reach the duct effectively it must be injected by a syringe. In operations on the lids, cystic tumors, etc., hypodermic injection within the area inclosed by a clamp forceps makes it perfect master of the situation (2% solution); without the clamp it speedily diffuses and is less satisfactory. For all operations on the cornea it is invaluable, especially in removing foreign bodies, in scraping ulcers, using the actual cautery, making punctures and incisions. Even when general anæsthesia is required because of the high excitability of the patient or of the severity of the operation, it is a useful adjuvant. It has no prejudical effect on the healing process and rarely causes toxic effects.

Digitized by Google

Its application in inflammatory troubles is wide, viz., in chronic conjunctivitis, ulcers and phlyctenulæ of the cornea, in the pain of iritis, in combination with atropine, and in combination with eserine in especial cases of glaucoma where an operation is unadvisable. Its power of temporarily controlling hyperæmia as well as sensibility, suggests many opportunities for its employment. Although temporary in its effect, it gives opportunity for examinations and applications of more positive value. Where great hyperæmia exists it is less efficacious, and its hurtful effects on the corneal epithelium are less. In facial neuralgia a solution of 10% to 20% dissolved in oleic acid or mixed with lanolin and rubbed along the painful nerve has a controlling effect.

As spray in 5% or 10% solution it may be applied to trachoma, when about to be cauterized, or a fleck of absorbent cotton laid under the lid soaked in 10% solution will so much control sensibility that some patients will even bear the actual cautery in the cases suited for its employment.

Something must be said upon its toxic constitutional effects. As with all other drugs, persons exhibit most various degrees of susceptibility. The usual constitutional symptoms are imperfect and sighing breathing, pallor, indifference, unconsciousness or coma, seldom delirium, rapid and weak pulse, which often does not go above 90, but I have seen it go to 120, and may intermit and even go much higher. Less frequently there is giddiness, nausea and vomiting, slow speech, extreme sweating, a red rash, spasms of the limbs. The direct effects are on the heart and respiration. The antidotes are whiskey, ammonia, nitrite of amyl, digitalis, sinapisms, friction and heat, hypodermic injection of morphine. In very sensitive persons and for prolonged operations we must use ether and chloroform. Therefore plastic operations, many lid operations, enucleation, neurotomy, and sometimes tenotomy and often advancement of mucles will need general anæsthesia. As to operations which enter the globe: paracentesis seldom needs it; iridectomy may often be done without it, but it is more satisfactory to have the patient passive by general anæsthesia.

Dr. Norris, of Philadelphia, has lately called attention to cases of fatal results of etherization in patients having Bright's disease. Experience has shown the value of this caution. The fatal result may not occur until after forty-eight hours, and it is to be heeded especially in the fibrous kidney. For children under ten, I use chloroform, for older persons, ether by preference, but not seldom chloroform. When a long operation is expected, and the person is feeble, ether is to be chosen. For a quick operation I often administer chloroform. The primary stage of anæsthesia, before muscular relaxation has come and consciousness is not fully destroyed, and which lasts only

Digitized by Illinois College of Optometry

part of a minute, requires a very small quantity of either ether or chloroform, and can often be seized as the happy instant for making an incision which will perhaps be all of the operation that the patient would not be well able to bear. Mr. Priestley Smith has suggested a full dose of bromide of potassium an hour before an operation, as a means of allaying excitement, and rendering a patient more submissive to the anæsthetic. I often give sodii bromid. ʒ ss.–i., chloral hydrate gr. xv., the previous night, and repeat the dose an hour before the operation. The anæsthetic is more willingly accepted, and vomiting is less liable to ensue. In eye operations the ill-effects of vomiting are more serious than in general surgery, by promoting prolapse of iris, loss of vitreous, and intraocular hemorrhage. For several years I have used an ether-inhaler which is valuable

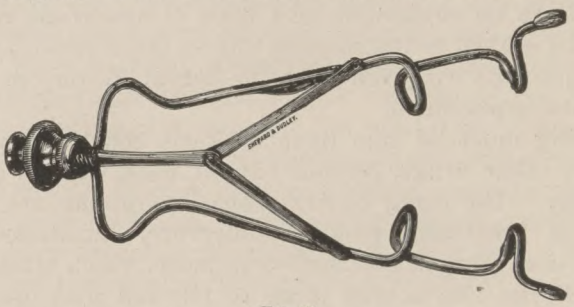

FIG. 87.

because it takes up little space and offers the least obstruction in operating about the eye. It has a rubber face-piece, and has a dried bladder at the distal end of the box, which affords space for vapor.

Eye operations should be done with the patient upon a table or a narrow bed. Operating chairs are by some preferred and may be taken into the patient's room: this applies to hospital practice. A head-rest or clamp is useful, but an assistant can do this service. An operator who is ambidextrous will always sit behind the patient's head, on whichever eye he may operate. But he will usually have to take his right hand for scissors, and sometimes, therefore, come to the front. One who is not equally apt with both hands, will change his place as the position of the eye or the place of operation requires. It is a great convenience to enjoy perfect use of both hands, but to many the accomplishment is never sufficiently realized, to warrant risking a patient's sight by a clumsy hand. As to brilliant display before spectators, no conscientious man would harbor the thought to the peril of his patient. How to gain needful skill? There must be an original endowment of facility of hand and a mechanical bent of mind. Practice upon fresh cadavers will teach something, but in them the eyes are too soft to

Digitized by Illinois College of Optometry

be suitable. Pigs' eyes mounted in an operating mask, or, in lack of this, fastened into the mouth of a bottle by a section of rubber tubing of proper size, or by strings, will teach one how to manipulate in the anterior chamber, and the resistance in cutting the cornea. A light touch and steady hand, and sensitive appreciation of weight and resistance, are essential qualities.

It is desirable to have the least number of assistants. In most cases but one is needed; sometimes a second, to give an anæsthetic and keep the head steady, is desirable. In manipulating the eye the operator should steady it by fixation forceps, and not let the assistant do it when avoidable. He thus keeps the command, and can co-ordinate his hands with accuracy. A fit speculum to keep the lids apart is an important instrument. It must open them *ad maximum;* it must not press on the globe; it must be out of the

FIG. 88

way of the operator. I have experimented extensively with these contrivances, and find none perfectly adapted to all cases. The form which I prefer is shown in Figs. 87, 88.

One which opens from the nasal side is sometimes convenient, especially if the globe is very deep, and gives a large field for work. But for deep eyes all such contrivances are imperfect, and one should have a smaller one for children and a larger one for adults. In case a speculum is impracticable, the operator may lift the upper lid himself by the point of his index finger. He draws up the lid by the skin as far as may be, then places the tip of his index beneath the edge of the lid, and pushes it back into the orbit. He does not drag or lift, but presses it under the orbital roof as he would push a sliding cover into the grooves of a box. If he does not choose to do this because the finger takes up room, he may use Desmarres' elevator, which is often necessary in examinations of the eye in children. It is made in sets of two and three sizes. Another elevator which I use in operating when a speculum has been taken out, or when I wish to expose the upper part of the globe to the fullest extent, is made of fine steel wire and presses the lid farther under the orbital roof than anything else can, and it need not make pressure upon or even touch the globe. These instruments are figured in the catalogue of Geo. Tiemann & Co., New York. A simple strabismus hook will often be valuable as an elevator.

Fixation-forceps are made with and without a spring catch.

They should be used so as to *turn* the eye, not to *drag* it; the line of push must be at a tangent to the globe. If, for instance, the eye is to be turned down, the forceps will be attached just below the corneal margin, and be held perpendicularly to the globe while the latter is rotated down and the forceps take a direction approaching a tangent. Another way, often useful, and which is very convenient for the operator, is to apply the forceps at the same place, to turn the eye by the same manœuvre, and then bring the top of the forceps up to the root of the nose, and a light push keeps the eye down and exerts the least pressure. With anæsthetics, the forceps may even be left to fall obliquely over the supra-orbital notch and keep the eye down while the operator uses his hand for another purpose. He may give the forceps to an assistant, and its position will not need to be altered. The conjunctiva is liable to tear, and the patient must be persuaded rather than forced to turn the eye as desired, while the forceps simply maintain the position aimed at.

Regarding other instruments, they will be considered when their special uses are to be described.

Medicines which have a special applicability to the eye, are those which act on the pupil and the ciliary muscle, viz., *mydriatics* and *myotics*. Of the former we have atropiæ sulphas, duboisia, homatropiæ hydrobromas, daturiæ sulphas, hydriodate of hyoscine. All of them are poisonous, and can exert toxic effects when used in sufficient strength as collyria, because they go through the cornea by endosmosis and enter the circulation by solution in the aqueous humor. They also pass down the tear-passages to the throat, and are there absorbed. Sulphate of atropia is the most common of these remedies. It affects the dilator iridis before it affects the ciliary muscle. It likewise is an anodyne to the sensitive nerves of the cornea and iris. It is used in solutions from one-fourth grain to sixteen grains to the ounce. It was erroneously thought by Graefe to relieve intra-ocular tension; when it fully paralyzes the ciliary muscle and iris, the eye often feels much relief. On the contrary, all mydriatics, even cocaine muriate at times, intensify intra-ocular pressure simply because the iris is pushed toward the angle of the anterior chamber (Holtze and Graser), while myotics diminish the pressure because the iris is pulled away from the angle. Atropia sometimes irritates the conjunctiva and after long continuance excites papillary conjunctivitis. Occasionally even the skin of the lids becomes erythematous. To render unpleasant constitutional effects less probable, atropia may be mixed with vaseline, or dissolved in castor oil (Green). If toxic effects appear, they will come as dryness of the fauces, which need not be heeded; but more important are, quickening and weakness of the pulse, flushing of the face, palpitation of the heart, headache, nausea, prostration,

garrulous delirium, desire to urinate, and sometimes muscular violence. The antidote will be brandy and morphia, and in urgent cases hypodermic injections of muriate of pilocarpine, gr. $\frac{1}{6}$, every fifteen minutes. Duboisia has more effect on the eye than atropia and it does not irritate the conjunctiva. Its toxic effects come more quickly and are more alarming, the prostration being extreme. Homatropia, a derivative of atropia, acts more feebly than either of the preceding. It dilates the pupil, if used in the strength of gr. iv. ad oz. i., in about half an hour, and has moderate effect on the accommodation; but in twenty-four hours its influence is gone. It is serviceable for purely ophthalmoscopic work, but must be taken at gr. xx. ad ʒ i. for refractive determinations. The full effect of atropia, whenever obtained, will last for from seven to twelve days. Of daturine nothing need be said. Equal parts of hydrobromate of homatropine and sugar of milk have been used by Mittendorf, dusted in the eye with a brush. Hydriodate of hyoscine is our most powerful mydriatic. Hirschberg reports that $\frac{1}{2}\%$ solution is liable to cause toxic symptoms. Emmert used it with safety in $\frac{1}{10}\%$ solution, *i.e.*, gr. $\frac{1}{20}$ ad ʒ i.

The important myotics are the preparations of Calabar bean, the sulphate and salicylate of eserine, and the alkaloid of jaborandi, hydrochlorate of pilocarpine. The eserine preparations should be used in solution, gr. ss. or gr. i. ad ʒ i.; if stronger, they become very painful by exciting spasm of the ciliary muscle. They stimulate the sphincter iridis and the ciliary muscle, and irritate the conjunctiva. Their effects are more fugitive than those of atropia in equal strength. In strong solution they excite pain in the eye and around the orbit, and can even cause clonic spasms of the extrinsic muscles. They reduce ocular tension and it is claimed by some that they reduce the calibre of the vessels. They are used in inflammations of the cornea with much confidence. The solution of the sulphate undergoes change to a reddish color, which somewhat abates its efficacy.

A second myotic, but far inferior to eserine, is the alkaloid of jaborandi, viz., pilocarpine, of which the hydrochlorate and the salicylate are the preparations in use. Its value in treating diseases of the eye rests more upon its constitutional than on its local effects. As a topical application its minimum strength is 1 to 400, and if stronger, its influence does not appear to increase (Jaarsma, Thesis 1880, quoted by Landolt). It is usually prescribed in strength gr. $\frac{1}{4}$ or gr. ij. It contracts the pupil moderately and approximates the near-point and the far-point slightly. Its effect on the pupil appears in about thirty minutes and lasts for twenty-four hours. On the accommodation the effect begins in two and a half hours and lasts two or three hours. It has therefore only

Digitized by the Boston College Libraries

limited value in ordinary needs, but because it is not irritating and topically devoid of unpleasant effects, it serves a good purpose in mydriasis caused by paralysis of the third nerve, and in feeble accommodation. Its constitutional uses are extensive and will be duly considered. Its poisonous effects should be mentioned. Its normal results are salivation and sweating, but added to these are temporary increase of urine, thirst, vomiting, nausea, belching, colic, and diarrhœa. The pulse is at first increased, then becomes normal or too slow. The action on the heart is through the pneumogastric nerve; prostration is caused by nausea and vomiting more than by a specific influence. But it is recognized to be a most capricious remedy and must be given internally in small doses, viz., 0.01 or 0.02, *i.e.*, $\frac{1}{12}$ gr. to $\frac{1}{4}$ gr. Its antidote is atropine and homatropine, besides general stimulation, galvanization, etc. The hypodermic injection of the muriate of pilocarpine (gr. $\frac{1}{8}$ to gr. $\frac{1}{4}$) has seemed to do good under certain peculiar conditions; for instance, in the late stages of chronic keratitis or scleritis, especially in gouty subjects, and also in the late period of gouty or rheumatic iritis, and in serous uveitis. Virtue is claimed for it in subretinal effusion. On the whole, the remedy has seemed to me to be overrated, although its powerful action on the salivary glands and on the skin gives it influence over local disease which doubtless can be sometimes successfully applied. As yet the indications for its use are not precisely formulated. A case is recorded where by mistake a 20% solution was hypodermically injected (Sziklai[1]). The case was one of absolute glaucoma in which sclerotomy had been done and 2% injections of pilocarpine employed. When the tenfold dose was given, the symptoms were abundant salivation and sweating for five hours. There was copious evacuation from the bladder and from the bowels, vomiting and belching, from time to time squeezing and tearing pain in the eyes. Afterward great prostration. Treatment is not related. Vision said to have been impaired and so remained for two years, but to what degree is not stated.

The Turkish bath is a similar measure, and is to be employed in similar conditions. It has decided value, but it is also capable of mischief if not properly regulated.

Another myotic is muscarine, the alkaloid of Amanita muscaria, which is little employed, but may be mentioned because, unlike eserine, it causes slight contraction of the pupil, but strong spasm of accommodation. It is very powerful and acts more on the punctum remotum than on the punctum proximum. It may be used in solution 1 to 400 or 1 to 100. Its antidote is atropine, but not *vice versa*.

There are other mydriatics which might be mentioned, as gelse-

[1] Jahresbericht für Ophth., 1881, p. 265.

Digitized by the College of Optometry

mine, daturine, which is identical with atropine, nitro-atropine, and nitro-daturine, but they are seldom useful. Cocaine has slight mydriatic effect, and a paper was written on this property of it by Von Aurep in *Archiv für gesammte Physiologie*, XXI., p. 38, in 1879. Unfortunately its peculiar anæsthetic properties were not then discovered.

As a summary of the whole: Among mydriatics we choose atropine sulphate or salicylate, in cases where a prolonged effect on the pupil and the accommodation is required. It is the mydriatic by far most frequently used for therapeutic purposes. In case it cause disagreeable effects, either local or general, we substitute duboisine sulphate or salicylate. For a less prolonged but vigorous effect on the pupil and accommodation we use duboisine gr. ss. ad oz. i., but must be watchful against toxic influences. Where a brief effect on the pupil and accommodation is desired, we use hydrobromate of homatropine 1%, or muriate of cocaine 4%. The one most likely to cause unpleasant constitutional effects is duboisine; that most likely to produce conjunctival irritation is atropine. All are liable with glaucomatous eyes to produce an acute attack, and in the ratio of their energy. Of the other therapeutic uses of these remedies it is not intended here to speak.

Of myotics the best is eserine salicylate or sulphate 0.1% or gr. ss. ad oz. i. It contracts the pupil, causes spasm of accommodation, and reduces intraocular tension. It also has other valuable therapeutic effects in inflammations of the cornea, to be referred to under that head. For a less energetic effect hydrochlorate of pilocarpine may be employed. While watery solutions are most commonly employed, mixtures with vaseline are very convenient, and Dr. Mittendorf has introduced 1% triturations which do not spoil by keeping, are easily applied, and are very convenient. He uses of either the mydriatic or the myotic 1; pulveris gum acac., 50; pulv. sacchar. lactis, 50; M., to be dusted into the eye with a camel's-hair pencil.

We are called upon to apply leeches, as, for example, for severe inflammations, and for inflammations of the deep textures. In reality they are not frequently employed. They should be placed on the temple, and not too near the lids—never on the lids or in their near vicinity. The artificial leech of Heurteloup is a cupping instrument which draws blood rapidly, and is useful for deep-seated congestions. It has quite superseded the ordinary cupping apparatus. As a matter of fact, the abstraction of blood is resorted to, in visible ocular inflammations to a much less degree than formerly, and only in those which are attended by great pain and hyperæmia. For deep seated diseases it is used in a way advised by Graefe. From one to two ounces of blood are withdrawn

Digitized by the Arnold Arboretum Library

rapidly from the temple, and the patient remains in a dark room for twenty-four hours afterward. This proceeding is repeated once in three, seven, or fourteen days, according to the character of the case.

Blisters and external stimulants, such as tincture of iodine, are not as much used as they formerly were. Their value as antiphlogistics is almost nil, and they were formerly in favor because the cases were too often incorrectly diagnosticated. As remedies for neuralgia they sometimes are useful, and in a few other special conditions.

Of external applications none is so common as water of various temperatures, and its effect is modified in the most remarkable manner by the mode of its use. For violent inflammatory attacks, as after wounds or in severe purulent conjunctivitis, a block of ice is kept beside the patient, and bits of muslin transferred from the ice to the eye every minute so long as the symptoms demand such extreme cold. We may use the water of higher temperature until it has no effect upon the surface, but serves merely to soften the secretions. From this point we may go until we get to 106° F. or 114° F. To keep the water cold the compresses must be constantly renewed; so, too, in attempting to keep it warm. To avoid such frequent change various contrivances have been adopted. I sometimes let a patient hold a small piece of ice, wrapped in muslin, upon the eye as long as it feels agreeable, and I have used a small rubber bag as large as a hen's egg, filled with ice, and stopped by a cork; but neither of these is very satisfactory. Contrivances for keeping up continuous irrigation, by coils of rubber or tin tubing, have been made (Becker, Chamberlain). For most cases we need moist cold or moist heat, and this we get best by compresses wrung out of water. Eye-douches are useful for certain chronic cases and are easily contrived, and may be for warm or cold water. They are used for only a few minutes at a time. For continuous moist heat, a good appliance is a poultice of ground slippery elm (*ulmus flava*) bark. Spongio-piline dipped in hot water, covered by oiled silk, is cleanly and serviceable. A bunch of absorbent cotton is exceedingly serviceable. It is an old rule which holds good to-day that applications to the eye should be of such temperature as shall be grateful to the patient. This cannot be accepted absolutely. For example while to the early stage of many external inflammations hot water is a relief, if kept up for several hours or if, as too often is done, a hot poultice be bound on the eye, an œdematous effusion is promoted which ensues in possible ulceration of the cornea and in such relaxation of tissues as to protract the attack. Some cases reject all moist applications; these are apt to be such as have little or no secretion except tears by reflex irritation, viz.,

Digitized by the Internet Archive

scleritis and iritis. Dry heat by a folded and warm napkin is often most satisfactory. On the other hand, when secretion is abundant, moist applications wash it away and by their temperature control the exudation to some degree, as they influence the contractility of the vessels. It is for the great majority of cases proper to use local applications for only a portion of the time—say for ten minutes or for thirty minutes three, four, six, ten times a day. Intermittent use is the rule in moderate cases. Continuous use applies only to severe cases. Details in this matter will come up in special diseases.

We next come to the so-called collyria, whose name is legion, and whose utility is regarded by the public as of the highest moment. They are to be given almost exclusively in cases of conjunctival disease. They are soothing, stimulating, astringent, and, caustic. The indication for them will be found in the presence of secretion which comes ordinarily from the conjunctiva, although the primary lesion may be in another tissue. This secretion is serum, epithelium, fibrin, pus- and blood-cells. The remedies are chosen according to their power of causing contraction of the vessels and coagulation of the secretion, or as they soothe the irritated nerve-fibres. We do not know enough of the *modus operandi* of medicines to reason exactly on this subject, and we act according to the results of experience. It is simply my purpose in this place to speak a warning against the misapplication of such remedies. To apply to iritis, cyclitis, and pure scleritis, such remedies as tannin or alum, or nitrate of silver, or sulphate of zinc, is utterly mischievous. So, too, they do harm in many, if not in almost all cases of acute keratitis. Before any "drops" are ordered, a diagnosis of the disease must be made, and if this be not made, no drops capable of mischief are to be thought of; better temporize by lukewarm water, or a weak solution of borax, or, best of all, frankly state the difficulties of diagnosis, and seek further light. Such conduct will save many an eye which rashness or false pride would ruin.

An indication of the highest importance in diseases of the eye is the regulation of its tension, especially to reduce it when excessive. The cases in which it is below par are usually of a chronic character, and are less amenable to improvement. To reduce increased tension we have, first, eserine as a medicinal agent. But the chief means are mechanical, viz., puncture of the cornea, and often not more than two drops of aqueous fluid will be removed. Again, free division of the cornea to let off all the aqueous fluid, and with it morbid products like pus or lymph in the anterior chamber. Thirdly, we have sclerotomy, which is done at the margin of the anterior chamber by a peculiar method, and also at the equator. Fourthly, we have iridectomy, which is done at the sclero-corneal

Digitized by the Boston Medical Library Company

junction, and includes excision of a piece of iris. Fifthly, under special conditions after chronic iritis and loss of the lens, division of a mass of agglutinated tissue (iridotomy) relieves extreme tension. Sixthly, I have seen two cases where removal of the whole iris through a small wound reduced the size and tension of a staphylomatous globe. In ordinary practice, paracentesis of the cornea and section of the cornea are proceedings which may be adopted by physicians who do not regard themselves as skilled operators, provided they cannot refer their patients to more experienced hands. The other proceedings need surgical training before they should be attempted.

Paracentesis corneæ is liable to be followed in certain cases by increased intra-ocular congestion and therefore the indications for it must be definitely recognized.

Digitized by Illinois College of Optometry

CHAPTER II.

THE EYELIDS AND CONJUNCTIVA.

Anatomy.

The eyelids are formed at about the second month of embryonic life as folds of skin which grow toward each other, and coming into contact at about the end of the third month, adhere at their margins by continuity of their epithelium. They remain closed until a short time before birth. The upper lid is much the broader, and in the substance of each a smooth firm portion can be distinguished which is known as the tarsus, and is composed of condensed fibrous tissue. It was because of its stiffness formerly regarded erroneously as cartilaginous. The tarsi may be spoken of as the frame-work of the lids; where they meet they are thick, while their orbital edges are thin. That of the upper lid is about ten millimetres wide at its middle, and that of the lower lid is about five millimetres wide. Their general form is exhibited in the diagram (see Fig. 89). The space between them is called the palpebral fissure. Its temporal end is acute, while the nasal extremity is rounded. The tarsi are united to each other at their extremities and also bound to the subjacent bone by internal and external palpebral ligaments. When open to its full extent the palpebral fissure is more rounded at its inner than at its outer extremity and is likened to the shape of an almond. At the inner angle (canthus) we find a fleshy mass called the caruncle (caruncula lachrymalis); just exterior to it are the openings of the tear passages (puncta lachrymalia) situated upon little eminences; that of the upper lid is usually the more elevated. The length of the palpebral fissure varies materially in different persons; it may be taken as 30 mm. in men. Its width at the middle when looking straight forward is about 12 mm., and the border of the upper lid covers the upper edge of the cornea for 1 or 2 mm. The outer canthus stands at a level 3 to 6 mm. higher than the inner canthus when the lids are open, and when closed the

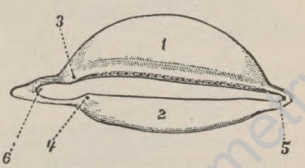

Fig. 89.—The Tarsi seen from behind. They have been isolated from other tissues and remain joined at the external and internal angles by the lateral ligaments, external and internal (or medial). 1, Posterior surface of tarsus superior — on its edge the openings of the Meibomian follicles; 2, tarsus inferior; 3 and 4, punctum lachrymale superior and inferior; 5, external or lateral angle; 6, internal or medial angle of the eyelids.

Digitized by Illinois College of Optometry

fissure is neither horizontal nor straight. When the eye looks upward the palpebral opening increases to about 15 mm. in width, and when it looks down the opening decreases to 7 or 9 mm. The borders of the lids are fringed with short, stiff hairs (cilia or eyelashes) which are thicker and longer in the upper than in the lower lid. They are slightly curved and the respective rows oppose their convexities to each other. (See Fig. 90.)

When the lids are open we have in the upper lid a deep fold caused by the retirement of the upper edge of its tarsus into the orbit, and called the sulcus orbito-palpebralis superior. Above it the skin is more prominent and is known as the orbital portion of the lid. Similar peculiarities exist in the lower lid, but are less conspicuous. We have the sulcus orbito-palpebralis inferior, and in addition another less emphatic line, the sulcus palpebromalaris (Arlt). In certain persons and particularly in the obese and after middle life, the above-named sulci may be strongly marked. These features present in different persons the widest variations. Above the upper lids we have the eyebrows (supercilia) situated at the upper edges of the orbits (see. Fig. 90).

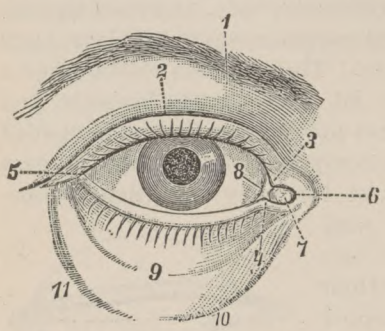

FIG. 90.—Right Eye and surroundings. 1, supercilium or eyebrow; 2, sulcus orbito-palpebralis; 3, papilla lachrymalis superior; 4, papilla lachrymalis inferior; 5, canthus externus (lateralis); 6, canthus internus (medialis); 7, caruncula lachrymalis; 8, plica semilunaris; 9, sulcus orbito-palpebralis inferior: 10, 11, sulcus palpebro-malaris.

The inner surface of the lids applies itself closely to the eyeball, and is lined by a membrane which is called the conjunctiva because it joins them to each other. Its description will be given hereafter. The lids are furnished with *muscles* to open and close them, and with several varieties of glands. The closure of the lids is effected by the orbicularis muscle, which lies just beneath the skin, to which it adheres loosely by connective tissue and without the intervention of any subcutaneous fat. Its fibres are more or less circular, constituting a sphincter, and extend over a part of the superciliary, the temporal, and the malar regions. They are inserted into a tendon which adheres to the lachrymal bone and are also inserted directly into the adjacent bony wall. The tendon crosses the lachrymal sac at about its middle and contributes to the internal palpebral ligament. Those fibres of the orbicularis which lie upon the tarsi are paler than the remainder, and certain bundles which lie close to the lid border and near the conjunctival surface are known as the ciliary muscle of Riolani; see figure, p. 251. The orbicularis is supplied by the seventh or facial nerve.

Digitized by Illinois College of Optometry

The levator palpebræ superioris originates at the apex of the orbit, lies close to its upper wall, grows wider as it comes forward, and has a threefold insertion into and about the upper edge of the tarsus (see Fig. 91.) The most anterior part of its tendon runs as a layer of fibrous tissue down upon its anterior surface and merges with the aponeurotic layer which comes down from the upper border

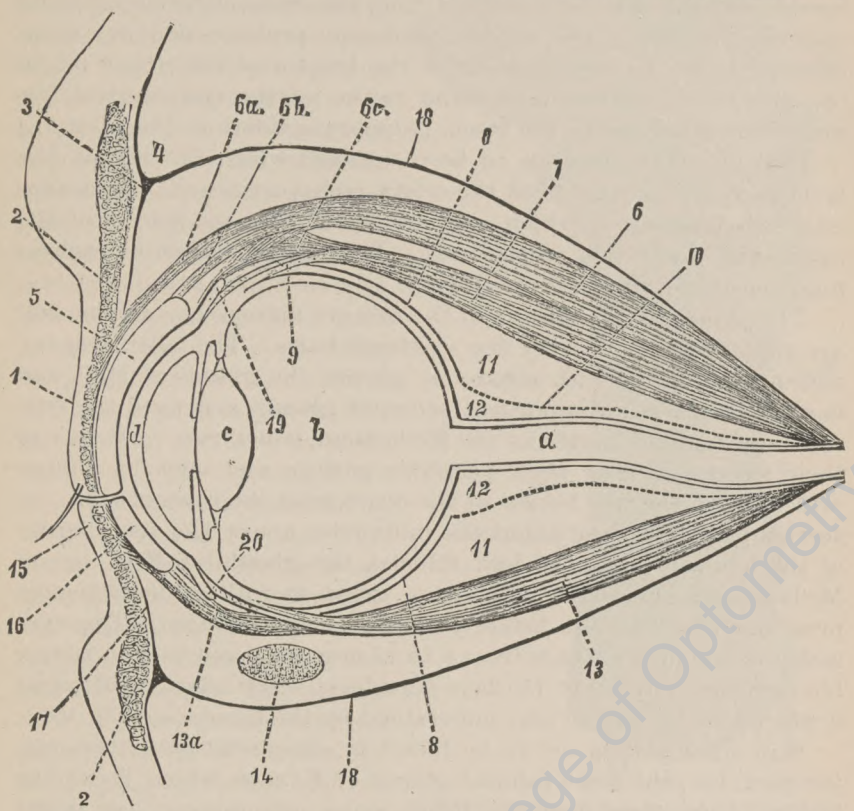

FIG. 91.—Vertical Section through the Globe and Orbit in the direction of the orbital axis, with closed Lids. 1, skin of upper eyelid; 2, 2, musculus orbicularis palpebrarum; 3, fascia palpebralis superior; 4, border of frontal bone; 5, tarsus superior, schematically represented; 6, musculus levator palpebræ superioris; 6*a*, its principal tendon which spreads out between the tarsus and musculus orbicularis; 6*b*, the smooth musculus palpebralis superior; 6*c*, conjoined insertion of the musculus levator palpebræ and musculus rectus superior going to the conjunctivæ; 7, musculus rectus superior; 8, 8, Tenon's capsule; 9, tendon of musculus rectus superior, passing through Tenon's space; 10, limit between inner orbital fat, 11, and supravaginal space 12; 13, musculus rectus oculi inferior; 13*a*, extremity of its fascia, going to lower lid; 14, cross section of musculus obliquus inferior; 15, skin of lower lid; 16, tarsus inferior, schematically represented; 17, fascia palpebralis inferior; 18, 18, periorbita; 19, 20, fornix conjunctivæ; *a*, optic nerve; *b*, vitreous; *c*, lens; *d*, cornea.

of the orbit and pushes into the fibres of the orbicularis muscle, thus binding together all these structures. The middle layer is inserted into the upper edge of the tarsus and consists largely of smooth muscular fibres. A third portion of the tendon dips back to mingle with fibrous prolongations of the insertion of the rectus superior

Digitized by the Illinois College of Optometry

and goes to the superior fornix of the conjunctiva and sends lateral off-shoots to be attached to the outer and inner walls of the orbit. By this arrangement the movements of the upper lid and of the globe when looking upward are co-ordinated, and a layer of dense membrane shuts in the contents of the orbit above the eyeball. The levator palpebræ superioris is supplied by a twig from the third nerve. It may here be remarked that the rectus inferior, after its insertion into the globe, sends a tendinous prolongation, in a manner similar to the arrangement of the levator of the upper lid, to the edge of the inferior tarsus and to the inferior conjunctival fornix[1] (Schwalbe) and to the fascia palpebralis inferior. (See Fig. 91.)

Still another muscle is to be mentioned which lies behind the lachrymal sac arising from the crista lachrymalis and bifurcating into two tendons, of which one is inserted into the border of the upper and lower lids respectively. It is called musculus lachrymalis posterior or muscle of Horner.

The *glandular structures* of the lids are numerous. In the skin are sweat glands and very fine scattered hairs. The follicles of the cilia are furnished with sebaceous glands, the glands of Moll, and in each tarsus is an important series of glands, arranged like currants on a stem, known as the Meibomian, which run vertically in their substance near their posterior surface and open by minute orifices upon the free border of the lids behind the rows of cilia. A section parallel to and about one millimetre above the free border of the lids will cross the hair follicles, the glands of Moll and of Meibomius, and reveal a number so great as will be likely to surprise one who has not before looked at such a section. The eyelashes of the upper lid are from 8 to 12 mm. long and said to have a life varying from 100 to 150 days (Donders). The relations of parts in the upper lid will be best understood by the figure (see Fig. 92).

Still other glands are to be found in close relation to the conjunctiva, viz., the acino-tubular glands of Krause, which lie at the border of the tarsi near the fornix, more numerous in the upper than in the lower lid, and other similar glands, very few in number, imbedded in the tarsal conjunctiva and in the tarsus. These are regarded as accessory lachrymal glands. In the tarsal conjunctiva are certain follicular cavities formed by irregular involutions of its epithelium which are called the glands of Henle and will be referred to again when describing the conjunctiva.

The large number of glandular structures thus mentioned give rise, as would be expected, to many and various pathological conditions to which attention will be called, and some of them are obstinate and distressing.

The function of the lids is to protect the eye both from mechan-

[1] "Lehrbuch der Anatomie des Sinnesorganes," p. 242, 1885.

Digitized by the Internet Archive

ical injury and from excessive light, and to distribute over it the moisture furnished by the numerous glands. The movement of the lids is both voluntary and involuntary or reflex. The latter is determined by the fibres of the fifth nerve which supply the cornea and ocular conjunctiva acting upon the orbicularis and especially upon those of its fibres which traverse the tarsal portion. The persistent opening of the lids during waking hours is provided for by the existence in the levator palpebræ superioris of certain unstriped fibres (H. Müller) to which reference has been made. The eyelids follow, as has been said, the movements of the cornea up and down, and in so doing the palpebral opening varies in width, becoming larger in looking up, and narrower in looking down. The opening of the lids is performed almost wholly by the lifting of the upper lid, but in looking down the lower lid is also made to descend by the indirect attachment to its tarsus of the tendon of the rectus inferior. (See Fig. 91, page 249.) Under special impulses the separation of the lids can be notably increased and so much, as to show a border of sclera both above and below the cornea. This occurs under emotions of surprise, of fright, of earnest attention, and appears in exophthalmic goître (Basedow's disease). Drooping or falling of the lids comes from fatigue, from paralysis of the levator, and from mechanical hindrance such as thickening of the conjunctiva, etc.

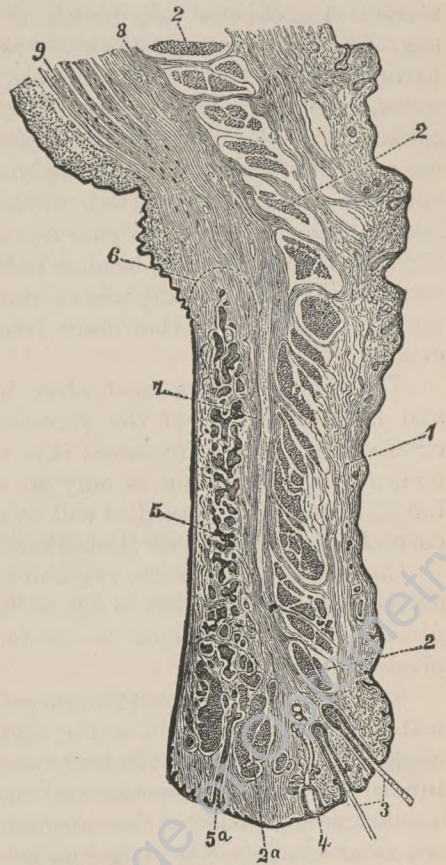

FIG. 92.—Sagittal Section through the Upper Eyelid. 1, skin; 2, palpebral portion of the musculus orbicularis oculi; 2*a*, its inner portion, designated as the musculus ciliaris Riolani; 3, cilia; 4, gland of Moll, opening into a hair follicle; 5, Meibomian gland; 5*a*, its orifice; 6, indication of the ill-defined limit of the tarsus; 7, loose connective tissue between tarsus and anterior insertion of the tendon of the musculus levator palpebræ superioris; 8, anterior connective-tissue-like insertion of the tendon of the musculus levator palpebræ superioris; 9, its middle layer non-muscular, called the musculus palpebralis superior. (H. Müller.)

Digitized by the Internet Archive in 2007 with funding from Microsoft Corporation

Blepharitis Marginalis. Ophthalmia Tarsi. Blepharo-Adenitis.

We have various degrees and kinds of this affection; for instance: 1st, chronic hyperæmia of the border with slight thickening; 2d, some redness with an accumulation of yellowish, fatty material at the base of the lashes, the hypersecretion of the glandules, a kind of seborrhœa; 3d, ulceration, minute abscesses, crusts gluing the lashes together and sometimes severe inflammation of the whole border; 4th, after long continuance the lid border becomes smooth, red, glazed, everted, thickened, weeping, and destitute of lashes (*lippitudo*). It is characteristic that the hair follicles atrophy, the lashes dwindle, become pale or curl up and fall out. Sometimes decided ectropium, and eversion or occlusion of the lachrymal puncta, takes place, this more frequently in the aged or the uncleanly.

The disease occurs most often in the young with delicate skin and light hair, and in the strumous. It is sometimes a kind of eczema. In very many cases it is associated with some refractive or muscular error and is only an expression of functional strain, for which no local remedies will avail, until proper glasses or other correction are employed (Roosa) (Schirmer).

Chronic conjunctivitis, trachoma, phlyctenula, are frequent concomitants. The ailment is apt to be chronic, but except in the inveterate form mentioned as the fourth type, will usually yield to proper measures.

Treatment.—The first two forms require soothing lotions, warm water or warm milk and water, and for the seborrhœa it should be made a little alkaline with bicarbonate of potash; at night a mixture of boracic acid powder and vaseline, gr. xxx. ad oz. i., may be applied, or soft oxide of zinc ointment. For the ulcerative form the crusts are to be softened, and as much as possible removed, and the following ointments may be used: two grains of hydrarg. oxid. flavæ to one drachm of vaseline or amylo-glycerin; or, ung. citrini, gr. x. vel. xx., vaselini, ʒ i., to be applied night and morning, or, in bad cases, more frequently. In a large number of cases, the best method is to pick off the crusts with fine forceps or the fingernails, and cauterize the exposed ulcers with a fine point of nitrate of silver. It often bleeds, and the caustic hurts. In cases of extensive incrustation, and especially in young children, the lashes may be cut off with scissors to facilitate the denudation and cauterization of the ulcers. The subsequent use of stimulating salve will then control the disease. But if the person be the subject of error of refraction, or of other error which causes eye strain, the removal of the blephharitis will not only demand the usual local

Digitized by the Internet Archive in 2010

treatment, but also that the error be corrected. (See Part I. of this treatise.)

In specially obstinate cases the evulsion of the lashes may be demanded (epilation) with use of lotions of acetate of lead (Liquor plumbi subacetatis, ʒ i.; Aquæ, ℥ viij. M.) and the ointments above mentioned, especially the yellow oxide of mercury. Treatment of conjunctival disease by nitrate of silver, gr. ij.–v. ad oz. i., must not be neglected. For the chronic thickening with eversion and loss of eyelashes (*madarosis, tylosis*), squamous blepharitis, stimulating ointments of more intensity may be used, such as an ointment of Hebra's:

℞ Emplast. diachylon co.,[1]
Olei olivæ, ... q. s.
M.

Or,

℞ Olei cadini, ... 1
Vaselini, ... 2.
M.

Apply every night.

The crystal of sulphate of copper may be applied daily, or the nitrate of silver, pure stick, *pro re nata.*

Sometimes constitutional treatment of scrofulous conditions is not to be omitted.

Hordeolum or Stye.

This affection is a phlegmonous inflammation at the tarsal edge, which forms a small and generally painful lump. It is apt to be associated with chronic blepharitis or conjunctivitis, and often depends on general debility. In its inception it may sometimes be checked by applying a bit of ice wrapped in muslin for a few minutes repeatedly, or by pulling the cilium which passes through it. One is apt to follow another in succession. When suppuration is unavoidable, a poultice of ground slippery elm bark (*ulmus flava*) is most comforting, and a puncture should be made at an early period. General tonics and mild astringents are the proper remedies to prevent their recurrence; but it is important also to investigate the state of refraction, because what causes eye strain will provoke styes. Another frequent concomitant and favoring condition, is nasal catarrh, which will also need attention.

---

[1] Emplastrum diachylon co. is made as follows: Emplast. litharge, 12 parts; flour, 1½ parts; ammoniac, galbanum, turpentine, each 1 part.

Digitized by the Internet Archive in 2010 with funding from Illinois College of Optometry

Chalazion, or Cystic Tumors.

Obstruction and distention of some of the follicles of the tarsus, more frequently of the Meibomian, is the origin of these tumors. They are painless, imbedded in the tarsus, and the skin is freely movable over them. They vary in size, and are apt to come in crops. The sac wall is usually thin, and as the tumor enlarges it causes a reddish or yellowish projection on the conjunctival surface, and sometimes presents granulations. The contents are a glairy, mucilaginous substance. Microscopic examinations have shown that nutritive disturbance in a Meibomian follicle, excites chronic inflammation in the surrounding connective tissue which leads to an infiltration with small cells. By confluence of several foci of infiltration, a nodule is formed composed of granulation tissue and giant cells. This results in mucoid softening and its escape by ulceration (Fuchs). Cocci are also found within them. Fluctuation is never felt, and I have sometimes found a solid, fibrous tumor when I expected to meet a cyst, and at times the cyst wall has been extremely thickened. When small, the tumors are not troublesome, and they occasionally disappear. If they reach a size to be annoying, they must be excised. We may do this on the skin surface, through a wound parallel to the lid-border, and no perceptible scar is left. The cyst may be opened on the inside surface if it project notably in this direction, and the contents scooped out with a sharp spoon. Sometimes the tumor runs for some distance up the lid along the line of a Meibomian duct: it will be apt to point at the lid border. Here a deep puncture may be made with a narrow knife and a sharp curette pushed up into the tubular cyst to scrape its walls and evacuate its contents. Special forceps have been contrived by Desmarres, Snellen, Prout, and Knapp, to inclose the tumor in a clamp to prevent bleeding. Before applying it, drop into the conjunctival sac a 4% solution of cocaine and wait for its effect. Then put on the clamp forceps, screw it tight, and inject hypodermically three drops of 4% cocaine solution alongside the tumor. In a few minutes the dissection can be made painlessly and almost without bleeding. Most of the clamps have a broad plate of metal or horn for one blade and this is sometimes useful. A simpler form will usually answer. (See Fig. 93.) In lack of clamps, a flat spatula or the operator's forefinger slipped under it, will hold the lid tense and check bleeding; the tumor is to be exposed and may be seized with a sharp hook by an assistant and

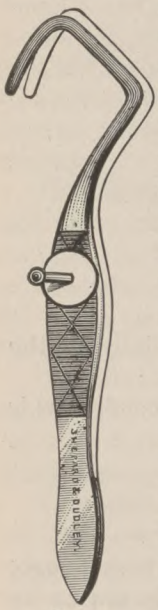

Fig. 93.

Digitized by Google

excised, or if without an assistant, pointed scissors curved on the flat will remove the projecting part, and when thus opened the remaining portion can be scraped out. Should a small perforation of the lid occur, no harm is done. For very large cysts with thick posterior wall, it may sometimes be well to touch it lightly with a point of lunar caustic instead of relying on scraping alone. To guard against recurrences, remove chronic palpebral conjunctivitis and correct eye strain, and in some instances cod-liver oil and means to improve nutrition, especially if there be a strumous diathesis, are important.

Phlegmon of the Lid.

If suppuration occur in the connective tissue of the lid, as may happen after debilitating disease, or in strumous children, or without recognizable cause, there will be great swelling, and fluctuation will be detected early. It may come with very little pain and but little redness. It is also important to remember, that a general inflammation of the lids may occur in delicate children, and not result in suppuration: there may be great œdema and slight redness, and the whole may disappear by resolution. On the other hand, the connective tissue may become gangrenous in cachectic subjects. If suppuration occur, the pus must have vent early, by a free incision, parallel to the border of the lid. The best knife is a Beer's cataract knife, or a very narrow, sharp pointed and curved bistoury. Stand behind the patient, pierce the skin, and run the point along with a quick, steady thrust. The earlier the incision is made, the less will be the likelihood of deformity after the abscess heals.

In cases of erysipelas of the face, if there be much induration of the lids, care must be taken to watch for suppuration. It is very liable to occur, and considerable destruction of tissue may take place, which early incision would obviate. In the severe forms of the disease, it sometimes becomes needful to make deep incisions when there is no evidence of pus, to save sphacelation of the tissue.

A very remarkable and fortunately rare occurrence is *spontaneous gangrene of the skin* of the lid. Two cases of this character were reported to the New York Ophthalmological Society by Dr. Rushmore, of Brooklyn, in 1883, and another by Dr. R. H. Derby in 1884. See case by Hilbert: *Centralblatt für Augenheilkunde*, Oct., 1883, p. 293. Deformity will ensue for which a plastic operation may be required.

Inflammation of the Tarsus.

Tarsitis.—This does not occur very often. It is usually syphilitic, yet may be simple or idiopathic. It is very slow in progress and not specially painful; it is attended by great thickening of the

tarsus, abscesses are apt to form in its substance and they break at the tarsal border. Hence, there will be ulcers, crusts and yellow projecting points, the eye-lashes will fall and their follicles atrophy. It will appear like *blepharitis marginalis*, but the great thickening of the tarsus declares its character. A diffuse redness spreads over the lid border and the appearance may be very unpleasing.

If, as is usual, syphilitic, constitutional treatment will be essential; if simple, it will be difficult to control. Hot fomentations may be applied and the stimulating ointments above mentioned, while in the case of a young lady whom I treated for over a year the only control over the minute abscess and the thickening, was by inserting a red hot needle alongside a hair, or passing in a platinum needle dipped in strong nitric acid. (See Bull, Trans. Am. Oph. Soc., 1878, p. 405.)

All varieties of *diseases of the skin* may appear on the lids and the following may be singled out: eczema, xanthelasma, molluscum contagiosum, herpes zoster ophthalmicus.

Eczema appears in the acute and chronic form. It is common among children in connection with acute conjunctivitis and keratitis, presenting crusts and ulcerations and discharge. The scaly and hypertrophic form appears chiefly among adults and especially in the aged. For the former, complete and careful washing away of scabs, and application of vaseline, or boric acid and vaseline, or yellow oxide of mercury ointment, may suffice. But in many cases, especially among children of the poor, it is better to give chloroform, remove the scabs, dry the bleeding with absorbent cotton and go over the surface with pure nitrate of silver. After this the above ointments will complete the cure. Starch powder may be dusted on the surface if needful. Commonly similar crusts exist about the nostrils and perhaps at the angles of the mouth; all such spots should be cauterized. Treatment of conjunctival inflammation will at the same time be attended to.

The squamous and hypertrophic eczema may be limited to the eyelids and vicinity, and may or may not be complicated with acute conjunctivitis. If the condition be chronic, the stimulating remedies may be used, viz., Olei cadini, 1 part; vaselini, 2 to 4 parts; or the diachylon ointment (vide p. 253). In acute conditions with serous effusion and, as may happen, with the whole face involved and the conjunctiva acutely inflamed, the milder ointments of oxide of zinc, vaseline and boric acid, of white precipitate of mercury, or dilute citrine ointment are to be preferred. Wet applications are generally decidedly unacceptable. Sometimes the irritation is extreme and may call for bromides and preparations of opium or other anodynes internally, as well as hypnotics: antipyrine, gr. x.; hyoscyamine, gr. $\frac{1}{100}$ or gr. $\frac{1}{50}$ in tablets, chloral, phenacetine, etc.

Digitized by Illinois College of Optometry

Such astringents, as tannin and alum, are better for the conjunctivitis than nitrate of silver, and cocaine may be employed to advantage.

Xanthelasma or *xanthoma* is a fatty degeneration of the connective tissue of the skin, which has a predilection for the eyelids, although it occurs elsewhere. Yellow or straw-colored, slightly nodular patches appear at the inner extremities of the lids, usually symmetrically, and both upper and lower lids may be affected. They gradually extend and may become large and prominent welts. They come oftener in women than in men and after middle life. They are easily removed by excision, which is the only mode of relief; but I have been disappointed to find the disease return within a year in one case. Being without danger and simply a slight blemish, few persons care to submit to their excision.

Molluscum contagiosum appears anywhere on the body and often about the lids. The little tumors may be as large as peas or hempseeds. The top is cupped and a little opening leads into the middle of the tumor. The sebaceous glands are probably the seat of the disease and they contain altered epithelial cells and peculiar bodies called molluscum corpuscles which are of a fatty nature. The contents may be squeezed out between the thumb nails through the little opening above mentioned; or, if needful, they may be opened with a knife. Evacuation cures them. That they are contagious does not seem to be well founded.

Herpes Zoster Ophthalmicus

exhibits conspicuous and important features. It is called by the French *zona ophthalmique*, and has been extensively described by Hybord, and previously by Mr. Hutchinson. It is, in truth, a neuropathic affection having its cause in degeneration of the ganglion of Gasser, or of the branches of the trigeminus, or of both. Any of the branches of the fifth pair may be thus affected, and the eruption appears along the distribution of the diseased nerve-twigs. It therefore happens that vesicles may occur on the eyeball as well as upon the skin, and both ulceration of the cornea, acute conjunctivitis and acute iritis may take place. It may even cause loss of the eye by irido-cyclitis. It is also said that small abscesses have been found in the ocular muscles. The mode of occurrence, as illustrated in a boy ten years of age, was as follows: the supra-orbital nerve was the one affected. The initial symptom was intense pain along this nerve at the supra-orbital notch, around the lachrymal sac and side of the nose, upon the forehead, and up to the vertex. In a few hours the skin of the forehead became red and swollen, tender to touch, and a few vesicles appeared above

Digitized by the Internet Archive of Optometry

the inner end of the brow. While the right half of the forehead, red and swollen, presented the look of erysipelas, the left half remained natural. The hair could not be combed because the scalp was tender, and a few vesicles were there discovered. The eyelids swelled, a slight conjunctivitis appeared, chiefly affecting the palpebral surfaces, and there was great photophobia. The pulse was quickened; it reached ninety, and some febrile reaction occurred. The urgent symptom was the pain, which continued day and night. A few vesicles appeared on the side of the nose; none whatever showed themselves across the median line.

The treatment consisted in keeping the boy in bed and dropping into the eye every two hours a solution of sulph. atropia, gr. ij. ad ℥ i., to abate the pain (cocaine would have been proper), using upon the forehead hot fomentations without intermission, and giving full doses of morphia and quinia sulphate three times daily. By the fourth day there was decided mitigation of the symptoms, but it was not until the twenty-fourth day that the patient could go out. No lesion of the cornea took place. In case the latter should occur, it would be much longer before the patient would be well. When there is an eruption on the cornea its surface is markedly anæsthetic. This suggests a reason for the long continuance of the affection in some cases, and also the need of keeping the eye bound up so long as the irritation continues. The special treatment suitable to cases of ophthalmic shingles, in which the cornea or iris may be involved, will be found under the chapters which treat of these troubles respectively. I have seen one case in which, while one eye was destroyed by the direct mischief of the disease, the other was also lost through sympathetic irido-choroiditis. I have notes of a case in which both sides of the forehead were attacked. Permanent scars remain, which may be recognized by their rounded form, and by a slight depression of the surface.

The disease may take place at any age, and it is most hurtful to the aged and feeble. It is very apt to be regarded as simple erysipelas, but from this it may be discriminated by the intense neuralgic pain following certain nerve-twigs, by the strict localization of the skin trouble, and by the vesicles. The lesion may go down to the tip of the nose, or upon any part of the distribution of the trigeminus. The treatment, as above specified, should be both local and constitutional, the latter being such as may control neuralgia, the former to soothe the local inflammation. For a severe attack in a man who was nearly eighty years old, ten-grain doses of quinine were given at intervals of two hours until fifty grains were taken daily, with marked benefit and perfect tolerance of the drug. It is said that when the vesicles appear on the nose, the cornea is most likely to be involved. I cannot support this state-

Digitized by Google

ment because I have found the corneal affection both with and without implication of the nasal twigs. See cases by Jeffries and Mathewson, Trans. Am. Oph. Soc., 1874, pp. 221, 228. Mathewson used constant (?) galvanic current with great relief to pain in five cases. Severe optic neuritis followed by atrophy has been seen (Daguenet, *Rec. d'Ophth.*, 1877, 177); paralysis of accommodation and mydriasis have been repeatedly seen.

Syphilitic ulcerations are sometimes found upon the lids—they may be chancres or secondary ulcerations; although the latter are more likely to appear on the mucous surface. It is hardly necessary to say anything about the recognition and treatment of these conditions. They only need to be mentioned (see paper by Dr. Bull, Trans. Am. Ophth. Soc., p. 408, 1878). French literature furnishes the greatest number (see paper by Dr. Beck, Trans. Am. Ophth. Soc., 1886, who has collected 94 cases).

Epithelial Cancer and Lupoid Growths

are quite often situated upon and near the eyelids. A discrimination between them is hardly needful for practical purposes. If a nodular, irregular elevation appears on the lid border, or on the skin, and is covered by a dark crust which, when picked off, exposes a bleeding surface, and if this continue for months or years, sometimes healing and again breaking out, but never going entirely away, this neoplasm, although quite painless, had better be excised. The true epithelioma is more rapid in development than a lupoid growth, and both may result in ulceration. In either case the neighboring lymphatic glands are not likely to be enlarged, except at a late date. The gland which we look for is that in front of the tragus—the pre-auricular gland. Growths such as we are now considering, occur during and after middle age, and usually remain unheeded for a long time. Sometimes soothing lotions will procure healing of the ulcer. The solution of chlorinated soda (Labarraque's), diluted with five parts of water, will often be followed by perfect cicatrization of a suspicious and extensive ulceration. It is applied for twenty minutes by a piece of lint six or eight times a day. I have made this observation many times during the last fifteen years.

For almost all cases, the best method of treatment is an operation, and not caustics. If the latter be applied to the lids, deformity will follow which will necessitate an operation, while if the knife be resorted to, the deformity may be at once remedied by a suitable plastic proceeding. If there be a spot of ulceration on the cheek or temple or nose, covered with a thin brown crust, which leaves, when removed, a bleeding depressed surface; if, too, the skin be hard and infiltrated at this spot, the case is probably *lupus non*

Digitized by Illinois College of Optometry

exedens. Scraping out with a sharp spoon, or thorough burning by actual cautery (Paquelin's thermo-cautery) will be likely to cure it. Escharotic plasters are to be eschewed; they cause great pain and wide destruction. In many instances of probable epithelioma upon which I have operated, there has been no return of the disease for many years. The prognosis is encouraging when a thorough removal is performed. If a relapse demands a second operation, even then, as I have seen, the disease may not recur.

I have seen one case of *amyloid tumor* upon the border of the lid. The patient was a young woman under the care of Dr. Prout, of Brooklyn.

Papillomata or *warts* are not uncommon on the border of the lids. They may be snipped off, or accurately touched with nitric acid applied by a platinum probe, or by a small and pointed stick.

Horny growths have been known to occur on the lids. One instance I have had in my own practice.

Milium presents a perfectly white tumor, not larger than the head of a pin. It is a retention tumor of a sebaceous follicle and simply needs puncture.

For an account of very rare cases of adenoma of the Meibomian glands and of the glands of Krause, see Salzmann, *Arch. für Ophthal.*, XX., 3, p. 380, 1891.

Nævi and Teleangiectatic Tumors.

Several varieties of vascular growths occur on or about the lids; they may be simple red patches, or slightly elevated and flattened patches, or they may be conspicuous and lobulated masses containing large vessels as well as capillaries, and are called cavernous tumors. The diagnosis is simple and no extended description is required.

Treatment.—Excision is advisable in the early stage of these tumors, and the lid clamp of Snellen or Knapp can often be used to check bleeding. Destruction of the tissue may be effected by puncture with red-hot needles (shoemakers' sewing awls are sometimes convenient). The dental blast lamp gives the requisite heat, if a Bunsen's gas burner or large alcohol flame does not suffice. A succession of operations will be required. For a considerable number of tumors excision may be successfully practised, because they will be found inclosed in a distinct fibrous capsule, and if this be respected, no serious hemorrhage will occur. Care must afterward be taken to keep the cavity well closed and to treat it antiseptically.

For certain large growths which may perhaps extend into the orbit, electrolysis offers a sufficiently safe and effectual method. The purpose is to coagulate the blood, not to destroy the tissue. A number of needles connected with the positive pole may be

Digitized by the College of Optometry

plunged into the tumor and the negative pole applied by a sponge to the temple. The needles should be of platinum to prevent oxidation. The current must not be strong, usually four small cells suffice. See Figure 230, under chapter on the Orbit.

In all operations care must be taken not to excite severe reaction lest deformity ensue. I have seen a case in an infant for which the common carotid had to be tied. The tumor disappeared.

Injection of persulphate of iron is too severe, of alcohol has been lately recommended. Threads may be run through to excite suppuration. In some instances small and even large vascular tumors have been known to disappear of themselves.

Minute vascular growths, like little red warts, sometimes appear on the border of the lid. They may be easily tied or burnt off.

Moles or brown patches may occur congenitally either upon the lids or in the neighborhood. They should be excised, and afterward a proper plastic operation performed. I was called upon to do this for a young lady, whom I saw again after several years, and found that similar pigment-nodules had appeared upon the neighboring skin which had previously been healthy. The primary growth was congenital, was set with stiff hairs and seemed to be innocuous, although a decided blemish. The subsequent pigmentation showed no malignant or ulcerating tendency.

Diseases of the Eyelashes.

They may fall out as the result of chronic marginal blepharitis, and when one of the symptoms of secondary syphilis without any noticeable inflammation; while at the same time the eyebrows will be shed. The condition is called *madarosis* or *tylosis*.

Canities is the name given to decoloration of the lashes. There may be a cluster of white cilia on only one eyelid. I have seen all the cilia of one lid perfectly white and the cilia of the remaining lids dark; in the same lady there was a wisp of white in the midst of the dark brown hair of the head.

Phtheiriasis signifies the presence of crab lice (*pediculus pubis*) among the lashes. Their eggs adhere in rows to the cilia, and the crawling of the creatures provokes itching. Mercurial ointment destroys them, locally applied.

Distichiasis means that there is a double row of lashes, one of which touches the globe. As many as two displaced rows have been seen. As a rarity the condition is congenital, usually it is acquired.

Trichiasis differs from the above in the irregular position and shape of the lashes which come in contact with the eye. A few or a great number may be inverted, and they curl in various direc-

Digitized by Illinois College of Optometry

tions. Many of them will be atrophied. There may be thickening of the tarsal border, but the tarsus is not bent or notably deformed. The state of the tarsus makes the distinction between *trichiasis* and *entropium*, although the former insensibly shades into the latter. Trichiasis is caused by blepharitis marginalis, by trachoma, by burns, etc. We may practically distinguish between partial and complete trichiasis. Either the upper or the lower lid may be affected and the effects upon the cornea may be more or less severe.

Treatment.—For *partial* trichiasis the methods available are 1, epilation; 2, snaring them with a thread; 3, destruction by hot needles or by electrolysis; 4, excision of the follicles. Spasm of the orbicularis and conjunctival irritation often coexist and if the border of the lids be forcibly inverted, spasmodic entropium.

1. Pulling out the hairs by forceps gives temporary relief and must be repeated every week or two. Often the offending lashes are very fine and difficult to seize, and a patient will much complain if the "short hairs" are overlooked. After operations some errant cilia may remain and their evulsion be preferred to any other proceeding, and will often be done by some member of the family.

2. Ensnaring the cilia in a loop of thread (Snellen) is done by entering a needle, through whose eye both ends of a fine silk thread have been passed, and as the loop is drawn to the base of the hair, the latter is put within it and dragged up into the substance of the lid. This proceeding applies to single or a very few hairs. A thread may also be used to destroy a group of hairs by carrying it into the substance of the tarsus up, across, and then down, inclosing them in its bight, and tying down hard upon the lid border to crush the follicles and set up destructive suppuration.

3. Destruction by red hot needles, by a platinum needle dipped in caustic potash, or by electrolysis is better suited to the above conditions. The last was proposed by Michel, of St. Louis. A triangular gold or platinum needle is pushed into the follicle and connected with the *negative* pole of a constant battery of from eight to twenty elements; the sponge of the positive pole is placed on the temple or held in the patient's hand. When the circuit is closed, minute bubbles of gas are disengaged and the tissue whitens about the base of the cilium. There is considerable pain and about a minute is needed to destroy the follicle. The treatment sometimes fails.

4. *Excision of the follicles* is done by taking out a rectangular portion of the tarsus, without encroaching on the Meibomian follicles. The superjacent skin is dissected up in a little flap, and this may be extended upward, and after the removal of the bit of tarsus the flap be dragged down, its tip cut off, turned in to cover the lid border, and held in place by a suture at each corner. Slight

Digitized by Internet Archive

traction is thus maintained and the gap is filled up (Anagnostakis).

When trichiasis is more extensive, the mode of proceeding will depend upon collateral conditions. As already said, the cases merge insensibly into those called entropium, there being in both classes lesion of the tarsus, but in the latter it is more severe. The choice of method will depend upon the length of the palpebral slit, the quantity of substance in the lid, and especially on the state of the tarsus.

It is convenient to deal with the subject under the head of entropium and indicate what modifications of method are suited to varying morbid conditions.

Entropium.

Besides simple inversion of the lashes, we find in old cases shortening of the palpebral slit, thickening and incurvation of the tarsus, as readily seen by the furrow along its middle when the lid is turned over, the tarsal border becomes sharp and thin, and often the lids hug the eyeball tightly. This last circumstance produces almost as great mischief as the presence of the inverted lashes, by fretting the cornea and keeping up the superficial inflammation. The effect of entropium is, opacity of the cornea, and if the lids are tight, the softened structure loses its proper curve and may even become staphylomatous. Entropium may appear during the progress of trachoma, but is usually one of its sequelæ, as will be hereafter described.

We have, besides the cases above referred to, two other forms of entropium, viz., the senile and the spasmodic. Senile entropium ensues from relaxation of the tissues. The skin becomes folded and droops, and the ciliary border turns inward, the orbicularis aiding in the effect.

For relief of the senile variety, the removal of a properly proportioned piece of skin is all that is usually required. Threads run vertically beneath the skin and tied tightly down to cut their way out and reef up the tissues by the cicatrices, are objectionable from the puffy state in which the parts are left. It is easier to effect the object in the upper than in the lower lid. Entropium of the lower lid often complicates the treatment of cataract extraction, being both spasmodic and due to relaxation. Sometimes a piece of caoutchouc plaster or the application of contractile collodion will draw the lid down, but generally a portion of skin will need removal. This will run parallel to the border and vary from six to twelve millimetres in width.

Spasmodic entropium of the lower lid happens in chronic keratitis and in other conditions. A suitable operation for an obstinate case is indicated in the diagram (Graefe), (see Fig. 94),

where the flaps being undermined, are brought together over the open wound. For a case of trichiasis at the outer third of the lower lid with entropium which was maintained by trachomatous cicatrices of the conjunctiva I did the following: At four millimetres below and parallel to the lid, I raised a flap about six millimetres wide and equal in length to the lid. It was left attached at its temporal extremity and about one-half of it cut off. The remaining piece was trimmed and turned up to be imbedded in the lid border where the erring lashes grew, and stitched fast. Like a piece of tape it held the lid in permanent eversion. The wound below the lid border was closed by sutures. The girl disappeared from view for seven years after the parts healed. I then cut away the bridge of skin. The deformity was cured, the cornea was healthy, and no return of the trouble took place. Probably a month would have sufficed to effect the object. Still other methods of dealing with these cases exist, as by sutures. (Saemisch, Wecker.)

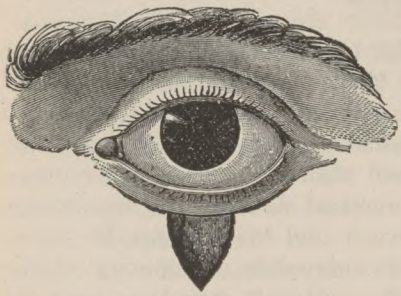

FIG. 94.

The methods of treating ordinary entropium are almost innumerable. One must make choice according to the needs of a given case. It must be remembered that its essential cause is deformity of the tarsus and all operations must be adapted to modify and correct its malposition.

The operations of Arlt, Jaesche, Flarer, and others begin by splitting the tarsus along the border into two layers for a depth of about three millimetres, and the ciliary border is drawn up after excising a narrow strip of skin above it. Another proceeding is not to throw away the strip, but to leave it attached at each extremity, to draw it by the middle below the ciliary flap, and make it take the place of the latter on the lid border (Gayet, Dianoux[1]). Swanzey figures the operation, but it hardly seems possible to avoid a clumsy and unpleasing result by such a device.

Where no serious deformity of the tarsus exists, Arlt's method of transplantation of the loosened lid border, which is well known, serves an excellent purpose. If the incisions inclosing the semilunar flap are carried a little beyond the outer and inner canthi, inverted lashes at the extremities will not be omitted in the effect. The excised flap of skin will be from four to six millimetres wide at its middle. The displaced marginal strip will be about four millimetres wide and may or may not be fully loosened at its upper

[1] Annales d'Oculistique, 1882, xxxviii., p. 132.

Digitized by Illinois College of Optometry

edge. The exposed surface at the margin of the lid is left to granulate. It is better to depend on a spatula by which an assistant lifts the lid and keeps it tense, than upon a clamp. It restrains bleeding sufficiently.

Acting upon another principle are the methods of Streatfield, Snellen, Pope, in which a deep groove is cut into the tarsus on its front surface just above the lid border, or the tarsus substantially dissected out; a strip of skin with subjacent muscular fibres is next removed, and the wound closed by sutures. A canthotomy may also be done. These proceedings are suited to cases where shrinking of the tarsus has begun, yet not advanced very far, and while often effective, more confidence can be placed upon another operation devised by Dr. John Green which will be presently described.

Mention must be first made of Hotz's operation, which is carefully described in Knapp's *Archives*, 1879. The theory of it consists in making the integument so adhere to the upper edge of the tarsus and the tarso-orbital fascia, that its tension shall draw the ciliary border outward. (See Anatomy, page 247.) The mode of performance is as follows: an assistant fixes the skin of the brow against the orbital edge, the surgeon draws down the lid at its middle with his thumb and finger or by forceps, he incises the skin horizontally along the whole length of the lid on a line which begins and ends two millimetres above the outer and inner canthi. The lid being stretched and drawn down at its middle, this line, although made horizontally, becomes a curve when the lid is let go, parallel to the upper border of the tarsus. The assistant pulls down the lower edge of the wound with forceps and the operator thoroughly dissects off the muscular fibres which cover the upper third of the tarsus. When bleeding stops, black sutures, three or four, are inserted by a curved needle through the skin at the lower edge of the wound, then through the superficial fibrous tissue of the upper part of the tarsus and made to dip into the aponeurosis just above its upper edge and finally emerge through the skin at the upper side of the wound. An assistant draws up this edge meanwhile. No muscular fibres must be included. The loop, when tightened by a surgeon's knot, draws the skin both above and below to the upper border of the tarsus and the aponeurosis, and fastens it down upon it. A lever action is thus exerted which tips up the ciliary border. Unless this effect ensues, the method has not been correctly followed, or the tarsus has undergone so much distortion as to make it inapplicable. Considerable reaction follows: the sutures remain *in situ* two days, never more than three, for suppuration must be avoided. Sometimes, when very redundant, a narrow strip of skin is removed, but usually this is needless. It may be requisite sometimes to simultaneously perform canthoplasty. See Fig. 95. There is no doubt

Digitized by Google

about the great value of this method, and it shares with Green's operation well-deserved confidence. Its fundamental idea was embodied in an operation by Anagnostakis in 1857, but less satisfactorily than by Hotz.

With Green's[1] operation my own experience has been highly satisfactory. The lid is everted and held by the fingers, and an incision made through the entire thickness of the tarsus upon its conjunctival side, parallel to the lid border and about two millimetres above it, and extending from end to end. A round-pointed scalpel is used by Green. I usually take a Beer's cataract knife and push the point through. Next a strip of skin not more than one and a half or two millimetres wide is removed along a line about one and a half millimetres above the cilia. Muscular fibres are left intact, to aid in maintaining by their vascularity the vitality of the lid border. By a curved needle A (see Fig. 96), the sutures are carried out as shown in the diagram from the conjunctival side of the cilia through the free edge of the tarsus just above the lower border of the skin wound. The thread is drawn through, the needle re-entered through the muscular fibres upward along the outer surface of the tarsus, at the point B, going in deeply, and emerges about one centimetre or more (about half an inch), higher up, through the skin. When the sutures, usually three in number, are tied, the skin wound is closed and the ciliary border is everted. An additional security, on which, in my experience, great stress is to be laid, consists in turning the eyelashes back upon the skin and holding them down by collodion spread upon a few fibres of cotton laid parallel to the lid border. This dressing of cotton fibres and collodion rigidly holds the lashes in the desired position, closes the wound hermetically, and permits in many cases the withdrawal of one or more sutures when the collodion is dry. All sutures may be removed in twenty-four hours and a fresh dressing of collodion and cotton applied. The tarsal wound gapes widely and fills in a few days with granulations. Canthoplasty may be combined with the operation.

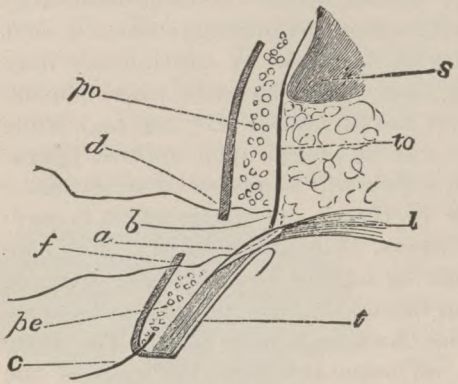

FIG. 95.—Represents a Vertical Section of the Upper Eye-lid. *s*, supra orbital margin; *to*, fascia tarso-orbitalis; *po*, pars orbitalis; *pc*, pars ciliaris of orbicularis muscle; *t*, tarsus; *c*, eye-lash; *f*, lower border, *a*, upper border of the wound; *a*, *b*, passage of suture through aponeurosis.

FIG. 96.

[1] Trans. Amer. Ophth. Soc., 1880, p. 167.

Digitized by Illinois College of Optometry

Green's operation is suited to cases of all grades. It does not involve risk of sloughing of the ciliary border as sometimes happens with Arlt's operation. Hotz's operation is available after other methods have failed of success and especially if, as too frequently happens, considerable skin has previously been removed. It can be applied to the lower lid, but should not be done upon both upper and lower lids at the same sitting, because reaction would be severe. From Green's operation little reaction ensues, and it likewise is effective on the lower lids. A choice between these two methods, which in the writer's view are superior to all others, is to be decided by the peculiarities of a given case and by the preference of the surgeon.

Very many methods besides the above have been devised and are figured in text-books. Among them Snellen's is certainly good, but the writer finds those described adequate to all needs. He may be allowed, however, to mention a proceeding once employed in a desperate case, where great shrinking and shortening and tightness of the lid, from which all lashes had been removed, produced by its friction extreme vascularity and opacity of the cornea with distortion of its curve. Various operations had been done. The indication was to loosen the nip of the upper lid. The forefinger was pushed under the lid to the top of the scanty conjunctival sac. A narrow knife was thrust under the skin on the middle line of the lid flat-wise and when the point had got above the upper border of the tarsus the edge was turned toward the operator's finger and the point caught in the nail, then in drawing down, the tarsus was split in the vertical line into two halves and they sprang asunder several millimetres. The pressure on the cornea was relieved, no deformity ensued, for the skin was not cut, and many months afterward the cornea continued free from vascularity and irritation.

The total ablation of the ciliary border has been formerly much practised, and it may in extreme cases be appropriate; but "scalping the lids" leaves hopeless deformity and is a slur upon surgery. Only absolute necessity justifies its employment

Ectropium.

Permanent eversion of the lids arises, 1st, from chronic inflammation and hypertrophy of the conjunctiva, especially of the lower lid in old persons—a condition due to relaxation of the skin with spasm of the orbicularis muscle. It sometimes occurs during recovery from operations, as well as spontaneously. Treatment consists in excising a suitable strip of thickened conjunctiva close to the ciliary border, and perhaps removing a V-shaped portion of the lower lid at the outer canthus, to draw the lid up to the globe as well as to replace it. The excision at the outer angle is only needed when the lid droops and the amount removed will depend on the degree to which it falls. Sometimes the destruction of

Digitized by the Pacific College of Optometry

conjunctiva by Paquelin's cautery is all that is required, and the slough is left to separate. No bleeding happens and by the help of cocaine, 10% solution, the operation is very simple and easy. A fine point must be used and a deep furrow made.

The second and more frequent type of ectropium is caused by wounds, by burns, by caries of the edge of the orbit with adhesion of the skin, by removal of tumors, etc. The amount of deformity is extremely variable and after burns and explosions may be frightful.

The following general suggestions in treatment are appropriate: While some kind of operation will be required, none which involves transplantation of skin should be done, until all tendency to contraction of cicatrices has disappeared. While ulcerated surfaces are in process of repair, no operation is feasible, except the introduction of a flap either with or without a pedicle. Usually we wait until healing has occurred. The exceptions will be after severe burns. Yet it might sometimes mitigate deformity and protect the cornea, to pare the edges of the upper and lower lids behind the cilia and stitch them fast, so as to obliterate the palpebral slit, save at its extremities. The tendency to ectropium would in some measure be thus counteracted until healing had become complete and contraction of scars had done its worst. It is easy to separate them when the time for operation arrives.

Scars of moderate extent will yield to persistent traction; if attached they become looser and stretch. Subcutaneous division will not release them, because adhesion will be re-established; but it may render traction more effective.

In a case of great deformity by loss of a large portion of the lower edge of the orbit at its temporal side, the deep hollow was successfully filled by inserting a thick flap shaped like a finger from the temple and covering it over by the thin integument of the diseased locality. An incision was made parallel to the border, the skin undermined freely and united by sutures above the buried flap. Union was satisfactory.

Certain general rules are to be observed in plastic surgery. Adherent scars should be excised, or they should be buried under a flap of skin; if not, adhesion will return. Scar tissue should not be included in a flap unless the scar is very superficial and the true skin has not been destroyed. An apparent exception is in the case of the Wharton Jones sliding flap, where the whole ciliary border furnishes vascularity, yet sloughing of the tip of the flap is the risk of the proceeding. The existence of a syphilitic dyscrasia is prejudicial to success. I once met a sad disappointment in a young girl who from hereditary syphilis had lost the nasal bones; attempting

Digitized by Illinois College of Optometry

to make a new nose by flaps from the cheeks, the wounds showed no disposition to unite and underwent a torpid and unhealthy process of suppuration; the flaps shrivelled and the condition was worse than at the first.

In constructing and placing flaps, allowance must be made for shrinking, which will amount to about one-fifth in length, and further shrinking will occur after the healing. Lines of union must be so planned, if possible, as not to reproduce the deformity as shrinking of the flaps slowly proceeds, but act in the contrary manner. Again, flaps will sometimes grow thicker during subsequent weeks if they be very loose. In plastic surgery of the face, one must fit parts as a tailor fits his cloth and not fear to cut out redundant material or to smooth down elevations. By a little ingenuity puckers and welts need rarely be left.

In ectropium the ciliary border will be elongated and must often be shortened, and this is done by excision of a triangle of skin whose base is at the free border of the lid and preferably at the outer angle, while sometimes it may be done at the middle. The operation to be performed in a given case will of course depend on the conditions to be met, and each case must be studied by itself. Wounds at the inner angle dragging down the lower lid are difficult to repair perfectly. In such a case as is shown in Fig. 97 the scar on the side of the nose should be undermined, the lid fully loosened and lifted higher up, a portion excised and the cut edge joined to the inner canthus; then to fill the gap a flap may be brought from the forehead with pedicle at the root of the nose and by properly managed lines, very little wrinkling need be made: *vide infra.* A small flap could be had beneath the brow. In both cases the base of the flap is above, or at any rate not below the site of the gap, and contraction tends to correct deformity. In such a case a flap from the side of the nose would be unfeasible because the part beyond the cicatrix would slough. The sutures must be very fine and numerous and the skin thin.

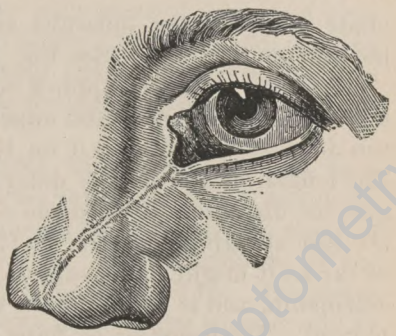

FIG. 97.

Fig. 98 shows ectropium of the outer part of the lower lid by cicatrization without adhesion to the bone. The mode of operating is clearly indicated. It will be noted that pin sutures are used. They should be very fine, be inserted well back from the wound, and are strongly to be commended. In the dissection of the flap and in bringing together the gap below the lid, the skin must be

Digitized by Illinois College of Optometry

freely undermined on all sides. The cutaneous incision may be extended right and left close to the border of the lid. The same proceeding may be applied at the outer canthus and the lines be

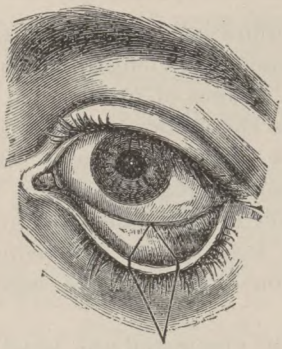

FIG. 98.

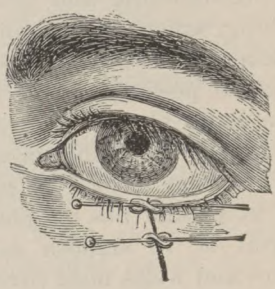

FIG. 99.

made more oblique outward and downward. This is a most important suggestion. (See Fig. 99.)

Another principle applies to more extensive deformities of this kind, both in the lower and upper lids. It is the operation of Wharton Jones, who intended it for the upper lid. (See Figs. 100 and 101.) The length of the flap is determined by the degree of deformity, and its dissection toward the conjunctiva must not be carried too far lest sloughing occur. In the figures the dissection does not go as far as it might. It is suited only to cases of moderate degrees of ectropium, and is to be chosen when the skin has not been deeply burned. The insertion of flaps is advisable for the greater degrees

FIG. 100.

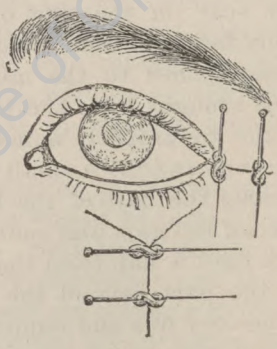

FIG. 101.

of deformity. Von Ammon figures the same method on a larger scale. I must again repeat the caution that the method must not be pushed too far.

There are many devices which may be employed in dealing with

Digitized by Illinois College of Optometry

ectropium. A most ingenious one involving the formation of two flaps, one of which fills the opening made in bringing the lid border to its place, and the other fills the vacancy whence the first flap was dissected, we owe to Richet. It meets cases of caries at the outer edge of the orbit, resulting in dragging down the outer canthus besides ectropium of the lower lid. To supplement it, the edges of the lids are pared and sewed together, not, however, destroying the cilia. See Meyer on Diseases of the Eye.

Blepharoplasty.

The transition from restoration of the lid by some method of displacement to its reconstruction by introduction of new skin, is most natural. Many cases of ectropium require the latter method, and for its accomplishment we may, 1st, use a flap from the adjacent parts kept in connection with the general circulation by a pedicle; 2d, we may transport a very thin piece of skin from a remote part and apply it in a wound (Wolfe's method); 3d, we may make use of small bits of skin, grafting them into the wound as a mosaic, the method of Reverdin; 4th, we may put in a thin shaving of skin by Thiersch's method.

The last two methods are suitable where the skin has been widely destroyed and healthy material for flaps is not available. They can also be happily employed during the granulation stage of burns to prevent or mitigate deformity. Partial closure of the lids by tarsoraphy may simultaneously be resorted to. The pieces (Reverdin) must be thin, say about two millimetres square, and as numerous as occasion demands. When in place they should be covered with gold-beater's skin, over this a pad of lint, and all held firm by plaster or a bandage. The outer dressings may be removed once daily, and the state of the grafts will be seen through the gold-beater's skin. They take on a white, sodden appearance, then become red and seem lost in granulation, but soon a healthy cicatrix, *i.e.*, epidermis appears. The proceeding may be repeated.

Analogous to grafting is the transplantation of a considerable piece of skin from a remote part. This proposal emanated from Mr. Wolfe, of Glasgow, 1875. The skin may be taken from the chest or the inner side of the arm. A pattern the size of the place to be filled, is to be laid down, and the outline of the piece to be transported must exceed it by eight to ten millimetres all around. Subcutaneous connective tissue is to be completely removed and this is most easily done while the piece is being lifted. When put *in situ* all bleeding must have stopped and fine sutures introduced; cover it with gold-beater's skin, then with collodion, and over all cotton or a bandage. The parts must not be disturbed, although

Digitized by Illinois College of Optometry

the bandage may be taken off in two days. The gold-beater's skin and collodion will remain unchanged for many days. The epidermis comes off and the piece looks very white; sometimes it becomes red, moist, and like ordinary granulation tissue. It at length assumes a firmer character and may correct the deformity. Such material is, however, subject to an extreme amount of contraction. A flap 3⅛ inches long by 1⅜ inches broad has after three months been reduced to 1½ x ⅜ inches. The tarsal margins may be united for several months to counteract the shrinking. It is both interesting and surprising that in so many instances (at least twenty are recorded) the flap survives and gives desired relief, yet it sometimes sloughs, as twice has happened in my own experience. The conditions of health are extremely important, and that the flap be free from fat and connective tissue, that it fit accurately, that no hemorrhage shall occur beneath it, and that it lie absolutely undisturbed for a week. If the operation fail, some other method may be tried, or it could even be repeated. The place from which the skin is taken may take several weeks in healing. The flap, according to Thiersch's method, is less liable to shrink, because the shaving is thinner, being taken by a razor, and is no more prone to slough. It is more simple.

In a large class of cases, particularly where neoplasms are removed and more or less of the lid is sacrificed, other methods for immediate repair must be employed. Without attempting to describe all the possible ways of meeting difficulties, certain proceedings will be illustrated which have been found effective in my own experience. There are several situations from which flaps may advantageously be taken: 1st, from the temple; 2d, from the forehead on the median line; 3d, from the side of the nose, the naso-buccal flap. All these are available for both the upper and lower lids. 4th, a flap may also be taken from the region in front of the ear, whose base shall be above and near the zygoma. This is in a direction opposed to the course of the blood-vessels and in so far is disadvantageous, yet if necessity compel, it may be employed. A vertical flap from the temple whose base is below, may be allowed to run a little distance into the hair, and the hairs will to a great extent fall out and disappear by obliteration of the follicles. Sometimes the place from which the flap is taken, in the temple for instance, cannot be closed by sliding the adjacent skin—in the scalp this is easily remedied by moving forward a second flap to fill the gap, and the vacancy thus caused may be left to granulate. The scar which results is pushed so far back as to be covered by hair and be unobjectionable. Even on the face this device may sometimes be practised.

A flap from the temple, when designed for the lower lid, should

Digitized by the Internet Archive

be more or less vertical and the pedicle be a little higher than the level of the lid. The cut on its lower or anterior side should run farther back and down than on the upper, and if much of a wrinkle occurs in turning it down, a triangle may be excised, and sufficient breadth of pedicle is to be allowed to permit it. Small trimmings should always be done at the time of operating, and extensive undermining practised to liberate the neighboring integument. The shortening of a flap after being lifted will usually amount to about one-fourth its length. Accurate coaptation by numerous very fine black silk sutures and by fine pins, so-called insect pins, where any tension occurs is indispensable. All bleeding must first be staunched. The lines of union may be covered with contractile collodion mingled with fibres of absorbent cotton, which makes an air-tight, inflexible dressing of the utmost value. Adhesive straps are wholly needless. I never use iodoform and, if antiseptic dressing is required, depend on absorbent cotton soaked with sublimate solution 1: 3,000, retained by a flannel bandage; it is kept constantly wet and need not be renewed oftener than twice in twenty-four hours. Sutures are allowed to remain three to seven days; pins to be removed on the second or third day. If any tendency to suppuration appear about the pins or sutures, remove them, wash well with sublimate solution, and either continue to apply it, or sometimes the collodion and cotton dressing may be reapplied. If at an early date the wound reopen for a short space, insert a silk suture. Such are some of the suggestions suited to all plastic operations.

Another mode of forming a lower lid is by horizontally sliding a flap forward, from the region of the zygoma (Knapp), and it may, if needful, be met by one from the side of the nose. An instance is represented in Figs. 102 and 103. The divergence of the lines of incision at their base is very important. The case was one of cancerous growth.

The *naso-buccal flap* is proper for repair of the inner portion of the lower lid, and less satisfactorily for the upper lid. If the tissues are very loose, a considerable loss of substance can be repaired at the nasal side of the lower lid without making any flap. In Fig. 104, page 275, excision of an epithelioma removed the inner half of the lower lid and skin over the region of the lachrymal sac. The deficiency was supplied by merely sliding up the cheek which was very lax. A vertical cut was made down to the ala nasi along the naso-buccal furrow; an incision close to the border of the lower lid was carried horizontally backward almost to the root of the zygoma. The whole cheek was undermined, taking care to avoid the duct of Steno, and carried forward and inward and attached to the inner canthus. No conspicuous scars were left.

Digitized by the Internet Archive in 2010 with funding from University of Toronto

The photograph was taken very soon after recovery, before swelling had subsided. Sometimes the incision backward may begin at the outer canthus and the remaining part of the lower lid be carried inward with the loosened cheek. Free division of the external canthal ligament must always be practised when the lid is slidden. If the inner part of the upper lid is also involved, we must take a flap from the glabella, or may slide one across the root of the nose, relying on the vessels of the other half of the face. Figs. 106 and 107 represent a case before and after operation where slid-

FIG. 102.

FIG. 103.

ing the cheek inward and upward was combined with a flap turned down from the glabella. The ultimate result was comely. I once combined the operation of sliding the cheek with the introduction of a transported flap (Wolfe's method) to fill the lack at the inner part of the upper lid, but the piece sloughed and I was obliged to slide a flap from above the root of the nose.

The naso-buccal flap can be made to form an upper lid. See figures illustrating case reported in "Trans. Fifth International Congress of Ophthalmology," 1876. (See page 277, Figs. 109 to 112.)

A flap from the middle of the forehead can be utilized for the upper lid and for defects at the inner canthus and of the inner part of the lower lid. Fig. 105 represents a case where epithelioma had

Digitized by the Ohio College of Optometry

FIG. 104.



FIG. 105.

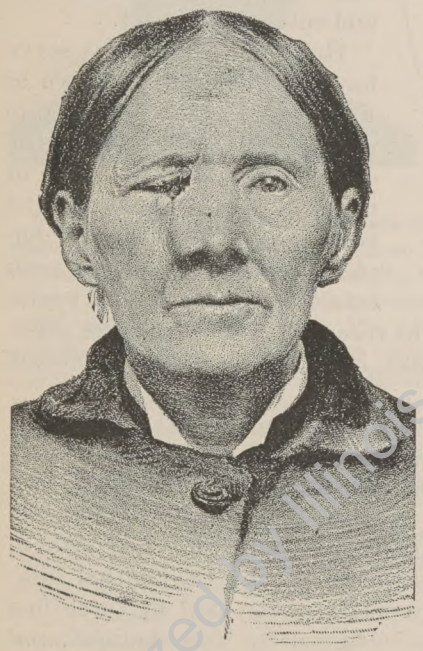

FIG. 106.

FIG. 107.

Digitized by Illinois College of Optometry

attacked the region of the inner canthus and begun to penetrate the orbit; the inner half of the lower lid, the caruncle and inner third of the upper lid had to be removed. The flap taken from the forehead was so arranged that its base was laid upon the opposite side of the root of the nose; the arterial supply coming from the trochlear branches and angular artery of that side. Before it was sewed down the wound in the forehead was closed after undermining the skin freely, the brows were slidden to each other, the gap in the upper lid was easily closed, and then skin was removed to make a bed in which the flap could lie smoothly and without traction. By carrying down the incisions for the flap to the opposite side of the nasal bones, the objectionable wrinkling of the flap is entirely avoided and it lies so smoothly that it is hard to be detected after a few months. This man was exempt for five years from a return of the disease, but now, seven years afterward, it has reappeared extensively and entered the orbit.

FIG. 108.

How such a flap may serve for the upper lid is shown in Fig. 108. The photograph was taken seventeen days after the operation and the same plan of reaching across the nose can be recognized. The relief was complete. The ectropium had been total and had lasted nine years.

Various other methods must be resorted to as exigencies arise, and they are described in text-books, but I have stated the means on which I rely.

Blepharophimosis, or narrowing of the palpebral opening, is generally the result of chronic trachoma. Its hurtful effect is by pressure of the lids on the cornea, and it is to be relieved by two methods of operating. The more usual one consists in splitting the lids apart at the outer angle and releasing them from their attachment to the bone by clips of the scissors through the canthal ligament, and finally uniting the conjunctiva to the skin by three fine sutures. This is *canthoplasty* as designed by Von Ammon, and it is often done as auxiliary to operations for entropium. Instead

Digitized by Illinois College of Optometry



FIG. 109.



FIG. 110.

FIG. 111.

FIG. 112.

Fig. 109.—The man's head and face had been burned by kerosene oil. There were numerous ulcers in the scalp and on the forehead and such deep cicatricial tissue on the forehead that the best available material was by the naso-buccal flap. The blood-vessels to nourish it were chiefly those from the opposite side of the median line. The ectropium of the upper lid was complete, and the flap had to be about four inches long. Besides inserting the flap and uniting the gap in the face, the edges of the upper and lower lids were freshened by paring their edges behind the cilia for two-thirds their length and then uniting by sutures. Primary union was obtained to a sufficient degree and the cornea was covered. As seen in Fig. 111, considerable thickening and irregularity remained, which was greatly remedied by a subsequent operation.

Had not the lid borders been united, the deformity would have largely returned. Many months after, the appearance was seen in Fig. 112. The outline of the incisions is shown in Fig. 110. A shorter flap will sometimes suffice, but the incisions are the same in all such cases. The dotted line under the lower lid shows how far this cut was carried, and the whole cheek was laid back. The tip of the flap was cut off to give it proper shape.

Digitized by the Internet Archive of Optometry

of cutting the lids apart with scissors, it is better to separate them by a speculum and push a Beer's cataract knife or very narrow bistoury into the edge of the lid at the outer angle, splitting up and down along the border, and then cut the skin in a straight line outward, but leave the conjunctiva undivided. The external canthal ligament will be severed by a few strokes of the scissors to free the lids, and then the conjunctiva united to the skin.

In very severe cases of shrinking of the conjunctiva with blepharophimosis and perhaps with entropium, a plastic operation may be needed and this I have called canthoplasty, while the above operation might be known as cantholysis. The lids are split apart for half an inch and a flap, with apex upward, is inserted; to obviate wrinkling, the cut is extended downward as required, both on the anterior and posterior sides.

Tarsoraphy, or the uniting of the edges of the lids, has been referred to. It is called for in total paralysis of the facial nerve including the orbicularis muscle, and may unite one-third of the length of the lids at the outer angle. Complete union of the edges of the lids is done as an auxiliary sometimes to operations for ectropium. The method is simple, viz., paring off the posterior angle of the tarsal borders by a Beer's cataract knife and uniting by stitches. If the lids are to be again separated, a point must be left ununited.

Injuries and Lacerations of the Lids.

Powder burns occur by accidents in blasting, and may be complicated with other and extensive injuries, as we find among miners; boys often suffer the penalty of playing with gunpowder. The pain and inflammation are relieved by cold lotions, while the removal of the unburnt powder is to be effected by patiently picking out each little granule with a spud or cataract needle. The process is tedious and rather painful. Much of the powder will come out with the desquamating skin, while what lies below the epidermis must be picked out bit by bit, soon after the burn is produced. Blistering after the skin has recovered, has been suggested to bring out the remaining granules, but it does not seem promising.

Lacerations and wounds through the tarsal border may, when fresh, be easily united by putting a fine pin through the free border of the tarsus, carefully stitching the conjunctiva and putting in the skin as many silk sutures as needful. Over all apply the collodion cotton dressing. If the injury is old and the parts have healed, perhaps, with ectropium, the edges of the cut must be freshened, the normal position restored, and the same treatment adopted. (See Fig. 113 from Lawson; a probe is inserted in the canaliculus.)

A case recently under treatment is illustrated by Fig. 114. An

Digitized by Harvard College of Dentistry

Italian was cut in the face by a razor. The wound involved the border of the upper lid, split the cornea and passed down through the lower lid three inches upon the cheek. The wound of the face was sewed up before he entered the N. Y. Eye and Ear Infirmary. There was prolapse of the iris and the lens was partially cataractous. The prolapse of iris was excised. In healing, adhesion of the inner border of the pupil, as well as of the lens capsule to the cornea, took place. Gradually by contraction of the thick scar on the cheek which had united with suppuration, the lower lid became everted. This was after many weeks relieved by excising the whole length of the cicatrix, undermining the cheek on either side of it, and at its upper extremity making incisions right and left at a point about one quarter of an inch below the lid border, stretching up the lid

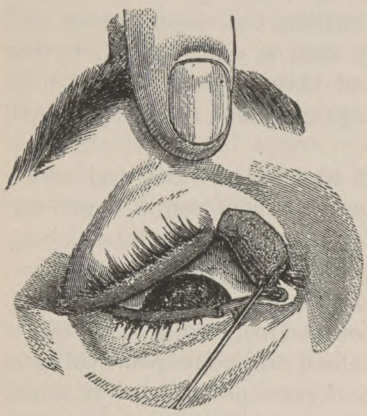

FIG. 113.

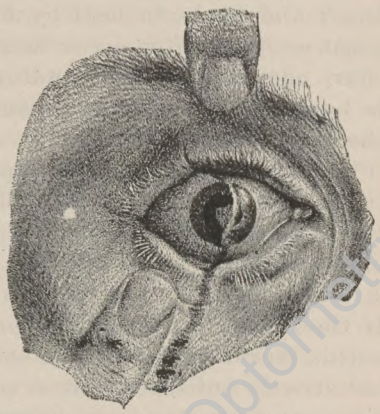

FIG. 114.

to open out the horizontal wounds and pulling them together from the sides. This raised the tarsal edge to place and brought the lid in apposition with the globe.

More than once I have known the lid torn away from the inner canthus by a button-hook which a young child had thrust under its own lid. The tarsus is detached from the superior conjunctival sinus, and in replacing it, sutures must be first inserted on the inner surface through the tarsus and conjunctiva to secure its replacement, and as a separate step the wound of the skin united. In a recent case no deformity need remain. Very recently a girl four years old inflicted the same injury upon her lower lid, tearing it off for two-thirds its length, and when brought to me ten days later, suppuration was established. It was necessary to freshen the edges of the wound, to extend it farther outward along the zygoma to compensate for the shortening due to its having flapped loosely for so long, and carry it well inward. Fine silk

Digitized by the Internet Archive of the College of Optometry

sutures and the collodion cotton dressing held the parts immovable for a week, and despite the tardiness of effective surgical help, union *per primam* was obtained with no deformity. Such accidents happen by bursting of soda-water bottles, by falling upon butchers' meat-hooks, by the thrust of a stick or of the horn of a cow, etc. Sometimes the levator palpebræ is torn off, and the walls of the orbit may be fractured. Treatment must be adapted to the various exigencies which arise. If a canaliculus is torn, one may have to search for the remaining portion and open a way into the sac, which probing a few times with a lachrymal sound will keep patulous. If this be impracticable, the uninjured canaliculus will usually fulfil the physiological requirements.

A blow or fall upon the brow often produces a wound of the skin which does not externally indicate its real severity. It may seem small and likely to heal by first intention, but suppuration and great swelling often occur because the skin is cut beneath by the sharp edge of the bone. Sutures are of little use and indeed may be harmful; warm poultices and antiseptic lotions are proper until the reaction subsides.

Ecchymosis of the lids happens by blows and falls and sometimes from straining in whooping cough or from senile degeneration of the vessels. If moderate in amount, stimulating lotions may in the beginning do good, such as alcohol and water, or as follows: ℞ Tinct. arnicæ, ʒ iv.; Liq. ammonii acetatis, ʒ i.; Aquæ, ad ʒ viij. If there be a large clot, the practice of the prize ring is to tap it with a lancet and squeeze or suck the blood out. The proceeding is not strictly antiseptic, but evacuation of part of the clot is sometimes good practice, care being taken to suture the wound or close it with collodion and cotton. After a few days no applications can be useful, save the artist's skill who "paints your eye while you wait."

Coloboma of the lids is a congenital deformity which rarely occurs and usually affects the upper lid. It may be on the middle or nearer the inner end, as in a case which fell under my notice. There may be no other defect of structure. But much more extensive deformities are seen with arrest of development of the face.

Treatment by paring the edges and uniting the opening by sutures, as in wounds, is obvious.

Epicanthus, sometimes called *encanthus*, is also a congenital malformation whose name is derived from crescentic folds of skin which run downward from the inner end of each brow, skirting the inner canthus and disappear over the lachrymal sac. But in many cases several other conditions coincide with this and are of more serious moment. These are, deficient development or absence of the levator palpebræ superioris muscle, narrowness of the palpebral

Digitized by the College of Physicians

slits, with a tendency to slope upward at their outer extremities, great flattening of the ossa nasi. The deformity varies in degree, is apt to be hereditary, and to be associated with defects in the development of the eye, such as hypermetropia, or albinism, or nystagmus. I have seen three cases in one family. A striking case is figured by Von Ammon. The frontal portion of the occipito-frontalis muscle is constantly called into play as in cases of paralytic ptosis, and the head has to be thrown backward to look at objects which lie even a little below the horizontal meridian. In some instances nothing can be done, or requires to be done, while in other cases the wrinkle at the inner canthus is unpleasantly conspicuous, and can be remedied to some degree by excising from the root of the nose an elliptic piece of skin, and undermining the adjacent folds very freely, so as to loosen them from their periosteal connections. The wound is closed by harelip or fine pin-sutures, and a vertical scar remains on the median line. Besides this, it is sometimes useful to perform the usual operation of canthoplasty at the outer angles. I have a photograph of a child who had a high degree of this deformity and aggravated converging squint. Nothing was ever done for her, because her drunken mother found the pitiful condition of the child a means of profitable mendicancy.

Affections of the Muscles of the Lids.

Spasm of the orbicularis occurs in two forms: the tonic or partial, and the clonic. The first affects only a few fibres, is hardly perceptible, and is merely a trifling annoyance. It comes from strained accommodation, or slight conjunctival irritation; rest and general tonics are appropriate.

The clonic form is sometimes called facial tic and is discussed in treatises on nervous diseases (see Gowers). It is paroxysmal and painful and the spasm often seizes upon other facial muscles. I have seen several examples of this affection. The face is thrown into ludicrous and painful grimaces, and the spasm is excited by very slight irritations. In the case of a car-driver who had two attacks of it under my observation, it once seemed to be produced by the severe cold of the winter wind. Only one side of the face was affected, and when the attack came, it would be thrown into extreme convulsions: the skin would become red, the mouth be drawn up, the lids tightly shut, and he would suffer severe pain. Such turns would happen many times a day, and they recurred during several weeks. He appeared to derive benefit from full doses of bromide of potassium. I have seen a clergyman whose whole face was thus contorted in interrupted paroxysms, and for whom remedies were of little value, but after several years I was happy to

Digitized by the College of Optometry

find that his affection had become almost imperceptible. Aconitine and gelsemium are remedies relied on, but materia medica is often useless. A less serious spasm, which is a kind of nictitation, may occur as an unconscious habit or trick. It may be confined entirely to the eyelids, and be a congenital and life-long peculiarity. A distinguished sculptor of my acquaintance is thus affected, and has a little impediment of speech. A lady friend had it for seventy years, and her powers of speech were not impaired. Sometimes there will be a point of tenderness over the supra- or infra-orbital nerves, or on the temple, and perhaps at the back of the neck, or the cause of reflex irritation may be a defective tooth. Should such tender spots be found, they suggest indications of treatment, such as neurotomy, local anæsthesia, counter-irritation, hypodermic injection of morphia at the place of tenderness, etc. The disease is often cerebral, either cortical or nuclear. See Gowers, p. 660, Am. Ed. In many cases no treatment avails.

It is important to bear in mind that sometimes the intensity of the symptoms can be greatly relieved by removing optical and muscular errors. While there may be some positive nerve or central lesion, removal of peripheral exciting causes may greatly abate the distressing symptoms. The analogy of such cases with asthenopia and epilepsy is obvious. The following case is in point and more briefly is referred to on page 209.

Dr. D. W., 47, first seen Dec. 29th, 1889. His father's grandmother became insane after the accidental death of her husband. His father has been twice confined in an insane asylum. The doctor himself resembles his mother, in whose family there is no insanity. No history of chorea or epilepsy on either side. Dr. W. has always been easily excited, quick to take offence, but is now much better able to control himself than in his younger days. Never had syphilis, rheumatism, or gout. Children strong and healthy.

Dr. W. has suffered much from malaria, which manifests itself particularly in hemicrania and frontal headache, recurring every two weeks, but controlled by quinine.

In the summer of 1881 he first noticed twitching of the right orbicularis muscle and consulted Dr. Weir Mitchell who suggested nerve section, but referred him to Dr. Thomson, who thought the trouble was reflex and corrected his refractive error under duboisia, viz.,

O. D. + 1.00s. ⊂ + 1.00c. ax. 10° V. = 1.
O. S. + 1.75s. . . ax. 180° V. = 1.

The correction was ordered for reading only. While using duboisia he was free from the spasmodic action of the orbicularis and was somewhat relieved by the use of the glasses for a time. Later on the trouble increased, so that now, Dec., 1882, all the muscles of the right side of the face twitch, the twitching being most marked in the orbicularis, wing of nose, and angle of the mouth in the order mentioned. There is tremor of the ocular muscles, producing nystagmus which prevents a view of the fundus of the right eye. There has been diplopia. After prolonged twitching there is numbness of the right side of the face. There is now tenderness over the supra-orbital,

infra-orbital, malar, mental, and palatine twigs of the right fifth nerve and also over the styloid process, with hyperæsthesia of the right side of the face.

Without atropine,

O. D. + $\frac{1}{36}$c. ax. 10° V. = $\frac{20}{20}$.
O. S. + $\frac{1}{36}$c. ax. 20° V. = $\frac{20}{20}$.

The above glasses were ordered for distance with an additional + $\frac{1}{36}$s. for reading. ℞ Pot. iod. in increasing doses.

Mar. 5th, 1883.—Has been much relieved by distance glasses. Less tenderness over branches of supra- and infra-orbital nerves, although the spasms occur at night with considerable severity. Had tried pot. iod., hydriodic acid, and galvanism without effect. Has seen Dr. Janeway, who thinks the lesion may be thickening of a nerve sheath.

Feb. 15th, 1888.—The glasses greatly relieve the spasm and he is unable to get along without them. The twitching is excessive if he leaves them off, and is confined to the right side of the face as before; it is greatly aggravated by any excitement. The eyes tire more quickly in reading than from any other cause and this provokes the spasm. He is often obliged to close the right eye in reading. The twitching is at times so excessive that he has great difficulty in getting to sleep. At times there is twitching of all the muscles of the right side of the face with slight numbness. Occasionally there is ptosis (right) and considerable rubbing and manipulation is required before he is able to open the right eye. Diplopia is an occasional symptom. Drugs have proved almost useless, although the bromide of ethyl and a 4% solution of cocaine are, however, of temporary benefit. He has also been somewhat relieved by galvanism.

Out of doors he rarely has any trouble. The nose is prominent, limiting the field of binocular vision to about 45°. Movement of O. D. outward is limited and irregular; movement of O. S. outward is also limited. Prisms with bases out render objects much more steady and distinct; without them he sees the gas jet as if through a fog.

18′ abd. = 3° add. = 13° v. d. = 5° latent conv.
13″ gl. abd. = 10°+ add. = 15° v. d. = 3° conv.

Javal's ophthalmometer shows:

O. D. 0.5 ± ax. 55° and 145°.
O. S. 0.5 ± ax. 90° and 180°.

℞ O. D. + 0.75c. ax. 10° ⌒ prism 1½°, base out.
O. S. + 0.50s. ⌒ + 0.75c. ax. 20° ⌒ prism 1½, base out.

June 18th, 1888.—Has found above glasses "wonderfully restful." Before wearing them could hardly get to sleep on account of the twitching, and then only by pinching up the skin over the right temple. Now has no trouble in getting to sleep unless very tired. Has much less twitching and less ptosis than formerly. Sept., 1890.—Still relies on glasses. Twitching grows worse.

Paralysis of the Orbicularis Muscle, or Lagophthalmus—causes annoyance by exposure of the cornea. The eye is fretted by external irritation and overflows with tears which cannot be directed into the lachrymal puncta. Both the tensor tarsi and orbicularis are flaccid and the lids fail to hug the globe. Chronic conjunctivitis, and even inflammation of the cornea are to be ex-

Digitized by the Medical College of Optometry

pected. The cause lies in lesion of the seventh or facial nerve. It is not uncommon for the orbicularis to escape when other muscles supplied by the inferior branches of the facial plexus are involved; but, if the orbicularis is paralyzed, all other muscles are also apt to suffer. The causes of facial paralysis are peripheral, or lie along the track of the nerve, or are in the brain. From the crookedness of its course, and the variety of tissues which it traverses, the nerve is greatly exposed to injury and it may be wholly or partially affected. One need only remember that diseases of the ear, and of the lymphatic glands, and of the parotid, are all liable to do mischief to the facial nerve. As to the cases of cerebral disease, Eulenburg says that facial paralysis, originating from lesions of the pons, involves the orbicularis; while, if it proceed from the cerebral peduncles, or from the central ganglia, or from progressive paralysis of cranial nerves, or from spinal cord affections, the orbicularis is likely to escape.[1] Peripheral paralysis of the seventh nerve usually includes the orbicularis. The cases of partial impairment are most common. I have seen two instances of total paralysis caused by wound in the space between the angle of the jaw and the mastoid process. In the case of a mason the wound was inflicted by falling on his own trowel. I have seen this patient sixteen years after the wounding and found partial recovery of function in the facial muscles. For seven years the outer half of the palpebral fissure was closed by tarsoraphy and then they were fully reopened. At this date (January, 1889) he has power to close the lids enough to protect the cornea. Union of the ends of the nerve has doubtless occurred.

Treatment will be governed by the supposed cause of the lesion. The remedies to be used will suggest themselves. If the cornea be much exposed, it may be necessary to wear a bandage, or to partly close the lid by a strip of plaster near the outer canthus. During sleep the lid will drop a little from its own weight, because the levator is relaxed and the cornea turns up so as to be covered, even when paralysis is total. One of the aggravations of the trouble comes from the frequent wiping of the eye to get rid of the tears, and the lower lid is dragged down to an additional degree, and may pass into permanent ectropium. When this state arrives, relief will be afforded by paring the edges of the lids for ten to fifteen millimetres at the outer canthus, and uniting them by sutures to shorten the palpebral opening (*tarsoraphy*). The cilia are left untouched. The sutures should be left *in situ* from four to six days. I have lately seen a man for whom I did this operation seven years ago, and the relief it gave continued until within a few months. The continued paralysis and the drag of the lax tissues

[1] See Gowers' "Diseases of Nervous System," p. 657.

finally brought on troublesome ectropium of the lower lid at the inner canthus, with a return of the former epiphora. I performed another operation of tarsoraphy at the inner canthus, in a different manner, as follows: I dissected up a parallelogram of skin above and below the canaliculi, for a space which reached from the commissure to three millimetres beyond the puncta. I turned the raw surfaces of the little flaps, raised from the respective lids, against each other and stitched through them. The puncta were thus turned inward and out of sight. The edges united, and the palpebral slit was left as a narrow oval through which the pupil could peep, and the annoyance of the epiphora was removed.

Ptosis.—There is a so-called spurious ptosis or drooping of the upper lid due to chronic trachoma and which remains after the disease is practically cured. The lid can be raised, but not to the full height. The levator is not paralyzed, but its action is hindered. Genuine ptosis indicates partial or complete paralysis of the levator palpebræ superioris. It may concur with impairment of other muscles supplied by the third nerve, or be isolated. If complete, the upper lid covers nearly all the cornea, and is raised only by extreme contraction of the occipito-frontalis, lifting the brow, and by traction on the skin pulling the lid up enough to enable the patient to peep under it, when he throws his head backward. The attitude of the head, when such patients attempt to use their eye, is highly characteristic. The causes of the disease are peripheral or central; the most frequent is syphilis. It may be well to remark that a little drooping of the lids may be congenital, and may be confined to one eye or affect both. The true action of the levator is conspicuously suggested, when the only muscle able to act on the lid is the occipito-frontalis. The latter simply stretches the skin, and if lax, can exert but little effect, while the levator pulls from the cavity of the orbit and rolls the lid over the convexity of the globe, and at the same time causes a furrow in the skin.

The *treatment* of ptosis consists, first, in combating the cause if this be ascertained; second, in stimulating the muscle by the faradic current of electricity; thirdly in operating. As to the first indication, we give iodide of potassium in small doses, gr. v. ter in die, for supposed rheumatic cases, and in larger doses with mercurials in syphilitic cases. This treatment should be held to, for four or six weeks. After the first week or two, the battery may be used for a few minutes, once daily, or as often as practicable. With one pole behind the ear, the other is placed on the lid, and the current should be only of moderate strength.

After the lapse of three or four months without adequate improvement we may employ an operation. The removal of a por-

tion of skin and orbicularis fibres is the old mode. Pagenstecher, 1881, suggested the introduction of sutures beneath the skin to run up to the forehead above the brow, to be tied tightly, and by the resulting cicatrices after they have cut out, reef up the lid. Wecker has combined excision with sutures in a manner portrayed in the figures. A portion of skin and muscular fibres is removed from the upper half of the tarsus and its breadth will depend on the fulness of the lid. A strong thread is entered at *a* above the brow, pushed beneath it and the skin of the lid, keeping close to the tarso-orbital fascia, and coming out at the upper edge of the wound; it glides over the muscular fibres and then dips under the skin and muscle at the lower edge of the wound, emerging is carried transversely

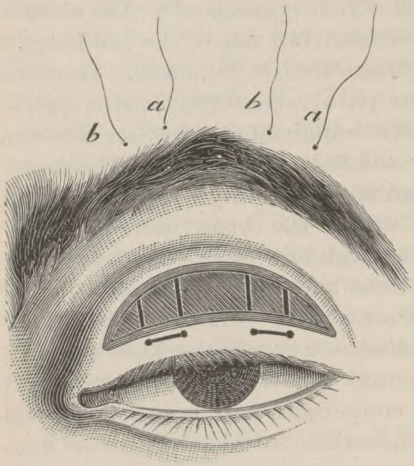

FIG. 115.

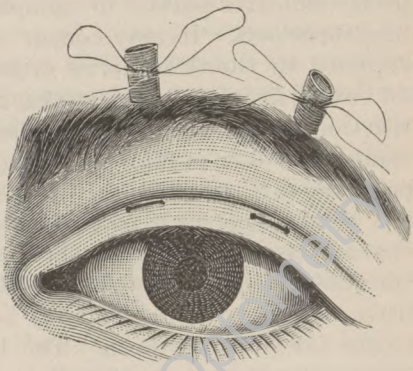

FIG. 116.

for a space of about five millimetres and then travels back on a reverse course up to *b*. Two such sutures are introduced. They are tied with a bow knot over a roll of plaster and tightened from time to time as they grow slack. The wound is thus pulled together and the due amount of effect is to be attended to. As the sutures cut through the tissues, cicatrices are formed which hold the lid up permanently. The proceeding is ingenious and superior to simple excision of a flap. I have done it with benefit in a case of ophthalmoplegia exterior bilateralis, where not only ptosis but paralysis of all the extrinsic muscles existed. The case was congenital and the lesion nuclear. If other branches of the third nerve are paralyzed, it may be inexpedient to cure the ptosis because the patient will be subjected to the distressing annoyance of double vision.

The drooping of the lid succeeding trachoma may be relieved by

Digitized by the Internet Archive of Ophthalmology

sutures employed in a manner similar to Hotz's operation for entropium (Gruening). An incision is made just below the upper edge of the tarsus and parallel to it. Some orbicularis fibres may be excised. With a sharply curved needle the thread is pushed along the surface and upper edge of the tarsus through the conjunctiva, until it loops up the cul-de-sac and returns upon itself beneath the skin to come out at the upper part of the wound. It never traverses the skin. Three sutures may be used. They are tied tightly and allowed to remain two to five days, according to the degree of reaction. The skin wound is closed as usual. By the same proceeding, if the needles are carried up to the edge of the orbit and engage the periosteum a much greater effect will ensue and superior to that secured by Wecker's operation just described. Drooping of the lid from redundancy of skin is easily cured by removing a suitable flap. The proposal to advance the tendon of the levator has not met with general adoption; it is not effective enough to be useful. An attempt has been made to enable a patient to open the eye by using a cord of india-rubber (Von Bibber), one end of which was fastened by plaster to the lid, and the other to the forehead. With the same object a spring clamp to pinch up a fold of skin has been devised, to be worn habitually. Neither the clamp nor the rubber band commend themselves in point of elegance and not much in utility. A moderate degree of ptosis is one of the symptoms of disease of the sympathetic in the neck which was first pointed out by Horner. It will be referred to later. See page 469. Two cases of lipomata of both eyelids causing ptosis are reported by Schell.

Burns of the Eye.

Superficial burns of the tegumentary surface of the lids need not detain us, but those of the conjunctival surface are important because they often lead to adhesions of the lids to the globe or to each other. Caustic materials or melted metal are the usual causes of the accident: for instance, fresh mortar, lime, nitric or other acids, ammonia, melted lead or iron; and red pepper may be mentioned, which, while not destructive, is extremely irritating.

When lime gets into the eye, it must be washed copiously with water, but the only effective means of removal is by forceps, or a spud or curette; wiping out the coarser masses with a bit of rag will serve, but the little pieces which remain, eat their way into the tissue and become incorporated with it. At the inner canthus, and in the cul-de-sac, it will be lodged, and must be dug out patiently and thoroughly. Often ether must be administered. After complete removal, syringe away all particles with warm water. The relief for pain is cocaine and cold water. Of course an anodyne may be given. The danger is of adhesion of the lids to the globe,

Digitized by the College of Optometry

and of deep opacity of the cornea. The lids must be pulled away from the eye and adhesions torn several times daily, and in mild cases good will follow. Nothing can prevent the formation of attachments in case the burn is deep, as the resulting ulcer slowly granulates and contracts. Shields of lead, and dressing with lint and sweet oil, and pulling the lid away, are then unavailing, but a shell of glass resembling that used as an artificial eye, transparent and convex enough to leave the cornea untouched has lately been tried with some success. I should advise a mixture of iodoform and vaseline on the cornea, say ʒ i. ad ℥ i., in bad cases where its infiltration threatens.

Fulminate of silver or mercury, which are used in percussion caps and in boys' torpedoes, besides their terrific explosive power, have a peculiar destructiveness in the kind of burn produced. The conjunctiva becomes covered by a deep gray thick exudation, which can be pulled off in sheets, leaving a raw, bleeding surface, and is speedily reproduced. It resembles the worst forms of diphtheritic exudation and is attended by severe inflammation. The cornea may share in the process, and if it do not, is most liable to ulceration. The destruction of the conjunctiva leads to adhesions of the lids to the globe. I have seen two accidents of this nature, and their results were deplorable.

Burns by melted metal are often less severe than those due to lime, because when the metal cools it is taken out as a cup, and there is no continuously destructive chemical action. Nitric, sulphuric, and acetic acids, can do great mischief. They are to be washed out with cold water freely applied, and the case treated for subsequent reaction. Ammonia causes a more superficial eschar, and is exquisitely painful. Besides cocaine we may use castor oil, vaseline, ice, etc. For red pepper, however dastardly its intentional use, it may be said that it does not cauterize. The ulcers caused by burns are damaging to sight in the ratio in which the cornea has been involved. But a better result can generally be expected than the first look of the case suggests. Several weeks or months will be needed for recovery.

Symblepharon. — When the ultimate contraction has been reached, we have adhesion of the lid to the globe, called *symblepharon,* and the question of repair is to be considered. The difficulties are in proportion to the extent of adhesion. For columnar bands, good results are possible; for total attachment of the whole lid-surface, the difficulties of an operation are great. No good at all is to be had by simply dissecting the tarsus and globe asunder— the lid is sure to go back to its old site. Naturally, the lower lid is the most frequent sufferer. Frequent traction on the cicatrix will in time stretch it to a greater or less degree. The cure is attained

Digitized by the Internet Archive

by means which shall not only separate the lid from the globe, but prevent readaptation. For columnar attachments, the old proposal of inserting a lead wire through the mass at the fornix is of value. It has to be worn until a permanent hole is formed, which shall be lined by a kind of epithelium; then the adhesions may be cut, and the parts can be kept from growing together. But this operation is superseded by one of Arlt's (Fig. 118). He dissects down the frenum, beginning on the globe, until he lifts it up to the fornix. Through its free end a thread armed with two needles is passed, and these are pushed through the cul-de-sac to the surface of the skin, and the thread tied over a roll of plaster or bit of wood; by this device the outer surface of the column is laid against the globe. The raw surface is now covered over by bringing down flaps of conjunctiva from either side. A glass shell may be worn over the

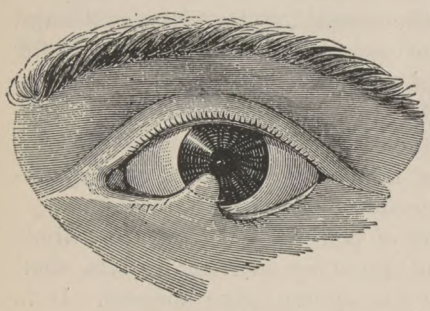

FIG. 117.

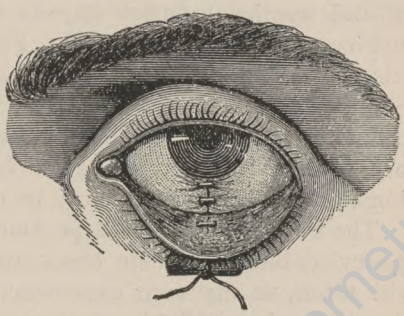

FIG. 118.

globe which will aid in preventing contraction. If the new tissue overlap the cornea, it may be left *in situ* and the dissection made where the edge of the cornea should be, as in Fig 117.

For more extensive degrees of symblepharon, another operation is available. The adhesions are dissected down to the fornix, then the vacancy on the globe is to be filled, while the lid is left to itself. Instead of sliding flaps of conjunctiva, as may be done in mild cases, a kind of sling is made in this way: from near one side of the vacancy a curved incision in the conjunctiva is carried around, just outside the cornea, to the opposite side of the vacancy. Then another incision, concentric to and outside this, is carried around, but its extremities must not come nearer to the vacancy than five to seven millimetres. It may even go up to the fornix, and with the first incision it incloses a band which may be from five to eight millimetres wide. Care is taken to make the ends of the band the widest part, by turning the extremities of the upper wound upward. The band is then loosened, except at its ends, and slipped down over the cornea to take its place in the

gap made by removal of the adherent cicatrix. It is convenient to put threads into the edge next the cornea before making the outer incision: they serve to hold and draw down the flap, and are used to fasten it in place. They may be carried entirely through the lid and tied on the skin. Some readjustment of intervening and adjacent conjunctiva is required, while the flap is carefully fastened by fine sutures in its bed. The spot from which it has been taken is left to itself. That in time, by granulation, becomes covered by a tissue which perfectly resembles normal conjunctiva. The result of the operation is most fortunate, and I have done it several times with great satisfaction. Operations by putting in separate flaps from either side, twisting them down, and uniting them by suture at their free ends, have been done by Knapp, Teale, and others. Mr. Teale, who first suggested conjunctival flaps, applied one to the inner surface of the lid after it had been dissected off and applied another flap to the eyeball, so that the epithelial surfaces should be in contact. For cases which may be too bad for this proceeding, grafting of bits of conjunctiva from the rabbit is available, and results in benefit. In most of these cases, the loosening of the adherent scar is demanded, for relief of pain and discomfort, without regard to sight. In many others additional operations, chiefly iridectomy, may be needed to gain better vision.

The transplantation of portions of conjunctiva from the rabbit is serviceable in extreme cases, and aided by wearing a glass shell will often, as my own experience has shown, give success. It is also the only available method in attempting to make a conjunctival cavity to permit the insertion of an artificial eye. I have lately seen a boy on whom I operated eleven years ago, when he was twelve years old. The eye was lost and reduced to a stump, and extensive symblepharon existed. It was impossible to wear an artificial eye. In March the adhesions were dissected away and as large a strip as could be taken from the rabbit's eye, inserted. Soon after a very small shell was worn and the size gradually increased. In May following, the operation was repeated, and larger shells employed. In four months longer, a suitable artificial eye could be worn, and now, 1889, he continues to wear it and the conjunctival cavity is capacious and perfectly healthy. Pieces of mucous membrane can be taken from the lower lip and transported.

The skin of the lower lid or of the temple may also be employed, as has been done by Harlan and Snellen (see *Oph. Review*, Dec., 1890). I have lately employed skin grafts of large size (Thiersch's method) with good result for preparing a cavity in which to wear a glass eye. Similar grafts might be used to line the raw surface of a lid when dissected from the globe, stretched in place by sutures, dressed with aristol, and the whole covered with bichloride gauze, 1 to 1,000.

Anchyloblepharon is the adhesion together of the tarsal borders, and is a result of burns and of wounds. It is easily remedied if there be any free spot or hole from which to start in separating the lids. If not, the attempt is useless. One must establish a permanent hole by wearing a metal ring or other method. But such a necessity has never occurred to me. Sometimes the lids are both completely attached to the globe, and also adhere to each other at their margins. For such cases no interference is proper. Such a case is exhibited in the illustration, where complete occlusion was caused by a piece of red-hot iron, both searing and sealing up the eyeball. The same result is sometimes procured when for cancerous disease both the globe and part of the lids must be removed. Under such conditions all of the conjunctiva, both palpebral and bulbar, must be dissected off and the edges of the lids pared. Such an operation was necessary in the case of epithelial disease of the lids which ultimately passed to the eyeball figured on Colored Plate No. VI.

Digitized by Illinois College of Optometry

CHAPTER III.

DISEASES OF THE LACHRYMAL APPARATUS.

Anatomy.—We have to do with the secretory and with the excretory parts of the apparatus. The former, which supplies the tears, consists of a series of small follicles situated in the superior conjunctival cul-de-sac, and the lachrymal gland, while the conjunctiva itself secretes moisture, which may be counted part of the lachrymal fluid.

The lachrymal gland is lodged in a fossa at the upper and outer angle of the orbit, and may be felt by the finger indistinctly under its overhanging rim. It is an acinous gland like the parotid, subdivided into a smaller and a larger lobule, which are separated by a septum of fascia. The smaller is sometimes called an accessory gland. There are numerous isolated acini lying near the principal masses. The size of the chief gland is variable, but may be stated at twenty millimetres in length, eleven to twelve millimetres from before backward (breadth), and five millimetres in thickness. It is concavo-convex, and lies against the periosteum. Numerous ducts, whose orifices are from ten to twelve in number, give exit to the secretion at the temporal side of the superior fornix. The tears contain 1.25 per cent of sodium chloride and 0.5 per cent of albumen.

The excretory apparatus begins as minute openings (the puncta), about six millimetres from the inner angle of the lids, which lead into small canals (canaliculi), and they unite to empty by a common orifice into the side of the lachrymal sac. The sac rises a little above the place of entrance of the canaliculi, and is continuous below with the lachrymo-nasal duct, which empties into the inferior nasal fossa, behind the tip of the inferior turbinated bone. The total length of the sac and duct is about one inch (twenty-five millimetres). Its section is ovoidal, with the long axis from before and outward, backward and inward. Its calibre varies greatly, and its shape may also vary. In the same skull, from which the soft parts have been cleared, I have seen the duct on one side to be round, and not more than three millimetres in diameter, and on the other to be oval in section, with its major axis six millimetres long. The membrane lining the duct and sac is like that of the nostrils,

Digitized by Columbia University

being both a periosteal and a mucous membrane. It is highly vascular, thick, and covered by cylindric epithelium, lying on several layers of spheroidal cells. The cylindric cells are by some declared to be ciliated. Next the bone the membrane is spongy and erectile. It is thrown into folds at two or three points, viz., at the junction of the sac and duct, which corresponds with the beginning of the bony portion of the tube in the ascending process of the superior maxillary bone, and also at the lowermost part, where it communicates with the nostril. There is also, sometimes, a less distinct fold at its middle. The lining membrane of the canaliculi is thin and pale, and the puncta are a little whiter than the neighboring membrane. They point toward and rest in contact with the globe. Muscular fibres surround these openings like sphincters, and they are held in apposition with the eye by the action of the orbicularis and tensor tarsi muscles.

The latter lies behind the lachrymal sac, and the tendon of the former crosses in front of it and is sometimes called the tendo oculi. It is brought into relief by pulling upon the lids at the outer canthus. The orbicularis has additional insertion into the lachrymal bone, by bundles of fibres which go to it directly. The tears are forced into the excretory passages by the action of the muscles just mentioned, aided by a kind of suction caused by the muscular fibres of the puncta and canaliculi (Klein). Unless the puncta are kept in tonic contact with the eye, the tears cannot enter. The quantity of fluid is usually so small that evaporation and secretion balance, and nothing passes down to the nose. With any irritation of the eye, a larger flux occurs, and frequently the capacity of the tubes is overtaxed and tears brim over the lids (epiphora). Usually the follicles in the superior fornix and the conjunctiva furnish all the needed moisture, but on unusual demand the lachrymal gland comes into play.

Diseases of the Lachrymal Gland.

Acute inflammation, dacryo-adenitis, occurs in rare instances. I have in one case seen both glands inflamed at the same time. The symptoms are, swelling, by which the gland is pushed down out of its fossa and can be recognized on turning up the lid; there is œdema of the lid, tenderness of the gland and of the adjacent bony edge, together with dull pain. The amount of swelling can be great, and it is sometimes difficult to exclude periostitis or abscess of the lid. There may be suppuration in the surrounding connective tissue, while often the inflammation resolves without suppuration. The treatment consists in warm fomentations and incision into acute inflammatory swelling. Constitutional treatment is not often

Digitized by Harvard College Library

needed, although the possibility of a syphilitic cause is not to be ignored.

The gland may be the seat of neoplasms, such as sarcoma and other tumors, and of cystoid degeneration, and it is liable to chronic hypertrophy; but these conditions need no special consideration. Its extirpation to cure epiphora was practised by Mr. Lawrence, but is not now approved.

Dislocation of the lachrymal gland came under my notice in a young girl and seemed to be due to slow relaxation of the inclosing capsule. The gland presented itself beneath the ocular conjunctiva over the insertion of the rectus externus muscle and was affected by slight degree of inflammation which was not, however, the cause of the displacement. The opposite eye was phthisical and there too the degenerated and atrophied lachrymal gland had descended below its proper place.

Diseases of the Excretory Apparatus.

We have eversion and stoppage of the puncta, occlusion of the canaliculi, catarrh of the sac, and obstruction of the duct. We also have acute dacryocystitis, chronic distention of the sac, and fistula lachrymalis. Sometimes there are two canaliculi in each lid. Eversion of the puncta is the consequence of chronic blepharitis marginalis or of chronic conjunctivitis, or it follows from paralysis of the orbicularis muscle in lesions of the facial nerve, and necessarily accompanies ectropium. In the first class of cases the orifice is apt to be made smaller; in the paralytic cases the punctum may be uncommonly prominent as a papilla, and while the lower one sags down, the upper also fails to lie upon the globe.

The canaliculi are sometimes the seat of stricture, and in a few cases chalky concretions have been found in them. Leptothrix, one of the microscopic algæ, has been found in them.

Dacryocystitis or *catarrh of the sac and duct* is a lesion not often presented to us at an early stage, because people are apt to avoid the surgeon until the disease has lasted so long that simple catarrh has become complicated with obstruction. There is practically no real distinction to be made between these conditions. In dacryocystitis we have swelling of the mucous membrane, hypertrophy of its epithelium, and papillary growth—sometimes a state precisely like granular conjunctivitis, and with this a muco-purulent, glairy, somewhat tenacious secretion, which fills the cavity and is there retained. The calibre of the nasal portion of the passage speedily becomes choked, and the morbid secretion cannot find outlet; hence, the sac-wall undergoes distention. The three factors of thickening of the mucous membrane, excess of secretion, and dis-

Digitized by Google

tention of the sac, gradually conspire to bring about a more or less aggravated condition, in which the lachrymal tumor becomes larger and the stricture smaller. The skin, after a long period, becomes thin, and may even get to be translucent. It may in very old cases happen, that the lachrymal bone becomes diseased. The constant and annoying effect of this state of things, at almost any period of its existence, whether early or late, is to cause an undue quantity of tears to be formed; they overflow the lid or stand ready to drip over. On exposure to wind or to cold air, the eye waters uncomfortably, and the fluid sweeping over the cornea makes vision misty, and continuous use of the eye is sometimes, and more especially at night, greatly embarrassed. The tears which thus flow too liberally are called forth, it is true, by a hypersecretion of the lachrymal gland; but they are likewise mingled with the products of the irritated conjunctiva and its glands. The universal concomitant of dacryocystitis is palpebral conjunctivitis, sometimes severe, and not infrequently blepharitis marginalis coexists. The caruncle and semilunar fold are swollen and injected, and aid in hindering the entrance of fluid into the puncta. The patient is constantly using his handkerchief, and thus materially aggravates his troubles. But he may learn, and this should be taught by the physician, to keep the sac empty by squeezing its contents into the nose, if the passage be permeable, or the secretion gushes out of the puncta upon the eye. Wherever it goes, keeping the sac empty affords some relief. But when the disease has lasted long, the secretion acquires irritating qualities, especially if it be permitted to stay long unexpelled from the sac. Then its contact with the eye sets up decided conjunctivitis, and the fluid may even have an offensive odor. The fluid then is sticky and unpleasant; especially is it mischievous if the eye is submitted to an operation. The pus has an infectious quality, and is extremely apt to cause suppuration in a corneal wound. The reason of this pernicious quality is the populousness of micro-organisms of many varieties in the secretion. With the exception of the gonococcus none are known to be more hurtful to the tissues of the eye. It follows that cases of cataract, or cases which require iridectomy, should be first relieved from any lachrymal trouble.

The disease is of slow progress, and often for a long time causes little annoyance. Even after a tumor appears at the inner canthus, the swollen sac may not cause great discomfort. But, if it be impracticable to empty it by pressure, the stricture is close and the condition will be both obstinate and troublesome.

A most unpleasant complication in the progress of the disease is the occurrence of acute phlegmonous inflammation and abscess. This is severely painful, and may cause extreme swelling of the

Digitized by Illinois Eye and Ear Infirmary

lids and neighboring parts. The tumor will be red, shiny, and tense. If not large, it will be very tender to the touch, and the conjunctiva will be hyperæmic. It is quite characteristic to find the swelling in the fold of the lower lid and sometimes there is so much infiltration of the skin as to suggest erysipelas. If the process be left to itself, the matter finally escapes by ulceration, and in this case a fistula lachrymalis is quite liable to ensue. The opening will be below the tendon of the orbicular, and may be large or small. (See Fig. 119.)

In cases which have been long neglected, the subjacent bone may become carious, and a passage may even take place into the

FIG. 119.

superior nasal fossa, or into the cells of the ethmoid. In general, the disease will either remain stationary or grow worse—it does not get well. It may be tolerated for years with slight discomfort, or it may prove unpleasantly exasperating. (I have seen one case of congenital lachrymal fistula affecting both eyes. It was reported by Dr. Agnew [1].)

Before entering upon the consideration of treatment, a few words may be given to a condition which causes epiphora, and is apparently not associated with the morbid lesions above described.

I have seen a few patients who were annoyed by an accumulation of tears, in whom I could find no swelling of the sac, nor tenderness over it, nor could I elicit any discharge. At the inner can-

[1] Trans. Am. Oph. Soc., 1874, p. 209.

Digitized by the Michigan College of Optometry

thus there was swelling of the semilunar fold, and turgescence of the caruncle; the puncta were prominent, but not everted nor choked, neither was there obstruction of the canaliculi. The cause of the epiphora seemed to be the swollen state of the caruncle and of adjacent parts; this irritation excited hypersecretion of tears, while the prominence at the canthus served to obstruct entrance of the fluid into the puncta. This rare condition has been noted by Graefe, and I have seen it a few times.

Diagnosis.—We have epiphora and a swelling over the lachrymal sac. The tumor will be effaced by pressure of the finger, and its contents will either flow over the eye through the puncta, or else

FIG. 120.

pass through the nose. If by pressure the tumor do not wholly subside, the sac-wall may be very thick, or the stricture be very tight. If very large and the walls thin, its bluish color may suggest a cyst; but the history of epiphora will settle the doubt. The *caruncle is red* and apt to be swollen, and the puncta also to be swollen and red, and of unusual size. In some very quiescent cases no tumor appears, but pressure will force fluid into the nose. These varieties depend on the duration of the malady, and on the amount of secretion and the degree of obstruction. We sometimes meet cystic or solid tumors of the skin overlying the sac, they will be recognized by the possibility of grasping them with the thumb and finger, or by their mobility and the absence of other signs. A mucocele or chronic abscess of the ethmoid cells sometimes points in the lachrymal region. Its position will be higher than the sac,

Digitized by Illinois College of Optometry

and above the tendon of the orbicularis instead of beneath or behind it (see Fig. 120).

Causes.—The prevalent cause is catarrh of the nasal mucous membrane. This cannot, however, always be discovered. We have frequently the scrofulous diathesis and also frequently constitutional syphilis. A local periostitis at the nasal outlet of the canal may be the starting-point. In most cases the disease is essentially a periostitis and, remembering this characteristic, its special and pertinacious behavior will not be surprising.

Prognosis, as has been intimated, is that recovery will be slow, requiring months. Six weeks would be a satisfactory period—six months not infrequent. Sometimes relief can only be partial, yet it can be absolute and complete. The pathological conditions are so varied that the expectation of cure must be determined by the features of each case.

Treatment.—We have the palliative and curative. A considerable number of persons are not greatly disturbed by their lachrymal trouble; another portion are too timid to submit to surgical proceedings, and others are unwilling to spare the time which effectual treatment demands. For these patients, only palliative proceedings can be used, and they are as follows:

To keep the sac empty by pressing on it with the tip of the finger from above, down, and backward, so as to force the fluid, if possible, into the nose, with firm slow pressure. A certain knack is often acquired by the patient which the physician cannot imitate. If the fluid must be disgorged on the eye, the handkerchief must be in hand to absorb the fluid at once without needless rubbing of the lids, and at all times the eye should be gently pressed, and not wiped. The sac must never be allowed to approach distention.

The use of astringent drops or of a lotion upon the lids, or occasional astringent applications to the palpebral conjunctiva, *e. g.*, Argent. nitrat., gr. ij.–v. ad ℥ i., as this surface may become more congested, will do good service. Moreover, the state of the nasal cavity must be inspected, and duly dealt with. Washing out the nostrils with warm salt water by a syringe, the application of depurating and astringent fluids by an atomizing apparatus, or by the blowing of powders into the nostrils, in the manner called for in the treatment of nasal catarrh, will be well worth doing. Dobell's formula is widely employed.

℞	Sodæ biboratis,	ʒ iv.
	Glycerini,	℥ i.
	Sodæ bicarbonatis,	ʒ ss.
	Acid. carbolici,	ʒ ss.
	Aquæ,	℥ vi.

M.

Digitized by Microsoft®

For powders, among many which may be chosen are the following:

℞ Bismuthi trisnitrat.,
Gum. acaciæ, ... āā ʒ i.
Pulv. cubebæ, ... gr. x.
M.
℞ Acid. boracic. pulv., ... q.s.

Under such management, some persons get along fairly well and are satisfied. Many do nothing more than keep the sac empty, and expect when they get a coryza to have more trouble—and so they do.

The curative treatment involves a careful discrimination of the state of the sac and duct, and the suitable adaptation of means.

If the lachrymal tumor is easily emptied into the nose—and this implies that the case is recent—external applications may suffice. In children of a strumous quality it may be only possible to use probes by giving chloroform, and often the cleansing of the nostrils by a camel's-hair pencil, and the use of cod-liver oil, iodide of iron, etc., will bring about recovery. Carefully wipe out the nostrils with cotton on a holder, and apply vaseline twice daily, and a solution of nitrate of silver, gr. x. ad ʒ i., twice or thrice weekly, or the powdered boracic acid once daily.

But the common run of cases call for treatment of stricture of the nasal duct. Becker uses conical probes with which he stretches the punctum and canaliculus and reaches the duct. The proceeding is painful and permits the introduction of probes of only moderate size, which are inadequate in many instances.

The first step is to slit the canaliculus, which Mr. Bowman taught to be the best mode of approaching the sac. My preference is for the lower one. I also choose a beaked knife, with a blade wider than is generally used (see Fig. 121), attached to a long and stiff, but malleable shank. Sometimes a narrow blade is useful (Agnew). (See Fig. 122.) For a case of no long duration it may be needful to do no more than slit the canaliculus. The surgeon, if operating on the right eye, will stand behind the patient, holding the head against his own body, use the left hand to draw the lower lid out and keep it tight, and insert the beak of the knife perpendicularly into the lower punctum. Sometimes this is partially occluded. The point of a pin or a Bowman's director (see Fig. 123) will usually open it for the tip of the instrument. When well engaged, bring the hand to the horizontal position, and push the blade with cutting edge inclined inward and upward into the sac until the tip is felt to strike the lachrymal bone; keeping the point firmly against the bone, raise the

Digitized by Illinois College of Optometry

handle up, and also lift up the blade so as to incise as freely as possible the conjunctival wall of the sac. Many surgeons stop at this point and let the patient apply cold water, and on the next day attempt to introduce a probe. In the greater number of cases I do

FIG. 121.

FIG. 122.

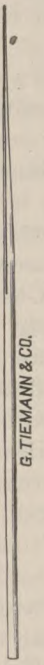

FIG. 123.

FIG. 124.

FIG. 125.

FIG. 126.



FIG. 127.

not follow this mode of proceeding, but at the first operation carry the knife down into the nasal duct and divide the stricture. I make two or three incisions upon different sides of the duct, to gain the greatest enlargement. Blood issuing from the nostrils is proof that the passage has been opened. When the stricture is divided,

Digitized by Illinois College of Optometry

as Stilling recommended, a large instrument should be inserted, viz., the larger end of Weber's conical probe (see Fig. 124), and afterward the probes of large sizes. Cases must be dealt with according to the calibre which is normal to each, and the fullest possible expansion obtained. The first operation may perhaps be done under an anæsthetic, and often two or three days will elapse before another introduction of a probe. Meanwhile the canaliculus must not be allowed to close. The introduction of probes is always painful and cocaine does not serve any useful purpose, no matter in what method employed. Usually the proceeding is less painful as the cure progresses.

The probe may be used three times weekly, and be left in place from ten to thirty minutes. Progress can, in some cases, be made rapidly; others will permit only a gradual increase. The amount of reaction after probing will regulate the frequency of introduction and the rate of enlargement. In passing the probe carry it horizontally into the sac, and when its point impinges on the bony wall, bring it to a perpendicular and attempt to follow the axis of the duct. The direction is downward, outward, and backward, toward the wing of the nostril. The aim must be to get behind the edge of the opening into the superior maxilla, and until this is gained the probe must be handled with delicacy, and in the exercise of a nice sense of touch. Caution at this point is indispensable, and a moderate degree of it will avoid making a false passage. After this opening is gained, the probe may be firmly sent down until it reaches the nasal fossa. It should be left in place for ten minutes, and then withdrawn. This exploration will indicate what kind of stricture we have in hand, and what instrument will best dilate it.

I have, during many years, made use of Theobald's probes (Fig. 125), and find them exceedingly satisfactory. They go up to large sizes, No. 16 being the maximum. Dr. T. has advocated the use of large probes in a paper in *Arch. of Ophth.*, vi., and in Trans. Am. Oph. Soc., 1879, and was not aware that Dr. E. Williams, of Cincinnati, myself, and others had, for many years, sought to secure the fullest dilation which the anatomical and pathological conditions make possible. Dr. H. W. Williams, of Boston, has introduced probes with bulbous tips and elastic necks (Fig. 126) which, while stiff enough to handle easily, find their way around projecting obstacles or through sinuous passages better than straight instruments. I have often had occasion to be pleased with their qualities. But my ultimate resort is to a large instrument, smooth, with conical point, which must press its way through the inflammatory deposit—not with violence, but with some force; and this is to be left *in situ* from ten to thirty minutes, but not long if its pressure be extremely

painful. Making haste slowly is the password to success with these cases, but I am convinced that the gate must be opened widely and made to stay open, to get full relief. Dr. Theobald's probes are of the following sizes: beginning with the diameter of one quarter of a millimetre, advancing by increase in diameter of one-quarter of a millimetre from No. 1 to 16, the last being four millimetres in diameter. I have found them so well contrived that I have adopted them almost to the exclusion of all others. The largest sizes are now made of aluminum with the advantage of lightness and greater smoothness.

As the result of probing, abatement of the catarrhal secretion is soon manifest. In most case, nothing more than probing and treatment of palpebral conjunctivitis is needful. In a certain number, secretion is copious, and does not measurably diminish. The syringe must then be employed with salt and water 2% or with a weak solution of argent. nitratis, gr. v. ad ℥ i., or gr. x. ad ℥ i. Perforated probes have been devised for this object, but a small, hard-rubber dental syringe can be readily adapted to the purpose by bending its nozzle in hot water to an obtuse angle. After the probe has been withdrawn, the syringe may be used. It will not require protracted employment.

In cases where persons cannot spend the weeks or months with the surgeon which treatment requires, the plan may be adopted of putting in a leaden wire, about size No. 6 or 4 Bowman, which shall lie in the duct with its upper end properly bent downward and inward at the inner canthus. This style may be worn as in old times Scarpa's nail was worn, for two months, more or less, and it will then be found to have brought about absorption of the stricture. It excites considerable secretion, is not agreeable to wear, but answers fairly well. Granulations are liable to spring up at the entrance into the sac, and when the style is taken out, the opening soon contracts and is difficult to find.

I have another suggestion to make in this matter. Some cases permit dilatation of the stricture with reasonable rapidity and to a satisfactory degree, but the annoying epiphora does not stop, and the patient does not find the pain of the treatment compensated by good results. It must be remembered that there may be another stricture at the bottom of the duct where it enters the nose. Here I have many times found a nodular projection from the side of the canal, or a decided narrowing of its calibre. To overcome this stricture the common probe is futile. I have had a form made which is a repetition of a very old instrument, with a bulbous tip and of unusual length (see Fig. 127). It is carried down to the lower end of the canal in the ordinary way, and then, to get it into the nose, the flat handle must be rotated toward the temple so as to turn the

Digitized by Google

point backward, and then push it onward. It will go down almost an inch farther, and it may so far penetrate the nostril as to touch the place of junction of the hard and soft palate. Some obstinate cases of epiphora have been cured by ascertaining the presence of this hidden stricture, and resorting to the instrument thus described. In cases where the obstruction at the bottom is osteoid, I have used a narrow gouge with a cutting end, and have bored a way into the nose (see Fig. 128). Afterward steady probing is needed to prevent the return of the obstruction.

I have found Theobald's probes frequently able to cope with the cases just cited, because of their well-fashioned tips and greater length. But they deserve special notice, and the probe I have devised will sometimes be necessary.

There remains another class of cases in which the passage cannot be restored to its normal state: either because of excessive

FIG. 128.

thickening of the lachrymal sac, or the duct is almost occluded by osteoid growth, and is practically impermeable, or there may be caries. The older writers proposed opening into the nasal fossa by perforating the lachrymal bone. The modern treatment is the obliteration of the lachrymal sac and duct. This is done by dissecting out the hypertrophied sac, or by destroying it either by the actual or potential cautery. Excision of the sac may be combined with the cautery. After dissecting out with scissors as much of the sac as can be removed, the Paquelin cautery is thrust into the duct. Usually, fuming nitric acid is the agent employed. The sac is freely exposed by an incision in the skin, and when the bleeding stops, a bit of wood—the untipped end of a match—with some fibres of cotton on it, is charged with it and freely applied to the mucous surface. Care must be taken to protect the eye, and the edges of the wound must be held asunder by sharp hooks. This operation has been done by Dr. Agnew through an incision upon the mucous side of the sac, with simultaneous division of the canaliculi, and he reports good results. I have not followed his method; and although, as commonly performed, a scar is left upon the skin, I have not found it a conspicuous thing or a deformity. Still another mode of destroying the sac is by putting into it pieces of nitrate of silver. They cause prolonged pain, and are less effectual

than the Paquelin or the nitric acid. After cauterization the sac is stuffed with lint, and cold water dressings applied. It will take two or three weeks for the wound to close by granulation. When the cavity is obliterated, the success which follows in relieving the epiphora, depends on the fact that there is no longer an irritation in the sac to stimulate a superabundant flow. The obstruction of the excretory passage causes no inconvenience, except when some special occasion for weeping arises, such as keen winds or mental emotion. In fact, however, it is not easy to perfectly obliterate the sac and duct, and hence this treatment does not give uniform results; but it is a great amelioration of the previous condition. In very young children a probe may be passed by the help of chloroform. I have seen lachrymal abscess with stricture, on both sides, in a child six months old, and treated it successfully by the usual method. I have sometimes instructed a patient to use the probe for himself, when he had reached the proper size, and simply needed to maintain the enlargement.

Added to the above suggestions for local treatment, the possibility of syphilitic infection must be borne in mind and the suitable medical treatment adopted. In late tertiary forms I have found this condition. The iodide of potassium and corrosive sublimate will do the same service as in any case of specific periosteal inflammation. In all cases where nasal catarrh shows decided symptoms, this must receive attention.

Phlegmonous Inflammation of the Lachrymal Sac.

This takes place as an incident during the progress of a chronic dacryocystitis. The attack is always painful, may be ushered in by a chill, and varies greatly in severity. Swelling, tenderness, and hardening of the sac are always present, while sometimes the lids become puffy, especially the lower lid along the furrow which lies below it and in a few cases the œdema of surrounding parts has simulated severe orbital cellulitis. Even though the swelling be small and circumscribed, the patient commonly suffers much pain, and the reason is the same as in the case of any subperiosteal inflammation, viz., the effusions are compressed by dense membranes and the nerves are numerous.

Treatment.—It is rarely of any use to do anything else than to make an incision into the sac. If the case be seen early, this may be done by way of the canaliculus and slitting freely the sides of the sac, thus preparing for the probe at a future period, when treatment of the original stricture shall be in order. But if much swelling have taken place, the knife should be put perpendicularly upon the skin over the middle of the sac and thrust through it to

Digitized by Illinois College of Optometry

the bone, and then with one sweep carry the incision down for half an inch, more or less, according to the extent of the tumor. The best surgery is an early and a free incision. By doing this the occurrence of fistula is almost certain to be avoided, while it is very likely to be the disagreeable consequence of permitting the abscess to "break of itself." After opening the abscess, warm water dressings and poultices will be applied until the attack subsides. The cut will be kept open by a bit of lint.

It is not denied that sometimes, when phlegmonous inflammation begins, resolution may occur and this is best promoted by the continuous use of hot poultices, of which the ground slippery elm bark is the most eligible.

Lachrymal fistula is occasioned by the imperfect healing of an abscess, and implies the existence of a permanent stricture. This

FIG. 129.

lesion is not seen as frequently as once it was, nor do lachrymal diseases often attain the extremity which the older writers describe.

Surgical aid is better and more ready to be instituted than in the older day. Hence, a bad case of caries or of fistula does not often get an opportunity for development. It is needless to describe the condition—it declares itself; and if dead bone be present, the probe will soon discover it, if the foul odor and discharge do not betray it. Fig. 129 shows a case of lachrymal abscess and fistula during the regressive period. The fistulous opening afterward

Digitized by Illinois College of Optometry

closed spontaneously, while the stricture was at a later period divided and treated by probes.

For a bad case, cleansing by the syringe through the fistula may sometimes be proper, together with attempts to restore the calibre of the duct. If there be dead bone, this may be left to gradual elimination or be removed by a small gouge. For such cases destruction of the sac will generally be a necessity. In general, it is better for the great majority, to slit the canaliculus and deal with them as if there were no fistula. So soon as a route can be established for the secretions to make their way into the nostril, the fistula will heal. In case it prove sluggish, the process of closure may be hastened by stimulating it with a pointed crayon of nitrate of silver (Squibb's caustic points). Cure of the stricture carries with it cure of the fistula. If the stricture be incurable, the obliteration of the sac is the alternative, in the manner above described.

It may be remarked, in summing up the whole matter of lachrymal troubles, that the larger number may be completely cured, another proportion are relieved of special annoyance, and the remainder gain some benefit, but still have trouble. That a perfect cure should always ensue, it would be unreasonable to expect; that palliation is better than no relief, is evident, while patient continuance and careful discrimination of the precise lesion, are indispensable to success. Moreover, in no cases more than these, is the tactile address of the surgeon an element of value to win confidence and spare needless pain, and thereby contribute to success.

A case reported by Dr. Bull (*Am. Jour. Med. Sci.*, July, 1880) is worth remembering, where caries of the ethmoid bone caused a pre-lachrymal abscess, and on opening it the lachrymal sac was not involved, nor its cavity entered. In such cases there will be no epiphora. Treatment will simply be to provide for the escape of the discharge by washing out the cavity with antiseptic and slightly stimulating solutions.

Leptothrix lachrymalis sometimes makes its home in the canaliculi, especially in the inferior. The symptoms are slight inflammation and swelling about the punctum, suggesting a stye, and at the orifice a stringy mucoidal pus presents and can be squeezed out. There is swelling of the caruncle and semilunar fold and persistent annoying "angular" conjunctivitis. The somewhat tenacious secretion can be seen issuing from the puncta spontaneously; the apertures will be widely open and a sucking or pumping motion may perhaps be noticed. The secretion collects in flakes and small masses and beginning at the inner angle spreads over all the inferior cul-de-sac. While on the one hand the mistake may be made of regarding the condition as simply a hordeolum, on the other the case may be considered a mild dacryocystitis. There will be no dis-

Digitized by Illinois College of Optometry

tention of the sac, and the chronic character of the trouble excludes the diagnosis of a stye. The condition is somewhat rare, but occasionally appears. A very precise and ample description of it was given by Von Graefe[1] in 1854, and again in 1855. By pressure a slimy yellow substance is brought out, but the swelling may not entirely disappear, because a number of small calcareous granules may remain. Microscopical examination shows a bacillary micro-organism, a fungus with jointed threads and spores, akin to the leptothrix buccalis which is found on the tartar of teeth and has the property of secreting lime salts. See Foster's "Encyclopædic Medical Dictionary," Vol. III., 1892. Treatment consists in slitting the canaliculus to expose the cavity, emptying it, and applying a solution of nitrate of silver gr. v.–x. ad ℥ i. for a day or two, and using a weak antiseptic solution as a lotion. So soon as the fungous character of the trouble is perceived, treatment will be readily understood. A point to be noted is that only one eye is affected.

Excessive lachrymation is caused sometimes by undue secretion of tears unassociated with disease of the excretory apparatus. This is by far more rare than the conditions above described. The epiphora is not constant, but appears when cold winds or similar irritation stimulates great conjunctival secretion. It may give no annoyance in summer or within the house, and be extremely troublesome when facing a cold wintry wind. There may not be very marked congestion of the ocular or of the tarsal conjunctiva. There will be no swelling of the caruncle as uniformly attends catarrh of the sac, nor pouting of the puncta, nor can any fluid be expressed from the sac. The sedative effect of cocaine temporarily stops the annoyance, and if the upper lid be everted so far as the cul-de-sac (sometimes needing a forceps for the purpose and the aid of cocaine) a band of swollen conjunctiva will be found in or near the fornix betraying the enlarged and irritated glands of Krause, the isolated lachrymal follicles which are the source of the hypersecretion. Diagnosis is included in the above description, and treatment consists in applying solution argent. nitrat. gr. v. ad ℥ i. to the site of the trouble twice weekly, or perhaps the more heroic method of slight touching with the actual cautery (Paquelin or a small galvano-cautery) will be admissible and more prompt. Nasal catarrh must be duly remembered. Extirpation of the lachrymal gland is scarcely to be thought of, although it was once practised by Mr. Laurence. This gland is not the source of the trouble, but the smaller ones referred to in the fornix.

[1] Graefe, Archiv f. Ophthal., Bd. 1, Abth. 1, S. 284, also Bd. ii., Abth. 1, S. 224.

Digitized by the Internet Archive

CHAPTER IV.

THE CONJUNCTIVA.

Anatomy and Physiology.—The membrane presents for consideration its tarsal portion, the fornix or sinus, and the ocular portion. The tarsal or palpebral part is closely and smoothly adherent to the tarsi, and permits the Meibomian follicles to be seen through it. It has a faintly yellow color and a few vessels. The fornix, or sinus, or cul-de-sac, or fold of transition, is very loosely attached to the parts beneath, and slips freely back and forth; it has numerous folds, is of a turgid dark color, and has many glands. The depth of the fornix varies according to age and individual peculiarities. Sometimes the whole of the superior fornix can be exposed to view, by everting the lid, and often no effort will display it. The inferior fornix can always be fully seen. The ocular conjunctiva lies smoothly upon the globe, but is loosely attached, and can be moved back and forth by pulling upon the lids. At the outer canthus the conjunctival sinus is deep, especially toward the lachrymal gland; at the inner canthus, on the contrary, the sinus, or fornix, is shallow both above and below. At the inner end of the palpebral slit we have the congeries of glandular follicles, called the caruncle, and between it and the margin of the cornea is a slight fold of the membrane running nearly vertically, yet somewhat crescentic, called the plica semilunaris. It is bound rather firmly to the parts beneath, and is the analogue of the third eyelid of some animals, and in them it often contains a plate of cartilage.

The *caruncula lachrymalis* is an isolated and modified portion of skin tissue covered by epithelium, containing fine hairs with their tributary follicles, and modified sweat glands resembling the glands of Moll. It also contains connective tissue and a little adipose substance; it is dense and firm and of a pale red color. Both it and the semilunar fold are connected by fibrous tissue to the subjacent structures and in the movement of the eyeball inward, they are drawn inward with the action of the rectus internus muscle. This relation is too often made unpleasantly obvious by the sinking which occurs after tenotomy for converging strabismus.

The different portions of the conjunctiva vary in structure. The tarsal part seems on casual inspection to be perfectly smooth, but

Digitized by the Internet Archive

closely examined, it is found to have a slightly velvety surface, and this is produced by numerous fine grooves and pits which reticulate irregularly, and constitute so-called papillæ. The papillæ are larger near the orbital edge of each tarsus. Their distribution is quite irregular. They are covered by epithelium whose superficial layer is cylindric and the deep layer flat. As the epithelium goes into the depressions between the papillæ, it is in several layers and distinctly cylindric. These depressions are irregular and complex in form. There is a layer of fibrous tissue beneath it, rich in elastic fibres and closely adherent to the substance of the tarsus. In the meshes of the fibres is diffuse lymphoid (adenoid) infiltration which grows more abundant toward the orbital portion. Lymphoid tissue is gathered into distinct masses (Henle) and called lymphoid follicles, and is normal in many domestic animals, and whether their occurrence in man is to be counted normal or pathological is a subject of dispute. It is admitted that they do not appear in the young. That they may, when in moderate quantity, be considered normal in man, seems to be the best opinion. This question has a bearing upon the pathology of trachoma. When the grooves and furrows of the tarsal conjunctiva are very deep and intricate, they form crypts and follicles lined by epithelium and may thus take on the appearance of glands. If their orifices at the free surface become occluded, they may resemble ductless glands. In young subjects the reticulations and furrows do not exist.

The orbital part of the conjunctiva, the sinus or fornix, is loose and plicated, and both variable in extent and imperfectly defined in limits, except at the tarsal side. Its tunica propria contains abundance of elastic fibres. Its epithelium is in many layers, the surface cells are cylindric, those beneath are rounded and there are very few of the depressions described as present on the tarsal portion. The only glands are the acino-tubular of Krause near the upper edge of the tarsi, and there is no lymphoid or adenoid substance. There is an abundant and loose submucous tissue.

The ocular part of the conjunctiva has a flat epithelium in numerous layers and in this respect resembles that of the cornea. The tunica propria has no papillæ and contains among its fibres many leucocytes. At the margin of the cornea the conjunctiva becomes closely united to the subjacent structure and its epithelium is more dense. This part is known as the *limbus corneæ*, and it is about 2 mm. wide, but varies. The sub-conjunctival connective tissue is loose and elastic, although the membrane is held smoothly in place, and especially by fibres which run into it from the insertions of the recti muscles.

The blood-vessels are very numerous in the region of the limbus,

Digitized by the Internet Archive

about the caruncle, and in portions of the tarsal conjunctiva, especially at the outer and inner angles. The large veins of the ocular portion are to be noticed, especially those which go to the muscular twigs and empty into the ciliary body.

The sensitive nerves of the conjunctiva are numerous, and come from the fifth pair. They form a special meshwork about the limbus, and in the tarsal portion special tactile bodies have been described by Krause. For this reason the presence of a foreign body beneath the lid is so intolerable, and reflex action between the orbicularis and the conjunctiva so prompt.

The function of the conjunctiva is to act as a lubricating surface and in this it resembles the serous membranes. The fluid for ordinary needs comes by transudation from its vessels and glands and no demand is made upon the lachrymal gland except under special circumstances.

The eversion of the upper lid may be most easily effected in the following way: The patient sits facing the operator, holds his head erect and looks at his lap, or the floor. Place the left thumb on the brow with its tip at the upper edge of the tarsus, while the other fingers rest on the forehead: gently press down the skin and with the other hand seize the border of the lid and bend it over the thumb nail as one would fold a piece of paper. When a patient offers no resistance one may turn the lid readily upon a pencil or a probe laid transversely across its orbital portion, but the thumb gives aid in forcing down the brow and skin and after eversion helps to extrude the fornix to view. A fuller exposure of the fornix is gained by pressing the eyeball backward through the lower lid as the cornea turns down and the eversion is maintained. As the globe is pushed backward the folds evert beautifully. If the lid be very short or swollen, or the patient rebellious, place one thumb at the upper edge of the tarsus, cover the tip of the other with a bit of muslin and pressing against the lid border push it up and over—one thumb aids the other. The muslin prevents slipping and the upper thumb catches the tarsal edge. For young children who make great resistance, lay them on the back in the mother's lap with the head between the operator's knees. Use the point of the forefinger as a fulcrum and with the other pull the lid over it. A bit of muslin will often be of service. It may be necessary to use an anæsthetic. Eversion of the inferior cul-de-sac is usually easy, but its complete exposure is secured by first having the patient look far down, then with the finger depress the tarsal edge and finally bid the patient look up—the cul-de-sac at once rolls out.

Diseases of the Conjunctiva.

According to Cohn's tables, 30% of the diseases of the eye are furnished by the conjunctiva, and of these almost all are inflamma-

Digitized by Illinois College of Optometry

tory. The phases of conjunctivitis are various, and numerous subdivisions can be made according to the principles used in classification. It is better to do this so far as possible according to the pathological types presented. The general features of conjunctivitis (*syndesmitis*) are redness, œdematous swelling both in and beneath the membrane, increase of secretion, which will consist of tears, serum, mucus, cast-off epithelium, and a greater or less amount of pus cells; there may be coagulable exudation upon or in the membrane; the lymphoid elements will be increased both in size and quantity, the papillary structure may be hypertrophied.

It may be said that congestion and undue and abnormal secretion always exist in this inflammation and on the latter characteristic particular stress must be laid. It is also to be emphasized, that in general the secretions of conjunctivitis are contagious. For the milder forms this is measurably true, while in acute and florid types the contagiousness is extreme and the effect liable to be severe. In certain cases, viz., in most of the purulent and plastic types, the contagious element is a micrococcus of a distinct character. Communicability resides not only in the secretions, but in some forms, seems to pervade the atmosphere, giving rise to endemic inflammations in asylums, homes, and hospitals, and in them the disease is prone to exhibit or degenerate into various pathological phases grouped under the name of granular conjunctivitis.

We may make the following subdivisions: 1st hyperæmia of the conjunctiva; 2d, conjunc. simplex or catarrhalis; 3d, conj. purulenta or blennorrhoica; 4th, conj. crouposa; 5th, conj. diphtheritica; 6th, conj. granulosa; 7th, conj. phlyctenulosa. To these inflammatory types we add, 8th, xeroma; 9th, lymphangiomata; 10th, hemorrhage; 11th, wounds and burns; 12th, tumors and ulcerations; 13th, subconjunctival emphysema.

Conjunctivitis.

1st. *Hyperæmia palpebralis* is frequent, may be acute or chronic, and is usually symptomatic. Mere hyperæmia of the ocular part of the membrane is rare and apt to be traumatic. Yet there are persons who get a mild attack of this sort for which they apply a cold compress at night and find their eyes quite well in the morning. They are usually affected with nasal catarrh. Hyperæmia of the tarsal conjunctiva is not seldom incorrectly called granular conjunctivitis, because the surface may be slightly more velvety than usual. The outer and inner angles always show the deepest congestion, while along the middle of the tarsus the vessels, both the large and fine, give a decidedly pink hue to the usually yellowish-pink surface. There is commonly only a trifling increase of secretion, almost no increase of thickness, and the papillary struc-

Digitized by the Internet Archive College of Physicians

ture is developed no more than may be compared to the surface of fine emery paper, and the transparency is not lost. Complaint is made of dryness, of smarting, pricking, or gritty sensations: perhaps the lids cannot be kept fully open, there may be some photophobia. The symptoms are worse at night and are aggravated by use of the eyes. The most annoying cases of this kind are those which are caused by various forms of eye strain. Whatever makes vision difficult, excites this hyperæmia. We see it in those who use their eyes to excess, for long hours, or late at night, in those who have wept extremely; in those who have errors of refraction, such as beginning myopia, or hyperopia, or astigmatism, or anisometropia or spasm of accommodation, or beginning presbyopia; in those who suffer from fatigue of the motor muscles (muscular asthenopia in various types). We see it with faint opacity of the middle of the cornea, with incipient cataract, or diffused haziness of the vitreous. It accompanies chronic ophthalmia tarsi, which is itself often occasioned by refractive or muscular errors. It is often coincident with chronic nasal catarrh, and if this develop at times into acute activity as "hay fever" or "rose cold," etc., the palpebral hyperæmia correspondingly increases and may grow to active conjunctivitis. Those who work in dust, such as millers or street sweepers, etc., naturally have this condition, and it always attends the lodgment of a foreign body under the lid. There is a chronic type of the disease found chiefly in old persons whose eyelids are baggy and who may have ectropium. It always co-exists with catarrh of the lachrymal sac and stricture of the nasal duct. Among all these subjects those who complain most will be the asthenopic persons, and the more excitable they are, the more will they emphasize their troubles.

Treatment.—The important point is to ascertain and remove the cause. It may disappear upon receiving suitable glasses for refractive or muscular errors, upon the removal of a foreign body, upon the subsidence of a stye, the removal of a cyst of the tarsus, or the cure of nasal catarrh. Concurrently with the proceedings hinted at, direct remedies may be called for which will be both soothing and mildly stimulating. Weak solutions of common salt, half a teaspoonful in a pint of water, the addition of a few drops of brandy to a tumbler of water, or as the fashion now is, of "Pond's extract" (fl. extr. hamamelis) in quantity varying from a few drops to a teaspoonful in a glass of water, are in popular use. The cold douche from a fine rose jet arranged as may be convenient, or spray of cold water from a double-bulb spray apparatus, are often grateful and to it the addition of a few drops of bay rum gives more efficacy. Some of the usual prescriptions are as follows: ℞ Sodæ biboratis pulv., ʒ i.; aquæ camph., ℥ vi. ℞ Acidi borici, ʒ i.;

Digitized by Illinois College of Optometry

aquæ, ℥ vi. ℞ Zinci sulph., gr. ij.; aquæ, ℥ iv. ℞ Fl. ext. opii., ʒ ij.; aquæ, ℥ iv. These mixtures are to be dropped between the lids by a dropper or may be put into an eye cup which is to be held to the eye and the lids being opened, the fluid remains for half a minute or more in contact with the globe. Afterward it may be applied by a compress to the outer surface of the lids for ten minutes. Such applications are made morning and evening, or at such times as the patient prefers.

If such measures do not remove the irritation, applications directly to the tarsal surface will be in order, and the surgeon must evert the lids. For this purpose a solution of nitrate of silver, gr. ss.–ij. to water ℥ i. or in chronic cases, tannin, gr. x., glycerin, ℥ i., or a smooth crystal of alum may be empoyed every second or third day. It is sometimes useful to apply to the tarsal border at night a weak mercurial ointment, such as, ℞ hydrarg. oxid. flav., gr. ij.; vaselini, ʒ i.; or ℞ Unguenti citrini, gr. ij.; vaselini, ʒ i.; vel cosmolini, ʒ i., in lieu of the "touching" of the lids and often in connection with some of the above-named collyria. The mixture of borax and camphor water is most frequent and is widely known. Solution of tannin in glycerin, gr. xx. ad ℥ i., may be applied by a spray apparatus (Agnew).

2. *Conjunctivitis simplex vel catarrhalis.*—It is necessary to allow considerable latitude to the definition of this inflammation, because we meet it in various degree and phases. One might make of it three subdivisions, viz., C. Simplex, C. Œdematosa and C. Catarrhalis. The first is attended by little swelling and presents chiefly hyperæmia. The second is not frequent and exhibits little redness, but abundant serous effusion in and beneath the conjunctiva and in the lids. It occurs in young subjects of delicate and lymphatic habit, is not much painful and there is little sticky secretion. The membrane shows little vascularity and the prevailing tone of color is a tawny yellow. This occurs idiopathically, while precisely similar conditions accompany some cases of periostitis and other orbital inflammations. The third is the typical and usual form of catarrhal conjunctivitis and has the following appearances. Increase of vascularity both palpebral and ocular; on the globe the mesh-work of vessels forms close and irregular spaces and is somewhat closer near the cornea, the hyperæmia is nearly equal in intensity over all parts of the eye. There will be more or less effusion in and beneath the membrane, and pressure with the finger through the lid will move it about. There will be swelling of the lids and inability to fully open them, and some redness along their margins. But the striking and special symptom is the abnormal secretion which glues the lashes into bundles and the edges of the lids together after sleep, which is flocculent and turbid, a mixture

Digitized by Google Original from University

of serum, tears, mucous epithelium and of some pus-cells. It collects in flakes and spreads in a thin layer upon the tarsal surfaces. When everted, the palpebral surface is deeply and uniformly red, succulent, and velvety. At the edge of the cornea there are often minute erosions and a fringe of vessels may after a time develop around its whole circumference and reach one or two millimetres into the transparent cornea. Sometimes there are minute hemorrhages in the ocular conjunctiva and the color of the hyperæmia varies from a bright scarlet to a deep mahogany.

The subjective symptoms vary according to the severity of the attack and the sensitiveness of the patient. There is heat, and burning pain, with pricking and itching and the constant sense of heaviness and of sand in the eyes. At the outer and inner angles these feelings are most pronounced and often the skin after a time becomes ulcerated at these sites, to the aggravation of the sensations. The flow of scalding tears and the persistent collection of the secretion provokes constant use of a handkerchief and there is often marked photophobia. The symptoms are apt to be worse at night and better in the morning. Usually both eyes are affected.

A form of this inflammation called by English writers *catarrho-rheumatic ophthalmia* seems to be a mixture of conjunctival and scleral inflammation. The secretion is more watery than sticky, there is a deep as well as superficial vascularity, and then there is acute pain in the globe, the temples, and forehead, added to the usual burning sensations. The eyeballs are tender to the touch, there is usually extreme photophobia and the sufferings of the patient are out of proportion to the apparent severity of the disease. Such persons are apt to be gouty or rheumatic.

Many times there is little discomfort experienced with catarrhal conjunctivitis, and especally in healthy persons, and frequently the services of a physician are not called for.

The disease is idiopathic or symptomatic and in a few cases it seems to be metastatic. It comes from atmospheric causes, from the foul air of ill-ventilated rooms, from exposure to dust, smoke and heat. It is apt to occur at the seaside in the summer, from heat, glare, and dampness. Workers at the forge, millers, cigar-makers, moulders are its especial subjects. It is frequent in orphan asylums and crowded eleemosynary establishments. It is often part of the attack in acute coryza and in hay-fever or rose cold. Sometimes epidemics occur and are thought to be more frequent in the spring and autumn.

A special type of acute conjunctivitis, usually called papillary, sometimes follicular, both which names indicate the differing phases set up by the same cause, comes in certain persons from a solution of sulphate of atropia. (Note previous remarks, p. 240.) With a

Digitized by Illinois College of Optometry

few who are remarkably susceptible a single instillation suffices. Generally it must have been kept up for some time before this result appears. There is often erythematous inflammation of the skin of the lid and of the cheek. The conjunctiva will exhibit besides redness and hypersecretion, enlargement of the follicles in the tarsal folds. The attack promptly abates on withdrawal of the atropia.

Furthermore we have epidemics of catarrhal conjunctivitis, usually of mild type with moderate quantity of secretion from the eyes and attended by coryza. The attack lasts usually from three to ten days and may be widespread in the community. It is popularly known as "pink eye" and evidently resembles the "distemper" of horses and other animals. Dr. John E. Weeks has studied its micrography and found it to be a germ disease communicable by contagion. He has isolated its special bacillus in pure cultures.[1]

We have mild conjunctivitis during extreme summer heat, especially if combined with exposure to the sand of the desert, or the beach, or the arid dust of the plains. It happens to travellers among arctic snows. Facing the glare of the electric light will produce it: if the light is properly diffused no harm results.

The *symptomatic* or *secondary* forms of the disease are numerous, as in dacryocystitis, acute and chronic, in hordeolum and abscess of the lid, in erysipelas, in eczema, in herpes zoster frontalis, in all the exanthemata, as measles, scarlatina, variola, and varicella. It is a serious and most annoying complication in acute eczema of the face, especially in old persons, and is utterly rebellious until the subsidence of the skin disease. It is an early token in measles, while in scarlet fever it comes during the later stages of the eruption, and similarly with small-pox.

Certain fugitive attacks in cases of gonorrhœa (Haltenhoff) seem to be *metastatic*, expressly excluding their production by the conveyance of secretion, and this opinion is founded upon the nature of the attack, its mildness, its short duration, the absence of the purulent secretion, and (of obviously less value as evidence) upon the negation by the patient of any carelessness on his own part. There may be coincident inflammation of the joints (gonorrheal). Such occurrences are rare. Cases have been observed in which a mild conjunctivitis has preceded each menstruation. Dr. W. O. Moore related such a case to the New York Ophthalmological Society.

Duration, Complications, and Sequelæ.—There is a notable tendency to spontaneous recovery, and the duration of the disease will be from a few days to three weeks. If, however, the surroundings be unfavorable, or if no care be taken or the person be cachectic or of bad habits, it may become a chronic malady. This is apt to

[1] Knapp, Arch. of Ophth., xv., p. 441, 1886.

Digitized by the University of Illinois College of Ophthalmology

be the case among tenement houses, and in badly managed institutions, where a seemingly mild attack refuses to get well, and passes over into a state of thickening and infiltration of the tarsal and orbital portions of the membrane, with hypertrophy of the papillæ and of the epithelium; a condition conveniently called granular conjunctivitis, and it is extremely obstinate although it may not seem to be severe. Again a simple attack in old persons is apt to degenerate into a chronic condition, and hard drinkers have been noted since the time of Solomon for "redness of eyes." It is rare that the cornea becomes affected, save in the moderate way above denoted. After measles the eyes are liable to remain irritable for a long period, and while no vigorous treatment seems needful, care in abstaining from use is required. It is generally true that the eyes are apt to be irritable for several weeks, even when a case has seemed to recover well. The possibility of granular conjunctivitis ensuing under special conditions has been mentioned and it is also possible for persons who give no attention to cleanliness, especially if aged, to have chronic blepharitis, lippitudo and ectropium, and perhaps impairment of the integrity of the cornea.

Treatment.—The first and chief consideration is scrupulous cleanliness, and where an endemic has broken out in an institution, the removal of the affected into large and well-ventilated rooms, and giving each abundant air space. Simple cleansing of the eye from all secretion by mild lotions is often all that is required. The first question always is, what should be the temperature of the fluid? That may be left to the sensations of the patient, whether it shall be lukewarm or cool, but as to the mode of application instruction must be given that it shall remove the secretion and not retain it within the lids. Hence, poultices, tight compresses, bandages, raw oysters and a farrago of disgusting popular remedies must be prohibited. It is also prudent to discard sponges, because they are apt to become means of contagion. A simple compress of linen or muslin, or a pad of absorbent cotton wetted in the fluid, may be applied for fifteen minutes or more at intervals of one or more hours according to the seriousness of the case. It should be wetted afresh every three or five minutes and the secretion gently wiped away from the edges of the lids. The purpose is to keep the eye clean, to remove and antagonize septic elements and to exert by the lotion a moderate control over inflammatory action. For mild cases a cool lotion, for more severe a cold lotion will be chosen. Nothing serves so well in the great majority of cases as a 3% solution of boric acid. It need not be accurately prepared, but the patient may be told to put a teaspoonful of the crystallized acid in half a pint of water and use it copiously. If the amount of secretion require, it may be squirted between the lids by a dropping tube or a small bulb. It is

Digitized by the Internet Archive

grateful to the inflamed surface and is of undoubted value. For a very large number of cases it fully meets the purpose and it has grown to be the stock prescription in the practice of the New York Eye and Ear Infirmary. It must not be forgotten that in all mild cases of conjunctivitis the diseased condition is of short duration, and that amid healthy surroundings a complete and prompt recovery is the natural order of events. Many persons prescribe for themselves weak sulphate of zinc solution dropped in the eyes at night. We therefore will carefully avoid unnecessary treatment, and especially any strenuous or harsh measures, which while they exhibit zeal, are in reality evidence of indiscretion. Under this category may be put leeches and blisters and the use of irritating "drops," etc. The treatment will be aimed at the uncomfortable symptoms. Under this head may be classed the cleansing of the eye, as has already been stated: before going to sleep the edges of the lids may be smeared with simple cerate, or unperfumed cold-cream, or vaseline (the last melts and disappears very soon), the same may be rubbed over the skin of the cheek or lids if the surface is irritated by frequent wetting. If there be much discomfort from feelings of grittiness or heat or smarting, a 2% solution of hydrochlorate of cocaine may be dropped between the lids at intervals of ten minutes until the sensations are allayed. This remedy has also the happy property of contracting the blood-vessels, thus serving a double purpose. It is, however, not to be used except to relieve discomfort and not with great frequency.

Many cases will require no other measures and a few days will see the eyes restored to health. For cases of more severity with a little swelling of the lids, slight sub-conjunctival effusion, more copious secretion and more pain, it may be needful to employ in addition astringent solutions. Among the oldest is a mixture of acetate of lead with infusion of opium, a drachm of the former to a pint of the latter. It doubtless has useful properties, but it must never be used when there is any tendency to ulceration of the cornea, because the lead is liable to be precipitated upon it. Its utility is in the early stage of a somewhat acute attack, and then is most grateful if warm. The mixture should be strained and made clear. It may be made also as follows: ℞ Liq. plumbi subacetatis, ʒ ij.; Fl. ext. opii. deodorat., ℥ i.; Aquæ, ℥ vi. M. A solution of alum, a drachm to the pint, is with many a favorite application both inside and outside of the lids. Mr. Tweedy, of the Royal London Ophthalmic Hospital (Moorfields), and some others have asserted that it has a tendency to increase ulcerations of the cornea in virtue of a solvent effect upon its cementum. He thinks he has seen decidedly mischievous effects of this kind. For myself I have almost discarded alum in favor of boric acid, and when the quantity of

secretion or the intense redness, or the degree of effusion call for active interference, the nitrate of silver is the most satisfactory remedy. A solution, two grains to the ounce, ½%, may be dropped into the eye twice daily from a dropper. If the tenderness and swelling do not prevent, the same solution, or one five grains to the ounce, 1%, may be applied with a small brush to the everted lids once daily, or be dropped into the eye. It causes a little pain, for which a solution of cocaine may be used, and compresses dipped in iced water sedulously applied until the reaction subsides.

For very nervous patients it may be needful to resort to bromides, and possibly to mild doses of morphine or Dover's powder at night, or better still to phenacetine, gr. x., once in two hours.

It is sometimes well to add sulphate of zinc to boric acid in the later stages of a moderately severe attack, as for instance: ℞ Zinci sulphatis, gr. iij.; Acidi boric., ʒ i.; Aquæ, ℥ vi. One may resort to solutions of corrosive sublimate, from 1 to 3,000 to 10,000, as was formerly done, and this would be suited to the mild epidemic cases, and to hospital or tenement-house out-breaks. It is irritating to many patients, but it is effective.

For cases where œdematous infiltration is great and secretion moderate, as in delicate children and sometimes in old people, solution of tannin, gr. v. ad ℥ i., or the liquor plumbi subacetat., ʒ ij. ad ℥ viij., is well adapted.

For severe cases of so-called "catarrho-rheumatic ophthalmia" it may be needful at the outset to apply two or four leeches to the temple to allay pain, to make very hot fomentations for the first day or two, to employ sol. sulphat. atropiæ, gr. ij. ad ℥ i., two or three times daily in the eye, and also perhaps a 2% solution of cocaine. No astringents or irritating drops are to be used until mucopurulent secretion is set up, and the temperature of all applications must be comforting to the patient. A saline purgative and often small doses of Rochelle salt frequently given for diuretic effect, will be valuable. In these cases we have to do no doubt with a general dyscrasia. Especially must one look for symptoms of a gouty diathesis, of which the signs may be slight and the tendencies not readily admitted by the patient.

As the acute attack subsides, if there be left a state of chronic hyperæmia, one may touch the everted lids once daily with solution of nitrate of silver, gr. ss.–ij. ad ℥ i., or with a smooth crystal of alum. Or if a patient cannot be so frequently seen he may drop into his eye a solution of zinc sulphate and boric acid. A patient never should have a solution of nitrate of silver given to him for this purpose. It soon decomposes, and its prolonged use causes brownish discoloration of the conjunctiva (*argyria conjunctivæ*).

It need hardly be said that during an acute attack a patient

Digitized by Google

must not read or write or smoke, and will remain in a dimly lighted, well-ventilated room. Even when recovery has been attained, caution must be given against prolonged use of the eyes, especially at night, and against exposure to wind, dust, smoke and foul air. Often colored glasses (light smoked or blue) will have to be worn in bright light.

In healthy persons with favorable surroundings and with proper care, the outcome of acute catarrhal conjunctivitis is perfect recovery within periods varying from five days to three weeks. On the other hand, there may be ulceration of the cornea with its various possibilities, or there may be chronic thickening of the palpebral conjunctiva, ectropium, pterygium, etc., etc. These conditions have been or will be considered under proper heads. Not a few cases of so-called granular lids have originated in an acute conjunctivitis.

3. *Conjunctivitis purulenta, Blennorrhœa, Pyorrhea.*— This phase of acute conjunctivitis is of more severity than the foregoing and present itself at different ages: first it occurs in infants at or soon after birth, and secondly it occurs in adults. In both classes the disease is essentially the same, and originates from contagion in the great majority of cases, but it is convenient and customary to consider them separately. The first is commonly called

Ophthalmia Neonatorum.—At birth the eyelids are always agglutinated by the parturient secretions. It is common too for the lids to remain red and sticky for a day or two. The nurse washes them off with warm milk and water, and soon the eyes are clear. A little attention may be required for several days, the principal point being the careful removal of secretion as fast as it may appear, and soon all is well. Should there be a little swelling of the lids, and secretion be rather troublesome, a compress wetted with a solution of borax or of alum may be laid on the eyes for fifteen minutes, once in two or four hours, and the edges of the lids smeared with simple cerate or vaseline. The great proportion of the cases of this disease will not require serious attention, and will not cause the physician any anxiety. A physician in large obstetric practice told me that he had had only one serious case in an experience of twenty years. But there are cases even in private practice which need active attention. Of these I have seen two varieties.

The less frequent are some which have more the character of granular than of purulent conjunctivitis. There is very little swelling of the lids—secretion is almost wholly watery. There is little or no hyperæmia of the ocular conjunctiva, while the palpebral conjunctiva is reddened, and at the fornix is considerably thickened and swollen. This hypertrophy is the essence of the trouble. It is truly a form of follicular conjunctivitis occurring at an exceptional age. While this continues the eye keeps watering

Digitized by University of Toronto

and a little sticky, and the condition goes on for weeks. The cornea does not get hazy, and there is no special danger. For the milder cases, where an anxious mother insists on something being done for the baby, I deprecate anything more than washing with a solution of boracic acid several times a day. But if a child is a month old, and the discharge continues and the fornix exhibits decided swelling, I have been obliged to use solutions of tannin and glycerin as strong as ʒij. ad ℥ i. before the condition would yield. I had tried nitrate of silver in mild solution, and, unwilling to make it more caustic, had taken a solution of tannin, gr. x. ad glycerin, ℥ i.; but this had only a temporary good effect, and the disease was not subdued until the strong solution was applied. It was done every second day to the everted lid, and was of course quite painful.

Much more important is the purulent conjunctivitis which is generally spoken of as *ophthalmia neonatorum*. It presents itself under various degrees of intensity, with swelling of the lids, with yellow, thick secretion issuing from the eye, or, if dried upon the tarsal edges, it glues the lids to each other, and the conjunctiva, both ocular and palpebral, is reddened and swollen; at the beginning the secretion is comparatively thin, but soon it becomes thick and creamy. This quality indicates abatement in the activity of the process. There may be chemosis, and the palpebral conjunctiva be thickened and intensely red and spongy, with ridges and prominences, and be cleft by fissures between the enlarged papillæ. The tumidity of the palpebral conjunctiva, which increases up to the fornix, is a notable feature. The cornea may remain clear, but its integrity is the object of anxiety. Its invasion may show, as the first sign, a diffused haziness, or a single spot of purulent infiltration, or an ulceration; while in weakly infants, of whom premature births and foundlings are often extreme examples, the cornea may suddenly break down with general infiltration, and become a mass of yellow putrilage. The place of ulceration in the cornea may be anywhere; if upon the periphery, and if it perforate, the iris falls into the opening and becomes permanently adherent, and from this a partial staphyloma may ensue; or, in case of less extensive destruction, nothing more than a distortion or concealment of the pupil. Should the ulcer be central, and not too large, so that if it perforate and the sphincter iridis cannot be drawn into the opening, the lens will then come forward and rest in contact with the posterior surface of the cornea. Sometimes a fistula will give rise to prolonged contact of the lens-capsule with the cornea. As a consequence, there will be an opacity reaching a little into the centre of the lens, at its middle a small white dot, and around it will be a fainter zone, and the whole will be apparently two or three millimetres in diameter. Sometimes, long after the

Digitized by Harvard College Library

eye is well, a fine thread is seen running from the lens to the middle of the cornea, which is the attenuated vestige of the material deposited while the surfaces were in contact. The opacity belongs to the capsule chiefly, and is both upon it and overlaid by it, sometimes having a distinct pyramidal form. It will be again referred to in speaking of cataract. In cases so marked as the above the secretion will be thick, creamy, and copious. The patients do not seem to suffer much pain, and usually nurse well. The skin of the cheek is apt to be excoriated by the discharge.

Prophylaxis.—The importance of preventing this disease will be appreciated from the statistics given by Haussmann.[1] Of the inmates of blind asylums the number made blind by this disease was in Copenhagen, 8%, in Berlin, 20%, Vienna, 30%, in Paris among 208 blind young subjects, 45%. In 1876 it was shown that among the young persons admitted to the blind institutions of Germany and Austria, 33% had been made sightless by this disease. In different countries the variation was from 20% to 79% (Horner). In Philadelphia, Dr. Harlan found in 1871, out of 167 inmates of the blind asylum about 20% had been admitted for this cause. In ophthalmic clinics, Hirschberg had among 21,040 new cases 314 of this kind; Schöler among 10,000, 156 of this kind. Horner in 1862 found among 10,000 cases, 161 of this variety and he gives this interesting analysis. Of recent cases there were 108, and of old cases in whom the disease had terminated, there were 53. Of the last named 53, 14 were blind in both eyes, 24 blind of one eye, and 15 had more or less serious corneal opacities. Of the 108 active cases only 24 were brought during the first week of the disease, and the remainder, viz., 84, came at later periods. Of the 24 cases seen during the first week, 2 already had corneal trouble; one healed with a trifling opacity, the other died before the end of the disease;—22 recovered with perfect sight. Out of the 84 less recent cases, 38 had disease of the cornea, and 46 did not have it. Of the 46, 3 acquired corneal ulceration, but in none of these patients was the eye lost. For the statistics of lying-in hospitals on this subject, reference may be made to Haussmann, l. c., and to Credé, "Die Verhütung der Augenentzündung der Neugeborenen," *Archiv f. Gynäkol*, XVII., 1, S. 50 (also in separate form, Berlin, 1884). The attention which of late years has been given to prevention of contagion, has proved by its success that to this, we are to look in the great majority of cases for its cause.

The origin of the contagion is the morbid vaginal secretions. The healthy secretions of the parturient state do not produce the eye trouble, at any rate there is strong reason for this belief, both from general experience and because direct inoculation of healthy

[1] "Die Bindehaut-Infection der Neugeborenen," Stuttgart, 1882.

secretion has been practised without evil effects. Microscopic study has found that both in the morbid vaginal secretions and in the pus flowing from the eye a special organism appears which was first pointed out by Neisser, of Breslau, in 1879 (*Centralblatt für Med. Wissensch.*, No. 28), and called by him the gonococcus, because it is characteristic of gonorrhœa of the urethra. This kind of infection is in the great proportion of cases the cause of the infantile disease. Other infectious causes cannot perhaps be absolutely excluded, such as the lochial secretion, or that from a suppurating navel, while from the nature of the case few investigations are made on this point, and it is also impossible to prove a negative. The eye disease appears usually about the third day, but may be delayed as late as the eighth day.

The prophylactic measures to be employed are on the one hand the washing of the vagina for some days before parturition, and while labor is going on, with a 3% solution of carbolic acid in all cases where the secretions are of a suspicious character. On the other hand attention is to be given to the eyes of the infant. By some, washing the outer (not the inner) surface of the lids and the eyelashes with a 3% carbolic solution is practised, while in accordance with the recommendation of Credé a single drop of a 2% solution (gr. x. ad ℥ i.) of nitrate of silver is dropped between the lids of each eye by a glass rod. The effect of these measures has been to reduce the frequency of the infantile disease in the lying-in hospital of Halle from 12% to 3%. In the lying-in hospital of Leipsic, where Credé instituted his own method, the cases fell from 7.5% to 0.5%.

It is impossible to resist the force of these facts and it becomes imperative to employ such measures in all cases where any suspicion may arise. This holds good especially in hospitals and lying-in wards, but it is applicable also to practice among the uncleanly and the poor. The solution of nitrate of silver in such strength, 2%, excites irritation, but a very small quantity is intended to be used (a single drop) and it neutralizes the poison. A 1% solution will certainly suffice, and the rigorous proceedings of a public lying-in hospital do not fully apply to private practice. For infants where only the usual secretions are present, cleansing the lids and eyes with a solution of borax or with any mild antiseptic solution or with warm water will suffice. It is seldom but that both eyes are infected at the same time. In case one only is inflamed, the other should be hermetically closed, and this can best be done by strips of india-rubber plaster, which may be left on for forty-eight hours and then renewed. The disease is usually more severe in the eye first affected.

Treatment.—If seen at the very beginning when the swelling of

Digitized by Google

the lids and a watery secretion are the chief symptoms, nothing but cold lotions and assiduous cleansing are to be employed. Besides the attested clinical value of cold lotions, Weeks found that a low temperature destroyed the vitality of the germs which he isolated in simple catarrhal conjunctivitis; the same is true of the more virulent types now considered. For the cleansing, boric acid 3% solution may be used. With the head upon the lap the solutions is to be squeezed from a rag or from a mass of absorbent cotton between the separated lids, and if needful is wiped away with a camel's-hair brush. The wetted cotton may be pressed lightly on the closed lids to squeeze out the flocculent secretion, and this is to be repeated as often as accumulation occurs. The cold application consists in laying linen or well-washed cotton compresses in iced water or on a block of ice, and transferring them every few minutes to the eye. In moderately severe cases the water need not be so cold. But the lotion is to be kept up day and night. As soon as the secretion grows a little thicker and the swelling of the lid grows less, so that it can be everted, we are to resort to nitrate of silver in strength varying from 1% to 2%, gr. v.–x. ad ℥ i. This is not to be dropped between the lids because it will thus endanger the cornea. But the upper lid is first to be everted, and if difficult to do, as often is true, the tip of the finger may be wrapped in a bit of rag or in the corner of the towel to aid in pushing or pulling the tarsal edge against the finger of the other hand which pushes down the brow. The physician has the back of the child's head between his knees and is provided with water and bits of rag. All secretion is to be wiped away and the caustic solution pencilled over the exposed palpebral conjunctiva, carefully avoiding the cornea. Afterward the lower lid is to be similarly treated. The effect of the solution is in proportion to the quantity applied and the lid should be washed with water afterward. If there be a little delay in the washing, the caustic effect is greater. The degree of effect can be estimated by the degree to which the surface is whitened, and repeated pencillings will intensify it. With weak solutions one may obtain various degrees of caustic action. Such a proceeding is to be gone through once in twenty-four hours, very seldom will it be required once in twelve hours. Immediately after, iced cloths are to be applied and very frequently renewed until the cries of the child cease and the pain has presumably disappeared. For several hours the secretion is held in check, although the swelling increases, and during all the time of its increase and of the painfulness of the eye, the cold is to be continued; this may be for two or four hours. After a time flocculent portions of the eschar and renewed secretion appear. Now cleansing is in order and the lotions will be kept up with less assiduity as the

Digitized by Boston Medical Library

swelling abates. If the daily personal attendance of the physician is not possible, a solution gr. v. ad ℥ i. may be dropped between the lids three times daily, taking pains to insure its entrance beneath the upper lid by lifting it off the globe and at the same time avoiding contact of the caustic with the cornea. It is not easy and is very important to inspect the cornea, to watch the first tokens of its invasion. To separate the lids, Desmarres' elevators are invaluable (See Fig. 130).

In skilful hands what is known as the mitigated caustic stick (one part nitrate of silver with two parts of nitrate of potash) may be usefully employed. It is more energetic than solutions, it can be more accurately applied and finds its special utility in the later stages of the disease when papilliform swelling is extreme, and the secretion is very thick. The cornea must be absolutely avoided



FIG. 131.

and the excess of caustic washed away. In ophthalmic clinics this is in considerable use.

Frequently the conjunctiva bleeds under the handling; it is not, however, needful to resort to scarifications, nor is canthotomy to be practised. In infants, despite the great swelling, there is little danger of strangulation of the tissues, and leeches are never to be employed.

In the event of the cornea having become affected, whether by opacity or by superficial ulceration, the caustic treatment is not to be interrupted, neither is it to be made more vigorous. If deep ulceration take place a solution of atropia, gr. ij. ad ℥ i., may be dropped into the eye three times daily or oftener, to secure dilatation of the pupil. For marginal ulcers, eserine sulphate gr. i. ad ℥ i. may be used twice daily according to effect, and atropine during the interim. If the ulcer threaten to perforate, a careful paracentesis at its thinnest point will sometimes do good, but one rarely has an opportunity to try it and it is always a delicate and difficult thing to do. On the other hand, if perforation spontaneously occur, there is generally an improvement in the condition. It is not meant that spontaneous perforation with the resulting prolapse of the iris is not to be deplored. Temporarily it affords relief, but it brings about permanent damage to sight. It is unwise to interfere

Digitized by the College of Optometry

with prolapse of iris unless it projects in a conspicuous prominence, when sometimes careful puncture, holding the needle at a tangent to the summit, will abate it. Excision is not to be practised. In bad cases the whole cornea may rapidly melt down, the iris extensively prolapse, the tissues rupture, and the lens escape. A staphyloma of the cornea or phthisis of the globe may eventuate. Some writers have reported favorably upon *finely* powdered iodoform dusted over the everted lids (Grossman[1] and others). It is said to check the discharge and have a favorable effect on the cornea after infiltration has begun. It is applied once or twice daily. Since its announcement in 1882, little has been said about it.

The duration of treatment in favorable cases will be from four to six weeks, while in bad cases it may go on much longer. The length of treatment and the prognosis as to result are greatly influenced for good or bad by the health of the subject and by efficiency as well as early commencement of the treatment. But even in cases which seem most unpromising the wonderful recuperative powers of early life, will eventually bring about a degree of improvement for which there seemed to be no prospect.

Sometimes the conjunctiva takes on extreme hypertrophy; the purulent secretion almost ceases, the cornea may be clear, the activity of the disease is at an end, but there has not been subsidence of the swelling, and a constant eversion of the lids remains (paraphimosis.) It does little good to apply caustics or stimulants or astringents. The lids may be inverted, but in a moment or certainly as soon as the child cries, the deformity returns. Nothing relieves this condition but mechanical methods. The lids must be inverted and so retained by strips of india-rubber plaster, and their ends may be held down by laying over them a few fibres of cotton and saturating this with contractile collodion. In fact such a dressing may cover the whole of the lids save a spot for secretion to escape. Should this fail after a fair trial, and it is not likely to fail, one might in a severe case carefully pare the edges of the lids over the middle third without doing injury to the cilia and stitch them to each other.. They will grow fast and may so remain for several weeks until the hypertrophy has disappeared. I should give several weeks' trial to the other method, provided the dressing could be kept in place without irritating the skin. It must be renewed every three or four days.

Purulent conjunctivitis in adults (*gonorrhœal ophthalmia*), is essentially the same disease as above described in infants. In a few instances it seems to be of spontaneous origin, but these are very rare, while in the vast majority some source of contagion can be traced. This will be from an acute or chronic gonorrhœa either

[1] Ophthalmic Review, Vol. i., 1882, p. 214.

Digitized by University of Illinois College of Medicine Library

in the male or female, by communication from a similarly diseased eye, by indirect contact through the fingers or handkerchiefs, towels, clothing or rags. The secretions from diphtheritic conjunctivitis or from vaginal leucorrhœa cause it. A very minute quantity is sufficient and that derived from an old gleet remains effective. The right eye, for obvious reasons, is oftener concerned than the left. More frequently than with infants is one eye only involved.

Reference has been made to the gonococcus Neisseri as the efficient agent in this disease. The micro-organism appears usually as diplococci in twos or fours within the pus-cells, or in isolated groups, and are also found at considerable depth in the epithelium and in the tissue of the conjunctiva. Their malignant influence has been unquestionably demonstrated by the fact that inoculation with pure cultures causes urethritis in the human subject. Moreover, Deutschmann reports a case of arthritis gonorrhoica in an infant with purulent ophthalmia (Graefe's *Archiv*, XXXVI., 1, 114, 1890). The cocci were in the conjunctival secretion and in the fluid ob-

FIG. 131.

tained from the joints by puncture. In the eye, the more active the gonorrhœa at the time of infection, the more violent will be the inflammation. The period of incubation is said to be about forty-eight hours. A physician must always be careful lest he incur infection. Sometimes pus spurts out in a jet as the lids are separated. Immediate washing and neutralizing by a drop of 2% solution of nitrate of silver will be indicated. The mystery which sometimes attaches to the transmission of the inflammation to a healthy eye is lessened, when it is known that the pus diluted 1 to 1,000 still retains decided contagious properties. It ought also to be stated that nitrate of silver, by its power of coagulating albumen, antidotes in high degree the noxious character of the pus, and it has been shown that a one-fourth-per-cent solution, or gr. ½ ad ℥ i., renders it innocuous. This fact explains why so few cases of contagion occur in public clinics, where the same brush may be used for different patients, when it has passed through a solution of nitrate of silver. I instance this fact, not to encourage economy

Digitized by Illinois College of Optometry

in the use of brushes, but as a point worth knowing. Every patient needing an application to his lids, should have his own brush; and purulent cases should be most vigorously quarantined from communication in any manner with other patients.

The *symptoms* are at the outset hyperæmia of the ocular conjunctiva, swelling and closure of the lids, and a thin and ichorous discharge; there will be smarting and burning, which soon rises to pain both in and around the eye, œdematous infiltration increases until the lids become hard, tense, and shine with a dusky red, and the upper overhangs the lower. A similar infiltration takes place beneath the ocular conjunctiva, lifting it from the globe and making it mount over the edge of the cornea (*chemosis*). The secretion in a little time becomes more and more purulent and soon seems wholly of this quality. The temperature of the parts is elevated, and the whole picture is that of an excessively severe inflammatory process. If the lids can be separated, the conjunctiva is not only red, but is often speckled with hemorrhages; it is covered with pus, and especially on the palpebral surface during the early period, there will also often be a layer of plastic exudation, which will come off in rolls or may adhere rather closely. When wiped away the surface beneath it bleeds. It is oftentimes impossible to separate the lids enough to view the eye properly, and the attempt gives so much pain that the patient involuntarily and strenuously resists it.

The great danger is mischief to the cornea. This may come during the full activity of the disease or not until we begin to felicitate ourselves that the climax of the attack has passed. There may be a variety of ways in its manifestation. Either the whole surface may have a uniform opacity of varying density, or this may appear at the centre or periphery. Ulceration may occur in company with it or soon follow it, or may be the first invasion. A furrow at the margin of the cornea, beneath the overhanging chemosis, may completely or partially encircle it, and it may eat through the cornea in a very few days. Ulceration at the centre, or at any point, is equally prone to occur. The degree of corneal mischief can never be predicted. It is the product of three factors, namely, the pressure of the swollen tissues, the corrosive action of the secretion, including the invasion of the gonococci, and direct continuity of inflammation to the substance of the cornea. It is also favored by unhealthy constitutional conditions, and by bad hygienic surroundings. It is impossible to assign to each factor its exact measure of influence, or to assert that a peculiar lesion of the cornea must be attributed to predominance of one or the other of them; in most cases, all concur in the disastrous effect.

The culmination of the active symptoms commonly arrives

Digitized by Illinois College of Optometry

within ten days, and the duration of the disease is from four to twelve weeks. The final result upon vision, in case the whole cornea is not destroyed or the eye escapes suppuration, is apt to be better than would seem possible during the severity of the symptoms. So much of the cornea as may remain will become far more transparent and serviceable than may seem at all likely.

Treatment.—From the beginning active measures must be adopted, and the patient should go to bed. In robust subjects, or with intense initial swelling or pain, four to six leeches may be put upon the temple. Bits of muslin taken from iced water, or from a block of ice, should be kept upon the eye constantly, and changed every minute or two as they grow warm. In some cases a bit of ice, wrapped in muslin, may be held upon the eye if its weight can be endured. Continuous cold, to the degree which can be tolerated, is the rule. Absolute cleanliness of the inside of the lids is equally imperative. To effect it, the lids must be drawn apart and the secretion removed by a soft camel's-hair pencil inserted between them, or by dropping an antiseptic solution upon the eye from a small sponge, or by injecting such a solution with a small bulb syringe. Some one of these methods may be chosen, according to convenience. This process will be repeated every five or fifteen minutes during the days and nights of active secretion, and at longer intervals as the discharge lessens. The antiseptic fluid may be sol. corrosive sublimate, 1 to 3,000–10,000, or boric acid 4%, or of chlorinated water 10%. It is sometimes well to use an elevator in separating the lids, but by sensitive persons this will not be allowed, and extreme delicacy is needful in all manipulations, especially when ulceration has appeared upon the cornea. In certain cases in which the discharge is not thick and creamy, but ichorous, gruel-like, and thin, and in which the attack is moderate in severity, nothing but this constant cleansing, by antiseptic lotions and the iced water, are needful; no caustic need be applied. I have seen a remarkably good recovery of a case like this, in a young man who acquired the disease from gleet. Mr. Grossmann of Manchester has recommended the ointment of yellow oxide of mercury in vaseline. Dr. Wilson of Bridgeport reported success by a mixture of boric acid and vaseline. Experience has shown that putting vaseline hourly between the lids is an important aid in getting rid of secretion and preserving the corneal epithelium. This practice is now generally adopted in New York. The fidelity and thoroughness of the cleansing by night and day have the greatest influence in the fight for preservation of the eye. Should the cornea become invaded, a solution of sulphate of atropia, gr. ij. ad ℥ i., should be instilled every three to six hours. It will be seen that, to perform this laborious nursing, not less than two attendants, both strong and faithful, are necessary.

Digitized by Illinois College of Optometry

Another indication is to be borne in mind in severe cases, viz.: the relief of pressure by incising the swollen tissues and unloading the vessels. Mr. Tyrrell laid stress on scarification of the chemotic conjunctiva, the infiltration does not flow away however deep the cuts, because it is of a plastic and coagulable quality, but the depletion is of use, and the incision may be repeated. Canthotomy freely done unloads the vessels and lessens the pressure of the lids by weakening the orbicularis and giving room for the infiltration to spread. I consider this proceeding indispensable when great swelling of the lids exists, and do it with little swelling if the cornea be threatened. It may be needful to again snip the tissues with scissors in the site of the cut, after a week or more, because healing quickly takes place, and conditions of partial strangulation by the lids may be reproduced. In resorting to such proceedings, a surgeon will require to act with discretion as well as boldness, appreciating the significance of the symptoms, the danger to the eye, and the general health of the patient. As against the propriety of incisions, the partial interruption of the process of cleansing is to be considered; but this need not be wholly suspended; its method may be so modified that the lid need not be greatly disturbed for the next twenty-four hours.

Mr. George Critchett once resorted to medial vertical division of the upper lid in an infant and thereby as he thought saved the eye. The writer believes that such a proceeding might judiciously be sometimes done in adults, because the disastrous results of the disease are deplorably frequent and the deformity to the lid could be easily repaired. The advantage is obvious both by relief of pressure and in facility of cleansing. Exposure of the cornea is the one thing to be guarded against.

Next, we have to consider the use of nitrate of silver. It will have no place during the period of invasion, and of copious thin, gruel-like, puriform secretion. But when the secretion becomes creamy and distinctly purulent, and the conjunctiva velvety, a solution gr. v. vel x. ad ℥ i., may be tried on the everted lids. The longer the brush is held in contact with the surface, the greater is its effect, and this may not be small. Pain will ensue for an hour, or longer; for a time the secretion is suspended, or becomes watery, and if after twenty-four hours the swelling is less, and the secretion not so copious, the remedy has been well chosen and may be repeated. It must be remembered that the first application is tentative, and to be carefully watched in its effects, especially on the cornea. The 2% solution is generally to be preferred (gr. x. ad ℥ i.). Formerly much stronger solutions were in vogue, but stronger than 4% they are not to be commended. Thorough contact with all of the conjunctiva is very difficult even when the lids can be fully everted,

Digitized by the Internet Archive of Ophthalmology

but an effort must be made to effect it by thrusting the brush up to the fornix. The solution is by some dropped upon the ocular conjunctiva, but care must be taken to avoid the cornea; it may be dropped in three times daily when chemosis is extreme. The application of caustic to the lids will usually be made once in twelve or twenty-four hours, seldom oftener and frequently but once a day. The recurrence of the purulent secretion is the signal for repetition. It is at this point that the good judgment of the physician is tested. That copious use of vaseline is a valuable coadjutor is indubitable.

No remedy has such general acceptance in this disease as nitrate of silver. Recently peroxide of hydrogen in watery solution containing 3% by weight has been proposed by Landolt as of value as an antiseptic. It acts by the rapidity with which it liberates oxygen, and it has the effect of abating the quantity of pus, but exerts no special control over the inflammation. It must be kept at a temperature below 60° F., and in a bottle tightly corked. The tissues remain swollen and soggy and the cornea is no less liable to be injured. It does not supersede the caustic. It is not irritating provided in its preparation it is free from sulphuric acid. Iodoform has been dusted into the eyes, but iced water and other remedies have at the same time been employed, and we are not authorized to assign special value to it. It may do well for cases of mild type and with persons who will not submit to confinement and constant treatment. The powder must be extremely fine and be dusted freely over the everted lids. When corneal ulceration exists it may be used, but the remedy is less in favor now than it was. Recent authors, Heyl, Freyer, have substituted *hot* water, of a temperature as high as 112° to 120° Fahrenheit, for iced water and reported useful results. Heyl uses it for one-half an hour three times daily, while Freyer employs it from six to eight hours. Heyl confesses want of success in dealing with adult cases, and his experience has chiefly been among infants. With them the disease, if attacked early enough, is seldom destructive to vision, and whether by hot water its duration is briefer than by iced applications remains to be corroborated. Freyer's claim of better success in the adult cases also awaits corroboration.

Very recently corrosive sublimate has been again brought into use and in two different methods. The first is applications of solutions 1 to 500 to the everted lids with such frequency as will hold the purulent secretion in check. The strength of the solution may even be increased if the physician is constantly at hand and does the work himself; this is feasible only in hospital practice. Great pain is produced, and all usual precautions of cleanliness and cold lotions are maintained. Another method is to scarify the conjunctiva both palpebral and ocular by incisions 2 or 3 mm. apart and brush it moderately with a solution 1 to 1,000. An anæsthetic must be given. A

Digitized by Illinois College of Optometry

common tooth-brush is used, and canthotomy may be done. A remarkable abatement of secretion takes place, although the lids may swell. The same proceeding may have to be repeated at intervals of three days for two or three occasions. The germicidal value of the remedy suggests the treatment. I have employed it in five cases with good effect, and purpose to use it further. An unpleasant complication is the ultimate production of more or less extensive and irregular adhesions between the lids and the globe. The cases were patients of the infirmary who could not be taken under hospital care, and for conditions so unfavorable I was glad to find an effective treatment, although painful and attended by the drawbacks mentioned. In no instance was serious damage done to the cornea. The customary auxiliary proceedings were insisted on. The depth to which the gonococcus penetrates the tissues and the amount of œdema determines the need of scarifications and the method and vigor of the brushing.

When infiltration of the cornea appears, a solution of atropia should be used and especially for central ulcerations. It is to be remembered that iritis is very liable to occur and hence atropia has an important indication in all corneal complications. Should there be a marginal ulcer, a weak solution of sulphate of eserine, gr. ss.–i. ad ʒ i., may be used twice daily. But it does not exclude the intercurrent use of atropia. If strong eserine solutions are used, they may provoke pupillary adhesions. In many cases we are not allowed to debate the propriety of this treatment because of the rapid advance of ulceration. If it threaten to perforate, we may perform paracentesis—for actual prolapsus iridis we are to do nothing with the iris: excision does harm. While in simple corneal ulcerations without blennorrhœa, we derive advantage from the actual cautery such is not the fact in the situation now considered. The tentative use of *very hot* water, 110° to 120° F., may be suggested on general principles because of the perilous predicament, but the writer has no experience on the point.

The issue of an attack may be in perfect restoration of the conjunctiva to its normal texture, in case it were healthy before, but it not seldom passes through a period of papillary hypertrophy (granulations) which may continue for weeks. The case may be under treatment for this condition long after the ocular conjunctiva has recovered its normal state, and at this stage, sulphate of copper crystal, tannin and glycerin, ʒ i. ad ʒ i. or stronger, will be the most useful applications. In the event of the cornea being damaged, all eventualities are possible, between a slight degree of opacity, almost amounting to transparency on the one hand, and staphyloma corneæ, or atrophy of the globe, on the other. A partial staphyloma, or anterior synechia, for which an artificial pupil may be practicable, is exceedingly common. It is of course possible that both eyes may be lost, but the right is the one most often affected; and it is common, when a second eye is attacked, for it to be less

severely inflamed than the first. The reason is, because the secretions are less noxious during the decline of the inflammation. For this reason, the pus of a florid urethritis will cause much more severe inflammation than that from the stage of gleet. The fatality to sight of this disease is great, and is set down by Klein as follows: Out of 40 eyes, 16 became totally blind, 9 retained some vision, and 5 had useful vision, or could obtain it by operation: in 30 the cornea was involved, while in only 10 did it escape. That is, corneal trouble occurred in three-fourths of the eyes, while 40% became blind.

The protection of the fellow-eye, in case it be intact, is of the utmost importance, and my experience has been that the endeavor to seal it hermetically by a bandage or plasters, is ineffectual. It cannot be carried out rigorously, because of the wretchedness which it inflicts in making the patient for the time wholly helpless, and because of the excoriation of the skin of the cheeks and lid, and of the impossibility of preventing the patient from slipping off the covering during the night, and unwittingly exposing himself to contagion by his soiled fingers or accidental communication from the other eye. In fact, the need of handling the eye to change the dressings, which should be done twice daily, involves more exposure than to warn the patient and attendants of the need of the utmost caution, and to insist that the patient sleep, lying on his back, or on the side of the affected eye. A device, whose authorship belongs to Dr. Buller, of Montreal, has answered well, viz., to cover the sound eye with a watch-glass, attached by means of rubber plaster. It need not be removed oftener than once in several days, as secretion may demand.

4. *Plastic Conjunctivitis,* viz.: *a. croupous* and *b. diphtheritic.*—Under the description of purulent conjunctivitis, we have mentioned that sometimes the secretion is to a degree plastic, either forming shreds, or adhering to the mucous surface. No special significance is to be attached to this fact, but cases sometimes arise where the plastic quality of the secretion is a distinctive peculiarity, predominating over all other features of the case, and, therefore they deserve special mention. Various grades of this quality appear, and if we find that the layer of false membrane can be easily rubbed from the conjunctiva, there may be no need of regarding the case as differing essentially from a blennorrhœa, because it will soon exhibit the features of the latter by transformation of the plastic substance into ordinary purulent secretion. On the other hand, we meet cases in which a plastic exudation is the dominant fact. It will appear in greater or less degree, and while the moderate cases differ so widely from the most severe, as

to warrant separate designations for each, we also meet intermediate degrees of severity which it is difficult to bring under an exact classification. Some authors insist upon describing *croupous* and *diphtheritic* conjunctivitis as separate diseases. In the former (*croupous*) the eyelids alone are attacked, the exudation is moderately adherent because superficial; by rather severe friction with a rag it can be rubbed off and exposes a bleeding surface. The deposit may be in patches or spread over the whole surface. The general reaction is moderate, the lids not much swollen, the ocular conjunctiva red and somewhat œdematous, the cornea seldom involved either in opacity or ulceration. On the other hand, *diphtheritic* conjunctivitis is described as a condition in which both the palpebral and ocular conjunctiva is covered by plastic exudation, which is dense and gray, penetrates deeply into the tissue, involves the whole mucous membrane, and in the lids attacks so great a depth of tissue as to make them hard, stiff, and brawny. The material cannot be wiped away and the structures are deprived of blood by the intrusion of the plastic substance. The cornea is very liable to ulceration or necrosis. There will be fever and general prostration. The first distinct portrayal of this condition was in one of the earlier papers of Von Graefe: and it was limned with a master-hand.

There is no doubt that under the above description of croupous conjunctivitis many cases may be ranged with correctness and that the disease is purely local. But if we attempt to be thus precise in our designations we fall into error. I have treated a case in which the plastic exudation was confined to the lids, but was not superficial, it was incorporated with the deep texture and never could be wiped away; and finally it disappeared by absorption or simple melting away, as I have seen similar material behave when exuded upon the tonsils and fauces in a fatal case of diphtheria. Again Nettleship describes (*St. Thomas' Hosp. Reports*, Vol. XIV., 1886) two cases of fatal diphtheria beginning in one instance on the conjunctiva of one eye and spreading to the nose, throat, and opposite eye, and in which both lids of the eye first affected, were lined with a moderately adherent membrane, but the substance of the lids was not infiltrated nor swollen; the ocular conjunctiva was infiltrated and the cornea was represented by a thick, white, soft slough. The fauces were covered with membrane. The other eye became affected, but the hard, brawny, rigid, and bloodless condition said to be typical of diphtheritic conjunctivitis was never present. Yet this case, by its complications and fatal issue, was unquestionably one of diphtheria and the ocular disease was diphtheritic conjunctivitis. Mr. Nettleship also reports another case of "muco-purulent ophthalmia of the right eye" with membrane on the lower lid, both its

mucous and cutaneous surfaces, also on the free border of the upper lid, but not on its palpebral surface. The other eye was normal. The pillars of the fauces on both sides, the tonsils, uvula, and soft palate were covered with a thick, gray, ashy membrane; the glands about the jaw on both sides were enlarged. This was of course diphtheria, and the eye considerably impaired; the other eye remained free, and on the tenth day the child died.

It seems more logical to speak of such cases in a general way as plastic or diphtheritic conjunctivitis, and not to expose ourselves, by a rigid definition, to a false description of a certain number. We may meet with all the types which have been referred to, and we may choose to call the lighter forms croupous, but it would be less erroneous to style them mild degrees of plastic conjunctivitis, and we may call the graver forms intense degrees of plastic conjunctivitis, or when constitutional symptoms appear we may correctly call the cases diphtheritic irrespective of the depth or extent of the plastic infiltration of the conjunctiva.

It may be proper to quote from Flint's "Practice of Medicine," 1881, p. 38, a passage which describes the pathological anatomy and which will also serve to explain the cause of the various forms of the disease we are discussing. He says:

"The terms *croupous* and *diphtheritic* are applied to fibrinous exudations upon mucous membranes. Unlike the inflammations of serous membranes, the ordinary inflammations of mucous membranes are not accompanied by a fibrous exudation. The term catarrhal is sometimes applied to those simple inflammations of mucous membranes characterized by an exudation of serum, mucus, and some pus-cells. According to the careful investigations of Weigert, fibrin is present in the inflammations of mucous membranes only when the epithelial covering is partly or wholly destroyed. The epithelium may be destroyed from various causes, among the most important of which is coagulation necrosis. The necrosis may extend deeper than the epithelium into the subjacent tissues. When only the epithelium is destroyed, the fibrinous exudation lies upon the membrana propria of the mucous membrane, from which it can readily be stripped off without loss of substance. This form of exudation is called croupous. When the primary necrosis involves the tissue-cells as well as the epithelium, the fibrinous exudation extends from the surface into the tissue of the mucous membrane, and cannot be removed without loss of substance. This second form of exudation is denominated diphtheritic. When the fibrinous exudation adheres closely to the mucous membrane without really infiltrating it, it is called pseudo-diphtheritic. It is to be observed that croupous and diphtheritic exudations require destruction of the epithelium only in one place, and that they may extend themselves over the surface of the surrounding intact epithelium. The fibrin in croupous and diphtheritic inflammations is derived partly from the blood, partly from metamorphosis of the epithelial and other cells, and, perhaps, partly from fibrinoid degeneration of the intercellular substance (Neumann)."

The remark made in this quotation "that croupous and diphtheritic exudations require destruction of the epithelium only *in*

one place and that they may extend themselves over the surface of the surrounding intact epithelium" was emphatically exemplified in a patient whom I saw with Dr. R. H. Derby; a young child with a thick coating of plastic exudation over the upper lid as the special feature of a severe inflammatory condition. It could be easily pulled off as a whole, and displayed at one point a mass of sprouting granulations as large as a pea where the mucous membrane seemed to be perforated. Observation for successive days proved this spot to be the focus whence the exudation extended. When by cauterization these granulations were destroyed, the tendency to diffuse plastic exudation speedily disappeared. The case continued for several weeks.

It must be added that cases are recorded in which a film of plastic material continued to form and be thrown off for many months, not only upon the palpebral, but on the contiguous ocular conjunctiva, while the reaction was moderate both in swelling and other inflammatory features, and finally the eye recovered. In other words, plastic conjunctivitis appears rarely as a *chronic* affection. Cases which persisted as long as five months are given by Nettleship, *St. Thomas' Hospital Reports*, Vol. X., 1880, and by Critchett and Juler, Trans. Oph. Soc. of United Kingdom, Vol. III., p. 1, 1883, with colored plate.

Sometimes one only, but usually both eyes are affected. While usually spontaneous, it may occur after operations upon the eye, as happened once in my experience in a boy ten years of age operated upon for strabismus; the dense gray plastic infiltration extended from the wounds over the ocular and then over the palpebral surfaces, with the typical characteristics of stiff and bloodless structures. It sometimes occurs after the exanthemata, measles, or scarlet fever, and broncho-pneumonia; it may go up from the throat and nose: chronic inflammatory conditions of the conjunctiva predispose to it. Epidemics may occur. At its outset it may be accompanied by severe swelling and great redness of the lids, almost erysipelatous, but ordinarily the swelling is moderate and the discharge slight.

In certain instances, which seldom occur, the lids are firm, stiff, hard, difficult to evert because of the depth of the infiltration. Their temperature is increased, and handling produces much pain; it may be impossible to evert them. The contrast between the abundant plastic infiltration and the absence of secretion in these severe cases is remarkable. The cornea is liable to opacity at an early period, and may easily succumb either by ulceration or by diffused infiltration. When cut into, the lid is gray, lardaceous, and little disposed to bleed. The tissues are filled with micro-organisms. Not infrequently diphtheritic patches are found in the

Digitized by Harvard College Library

nostrils. The period of infiltration lasts from six to twelve days, when the membrane begins to be dissolved and comes off or is absorbed; reddish streaks and patches appear in the white deposit, the lids become softer, the conjunctival tissue is more succulent and velvety, showing a papillary outgrowth, and a discharge, which gradually becomes purulent, sets in; after a time the case takes on the aspect of an ordinary blennorrhœa. During the process of healing of severe cases, an abundance of cicatricial tissue is developed, giving rise to atrophy and shrinking of the conjunctiva. The prognosis is in these cases extremely grave, and life itself is sometimes at issue.

It must be added to the above description that a membranous exudation may form on the cutaneous surface and edges of the lids, and the conjunctiva present simply a blennorrhœal condition. Even sloughing of the skin has been observed (Nettleship) and there may also be ulcerations and exudations or herpetic eruptions on the cheeks about the nostrils and lips, and perhaps exudation in the throat.

The health of the patient and his surroundings are of great importance in contending with this malady.

Treatment.—For the milder cases cleanliness and not very cold lotions are sufficient; boric-acid solution may be employed, and the disease will readily yield within a few days. As the tendency to production of plastic membranes abates, a weak nitrate of silver solution, 2 or 5 grs. ad ℥ i., may be employed once in twenty-four hours. There are, however, exceptional cases, of which within a year I have seen one, where the disease is more obstinate. The exudation, though confined to the lids, penetrates the membrane, cannot be wiped away, and persists for weeks; at the same time some ulceration may take place at the edge of the cornea. In the instance in my mind, applications of cold with cleanliness and mild remedies had no controlling influence. The best result was at length obtained when a solution of corrosive sublimate, 1 to 2,000, was pencilled over the everted lid several times a day, and a solution, 1 to 5,000, used as an external wash.

Antiseptic and germicidal substances are obviously indicated. In selecting them and their degree of concentration we must be guided by the intensity of the process and its stage. The very grave cases are fortunately rare, and in them the dense infiltration imperils the vitality of the tissues, threatening gangrene. If this confronts us we may use hot instead of cold lotions, and resort to antiseptics cautiously. A trial of corrosive sublimate, 1 to 1,000, may be made when some secretion appears, and if not too greatly resented may be repeated, carefully watching its effects. In fact the treatment must be tentative and the case frequently inspected.

Digitized by Harvard College Library

If swelling be great we will use cold, even iced lotions, and employ mild antiseptics cautiously to remove secretion. The germicidal use of corrosive sublimate, meaning in strength 1 to 500 or 1 to 2,000, requires caution and judgment. Its antiseptic use 1 to 5,000 will be persistent. One may employ as antiseptics aqua chlorinat., sol. sodæ chlorinat. (Labarraque), 1 to 5, sol. potass. permanganat 2%. Finely powdered iodoform, dusted into the eye, or mixed with vaseline, ʒ i. ad ℥ i., is to be suggested.

If swelling be so great as to make canthotomy advisable, the cut surfaces will be invaded by the exudation. Wolfring recommended the ung. hydrarg. oxid. flav. with vaseline 3% rubbed on the mucous surface once or twice daily with energy, but its value has not been sustained, although approved by Schmidt-Rimpler, 1885.

When the plastic material begins to disappear and a red and succulent surface emerges, the nitrate of silver will find place, but never until this stage. Its utility is precisely the same as in cases of purulent inflammation, and the rules for its employment will be the same. As the disease abates, the cold lotions and the cleansing will be less frequent. Leeches and depressing remedies are out of place.

Constitutional treatment may not in many cases be neglected. Foremost is the necessity of sustaining the nutritive power by careful feeding, by iron in full doses, by quinine, and perhaps by stimulants. Milk will be largely employed, and all the measures called for by other complications, whether in the nostrils or the throat, on the face or in the chest, will be resorted to. By v. Graefe and by some of his followers mercurials have been given, but they are not to be relied upon.

The disease may be very serious and the great danger is to the cornea, while in certain types the conjunctiva undergoes atrophy, sometimes causing broad adhesions or fræna at the retro-tarsal folds, and may eventuate in entropium or trichiasis. The risk to life has been referred to, but this is not often met with. The cornea in some instances suddenly and totally breaks down with yellow infiltration, while usually the damage comes by ulceration and perforation beginning at a particular spot. Graefe, out of 40, lost 9 eyes; Hirschfeld, out of 94, lost 34 eyes; Jacobson, out of 22, lost 5 eyes. The fatality in epidemics is apt to be most severe.

5. *Granular Conjunctivitis—Trachoma.*—Under this name is grouped a variety of conditions apparently quite dissimilar, whose chief characteristic is hypertrophy of tissue, and which has received its name from the presence of certain granules or follicles which under one form or another are considered essential to it. It may or may not be attended by acute inflammation. The name tra-

choma was popularized in ophthalmology by Steilwag, who called attention to the granules as marking the disease, and they are often called trachoma granules, but have nothing in common with the granulations of a healing wound. In many cases of granular conjunctivitis they are not recognizable to the naked eye because imbedded in the tissue; in some cases they do not exist, in some cases they are few and hard, in other cases they are most exuberant and very soft. We find them as semi-transparent, seed-like bodies, compared to grains of boiled sago or the spawn of frogs; they may, in old cases, be dull red and in hard, flattened masses. They often appear in a ridge along the orbital edge of the tarsus as a semi-opaque infiltration, and their seat of election is the fornix of the upper lid and not much less frequently of the lower lid. In these localities they exhibit clefts and prominences like a cauliflower, owing to the laxity of the tissue.

Besides these granules we have more or less hypertrophy of tissue, which may appear as fine or conspicuous papillary outgrowth; the membrane is deep red, usually rough, sometimes is smooth, and occasionally is enormously thickened. After long continuance fibrillæ of connective tissue appear, and in the end it supersedes all other textures, bringing about atrophy and various degenerations. Under certain phases there is secretion, either watery or mucoidal or puriform—in most cases, and these the chronic ones, there is little or no secretion.

While of necessity a source of discomfort, the chief misery and mischief are through the lesions of the cornea. This becomes hazy, vascularized, ulcerated, densely opaque, sclerosed, perhaps perforated and staphylomatous. The vascular haziness is called *pannus* and may be in most various degrees of density, called *p. tenuis* (thin), or *p. crassus* (fleshy). The upper portion of the cornea may alone be affected, the whole may be implicated. The pannus may occur during the period of hypertrophy; its worst forms are found in the last sad stage of conjunctival atrophy.

The disease affects the upper lid more than the lower; very rarely does it attack the ocular conjunctiva, save in the form of follicular trachoma, and then by continuity from the fornix. It is chronic in its duration, liable to intercurrent inflammations, affects chiefly those in poverty or living in unhealthy conditions; is a pest in asylums, orphanages, barracks, and poor-houses; is found among children (seldom in infants) and adults of all ages; in later life is seldom begun, but merely continued. It has general geographical limitations, in the sense that in certain countries it is far more severe and prevalent than in others. For example, in Ireland, Holland, Belgium, Turkey, and Egypt it is the curse of the common people. In Russia it abounds, in middle Germany it prevails less

Digitized by Illinois College of Optometry

than in southern Germany and Austria. In the United States it affects the dwellers in tenement-houses, and goes with unhygienic conditions in large cities. It prevails in the Western prairies and is found scattered widely over the country. A high altitude is unfavorable to its production, as proven in Switzerland. See Chibret.[1] The negro race are said to be exempt (Burnett), although mulattoes of every grade are its victims. It occurs among the Western Indians. Most important is the favoring influence of the so-called lymphatic (scrofulous) temperament. On this point sufficient stress has not until lately been laid, although clinicians have always recognized the fact in practice. This accounts for its appearance occasionally among the wealthy and well-cared-for, and it is not less obstinate among them than their poorer fellow-creatures. See Truc.[2] For its dispersion another cause must be assigned, viz., a degree of contagiousness. On this point careful discrimination is requisite. Those phases accompanied by secretion are undoubtedly contagious, and in the degree of its copiousness. For example, the so-called Egyptian ophthalmia, which is a mixed condition; the disease as found in public institutions, educational and eleemosynary; the so-called acute trachoma, some cases of follicular trachoma—all are attended by muco-purulent or other secretion, and in all a great variety of microbes are to be found. The means of contagion are in Egypt flies and other unsavory media (Howe), use of towels and toilet articles in common, washing in the same water, and the innumerable modes of conveying filth practised by filthy people. The contagium may adhere to the walls and floors of the places where the patients live (Cohn[3]), it being assumed that these places are prone to be dirty and the inmates will always be more or less crowded. Accidental conveyance to the eye of a cleanly and healthy person by the secretion is of course possible. On the other hand, the large proportion of chronic cases, of whatever variety, do not communicate the disease to others, because the quantity of secretion is a minimum. A single person in a cleanly household does not spread the disease, and if there be several patients its extension may be prevented by strict care and attention to hygiene.

It has been stated that numerous micro-organisms are found in the secretion, and they are of many varieties, sometimes including even the gonococcus, while the usual pus-producing organisms and the streptococcus can always be detected. This fact explains easily the rapid and insidious extension of the disease in suitable localities and among susceptible persons, and does away with the

[1] Annales d'Oculistique, t. cv., Jan. Fev., 1891, p. 22.
[2] Annales d'Oculistique, t. cvi., Aout, 1891, p. 81.
[3] Lehrbuch der Hygiene des Auges, p. 139, 1891.

Digitized by the Osler Library

mystery which has seemed to conceal its mode of propagation, because the air as well as numerous recognizable agencies become the ready means of transmission. Yet another supposed possibility of contagion is to be mentioned, viz., a micro-organism peculiar to and residing in the follicles of trachoma, a coccus first described by Sattler[1] in 1882, and by Michel,[2] 1885. It is a diplococcus smaller than the gonococcus and appears in groups like sarcinæ. Some observers have confirmed this discovery, while not a few deny that its culture can give rise to trachoma. Contrary opinions yet prevail, but the belief in the important influence of micro-organisms is universal, because antiseptic treatment has become so efficient and widespread.

We have now given an account of the disease in its general features, and we must set forth its *subdivisions.* We designate them from a clinical standpoint, and in so doing point out the conspicuous features of each variety, admitting that sharp divisions are impossible because one type shades into another, and this is true not only in external appearance, but in course of development, and in pathological anatomy. We may speak of: 1, *Papillary trachoma;* 2, *Acute trachoma;* 3, *Follicular conjunctivitis, follicular trachoma, folliculosis;* 4, *Chronic trachoma;* 5, *Sequelæ.*

(1) *Papillary trachoma* or *chronic blenorrhœa* presents itself under two phases. The first is a condition of velvety hypertrophy of the palpebral conjunctiva with moderate injection and no secretion, and not thick enough to conceal entirely the normal yellow tint of the tarsus. It is the outcome of mild but chronic conjunctivitis; no granules are ever to be found; the papillæ are very fine and short. The second phase exhibits greater thickening, resembling plush rather than closely shaven velvet—the papillæ completely conceal the color of the tarsus, they stand thick and high, may present clefts and prominences; the whole tarsal surface and the fornices are involved; the semi-lunar fold and the ocular conjunctiva are injected and more or less swollen. There is constant, perhaps copious secretion with photophobia, erosions of the corneal epithelium, vascularity at the limbus. The condition follows acute, usually purulent conjunctivitis, and has been strenuously separated from "true trachoma" because the fibrous degeneration rarely occurs. Nevertheless the follicles are to be found imbedded in the tissue, although not visible during the distinctive papillary period and perhaps never seen by the physician. The cornea may be superficially hazy, but eventually clears up if proper treatment is used.

(2) *Acute trachoma,* a condition in which there is great swelling

[1] Archives of Ophth., xv., 452, 1886.

[2] Bericht der Congress Heidelberg, 1882.

Digitized by Google

of the whole thickness of the lids, great hypertrophy of the conjunctiva, which comes on rapidly, accompanied by severe pain, heat, injection of the ocular conjunctiva and discharge of an almost purely watery quality. Eversion of the lids is difficult, and the palpebral conjunctiva has a dotted look, is intensely red and shiny, and does not exhibit special papillary prominences or trachoma granules. After the subsidence of the acute symptoms, viz., in from one to three weeks, trachoma granules and moderate papillary hypertrophy will be seen. This condition is not very liable to cicatricial degeneration, and the cornea usually escapes. It is sometimes evidently dependent upon an acute exacerbation of hypertrophic nasal catarrh. It may begin without previous conscious trouble, it may come as an exacerbation of chronic trachoma, especially in lymphatic subjects. It passes into the chronic type as the acute symptoms decline.

(3) *Follicular Trachoma—Folliculosis.*—The subject is usually young, apt to be of lymphatic temperament. For some time has been unable to use eyes with comfort, either one or both. The lids droop, perhaps seem swollen; no redness of ocular conjunctiva, but it is moist. There is moderate sticky secretion. The patient shuns the light, is much irritated by wind and dust, but has no pain; cornea clear. The lids are easily everted, and if pains be taken to unfold the fornices (see p. 310) a most striking picture is sometimes displayed. We find the tarsal surfaces dotted with small seed-like bodies, semi-transparent, perhaps as large as hemp-seeds; they lie in and upon the pale pinkish-gray membrane, and as we pass to the folds of reflection they increase greatly, perhaps enormously in number, crowding forward in great, succulent, gelatinous-looking masses. The conjunctiva at the culs-de-sac is pale, yellowish-pink, but thrown into transverse ridges. The conditions vary in intensity, but it is not rare to meet a case of prodigious redundancy of follicular masses of which no serious complaint had been made and accompanied by no important symptoms. The condition has developed slowly, is slow to disappear except by surgical treatment. It may pass over into the usual phase of chronic trachoma with fibrous tissue formation (Raehlmann,[1] Reich [2]), but this issue is not frequent; nevertheless, the attested fact proves the cousinship of the disease. The cornea is not affected unless the case be neglected. It yields readily to proper treatment. By some writers this condition is regarded as standing apart from trachoma. The evidence of recent investigations, clinical and pathological, is in favor of its kinship, although it is far less serious than chronic trachoma.

[1] Graefe's Archiv, xxix., 2, 73, 1882; also, Wiener med. Wochenschrift, 41, 1890.

[2] Nagel's Jahresbericht, p. 283, 1889.

Digitized by the Boston Medical Library

(4) *Chronic or Mixed Trachoma.*—We meet with extremely different degrees of this condition—the characteristic of all being the presence in varying quantities at some period of their duration of the trachoma follicles, or, as it is also called, of *lymphoid* infiltration. We classify the different degrees into the following:

(*a*) Isolated deposits of granules with little or no thickening of the conjunctiva. These are found almost exclusively in the folds of reflection; they may be single or in groups. They cause slight or sometimes no irritation and no secretion. Frequently no history of either previous or present inflammation can be elicited. Yet it may have occurred.

(*b*) Lymphoid infiltration disseminated in granules, or forming a ridge at the orbital margin of the tarsus, and sometimes presenting also thick deposits in the culs-de-sac and accompanied by thickening and more or less papillary hypertrophy of the conjunctiva. This condition is most pronounced in the upper lid, while the lower may not escape. The ocular conjunctiva is very rarely implicated. There is little secretion, but there may be lachrymation; the amount depends on the activity of the attendant inflammatory action—it may be almost wanting. There will be photophobia, and to an intense degree, if the cornea have become vascular. Serious implication of the cornea is the tendency of the lesion. Occasionally lymphoid infiltration occurs in its substance. The diversified appearances of the palpebral conjunctiva cannot be fully described. One must imagine a very great variety of possible pictures, both in quantity and distribution of the infiltration. After a certain duration, with or without abatement of thickening grayish lines of fibrous tissue make their appearance; they form a mesh, and patches, and sometimes hard masses of lymphoid substance are left projecting above intervening spaces of dense and shrunken conjunctiva. The shrinking after development of fibrous tissue sometimes affects the membrane uniformly and leaves a glazed, red surface or a patchy piebald mixture of red and yellowish spots, with a concave tarsus which has shrivelled in breadth and length, sometimes reduced to a solid ridge. Meanwhile the folds of reflection have been shortened or possibly obliterated and the conjunctiva may spring out into vertical ridges when the lid is everted. The degenerative process in the final stages reduces the conjunctiva to a dry cuticular membrane, *xerosis*. Reference has already been made to the possible damage which may be entailed upon the cornea, and this feature commands the constant vigilance of the physician. Without dwelling on the desperately bad conditions which are possible, it must be emphasized that haziness of an apparently unimportant degree will sadly reduce vision, so that $V=\frac{1}{10}$ may be considered fortunate, while to the naked eye

Digitized by the Internet Archive

the corneal tissue is pretty clear. Add to this the depreciation due to change of curve under the softening tendencies of the process and the pressure of the lids, and we find irregularities which defy correction by any glasses. I have recently seen a patient, observed twelve years ago, who requires cylinders −20.D at oblique axes, and gains vision of 0.2 in one eye and 0.05 in the other. She is now forty-five and dates the lesion to her childhood. She is on the whole fortunate.

(*c*) Still another phase of chronic trachoma is that in which enormous hypertrophy of the palpebral conjunctiva takes place, increasing to a uniform thickness of 5 to 7 mm., as I have often witnessed. There is marked ptosis; eversion is very difficult, for the tissue is hard and brawny; the conjunctiva when exposed is smooth and glazed and very red; there are no granules visible, or they are deeply set and scarcely discernible. I have known such cases looked upon as amyloid or tuberculous, or syphilitic. In fact, a condition called hyaline degeneration of the conjunctiva has been described by Raehlmann and by Kansocki and Vossius.[1] It corresponds very closely to the sketch above given; the pathological examination does not exclude the possibility of its origin in trachoma.

The duration of cases of chronic trachoma may be months and years, perhaps a score of them. Much depends on the attention bestowed and the wisdom of this attention. Too often patients lose heart and cease trying to get well, or their exigencies compel them to turn to work as soon as matters begin to mend. Hence with increasing trachoma they are liable to relapses and continue to be the patrons of public clinics for long years or decades.

Results and Sequelæ.—Under this title is included what we ordinarily mean by *prognosis* and considerable more. It has already been stated that the milder types may under suitable handling be fully controlled without injury to sight and with no important changes in the conjunctiva. The time required will vary from one to several months. With the softer and more papillomatous varieties, provided lymphoid infiltration be not great, and including some cases of true trachoma, the same good result may be achieved, only after a longer fight. I may call attention to a condition which I have never seen mentioned, presented at the very late stage of the cases now considered when most of the hypertrophy has been removed. In the pockets and clefts of the tissue, and to some degree imbedded in it, I have sometimes seen white specks of soft molecular substance, suggesting calcareous matter but probably mere detritus of degenerated cells, which keep up troublesome irritation. Under cocaine they may be picked out with a cataract

[1] Bericht Ophth. Gesell., Heidelberg, 1889, pp. 108, 114.

Digitized by Google

needle, and after two or three sittings the irritation has been entirely removed. The result of the disease, too often aggravated by heroic treatment, is in severe cases the development in the conjunctiva of connective tissue to excessive amount, altering its texture and impairing its secreting functions. The more moderate cases exhibit smooth red patches or lines, or a satiny surface; a higher grade is indicated by frœna and ridges at the folds of reflection; beyond this stadium the fornix becomes shallow and loses its loose texture in a smooth scar surface, and the last stage is *xerosis* with posterior symblepharon, and the ocular conjunctiva is reduced to the same cuticular condition, while the cornea has become dry and densely opaque.

The connective-tissue growth and resultant contraction enters also into the tarsus, thickening it, bending it inward, and causing the free border to press against the cornea, and on eversion exhibits a furrow along its whole length about 4 or 5 mm. from its edge. The deformity in extreme cases reduces the tarsus to a thick cord which shows a ridge on the exterior surface of the lid and at the same time causes shortening of the palpebral fissure and partial ptosis. Coincident with these changes the numerous glands and follicles of the lid border and tarsus become obstructed, atrophied, obliterated, and in the hair follicles the effect is loss of cilia, trichiasis, and entropium.

It is superfluous to dwell on the mischief wrought upon the cornea, because this is obvious, and it has been already more than once referred to. To prevent it, to mitigate it, to cure it is the great end of our treatment, and our success in this particular is the gauge of the wisdom of our method and the value of our remedies. To shorten the duration of the malady is a great desideratum, but to protect or restore or to save as much sight as possible is of course infinitely more important.

Pathological Anatomy.—Much has been written on this topic, and the chief authorities of the last ten years are Raehlmann, Reich, Sattler, Michel, Noiszewski,[1] Mutermilch,[2] and Reid.[3] For more authorities consult Cohn, "Hygiene des Auges," p. 780. As to the trachoma coccus, about which something has already been said (see p. 340), the last word is to the effect that the described organism does not have the specific qualities ascribed to it, but that the generative cause of trachoma is a vegetable fungus called microsporon trachomatosum s. Jagium, which bears very close analogy to the microsporon furfur, which is the cause of Pityriasis versicolor, and can be seen by a low magnifying power (Noiszewski, l. c.).

[1] Centralblatt f. Augenheil, March, 1891.
[2] Annal. d'Oculistique, Oct., 1891, and May, 1892.
[3] Trans. Oph. Soc. United King., x., 1890, p. 57, with plates.

Digitized by Illinois College of Optometry

The author declares that he has produced trachoma by pure cultures of this fungus in calves and rabbits. Dr. German has traced three cases of acute trachoma to the poisonous effect of the soil which entered the eyes. The patients were farm laborers and with dirty hands and clothing easily infected themselves (*St. Petersburg med. Wochensch.*, 1890, 29). Evidently the end of this investigation is not yet.

Almost all authorities have bent their attention upon the trachoma follicles and their various appearances as the typical elements of the disease, and have classified cases accordingly. What gives birth to them has not been clearly set forth, and little interest attaches to the shades of difference which follicles from follicular trachoma or from chronic trachoma exhibit. They consist of lymphoid cells, some within, dead and shrivelled, others without, living and active, enveloped in a capsule of adenoid tissue, and the mass penetrated by connective tissue, fibres and blood-vessels. The

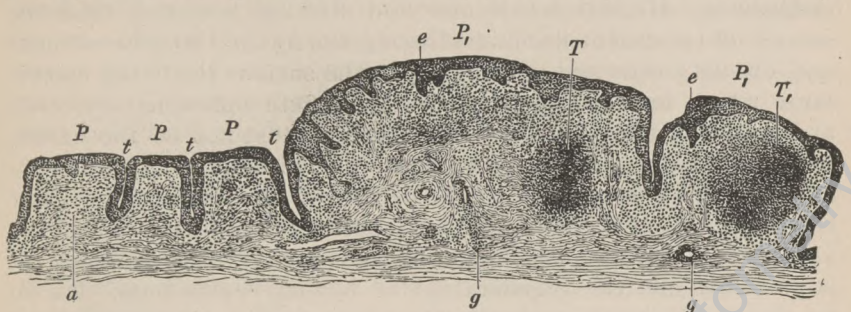

FIG. 132.

interior of the glomerule undergoes further degeneration by either hardening or liquefaction, and the capsule is thick or thin according to age and natural abundance of adenoid tissue. There are also numerous papillæ, covered with a thick layer of epithelium in various stages of proliferation. As they are crowded together, are ulcerated, and adhere more or less perfectly, pockets and clefts and tubules lined by epithelium are produced, and sometimes cystoid cavities are developed. The epithelium easily breaks down and by its metamorphosis gives rise to goblet cells which undergo various regressive changes, and the epithelium may assume a stellate form after its nuclei have become vacuolated. Combine with this the development of connective tissue and the presence of a large amount of adenoid tissue, and the picture as usually given is complete.

To the above nothing would be added but for the fact that a paper by Mutermilch (l. c., 1891–92) describes an investigation beginning with the earliest phases of conjunctivitis and tracing the

Digitized by Illinois College of Optometry

process step by step to the various manifestations of trachoma, and shows how follicles, papillæ, epithelial degenerations, fibrous tissue, etc., make their appearance: it shows up the whole panorama. It is a study in pathogenesis as well as in pathology. It were too long to attempt to reproduce this most masterly description even greatly condensed. This may be stated: he traces all the morbid changes to the epithelium and its alterations. Of it he gives a careful description with its superficial mucous corpuscles and its deep layers which send fine processes into the subjacent adenoid tissue, which is a cellular tissue infiltrated by lymphatic cells. Describing what transpires with ordinary chronic and acute inflammation, he finds the follicles an accidental production dependent on the amount of adenoid substance and the quantity of lymphoid infiltration. He shows how the papillæ appear, and the various phases with which we are familiar. But the dominating and novel feature of his exposition is the importance given to the rôle of the epithelium. He makes this new and striking assertion, that the success of treatment lies in destroying the hyaline lacquer of fused and obsolete cells and in bringing to the surface the living epithelium which has been buried beneath effete inflammatory cells and material, and therefore our remedies must not be too harsh. Moreover that *pannus* appears when the epithelium has been destroyed, and corresponds to the degree of its destruction. That the roughness of the palpebral conjunctiva is not its cause, but the absence of living epithelium. Moreover that disappearance of pannus attends the regeneration of healthy epithelium. As to trachoma follicles, he traces in them the effect of a low vitality of constitution with imperfect oxygenation as the predisposing cause why lymphoid cells exuded in inflammatory action cannot maintain their activity, are soon devitalized and incapable of amœboid movements, and become grouped into globules by the mechanical influence of the loose adenoid cellular tissue beneath the epithelium. Such enfeebled cells undergo regressive changes and absorption and may quite disappear, but if in large masses they form the beginnings of the future follicles. It is inexpedient to go extensively into this fascinating exposition, but the writer finds no essential difference between the follicles of follicular trachoma and those of the more chronic malady. He recognizes that when formed and solidified they become foreign bodies liable to provoke irritation, and while themselves the product of an arrested or imperfectly resolved inflammation they may be the exciting cause of persistent or renewed inflammation. He also makes clear how the inflammatory products of acute trachoma and of the occasional enormous hypertrophic forms of hyaline material are not anomalous but are in accord with the usual phenomena of inflammation. He makes

Digitized by the Osler Library, McGill University

it reasonably clear that granular trachoma is no strange exception in pathology, but simply a special appearance due to special local conditions of tissue and interesting because easily observed.

Prophylaxis.—A few words are needful as to the measures to protect the healthy from infection, and to put the diseased in the best conditions for recovery. We face this requirement in families, in orphanages, barracks, and places where many persons congregate under unfavorable hygienic conditions. It will be remembered that the conspicuously dangerous element is the secretion —that this contains numerous pernicious germs, that the air may be foul with them and the walls and clothing may be tainted by them. Hence the rigor of precautionary measures will be in direct ratio to the number of affected persons. In crowded institutions the inmates may have to be scattered, or put into tents, or assigned to other and larger quarters. In schools the pitiful meagreness of the toilet economy, the few and numerously used wash-basins, the vile roller-towel, and other easily imagined vehicles of filth like rags and handkerchiefs and fingers, *et id genus omne*, must be thoroughly and peremptorily destroyed, abolished, or purified. Cleanliness, proper air space, sleeping-rooms healthful and well ventilated, good nutrition, out-door life, plenty of water, reasonable separation or even isolation are the prime requisites. Next to these come antiseptic lotions, of boric acid, corrosive sublimate, and permanganate of potash (see Cohn, l. c., p. 139).

Treatment.—For the sake of convenience we shall depart from the order observed in describing trachoma and begin with the acute conditions. We consider attacks of *primary acute trachoma* and the *acute aggravations* which may take place during chronic trachoma.

If there be acute pain and photophobia, more or less swelling, the ocular conjunctiva injected and possibly vascularity with or without ulceration of the cornea, we must employ atropia, cocaine, and cold lotions vigorously. The pupil must be kept dilated; anodynes may be required. It is always best to use an antiseptic, and while boric acid has value, corrosive sublimate, 1 to 2,000 to 1 to 5,000, is most worthy of favor (the old *lotio flava* of sol. corrosive sublimate and lime-water is nowadays fully justified). Scarifications of the conjunctiva may be serviceable. Frequently the aggravated situation depends on the bad (strumous) condition of the patient. The best hygienic surroundings and confinement to bed are necessary. The scratching sensations may be mitigated by free use of vaseline under the lids. If the secretions are copious and watery, medicated applications avail little; so soon as a mucopurulent material appears, sol. nit. arg., gr. v. vel. x. ad ℥j., may be tried, but with caution. It is always imprudent to employ irri-

Digitized by Google

tating proceedings during an acute inflammatory stage. It may require from three days to three weeks for this period to pass. It is imperative to keep the pupil dilated, and a 4% solution of cocaine muriate has useful effects in relieving pain, causing the vessels to shrink, and in reducing tension. Hippel and Sattler recommend sol. corrosive sublimate, 1 to 1,000, applied with a brush to the lid, as soon as any granular prominences appear. It is to be tried with caution, and though painful does prove remarkably useful. If an acute attack supervene during the chronic period, we must abandon the usual remedies of nitrate of silver and sulphate of copper, and endeavor to find out the cause of the outbreak, which may be found in a severe nasal catarrh or in a depreciated state of health. If the former exist, sol. nit. arg., gr. xx. or xl. ad ℥ i., or in less acute conditions chromic acid inside the nares will help us. For the low health, food, change of scene, tonics, cod-liver oil, iron, fresh air, regulated baths will be our reliance. As to the local treatment, what has been said above need not be repeated.

Papillary trachoma requires moderation in treatment; touching the lids lightly once a day with a crystal of sulphate of copper or alum, with solutions of tannin and glycerin (gr. x.–xxx. ad ℥ i.), or with a solution of nitrate of silver (gr. v. ad ℥ i.). The patient, if unable to see a physician, may himself make use of an ointment consisting of three grains of sulphate of copper to the ounce of vaseline. As the parts become accustomed to one remedy, another must be substituted. Patients may often be provided with astringent washes of alum, of boric acid with sulphate of zinc, and, if no corneal complication exists, of sugar of lead. Powdered boric acid may be dusted on the everted lid.

It must be added that for even this class of cases one may make trial of the solutions of corrosive sublimate, 1 to 1,000 *plus or minus*, believing that this potent remedy will do for them what it has so signally done for other cases to be presently related.

Follicular Trachoma.—The annoying secretion may be washed away by lotions of boric acid 3%, or of acetate of lead 1%. But there is no reason to lose time on such merely palliative methods. The effective treatment is to destroy and squeeze out the follicles, whether they are in isolated masses or in such exuberance as to resemble the everted rectum of the horse during defecation. Since this method was proposed, I have practised it with much success and to the exclusion of every other proceeding. The patient lies on his back. I use two forceps (see Fig. 133), one in each hand, and having thoroughly cocainized the surface by a pledget of cotton soaked in 10% solution, evert the lid and hold one end of the tarsus with one forceps and applying the other, pull against the first, thus squeezing and stripping out the granules (see Fig. 134). The for-

Digitized by Google Original from Columbia University

ceps enable one to pick up the deepest parts of the membrane, and the line of demarcation between ocular and orbital conjunctiva is usually well marked. I have seen the follicles on the ocular membrane. Bleeding is rather free and must be wiped away with cotton and by drenching with sol. sublimate, 1 to 3,000. All the morbid material can be removed at one sitting.

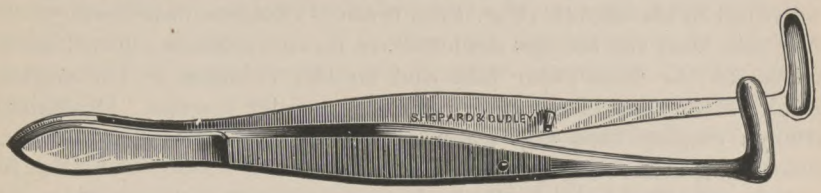

FIG. 133.

Some and occasionally smart reaction occurs, requiring cold lotions. This subsides in a few days. For a certain period applications of nitrate of silver, gr. ij.–v. ad ℥ i., will be made once a day or every second day and simple lotions employed. Some cases are perfectly cured in ten days; others require a month, according to the severity of the case. I have occasionally seen reproduction of the follicles requiring repetition of the operation.

Efficient and truly curative treatment consists in excision of

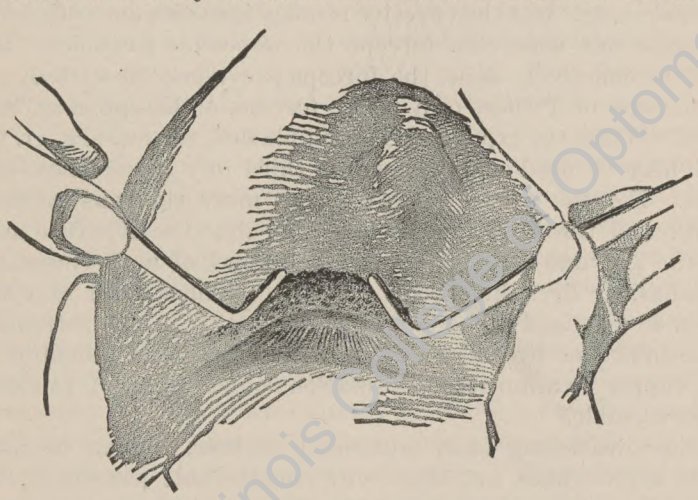

FIG. 134.

the redundant folds at the cul-de-sac. For many years I have, in selected cases, done this, and fully recognized the importance of not doing it to excess, and of careful judgment in the selection of cases. I strongly deprecate resort to such a method in ordinary cases, but for some it is adapted. Galezowski has followed this

Digitized by Illinois College of Optometry

practice. It is only when the folds are very loose that excision is proper. It may be done with forceps and scissors, leaving sufficient tissue not to restrain free movements of the conjunctiva after cicatrization shall have occurred. It is also important not to go so deep as to damage the thin expanding tendon of the levator. The effectiveness of the squeezing process, of which the method is indicated in the sketch (Fig. 134), renders excision unnecessary. I may add that the forceps depicted are more workable and will give access to the semi-lunar fold and to the recesses at the angles much better than either ring forceps or a roller forceps. One must always employ two and often give an anæsthetic, because the proceeding is severely painful.

Chronic Trachoma.—We have to consider first the simple condition where isolated granules or groups of them lie imbedded in an apparently normal membrane, or we may have the case of an old trachoma with a few hard and red deposits lying like boulders on a devastated plain where the fury of a fire has been spent. To both these classes of cases similar treatment is suitable. In the former instance there may be no history of previous trouble, in the latter there has been a long-standing lesion of which the existing status is the remnant. In this the slight irritation will be soothed by lotions of boric acid 3%, or of sublimate, 1 to 10,000, or potass chlorat. 2%. But the effective remedy is to pick out with a needle or squeeze out with cilia forceps the imbedded granules. If this cannot be effectively done, the forceps previously described, or the ring forceps of Prince, or a roller forceps of Knapp may be employed. When the expulsion is accomplished, sol. nit. arg. gr. ij.–iij. ad ℥ i. may be used every second or third day in addition to the lotions. For the second class of cases more rigorous means are needful, and the best success is by burning the separate masses with the galvano-cautery, or the fine point of a thermo-cautery (Paquelin), or by a hot needle. With cocaine several may be destroyed at once and all at two or three sittings. After-treatment will be indicated by the conditions—perhaps light touching with sulph. copper or alum stick, or solutions of sublimate, 1 to 3,000, as may be suitable.

Before discussing local treatment further, it must be insisted on that severe cases, *i.e.*, those with considerable pannus or thickening of the conjunctiva, with hyperæmia of the bulbar membrane, with acute photophobia and lachrymation, cannot be successfully dealt with unless placed in good hygienic conditions. They need protection from wind, dust, smoke, and bad air. They may have to go to hospitals, but the utmost pains must then be taken to secure free ventilation, good food, and absolute cleanliness in hands and person, clothing, utensils, habits, and surroundings. When

Digitized by the Boston College of Optometry

such conditions are fulfilled, and they are difficult to fully realize both in hospitals and in the houses of the poor, the battle is half won. Frequently a patient must stay in bed a good part of the day to permit the continuous fomentations; but sufficient exercise must be given to secure good digestion and assimilation. Sometimes with absolutely perfect hygienic conditions the disease assumes an acute type, and then we have to contend with a feeble or strumous constitution. It is very rare for trachoma to develop acute and obstinate forms among healthy persons in healthy conditions.

Next we discuss the cases of *chronic* or *mixed trachoma.* The hitherto established treatment consists in sol. nit. arg., gr. v.–x. ad ℥ i., every second or third day to the everted lids, if possible reaching the retro-tarsal folds, or the more painful sulphate of copper in crystal, or for mild cases the daily use of a crystal of alum. By some the yellow oxide of mercury ointment, gr. v. ad ʒ i., or powdered boric acid is rubbed on the everted lid with the finger: tannin and glycerine, gr. xx. ad ℥ i. or stronger, is employed during the late stage when cicatrization and patches of hyperæmia appear. As a lotion, to be used several times daily, nothing equals sol. corrosive sublimate, 1 to 3,000, *pro re nata.* Under the plan thus sketched cases get well after many months, with liabilities to acute exacerbation and prolongation of the disease for years. Because the poor are the usual victims, their necessities compel them to omit treatment as soon as they can return to work. Soon they present themselves again, and the process must be begun *de novo.*

In view of the obstinacy of the malady, and the conviction that its malign character is found in the presence of micro-organisms which provoke cell growths and other changes, and guided by the beneficent effect of corrosive sublimate in collyrium, a vigorous and effective employment of this remedy has of late years been widely adopted. In strong solution, 1 to 500, it is painful and caustic. This has been used in France and Italy after cocaine anæsthesia, once and even three times daily to the everted lid, while a solution, 1 to 120 (Arnaut's), has been twice a week employed. Von Hippel, whose judgment and experience are worthy of respect, reports good results in 300 cases, by vigorously rubbing the surface with sublimate sol., 1 to 2,000, once daily by a mop of cotton. The severity of the friction is proportioned to the density of the tissue—if soft and much swollen it will be light, if hard and the follicles firm it will be energetic. The endeavor is to rub out the contents of the follicles and the lymphoid infiltration. In some cases of diffused thickening and infiltration this is impracticable, but even in them the treatment is greatly effective. Cocaine is needful, but on repetition the treatment is less painful than at first. With hyperæmic and soft tissues

Digitized by Illinois College of Optometry

the reaction may be sharp and require cold lotions for several hours. On the following day there will be a thin layer of gray exudation, which is easily removed, and the proceeding may be renewed every day during the first week. In old cases with beginning atrophy exudation does not appear. Pannus and slight erosions of the cornea respond favorably, unless the conditions are severe or there be co-existing iritis. Heisrath, commenting on this treatment, reported good results, but stated that he had seen instances where the healthy cornea became ulcerated and infiltrated (Berlin. Klin. Wochensch., 1891, No. 5). When the follicles disappear treatment of the chronic catarrh which remains "requires lotions of acetate of lead, 1 %, and discontinuance of the rubbing." Some caution must be given as to the use of lead lotions at any period of such cases. Alum or weaker sublimate solution or boric acid will be safer, and sol. nit. arg., 1 %, or light use of copper will be proper. Von Hippel does not make extraordinary claims for this treatment, but holds it superior to our old methods, and in this he is supported by others. To his statements[1] so much space has been given because his experience leads up to another plan which embodies the same ideas and which has been practised and witnessed by myself extensively during the past year.

The fundamental ideas are to get rid of the follicles and lymphoid infiltration, to apply sublimate solution in effective but not destructive strength, to avoid such violence either mechanical or medicinal as will provoke development of fibrous tissue; when the follicles have disappeared to treat the case as one of chronic conjunctivitis. Severe reaction, if present in the cornea, must first be made to subside and must not be excited by treatment. Especially must iritis be respected and brought under control by atropia, and all irritants until then be avoided.

The removal of the follicles is best done by the two pairs of forceps referred to on p. 348. I find them superior in most cases to roller forceps. But if the tissue be somewhat firm and the lymphoid infiltration cannot be sufficiently expressed, a more heroic method is practised, which was first instituted in Abadies clinique in Paris. An anæsthetic is given; the lid is rolled completely outward by a small pair of dressing forceps. (A special forceps has been contrived by Dr. Gibson which is of decided advantage in not cutting the edge of the lid and in securing full control—Fig. 135). The fornix is fully exposed and the membrane lightly incised by a three-bladed scarificator in parallel lines about 2 mm. apart. With a rather soft tooth-brush the corrosive sublimate, 1 to 500, is rubbed into the lid and the bleeding checked by wads of cotton dipped in the same solution. The epithelium is of course considerably de-

[1] Bericht Ophth. Gesell., Heidelberg, 1892, p. 91.

Digitized by Google

stroyed and wiped away, but one must not deal harshly with the tissue. The depth of the scarifications, their number, and the vigor of the brushing must be in proportion to the induration and thickness of the structures. The eyes will be covered with cotton soaked in the same solution and bandaged firmly for a few hours to prevent undue swelling. In a markedly lymphatic patient reaction will be severe. There is always considerable secretion the next day and the surface will be covered with a gray pellicle. Some swelling will occur and cold lotions be necessary. Sublimate solution, 1 to 500, will be applied daily to the everted lids by a little mop, taking care to reach the fornix and prevent formation of adhesions. If severe reaction contra-indicate the sublimate, the manipulation will not be omitted. A patient will remain in hospital about a week, less or more.

As already intimated, the cases suitable for the above proceeding (*"grattage"*) are those in whom squeezing by forceps cannot sufficiently remove the lymphoid infiltration because it is buried amid great general thickening, which also prevents the effective contact of the sublimate with the tissue. Experience has shown

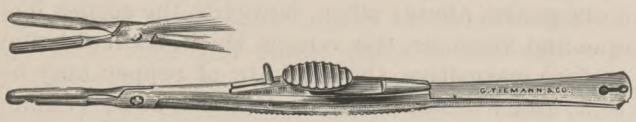

FIG. 135.

that while a rapid removal of the granular thickening is effected and the hazy cornea clears up, there is a tendency to production of connective tissue which may easily induce unpleasant deformity of the lids, causing bridles, ridges, and degrees of symblepharon. In numerous instances it has been found that the superior fornix, six months after a judiciously mild grattage, has been obliterated. This condition may not be important, but one must not let zeal for a rapid cure run into rashness which may occasion deformity. Such cautions seem needful lest enthusiasm in behalf of a valuable method of treatment overstep the limits of prudence. In public institutions where children are assembled there is especial fitness in the sublimate treatment, and it soon establishes a practically aseptic condition among the patients which is the great desideratum. It is also to be remembered that steady treatment must be continued by usual remedies for weeks after the first favorable impression by squeezing or sublimate, or both, has been made.

Cases of less duration and severity, and especially such as consist largely of papillary hypertrophy, do well enough under the nitrate of silver gr. v.–x. ad ʒ i., where there is decided secretion,

Digitized by the Internet Archive in 2007 with funding from Microsoft Corporation

or sulphate of copper where there is little of it, but the present tendency is to use sublimate solutions in all cases for which mechanical means are not indicated. My most recent experience favors solutions of sublimate 1 to 600 or 1 to 1,200 rubbed upon the lid with a small cotton mop daily or once in two or three days, in moderate cases, as the most satisfactory proceeding. "Grattage" will be reserved for the more obstinate. In them a canthotomy is often requisite to sufficiently expose the field of operation. A repetition of squeezing or sometimes of grattage may be necessary. In former days cantholysis was often employed to help alleviate the corneal lesion; we now resort to it only when deformity of the lids, "phimosis," indicates its necessity. It will be referred to later.

I have in a few cases of extreme and general thickening of the conjunctiva used the Paquelin thermo-cautery once in ten days or two weeks and with considerable vigor. It has served me well, and the subsequent fibroid degeneration was not excessive, although it was considerable. The cases were exceptionally severe, and the remarkable feature was the moderate reaction after extensive burning.

As the thickening of the conjunctiva subsides, the corneal trouble will, *pari passu*, abate; when, however, the cornea has become very opaque and vascular, the vessels thick, the epithelium dense and the surface insensitive, the sulphate of copper may be applied directly to it, and with advantage. Excision of the conjunctiva for the breadth of one-fourth of an inch around the entire circumference of the cornea has been employed under the name of *peritomy*, and has been of some service, but it is far less resorted to now than in former days. Curetting the corneal surface by a small knife has been done by Dr. Gruening, and with improvement and little reaction (see Trans. Am. Oph. Soc., 1889).

In these extreme cases, and also in cases less severe, improvement of vision has been sought for, especially in Belgium, by resorting to inoculation with blennorrhœal pus. In doing this an acute purulent conjunctivitis is set up which is left to run its course with but little interference, occupying from four to six weeks, and in some cases valuable improvement in the cornea has been obtained; there is, however, always risk of the destruction of the cornea and of sight. This proceeding is at the present time little employed.

Within a few years an infusion of the jequirity bean, a Brazilian plant, *abrus precatorius*, has been extensively employed in treating not only the advanced and extreme cases of granular lids, but all forms of the disease. Brought to notice by Wecker, of Paris, in 1882, it has had large trial, and experience up to the present time seems to show that its chief value is during the later stages and when the cornea has become seriously vascular. The bean is to be

Digitized by the Internet Archive

powdered and macerated for three hours in water of the ordinary temperature in the concentration of about 3% (Wecker).[1] The infusion when old is not as effective as when recent. With a brush it is applied two or three times to the lids; within twenty-four hours reaction should appear; if it do not, the application may be repeated. The mucous surface becomes covered with a grayish membrane which adheres for days. The lids swell, copious secretion occurs and the cornea is apt to become very hazy. The patients suffer pain, and iced water is to be freely employed. The inflammation will run for two weeks or more, and in favorable cases not only does the cornea clear up, but the conjunctiva recovers a much more healthy appearance and old cicatrices become softened. The secretions from this inflammation are not contagious.

The active principle of the plant is called *abrine* and is regarded as a ferment; there is no specific microscopic germ associated with it.

A patient who has once been treated by jequirity, though less susceptible, may be again brought under its influence. If it be employed in unsuitable cases, or with too great freedom, suppurative inflammation or even destruction of the eye may follow. The remedy is to be used with safety only in inveterate cases where other remedies have failed and where vision is seriously impaired. Its non-contagiousness permits its use when one eye only is affected. It is never right to inoculate both eyes at once. Coppez, who treats in Belgium a great many cases of trachoma, sometimes uses the infusion as strong as 10%. But the cases must be extremely severe and unyielding to warrant the proceeding. Similarly the jequirity infusion is employed in so-called scrofulous pannus of the cornea not caused by granular lids, and also in sclerosed conditions of the cornea after parenchymatous keratitis. It has been tried to a limited extent in torpid ulcers, but not with advantage.

It is imperative to know that for cases of simple chronic blennorrhœa, or chronic conjunctivitis, its use is contraindicated, because it is likely to do serious mischief. So, too, in recent trachoma with succulent hypertrophy and moderate secretion it is not a safe remedy. When the conjunctiva is hard, nodular, or cicatricial and the cornea decidedly opaque, it becomes a useful agent. It is employed by some surgeons (Roosa, Cheatham: see also Widmark, "Beiträge zur Ophth.," Inaug. Diss., 1884–1891) at the present time, but it is far less in vogue than five years ago. It sets up a very uncomfortable reaction and threatening appearances. The methods previously described are in my esteem to be preferred.

In summing up the treatment, while old and well-established

[1] Others have used a smaller quantity, say one bean to an ounce of water and infused for twenty-four hours.

Digitized by the Boston Medical Library

principles and methods have been reiterated, certain new proceedings are set forth, viz., the squeezing by forceps of flabby, gelatinous, extremely redundant masses of granules; exceptionally they may be excised; the picking out the contents of the granules with a broad needle, scraping the tarsal conjunctiva with a sharp curette or by a fine rake so as to get rid of moderate prominences.

The same effect is attained by touching the granules with a hot needle. For large masses, whether left as isolated projections in old cases or occurring as general and extreme hypertrophy, a more decided use of the actual cautery is proper, viz., the thermo-cautery of Paquelin. For this and sometimes for the use of the forceps an anæsthetic as well as cocaine will be needful. (Mem. Ether is inflammable, chloroform is not.)

For chronic cases, grattage, with or without expression and canthotomy, is a recent valuable resort. Like all surgical methods it demands good judgment. The infusion of jequirity will improve vision in desperate cases, while it, too, demands care and discrimination.

It happens that patients cannot always remain under the hands of the surgeon for the completion of the treatment of this tedious disease, and it becomes advisable to instruct a friend in the manipulation of turning the lids and applying either sol. tannin and glycerin, alum crystal, or the sulphate of copper crystal. In case the patient must depend wholly on himself, he may be supplied with an ointment of sulph. cupri, gr. v.–x., ad vaselinum, ʒ i. The vaseline may in warm weather be stiffened with powdered gum arabic or starch. The usefulness of corrosive sublimate solution will vindicate itself, and an ointment of hydrarg. oxid. flav., gr. x. ad ʒ i., once or twice daily between the lids is well worth trial.

The necessity of remitting active treatment when relapses of inflammation occur, as they may frequently, must not be forgotten, and then warm water and atropine will be the best relief. The use of the latter is often kept up during the continuance of the local stimulants. Sometimes with prominent eyes the lids in the atrophic stage of trachoma are left so shortened as to press disagreeably on the cornea. Canthoplasty may have done all that it can, and the skin operation above described (see p. 278) may not be desirable. In such cases, continual pulling at the skin of the temple, forehead and cheek, a kind of massage, will, in time, loosen the subcutaneous connective tissue and secure some relief.

Xeroma of the conjunctiva, which is the stage of consummate atrophy of the membrane, only admits of palliation by emollients, such as vaseline or olive oil, several times daily. An admirable summary of treatment of trachoma has been published by Sattler, "Die Trachombehandlung einst und jetzt," Berlin, 1891, p. 44.

Digitized by Google

Sequelæ of Granular Conjunctivitis.—The secretory glands become obliterated, the conjunctiva cannot supply the proper amount of fluid, and hence there is an unpleasant dryness and irritation of the lids. By the shrinking of the tissues the hair follicles are distorted, the hairs become few and some or many or all of them may be turned upon the globe. In other words we have trichiasis or entropium. In the latter condition the palpebral fissure is shortened, the lids cannot be sufficiently separated, the tarsi become prominent and are shrivelled into dense ridges. The cornea loses transparency and its curve becomes altered in irregular forms. To the casual observer it may seem normal, but a test of the acuity of vision and the failure of glasses to improve it will show how serious is the mischief. If examined by the ophthalmoscopic mirror (preferably by the plane mirror) or still better by the ophthalmometer of Javal, the corneal irregularity becomes apparent. It may become conical and no satisfactory view with the upright image will be possible.

Treatment of some of the above conditions has already been described when discussing affections of the lids (see Entropium and Trichiasis, etc., pp. 262, 276, 278), and those which concern the cornea will be hereafter referred to. Sometimes during the progress of the treatment of trachoma, the lids become tight or even shortened, the cornea is greatly irritated, and the operations of cantholysis or canthoplasty are resorted to to check the distressing symptoms. A few years ago these proceedings were employed very frequently, but their use is now more limited, yet occasionally suitable. The writer's experience in one extremely bad case for which relief was gained by subcutaneous division of the superior tarsus on its median line may be again referred to (see page 267). To operate during acute symptoms will often aggravate them, while the free use of cocaine and other measures, such as cold lotions, etc., will control the condition.

Partial ptosis is not infrequent. It may be corrected by deep sutures from the orbital margin of the tarsus, carried up under the edge of the orbit by a curved needle, and tying the sutures tight to remain several days. A similar operation might also be done on the conjunctival surface with excision of some of the fornix.

6. *Morbid Growths on the Conjunctiva.*—Under this head are included *syphilitic lesions, tubercular deposits, epithelial, lupoid,* and *cancerous* disease, *amyloid degeneration, cystoid growths, congenital fibrous growths, papillomata,* even a *bony* growth has been observed and *calcarous deposits* occur; we also have *angiomata,* and *pigment* patches.

The *syphilitic* lesions of the conjunctiva occur oftenest in the

Digitized by Illinois College of Optometry

papebral portion, under the form of chancre or of mucous patches. On the bulbar portion gummy tumors have been seen, and while they often include subjacent structures, sometimes their mobility shows that only the conjunctiva is affected. The diagnosis cannot with certainty be made from local appearances, but rests also upon constitutional symptoms. Mucous patches have also been seen on the ocular conjunctiva. In all these lesions it is usual to find swelling of the pre-auricular lymphatic gland of the corresponding side. As has been said, we may have upon the conjunctiva either the primary, the secondary, or the tertiary lesions of syphilis. Cases of this kind are rare, yet they must not be overlooked. Among many contributions to the subject are papers by Bull,[1] and by De Beck[2] in which the literature is extensively quoted.

Local treatment will be the same as would be proper if the lesion were on another locality, save that cauterization of an ulcer must be done so as not to harm the cornea, and the liability of this structure to suffer mischief will modify the proceedings. Soothing applications will be preferred, such as atropia and the milder antiseptics, boric acid, diluted chlorine water, iodoform, etc. The chief dependence will be on constitutional treatment.

Within the last few years attention has been much called to *tubercular* disease of the eye, which may invade any part of it, and has been found in the conjunctiva, both of the lids and of the globe. The tendency of the disease is to attack in its progress deeper structures, and it presents ordinarily an open ulcer, with grayish surface, from which nodules spring up either within its area or upon its margin. The disease more frequently seizes upon the inner than upon the outer structures of the eye primarily, and reference will be made to it again. The chief importance attaches to *diagnosis*, and we have to distinguish tubercular deposit from granuloma and from lupus. The former (granuloma) is a firm, reddish, highly vascular mass of uniform character, and the neighboring lymphatic glands are not swollen. Persons of any age may be affected. A tubercular deposit is a mixture of nodules and ulceration, it involves all the tissues of the part affected, its edges are beset with trachoma-looking masses. In lupus the skin is generally also affected; Arlt, 1863, speaks of two cases in which the disease began on the conjunctiva bulbi, and the eye was attacked by continuity of invasion. In tubercle we find giant cells, and the peculiar bacilli. In lupus we also find bacilli closely resembling those of tubercle, and at the present time the two diseases are coming to be regarded as essentially the same.

[1] "Syphilis of the Conjunctiva," by C. S. Bull, Amer. Journal of Med. Sciences, Oct., 1878, p. 405.

[2] "Hard Chancre of the Eyelids and Conjunctiva," by David DeBeck, Cincinnati, Ohio, 1886. Press of Robert Clarke & Co.

Digitized by the Internet Archive

There is no satisfactory treatment of tubercular deposit in the lids, and if it occur upon the globe, enucleation will be the ultimate resort. The suitableness of operating for tuberculous disease of the lids will depend on the stage of the disease and on the state of the patient. He is usually young. If possible, thorough excision should be done, to guard against general infection. There are numerous cases recorded in literature, but one which is typical and carefully described is by Baumgarten.[1]

Epithelial disease and *lupus* attack the lids quite frequently, beginning at their margin. They may, if neglected, extend to the globe (see Plate VI., Fig. 18, colored illustrations). We also sometimes find an epithelioma as a reddish lobulated mass growing at the limbus corneæ. A tumor of this kind which displayed the characteristic microscopic structure I removed from a man fifty-seven years old, and it has not recurred for nine years. I have also removed a pigmented (melanotic) epithelioma from the same region, and with no recurrence up to the present time. For details of the case and references to the literature, see *Archives of Ophthal. and Otology* for 1879. *Cancerous* ulcerations may attack the ocular conjunctiva. I have notes of such a case.

Sarcoma, either white or pigmented, may also appear, and while removal of the disease without sacrificing the globe is to be preferred, such a course is not always possible. Complete removal is imperative and that will often compel the loss of the globe. *Papilloma* is found at the inner canthus as a favorite site and is easily recognized by its softness, its clefts, and its small pedicle.

In the lesions now considered other organs, such as the lymph glands, the lungs, the liver and other viscera, are to be scrutinized to learn the true meaning of the case.

Cysts sometimes appear beneath the conjunctiva, usually on the globe, sometimes over the caruncle. Their contents are commonly watery, sometimes oily or sebaceous. Young persons are more often the subjects. The sac may grow to hold as much as two drachms of fluid and sometimes it reaches back into the orbit. (The occurrence of true orbital cysts is not meant.) Their walls are usually very thin, and their transparency suggests their character. Greater firmness has, however, been observed. Treatment requires either simple puncture, or besides this a silk seton, or if obstinate, cauterizing the wall with nitrate of silver. See an article by Dr. C. S. Bull.[2]

Fibroid tumors, or more properly *dermoid* growths, appear on the ocular conjunctiva, and especially as a congenital formation.

[1] "Ein Fall von tuberculösen Geschwüren der Lid-Conjunctiva," Graefe's Archives für Ophthal., Bd. xxiv., Abth. iii., S. 225.

[2] "A Study of Sub-conjunctival Serous Cysts," Amer. Journal of Medical Sciences, Jan., 1878, p. 85.

Digitized by the Internet Archive of Ophthalmology

There may be more than one, and there may be stiff hairs growing upon them. A not infrequent condition is to find at the outer angle a dense plate of hard tissue with thick white covering pushing forward from the orbit usually on the temporal side upon the sclera, half-way perhaps to the cornea, with a thin, rounded edge. It is imperfectly movable, but with a rigid base, and resembles to some extent the plica semilunaris of rabbits and sheep. Between it and the cornea may be small hard tumors. This is a congenital malformation. A careful description of such a case and an account of others is given by Hirschberg.[1] A tumor of similar kind was described by Graefe as coming from the orbit between the rectus superior and rectus externus muscles from the superior fornix.

I have notes of the case of a man who had three hard sessile dermoid tumors growing upon the limbus corneæ about equidistant from each other. The outer angle of the lids was tied by a band of fibrous tissue which stretched across it and also adhered to the conjunctiva bulbi. A similar band ran across the inner angle between the lids. These bands were quite dense and prevented the lifting of the lid. The condition was congenital. The other eye was normal.

Tumors like the above may be removed to get rid of a blemish, but if they reach into the orbit, the rules of antiseptic surgery must be strictly observed, because the proceeding becomes serious.

Pinguecula is the name given to a small yellowish elevation between the semilunar fold and the edge of the cornea. It consists of connective tissue, elastic fibres, and epithelium, and contrary to the import of its name it does not contain fat. Most persons in adult life or at its later periods will present this little elevation more or less conspicuously. It causes no harm, never becomes large, and is not to be meddled with.

Pigment patches of a brown or even deeper hue are sometimes seen on the conjunctiva; they may be stationary and innocuous, or they may increase, and they may be associated with co-existing pigmented malignant growths.

Angioma sometimes occurs. Its most frequent seat is the caruncle. In the same region we find more frequently *polypoid* growths or *granulomata*. In gouty subjects *cretaceous* deposit is sometimes found in the conjunctiva. Loring[2] has reported the remarkable fact of a *bony* growth.

Xerosis of the conjunctiva or its extreme degeneration and atrophy is brought about by trachoma, is a result of pemphigus,

[1] Centralblatt für Augenheilkunde, Jahrg. vii., S. 295, 1883.

[2] "Case of osteoma of the conjunctiva," by Dr. E. G. Loring, New York Medical Journal, xxxvii., p. 12, 1883.

Digitized by Harvard College Library

also appears in small glistening patches three or four millimetres across upon the inter-palpebral ocular conjunctiva, and lastly happens idiopathically to the production of complete symblepharon when it reaches its ultimate development.

Taking up the third form, we remark that these satiny white spots were described by Kuschbert and Neisser and also by Leber,[3] and have a special interest because bacilli and cocci are found in them. In some instances the patients have the form of amblyopia called hemeralopia. The connection between the two facts is not explained, nor do they always concur. When these patches exist there is also a little foamy secretion gathered along the edges of the lids due to fatty degeneration of the cells, and in some instances the cornea becomes infected and ulcerated by the penetration of the microbes. The disease occurs mostly among children and especially among the poorly nourished. It was observed as early as 1874 by Bezold, and by Horner in 1877: the lesion of the cornea was severe and the dryness of the conjunctiva was regarded as incidental. Leber considers degeneration of the epithelium the first step, followed by loss of sensibility through injury to the terminal nerve twigs; the consequence is imperfect closure of the lids and additional dryness of the conjunctiva—naturally the cornea becomes most seriously exposed to ulceration. The same kind of degeneration takes place in the epithelium which clothes the pelvis of the kidney, and the same microorganisms are found as in the conjunctival epithelium. Cultivation of these was found to cause the corneal lesion and also the degeneration of the conjunctiva. For cases among negro children, see Kollock, Trans. Amer. Oph. Soc., 1890, p. 626.

Leber proposes to give the name *xerophthalmus* to the alteration which follows trachoma and which includes atrophy of the whole membrane, but he points out that this condition may arise without trachoma, and both he and Arlt have noticed that it may be attended with atrophy of the lachrymal gland. There is almost complete absence of normal secretion, which can be only imperfectly supplied by water containing ¾% of chloride of sodium and 1% of bicarbonate of soda. Anointing with vaseline is of value.

Idiopathic xerosis is a very rare affection. It is described by Knies (Graefe's *Archives*, XXIV., 1, 157, 1878). In the case related there was complete adhesion of the lower lid of one eye to the globe, and partial adhesion of the lid borders to each other. There had been only a slight precedent inflammation. The cornea intact and no deformity of the ciliary margins. Cases in their outcome

[1] "Ueber die Xerosis der Bindehaut," etc., Graefe Arch. für Ophth., xxiv., Abth. iii., 225.

somewhat resembling this are described by Shaw,[1] one his own and others quoted from literature (see Trans. Oph. Soc. United King., VI., 138, 1886). In some of these there was a syphilitic history and there had been much thickening before the onset of the atrophy. Cases of pemphigus are confounded with this disease. I have seen one case entirely parallel to that of Knies (Alfred Graefe) in which there had been no thickening, no syphilis, no pemphigus; the corneæ were clear, the ciliary borders normal, but in one eye the lower lid was totally adherent to the globe, the canthi obliterated, and the same process was attacking the upper lid and the other eye. The adhesion of the lower lid to the left globe was complete. See Trans. Oph. Soc. United King., X., p. 62, for examination of corneæ in two cases, by E. Treacher Collins, in which this tissue was involved.

Amyloid tumors or degeneration are of very rare occurrence and appear upon any portion of the conjunctiva. Their growth is extremely slow, extending through several years. They are not accompanied by inflammation. The best account of them is found in a paper by Kubli, *Archives of Ophthalmology*, Vol. XI., p. 148, and another by Raehlmann in the same volume, p. 467, and also in Vol. X., p. 171, with plates. The tumor is diffuse, it may have roundish lobes, its color depends on its stage and its supply of blood-vessels; if the latter are few, the tumor will be of a bright yellow glassy color, but with more vessels the color takes on a reddish-brown hue. The following stages are recognized: 1st, simple adenoid proliferation of sub-conjunctival connective tissue; 2d, hyaline degeneration; 3d, marked amyloid degeneration; 4th, calcification and ossification. There will be tumors or knobs of various size and situation, either beneath the lids growing from the fornix, or in the lids, and of varying color and hardness according to the stage of growth. Complications may exist, such as trachoma and in one case reported by Frout and Bull (*Archives of Ophthalmol.*, Vol. VIII., p. 73) there was also sarcoma tissue mingled with the growth. In Raehlmann's paper (*l.c.*) colored plates show the peculiar reaction to iodine and sulphuric acid which distinguishes these growths.

The only treatment is extirpation, and the prognosis is good.

7. *Circum-corneal hypertrophy of the conjunctiva or vernal catarrh of the conjunctiva* is the name of an affection which is rare and consists of a chronic thickening of the tissues at the lim-

[1] Journal of Ophthalmology, Otology, and Laryngology, Oct., 1892, New York.

Digitized by Illinois College of Optometry

bus of the cornea.[1] One of the names is given because the disease is aggravated by the early warm weather. It progresses very slowly, viz., during years and presents a grayish-red ring, which rises one or two millimetres above the surface, has a breadth of several millimetres, is widest and thickest at the outer and inner sides of the cornea, is somewhat nodular and has a gelatinous look. There will be more or less general conjunctival irritation, and similar deposits are found sometimes upon the upper palpebral conjunctiva. The look of the disease suggests a kinship to trachoma, or to cancroid, but in microscopic character it is unlike them. The chief constituent is hypertrophied epithelium with some hyaline masses, and the connective tissue may or may not be hypertrophied. Excision of the mass is the best treatment heretofore practised. I have seen a few cases and should be disposed to employ the thermo-cautery in future. This is not in accord with most writers, who advise mild remedies, or as in Horner's[2] clinic, ointment of sulphate of copper 1% or of acetate of lead 3%.

The disease may disappear of itself and leave a dense mark on the limbus as of an accentuated arcus senilis. The aggravations which occur in warm weather suggest cooling lotions and protection of the eyes, but a radical removal by the cautery seems to me rational. No injury to sight usually occurs, although opacities of the cornea are not impossible, and in some of Vetsch's (Horner's) cases conical cornea was developed.

8. Certain *cutaneous* diseases give rise to conjunctival lesions and while the difference in anatomical structure between skin and mucous membrane necessitates marked differences in their pathological appearances we do well to keep in mind their resemblances.

For example *eczema* of the face and head is attended often with acute conjunctivitis, and sometimes we may find upon the mucous membrane and also on the cornea, minute erosions or even eruptions which suggest the skin disease.

Among children so common is the association between these affections, that Horner, in his treatise on "Diseases of the Eye among Children" (see p. 279 et seq.), puts catarrhal conjunctivitis down as eczema. He simply divides the affection into the solitary and the multiple or diffused eruption. The former is usually described as *phlyctenula* and by some, especially by Stellwag, has been called herpes of the conjunctiva, but the analogies of the disease are de-

[1] Uhthoff in Graefe's Archiv für Ophth., xxix., iii., 174, 1883. Burnett in Archives of Ophthalm., vol. ix., p. 414, 1881. Graefe and Saemisch, Bd. iv., p. 25. Bronner, Trans. Oph. Soc. United Kingdom, viii., 56, 1888.

[2] Vetsch, "Ueber den Frühjahrscatarrh der Conjunctiva," Inaug. diss., Zurich, 1879. Also Schiele, Archives of Ophthal. (Knapp), xviii., 4, 472, 1889.

Digitized by the College of Ophthalmology

cidedly in favor of eczema instead of herpes. There may be a true herpes corneæ, such as we find in herpes zoster, but for the disease known as phlyctenula of the conjunctiva, which Horner calls solitary eczema, we do better to keep in mind the characteristics of eczema rather than those of febrile or neurotic herpes.

Simple phlyctenular conjunctivitis appears on the bulbar conjunctiva in one or more eruptions, each having its own area of congestion, and each may be from one to four millimetres in diameter. The nearer they approach the cornea, and they often develop on the limbus, the more serious do they become. At their inception there will be a little stinging pain, lachrymation, and spasmodic closure of the lids. The eruption will be dull red and be surrounded by congested vessels which are apt to form an imperfect triangle of which the phlyctenula is the apex. At first the summit of the elevation is smooth, but soon the epithelium is cast off and an ulcer appears. Gradually the prominence subsides, epithelium is regenerated, and the vascularity abates. So long as the eruption is distant from the cornea it is not dangerous, and its duration will be from four to fourteen days.

Another form of the eruption is in minute vesicles or infiltrations or ulcers at the limbus corneæ, which accompany a diffused and acute conjunctivitis. There will be swelling of the lids, considerable muco-purulent secretion which agglutinates them, and a patch of hyperæmia growing more intense toward the cornea, while their orbital portion will also be swollen. The only eruptions will be around the cornea, and the importance of the attack depends upon whether the cornea may be deeply invaded. Such cases are apt to follow the acute exanthemata, such as scarlet fever and measles and varicella. We do not here trace the disease in case it should penetrate the cornea, reserving it for consideration when dealing with this structure, but the entity of the disease is the same, notwithstanding the difference of soil in which it flourishes.

Prognosis and Treatment.—The isolated phlyctenulæ remote from the cornea will get well without producing any harm. Their disappearance will be hastened by dusting into the eye very pure and finely levigated calomel once daily. It becomes converted into a minute quantity of corrosive sublimate, and if not properly prepared is irritating. Care must be observed not to use calomel in this manner if the patient should be taking iodide of potassium, because in this case the irritating iodide of mercury would result. Besides the calomel very little else is needed. A little warm water or warm milk and water may be locally used if agreeable to the patient. Tonics are indicated.

For the diffused form of inflammation with eruptions at the limbus, the treatment will be antiphlogistic and expectant. Cool

Digitized by the Internet Archive

lotions of lead water upon the swollen lids or boric acid or alum may be kept up. As the acute sympoms retire, nitrate of silver, gr. iij.–vi. ad ℥ i., may be applied to the everted lid once daily, or dropped into the eye. If there be excoriations on the angles or margins of the lids, they must be touched with pure nitrate of silver and kept greased with simple cerate. The depreciated health of the child will need special consideration, as regards nutritious and simple food and correct assimilation. Bad hygiene, a scrofulous taint, and feeble health lie behind the malady. The disease is liable to attack the cornea and that will be hereafter referred to.

Particular notice may be give to cases of *acute eczema* of a phlegmonous character, which occurs in old persons, especially if gouty. When this attacks the face it spreads to the skin of the lids, makes them puffy and sets up general conjunctivitis, which is attended by intolerable itching, smarting, and heat. Excoriations of the margins of the lids occur, and while the discharge is chiefly watery and the tissue changes are not dangerous, the discomforts of the patient are extreme. Cold lotions give temporary relief, but are soon rejected, and relief by anodyne and astringent applications is slight. The free use of cocaine in 5% solution may be tried with hope. I have not seen such a case since this remedy has come into use. Dusting with starch powder or with oxide of zinc, etc., is to be tried. One may have to resort to opiates or the bromides and chloral to allay distress and at the same time endeavor by general remedies to antagonize the constitutional cause. Cod-liver oil both internally and externally may be the best remedy, while alkalies, lithates, etc., and all the dietary rules against lithic acid and gout rigidly observed.

The lesions of the eye after *variola* deserve attention. So far as any observations have been recorded, pustules are found on the palpebral and ocular conjunctiva, but not on the cornea (Arlt,[1] Hirschberg[2]). There has also been seen, if during the height of the disease the lids have been opened, a grayish-yellow infiltration of the conjunctiva below the cornea, closely resembling diphtheria. When the disease has spent itself and the eyes can be examined, there is usually little trace of any lesion of the conjunctiva, but we may have ulceration or dense opacity of the cornea. This is considered to be the secondary result of the conjunctival inflammation or eruption, either by extension of ulceration or by subsequent abscess.

If it is possible to separate the lids and perceive the commencement of conjunctival inflammation, the eyes should be assiduously

[1] "Klinische Darstellung der Krank. des Auges," Wien, 1881, p. 78.

[2] Berlin. Klin. Wochenschrift, 1871, S. 282.

Digitized by Internet Archive in collaboration with Open Library

cleansed with boric acid solution or chlorine water, and an incipient pustule may be cauterized with pure caustic melted in a fine bead on a probe, followed by careful neutralization with salt water. It is not meant to do this when the cornea is deeply implicated. The free use of boric acid and vaseline will help exclude noxious secretions, and should be put between the lids very frequently.

Herpes, as a skin disease, is known under two forms: as *herpes febrilis* or *catarrhalis* it may extend to the conjunctiva; with greater but with very moderate frequency it appears upon the cornea. That *herpes zoster* breaks out both upon the conjunctiva and cornea has been for many years a recognized fact. The occurrence of the febrile variety upon the eye has not been generally recognized, and it is to Prof. Horner[1] that we owe most of the observations which have been made. Arlt[2] confirms these assertions and others have reported cases. The vesicles will seldom be found distended, but will have burst, leaving a superficial ulcer, and shreds of epithelium with localized hyperæmia. There will be the usual eruption on the face, and in consequence of some debilitating illness such as pneumonia, etc., this form of herpes will seldom be recognized upon the conjunctiva, but on the cornea it will sometimes be found if attention is alive to it.

The eruption of herpes zoster on the conjunctiva or cornea will seldom escape notice because of the accompanying severe neuralgia, and in this place it is unnecessary to dwell upon it because the matter has been before considered (see page 257). Herpes catarrhalis as a corneal disease will be hereafter considered: as a conjunctival affection nothing special need be said beyond calling attention to its true nosological relations, and to give up the erroneous application of the term which has more or less prevailed.

Pemphigus being found on mucous membranes, as in the mouth, pharynx, and intestines, as well as on the skin, may appear upon the conjunctiva or upon the cornea. Such an occurrence is very rare. A few cases have fallen to my observation. A paper has been written about it by Cohn,[3] describing a case in a child and summing up the literature. The body of his patient was entirely covered with bullous eruptions, they occurred on the tongue and in the mouth, upon the conjunctiva bulbi of first one eye and then of the other and progressed to cover the corneæ. Treatment was of no avail. The baneful effects of the disease, how it causes shrinking of the conjunctiva, are vividly portrayed by Mr. White Cooper.[4]

[1] Klinische Monatsblätter für Augenheilkunde, Bd. ix., S. 321, 1871; and "Ueber herpes corneæ." Inaugural dissertation von A. Josephine Kendall, Zurich, 1880.

[2] "Darstellung," etc., 1881, S. 79.

[3] Breslauer Aerztliche Zeitschrift, 1885, No. 10.

[4] Ophthalmic Hospital Reports, vol. i., p. 155, London, 1858.

Digitized by Illinois College of Optometry

His patient was a young woman, twenty-four years old. Upon the inferior cul-de-sac of each eye in turn, a bulla was formed and a succession of them took place. She had for several weeks had them on the limbs and body. For three months she was treated with no benefit. She was seen again after twenty-seven months and he describes the condition as follows: "A person not acquainted with the history would have pronounced that some powerful escharotic, as lime, had been applied to them, for a series of frœna or adhesions existed, as represented in the sketch." The colored plate would be taken for a picture of symblepharon after a burn, and in both eyes the corneæ were implicated. In other reported cases the conjunctival sac becomes shrunken and the adhesions, which at first are red, become in time pale white bridges. The edge of the cornea may be overridden or it may be extensively involved in a leucoma.

Some cases are less severe than others, but the duration is most tedious and the ultimate result cannot be predicted, in fact, in most cases the eyes are lost. Samelsohn observed a series of eruptions confined to the inner surface of the lids during seven years, and but little atrophy had occurred. The globe did not within that time become affected. Treatment must be founded on symptoms (syphilis may exist) and will be mainly supporting, while local applications must be palliative and soothing. Sometimes weak nitrate of silver solution, cold water, and in the late stages, fatty substances; but all is of little avail.

9. *Traumatic Conjunctivitis.*—Under this head we may group lacerations, burns, and foreign bodies upon the conjunctiva. So far as wounds and burns of the lids are concerned sufficient has been said (p. 278 *et seq.*); and lacerations of the ocular conjunctiva almost never require any adjustment.

Foreign bodies easily penetrate the conjunctiva and are sometimes only to be removed by snipping them out with a bit of the membrane. Grains of powder become imbedded and being soft are with difficulty entirely removed. Husks of seeds, beards of grain, bits of stone, glass, or wood, or the spines of chestnut burrs, etc., are some of the things to be dealt with. A finely pointed forceps with roughened tips is the efficient instrument, aided by cocaine. Sometimes a piece of stick or twig or something of the sort finds its way into the superior fornix and may elude detection. It may be held there by the grip of the lids and cause inflammation and pain, etc., or even remain hidden so long as to be encapsuled with granulations.

"Eye stones," or "crabs-eyes" (the shelly operculum of small *turbinideæ*, Dunglison) which are put into the eye to expel foreign bodies, sometimes remain imprisoned and are even forgotten. The

removal of foreign bodies from the tarsal surfaces requires only eversion of the lid, while if anything be hidden in the fornix, a camels'-hair brush, or curette or strabismus hook, gently swept along will dislodge it. It is needless to disapprove of the tongue of a friend as an implement for removing foreign bodies.

9. *Sub-conjunctival ecchymosis* forms a well-defined patch which, by its uniformity of color and absence of vessels, is readily distinguished from inflammation. It requires no treatment, and does no harm unless it be large and may cause a little sense of fullness. The blood is sometimes absorbed into the aqueous humor and may slightly obscure vision. Its chief importance respects cause and prognosis. It comes after coughing, especially during pertussis, or any kind of strain. In adults, especially in those after middle life, such hemorrhage, if without strain, signifies a degenertion of the blood-vessels, and if oft repeated, suggests a serious condition and calls for the exercise of prudence in habits of eating and drinking and exercise. Similar lesions are liable to occur in the retina or in the brain or in other organs and with effects notably serious.

Pterygium.

10. The typical form of this condition is a triangular thickening of the conjunctiva, which advances from the caruncle to the cornea and encroaches more or less upon its surface. It may be delicate and semi-transparent with few vessels, and justify its name by the resemblance which it bears to the wing of a house fly. On the other hand it may be so thick and vascular as to be rightly called *pterygium crassum*, as the other is called *p. tenue*. While the favorite site is the inner side of the eyeball (see Fig. 136), the outer angle is next in frequency in giving it origin. Sometimes one may be present at the same time in both situations. The structure grows very slowly and may remain stationary for years, or push forward gradually until it approaches the pupil and may in extreme cases attain the middle of the cornea. From time to time it may be subject to inflammation. It seldom, except at such times, causes annoyance, and it offers no obstacle to vision until it has reached some millimetres beyond the corneal edge. It will, however, impair sight before it has seemed to have gained the pupillary area, because there is a patch of haziness beyond its apex, and even when haziness does not exhibit itself, the structure of the cornea will have lost its homogeneousness and cause irregular refraction. I have demonstrated this by the ophthalmometer. The apex is more or less rounded and seems to dip into the substance of the cornea. The edges near the apex will be found to be rolled under and will

Digitized by Google

admit a fine probe to be thrust beneath for a short distance. Toward its base the growth merges into the neighboring membrane. It appears mostly in persons who are exposed much to the weather, or to dust and irritating atmosphere, and they are generally adults or perhaps of advanced age. In such persons a chronic conjunctivitis, especially of the inter-palpebral region, is prone to be produced and attended by little erosions at the margin of the cornea. In winking, foreign particles are driven toward the horizontal meridian and thus the site of the erosions is easily accounted for.

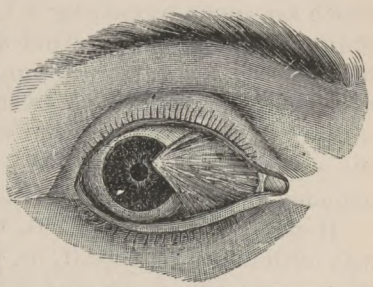

FIG. 136.

The mode of growth and pathology have caused some discussion. The view most in favor is that because of its laxness the conjunctiva at the inner angle is folded and rides over upon the cornea where an erosion may exist, an adhesion occurs and gradually the membrane is drawn over as if one should pluck the lining of his coat sleeve out over its edge. Sometimes the apex buries itself slightly in the tissue or it may seem to push straight on over the surface. Microscopic examination of a horizontal section of a pterygium as it is found actually growing, and with the relation of the parts undisturbed, has shown that a close relation exists between pinguecula and pterygium. The anterior elastic lamina of the cornea is corrugated beneath it, there is a cell infiltration of the cornea both beneath and beyond the tip. It is found that an epithelium exists beneath the end of the pterygium and that a slight cavity or even two small cavities may exist whose walls are clothed with epithelium.[1] Cocci have been found imprisoned, but their occurrence may be accidental. In the superficial layers of the cornea are numerous fine capillaries which readily become the agents of farther progress of the growth. In the conjunctival part of the pterygium is an abundance of fibrillar tissue, cell-infiltration, and blood-vessels.

There are other varieties of pterygium which are the evident result of ulcerations, as in the case of burns. These are more fleshy and may occur at any portion of the eye and spread in an irregular form over a greater or less extent of the cornea. They are sometimes called false pterygia.

Treatment is surgical and preferably by excision. In the early stages it may sometimes be possible to tear off or forcibly unfold the attachment of the tip and the remainder may be partially cut

[1] See Harder, "Zur Lehre vom Pterygium: Mittheilungen aus der Augenklinik zu München," S. 247, 1882.

away and the gap closed by a suture. In most cases the method is to seize the corneal portion with toothed forceps and as it is lifted, push beneath it a cataract knife and shave it from the cornea. With sharp-pointed scissors dissect back the base as much as may be needful. The apex may be torn away from the cornea and be removed very perfectly and with less loss of epithelium (Prince). Cut away as much of the vascular sub-conjunctival tissue as possible. Cover the raw surface by flaps of the adjacent conjunctiva, which are made by cutting it loose from the edge of the cornea and sliding them together. They will be retained by silk sutures. A 10% solution of cocaine will annul pain and reduce vascularity. The eye may be bandaged for twenty-four hours, or in old persons for several days, and then cold water applied. In two or three days the sutures may be removed. Union is prompt, but a vascular and denuded spot remains upon the cornea which heals slowly.

Hence an opacity is left, which will continue for months. It may ultimately disappear, or, if the pterygium has been large and thick, a secondary one may take its place. This, however, is nothing more than the development of blood-vessels as a necessary part of the healing process in the cornea, and the new growth is always smaller than the original, and may not show any disposition to extend. If it should, there would be no objection to a second operation. In regard to the recovery of sight, it must be remembered that haziness of the cornea extends an appreciable distance beyond the pterygium, and the reaction due to the operation will render this area temporarily larger, hence there is not at first that gain in vision which will be finally secured. This circumstance is to be borne in mind in treating cases where the growth has reached the border of the pupil. I have observed with the ophthalmometer, that removal of the pterygium has changed the corneal curve. It follows that one should look for astigmatism, because this may, as I have found, explain the imperfect vision. I have formerly been indisposed to remove pterygium until it made appreciable advance toward the region of the pupil, but having noticed that under its influence astigmatism arises, I now remove it when not more than 2 millimetres beyond the limbus.

It is conceivable that the most suitable way of dealing with an extreme case might be to perform iridectomy downward and outward, and the removal of the growth would be optional. That this proceeding may be required has been shown by two cases reported by Dr. Ryerson, *Medical Record*, May 9, 1891.

The intimate relation between pinguecula and pterygium has been referred to. Fuchs has attempted to show that the latter is really a morbid transformation of the former. Graefe, *Arch.*, Bd. XXXVIII., Abth. 11, p. 1, 1892, with plates. See also "Lectures on the Human Eye," by Alt, 1884, p. 31, with plates, New York.

CHAPTER V.

THE CORNEA.

Anatomy.—Fitted into the sclera like a watch-glass, the cornea has a vertical diameter of about 11 mm. and a horizontal diameter of about 12 mm. Its radius of curve is about 8 mm. (7.8 mm.), but it forms, at least at its middle part, an ellipsoid, whose shorter radius belongs to the vertical meridian. The curve as we approach the periphery becomes difficult to describe and cannot be reduced to any ordinary figure (Burnett[1]). At the rim the thickness is 1.1 or 1.2 mm., at the middle it is reduced to 1 mm. The border runs under the sclera with a sloping edge. As the conjunctiva approaches the cornea, its epithelium becomes thicker and forms a whitish ring known as the limbus. The cornea constitutes the front of the space known as the anterior chamber, and of which the iris forms the posterior wall, and the plane of the iris passes through the sclera at a distance of 2 mm. more or less from the apparent boundary of the cornea. The apex is 2.68 mm. above the plane which passes through its base, and this gives the height of the anterior chamber measured from the lens to the back of the cornea (see Fig. 2, p. 4).

The cornea has about the transparency of glass; when squeezed it becomes whitish and it readily imbibes water after death, then becoming bluish-white. We find in it five layers; superficially an epithelium and posteriorly an endothelium; an anterior basal membrane (anterior elastic lamina of Bowman); a posterior elastic lamina or membrane of Descemet, between these last the substantia propria. Based upon structural character and pathological relations, we may make three divisions: 1, the conjunctival, viz., the epithelium; 2, the scleral, which takes in the anterior basal membrane and the substantia propria; 3, the uveal portion, to which belongs the posterior elastic lamina with its endothelium. The cornea has no blood-vessels except for a narrow space about 1.5 mm. wide at the margin, and these vessels coming from the conjunctiva run under the epithelium as far as Bowman's membrane. They turn upon themselves in capillary loops. The statement has

[1] Archives of Ophthal., vol. xii., 1, p. 1, 1883.

Digitized by the Internet Archive of Ophthalmology

long had currency that in the embryo the human cornea is covered by a network of blood-vessels. This has been declared by Prof. Schöbl, of Prague, after the examination of many specimens, to be incorrect.[1] He also declares that, besides the conjunctival zone of vessels, a deeper layer is to be found in the corneal substance which comes from the sclera.

The corneal epithelium consists of six or eight layers at its middle and more at the periphery. The surface layers are flat, the middle polyhedric, the deepest cells are cylindric and rest on Bowman's membrane. These last by division and the changes of their nuclei known as karyokinesis, give rise to young cells which press their way upward and undergo changes of form until they are rubbed away on the surface.[2] They never lose their watery contents entirely, as they become superficial, and they are held together by an intercellular cement. The cells are nucleated.

The anterior basal membrane is clear and structureless, it may be resolved into fibrillæ by chemical treatment and may even be dissolved, and Schwalbe says it does not resemble elastic tissue.[3] Its outer surface supports the cylindric cells of the epithelium, which send minute teeth into it. It is pierced by the ultimate fibrillæ of the nerves proceeding to the epithelium, and to its lower surface the fibres of the corneal substance are adherent. Union with the latter is extremely firm, while removal of the epithelium is easily effected.

The parenchyma of the cornea has a laminated structure. The lamellæ, from eighteen to twenty-five in number, may be resolved into bundles of fibrillæ by chemical treatment (see Schwalbe, l.c., p. 152). Their general course is parallel to the surfaces, yet they intersect in various ways, running obliquely upward and downward, uniting the lamellæ, and being excessively fine are closely interwoven. A homogeneous cement binds them together. At Bowman's membrane the fibrillæ are the finest, they cross at sharp angles, or even in perpendicular lines, and attach themselves to it intimately. The corneal substance presents another and peculiar feature in the system of canals which permeates it, and in which are found specialized cells called the corneal corpuscles. The canals intersect and also expand frequently into spaces or lacunæ (see Fig. 124). They anastomose with those above and below them, yet have a general tendency to parallelism with the corneal surfaces. In their enlargements and intersections are found the corneal corpuscles,

[1] Centralblatt für Augenh., Nov., 1886, p. 321.

[2] "Ueber das Wachsthum, etc., des Epithels der Cornea," Vossius. Graefe's Archiv f. Ophth., xxvii., Abth. 3, S. 223, 1881; Flemming, "Zellsubstanz," Leipzig, 1882. Klein.

[3] Schwalbe, "Lehrbuch der Anatomie der Sinnesorgane," 1883, p. 151.

Digitized by the Internet Archive in 2007 with funding from Microsoft Corporation

which seem like more indurated portions of the canal walls, and by certain methods of treatment can be isolated and present a body and processes running in various directions. Within the body is the cell nucleus adhering to its side; they resemble bone corpuscles. The contents of the canals are, 1st, a clear fluid, and 2d, two kinds of cells; one the fixed cells or corneal corpuscles, just referred to, and the others are leucocytes or wandering cells. The fixed corpuscles are a kind of partial endothelium of the canals.

The posterior elastic lamina is structureless and elastic, transparent and very resisting. By long boiling in water it splits into many fine lamellæ which incline, like the whole structure, to roll in a forward direction. The union of this membrane with the corneal substance is less intimate than is that of the anterior layer. It is thicker at the rim that at the middle, and in adult age is apt to have little colloid eminences on its surface. It runs into the sclera and at the angle of the anterior chamber fibres run from it into

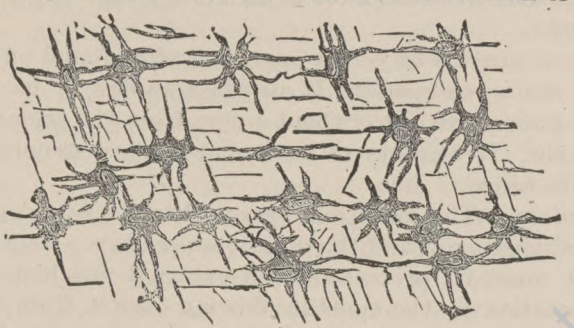

FIG. 124.

the iris sometimes called the pectiniform ligament (see Fig. 2, p. 4). Upon them are isolated cells. In some animals these fibres are well developed, and we find here the so-called canal of Fontana. Upon the free surface of the posterior elastic lamina is a single layer of nucleated endothelium; the cells are flat and polygonal.

At the junction of the cornea and sclera, one tissue passes insensibly into the other. Parallel to its margin and lying near the deep surface, is a circular channel, known as the canal of Schlemm, which is usually oval in section, but may be slit-like, or present more than one opening. It is a lymph vessel, also called the circular venous sinus (Bowman) which may separate into smaller ones which again unite. This canal lies beyond the angle of the anterior chamber (see Fig. 2, p. 4).

The nutrition of the cornea is maintained by lymph coming from the marginal vessels which traverse the channels of the tissue, and by diffusion from the aqueous humor. The entrance of aqueous is greatly facilitated by removal of the endothelium. That

Digitized by Illinois College of Optometry

fluids can pass through the epithelium is proved by dropping fluoresceine and medicinal substances such as atropia, etc., into the conjunctival sac.

While the nutrition of the cornea is thus secured, it is not easy for fluid to escape by filtration through it. Leber has shown that so long as the endothelium remains intact, the aqueous humor will not reach the surface even under extreme intraocular pressure. The outflow of fluid is by way of the marginal blood-vessels and by the canal of Schlemm.

The nerves of the cornea come from the ciliary, which having passed the ciliary body, form a plexus around the corneal border, both deep and superficial. The terminal fibrillæ are most abundant in the epithelium and in the anterior layers of the cornea. The larger twigs are contained in perineural canals lined by endothelium. Some twigs come in from the nerves of the conjunctiva. The highly sensitive character of its surface attests how rich is the nerve supply.

A ring of grayish or yellow opacity is often found on the cornea, known as the *arcus senilis*. It may be complete or incomplete. It usually begins above. It is about 1 mm. from the sclera and is 1 to 1½ mm. wide. It consists of molecular fatty degeneration of the corneal substance.

Physiology.—The conditions essential to the function of the cornea are transparency, and the maintenance of its polish and correct curve. It must be protected from external mischief by the lids; from desiccation by the moisture flowing over it from the conjunctiva, and by nutritive fluid supplied by other adjacent vessels. The regularity of its structure is indispensable to its transparence. The maintenance of its curve demands strength to resist the external compression of the lids and the muscles, as well as intraocular pressure, and also that the latter pressure do not fall below a certain amount. It is the most important of the refractive media. Its angular aperture is more than 100° (Schoen[1]) although only from 40° to 50° are used, because of the effect of the pupil. The refractive index of the cornea is substantially the same as of water, viz.: 1.3365, and the focus for parallel rays coming from air will be 31 mm., which is the second focal distance; the focus for parallel rays coming from behind and passing into air is 23 mm., which is the first focal distance.[2] Very slight irregularities in the structure and curve of the cornea are damaging to vision, whereas slight

[1] "Der Aplatanismus der Hornhaut," "Beiträge zur Ophthal. als Festgabe," Friederich Horner, p. 125, 1881.

[2] See Burnett, "Analysis of the Refraction of 576 Healthy Human Corneæ," Trans. Am. Oph. Society, 1888, p. 48, and especially p. 54, which states the variations in the cornea, viz., that its refraction in emmetropia varies from 39 D to 47 D. The general prevalence of slight asymmetry in curve (astigmatism) has been referred to.

Digitized by the Internet Archive in 2010

opacities of the lens have little or no effect. The lens may be removed and a substitute be found for practical vision in a pair of spectacles, but nothing can take the place of the cornea.

Pathology.—1st. There are abnormal conditions which consist in alterations of curvature, either congenital or acquired, and which do not result from inflammation. To this category belong astigmatism and conical cornea. 2d. Inflammation causes opacity of the most various kinds in all the layers of the cornea; infiltration of serum, of pus; ulceration, which takes on diverse forms and degrees, and may lead to total destruction or perforation, and consequent change of shape; there may also be newly formed blood-vessels both in the superficial and deep layers; in very chronic cases of inflammation we have sclerosis as its result, which appears as a yellowish degeneration, and we sometimes find calcareous and other mineral concretions; pigment deposits are rare.

The study of inflammatory action in the cornea has excited very great attention, because the want of blood-vessels apparently simplifies the problem. Cell proliferation and cell immigration are conspicuous factors. Taking up first the epithelium, we find it disappear and also proliferate. In multiplying, the deeper cells divide and their nuclei undergo all those changes of form called karyokinesis by Fleming (see Da Gama Pinto[1]). They are liable to become irregular in arrangement and may be lifted by effusions either between the layers, or between them and the corneal substance. Regeneration occurs rapidly and either with or without the appearance of new vessels. In case the corneal substance has been involved, the epithelium may be restored more quickly and leave minute irregularities called corneal facets.

In the corneal parenchyma, inflammation exhibits intrusion of leucocytes, coming either from the neighboring vessels, or if there be any lesion of the epithelium, from the conjunctival surface. As they force their way along the numerous interstitial canals they take on oblong, curved, or spindle shapes. They appear in rows, and under focal illumination constitute the fine straight lines which are familiar after wounds. They often break up and leave only their nuclei.

Besides leucocytes, the fixed corneal corpuscles undergo changes of form and size, they multiply and are likely to form concentric groupings. Their behavior is not fully understood. The fibrillæ also soften and disintegrate. If the number of leucocytes or lymphoid cells is not too great, they may be entirely removed and transparency be restored. On the other hand, if in great quantity, we have necrosis of tissue, which if it find vent superficially gives an ulcer, or if circumscribed, constitutes an abscess. Suppuration may be limited or it may be general; it may get into the anterior chamber (*hypopyum*).

[1] Centralblatt für prakt. Augenheilk., April, May, 1884, p. 97.

Digitized by the Boston Medical Library Company

The intimate relation which pathogenic germs bear to suppuration is fully established in corneal pathology. In most cases they find entrance through breaches of epithelium, and sometimes, as in

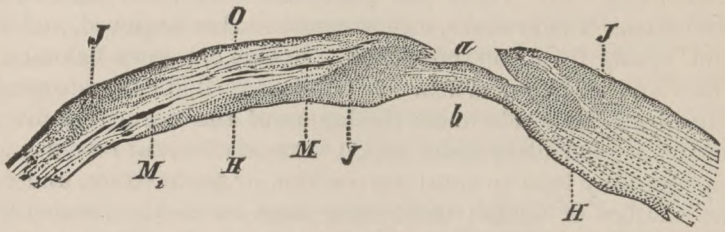

FIG. 138.—*Keratitis mycotica* (Kerato-malacia infantum). *a*, ulcer with undermined edges; *b*, bulging of its base; *H*, posterior surface of cornea; *O*, its anterior surface; *J*, cell infiltration; *M* and M_1, colonies of micrococci.

kerato-malacia of infants, they bring about speedy and total destruction.

The plates from Haab[1] exhibit them (see Figs. 138 and 139). The gonococcus of Neisser has been recognized in the cornea in gonorrhœal conjunctivitis. The influence of germs is of the greatest importance in corneal suppuration, and experiments by Sattler and others have fully confirmed the fact of their giving rise to it. They also appear sometimes in branching figures limited to a small

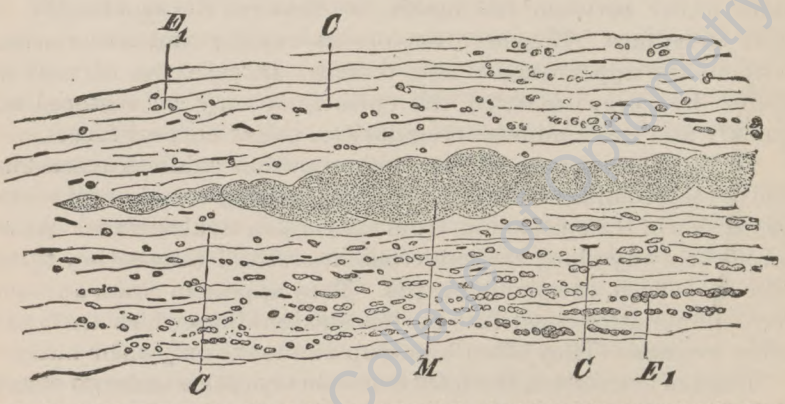

FIG. 139.—Micrococci of Fig. 126 at *M* more magnified. *C*, nuclei of the corneal cells; E_1, pus corpuscles; *M*, masses of micrococci between the corneal layers.

number of corneal canals and compose the cases of keratitis mycotica dendritica (see cases by Hansen-Grut,[2] and Emmert[3]). They play an important part in the inflammation which sometimes follows

[1] "Pathologische Anatomie der Augen," Ziegler.
[2] Trans. Ophth. Congress, Heidelberg, 1888.
[3] Centralblatt für Augenheilk., Oct., 1885, p. 302.

Digitized by Illinois College of Optometry

paralysis of the fifth nerve. Certain ulcerations, the ulcus serpens (Saemisch), the ulcus rodens (Mooren), in all probability are of mycotic origin. The same has been observed after erysipelas of the face (Horner).

The membrane of Descemet, or posterior elastic lamina, possesses great ability of resisting destructive tendencies. Its endothelium may proliferate and may go into fatty degeneration without proliferating. If, however, perforation of the cornea occur, the iris will fall into the wound, become attached and form anterior synechia. If the opening take place at the middle of the cornea, the lens comes forward and sometimes acquires adhesions. After a time it is usually pushed back and leaves an opacity on the cornea and likewise upon the capsule. It may penetrate the lens to considerable depth. Occasionally a fine thread of exudation may unite the cornea and lens. With a large ulcer the lens may present itself fully in the opening and perhaps be expelled, or be covered in by new tissue, which afterward develops into a staphyloma. Whenever destruction extensive, either in area or in depth, occurs, the healing is attended by deformity through distention of the cicatrix, and staphyloma, either total or partial, ensues.

Reparative processes are frequently attended by the development of blood-vessels. We meet them most frequently in the superficial parts, but they also appear in the deeper parts of the cornea. They may grow in the tissue, but they commonly shoot in from neighboring vessels. When they are very numerous, as happens in trachoma, they are called by the name of *pannus*.

There are certain eruptive processes upon the cornea called eczema, phlyctenula, herpes, which will be referred to under the description of the diseases. We also meet certain pathological changes on the posterior surface whose consideration will be deferred.

It may be well at this point to say a few words in general upon opacity of the cornea. It is the physical result of the changes already described by which the homogeneity of the tissue is impaired. There are numerous analogies: for example, glass reduced to powder becomes white, water as foam or crystallized into snow is no longer transparent. The cause is the irregular way in which light is reflected from the multiplied surfaces. To detect a faint corneal opacity it is best to use oblique or focal illumination in a dark room. A feeble reflection from the ophthalmoscopic mirror swept across the pupil will often bring out shadows which betoken want of homogeneity, especially if viewed from a distance of one or two feet. A plane mirror is the best. The determination of a departure from the correct curve may be roughly made by letting the bars of a window frame be reflected from it as a patient sits full in its light. A clearer determination is possible by holding near the

Digitized by Illinois College of Optometry

eye a white disc on which concentric black circles have been traced. The disc is about ten inches in diameter, has a small tube at its centre and a magnifying lens of four inches focus behind it. The patient sits with his back to a window and the disc is held close to his eye; he looks in various directions and the observer notes the distortions in the reflected image of the rings. The disc bears the name of Placido (see Fig. 52, p. 126). For more perfect observations the ophthalmometer of Helmholtz or more easily that of Javal and Schiotz are to be employed (see Fig. 49, p. 124). Dense opacities are seen at a glance and their location determined by viewing them from different points. Should opacity of the cornea and of the lens both be present, the seat of each respectively is shown by oblique illumination (see Fig. 16, p. 36), and also by the influence of the size of the pupil, which has no effect on the one and will display more of the other.

Various terms are used to denote opacities, namely, *nubecula* (a mist), *nebula* (a cloud), *macula* (a spot), *leucoma, albugo.* The designations are arbitrary, but the last two signify the most intense. *Leucoma adhærens* means an opacity or scar left after perforation and to which the iris is attached.

Keratitis.

Subdivisions.—A convenient arrangement is to classify the varieties of corneal inflammation into, 1st, superficial; 2d, interstitial, or those of the corneal substance, and 3d, the posterior or profound. In cases of suppuration the whole cornea may be involved, and the origin may be at the surface, or in the substance: hence, we may properly speak of suppurative keratitis without regard to its locality. Moreover, we may designate corneal diseases according to their cause, such as traumatic or eruptive; such as eczema and herpes, mycotic, neuropathic, syphilitic, scrofulous and gouty, malarial, marasmic, exanthematous, etc. No subdivision can be made which is unobjectionable, and no uniform basis for it is possible either in etiology or pathology.

Preliminary to an account of these varieties it will be useful to group together the *symptoms* which are common to all forms of corneal inflammation. These are subjective and objective. We have hyperæmia both conjunctival and scleral, or ciliary. It grows more intense near the limbus; it may be confined to a limited space, being triangular or elongated, or it may cover the whole front of the eye. There will be lachrymation and in case the conjunctiva participates or the process is suppurative, there will be muco-purulent secretion. There will be pain and a sense of something foreign in the eye, and the dominant symptom will be photophobia. The

Digitized by Google

younger the subject, or the more sensitive, and the more superficial the lesion, the more aggravated will it be. Cases in which there is little or no intolerance of light will attract special attention, because they imply paralysis of the sensitive nerves, as in neuropathic and malarial inflammations, and in severe and extensive mycotic processes. This symptom is a reflex action from the fifth nerve to the optic and to the seventh, which acts on the orbicularis muscle. Opacity and ulceration and vascularity have been referred to, with other conditions.

Phlyctenular Keratitis, Eczema Corneæ.

A description of this disease as it appears on the conjunctiva has already been given, and what is now to be said has, to some degree, been anticipated. The margin or limbus is the favorite site. One or more slight elevations of a grayish-white or yellow color appear, which are about the size of a pin head, or sometimes larger. Often they are not at any time vesicles, but semi-solid, and soon their summit is eroded and leaves a little ulcer; this may affect only the epithelium, whose layers are numerous and corrugated, or it may reach more deeply beneath it. Should the eruption attack the transparent cornea, it will seldom show any elevation, but present a yellowish round little pit with soft bottom and about it an area of bluish-white opacity. There may be several at once, and after a time blood-vessels will enter the corneal surface. In case of repeated attacks, the whole cornea may be covered with a network of vessels in whose meshes the epithelium looks gray and dull and facetted, a true pannus. There will be injection of conjunctival and ciliary vessels; usually there will be severe pain, photophobia and lachrymation. Especially a disease of children, it attacks the ill-fed, or over-fed, the weakly, the dirty, those who have miserable homes and those who in good homes are either delicate or unsuitably fed. There will be eczema of the head or face, about the lips and nostrils or chin. There will be running from the nose, often ulcers exist at the angles of the mouth, at the nares, and at the angles of the eyelids. The children are flabby and pale and they may be fat; the secretions of the bowels are often perverted. In bad cases the resistance to light and to examination and treatment, is frantic. Often the temper is much "on the move." To pacify the child the pitying mother will give candy, cakes and various bribes of the toothsome kind, which simply aggravate the general tendencies. The lids will be swollen and firmly corrugated. Sometimes the cornea suffers perforation, and destruction of the whole eye, or staphyloma, is seen too often in public institutions. In milder cases the

spot may disappear without any perceptible blemish. More frequently the trouble lasts for some weeks, leaving one or more maculæ and a mesh of capillaries in the cornea. The palpebral conjunctiva is always hyperæmic. During the late period of a phlyctenula blood-vessels frequently form a more or less triangular bundle running from the conjunctiva to the site of the corneal ulcer, which is its apex. Sometimes ulceration progresses in a crescentic form, with edges undermined, its surface soft, gray, infiltrated; and sometimes it advances with alarming rapidity. Most of such cases are infected by micro-organisms, and it is because of their presence that they are both obstinate and severe. To them is due the deep invasion of the tissue, and the progress of the case is often to iritis and still deeper mischief. Should the corneal lesion disappear, the habit of shutting the lids will long continue and the patient shun the light.

The disease has been called scrofulous keratitis or strumous ophthalmia, or pustular ophthalmia, and by Stellwag is called, incor-

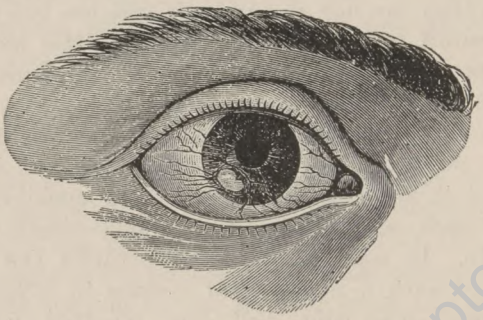

FIG. 140.

rectly, herpes corneæ. Horner first set forth its analogies with eczema, while true herpes will be next described.

There have been few opportunities for anatomical study of these cases. It is known that in the superficial eruptions there is a massing of lymph cells beneath the epithelium and that they often follow the canals which surround the nerve twigs (Iwanoff). From this fact one may understand the intense irritation which attends the disease. The anterior basal membrane undergoes both thickening and attenuation and is often crumpled. Sometimes a papilliform elevation is thrown up from it on which is a loop of vessels and lymph cells heaped amid connective tissue. Such appearances explain the minute irregularities of the surface and the loss of polish.

The presence of blood-vessels must be regarded as a tendency to repair, notwithstanding that in pannus they are a grave impairment to sight. See Fig. 140 which represents a condition common to a variety of localized affections after a certain duration. There

Digitized by the Internet Archive of Optometry

is an infiltrated ulcer, in process of repair as denoted by the blood-vessels surrounding and entering it. At this stage local stimuli are in order, while the period of active genesis of germs has probably passed, and with it the need of their mechanical removal.

Treatment must be both local and constitutional. Local measures will be adopted in accordance with the severity and complications of the case. If there be only one or two eruptions and they *recent* and situated on the cornea, they may be scraped out clean by a sharp spud, under the influence of a 4% solution of muriate of cocaine. Then tie up the eye, wash it out once in three hours with a 2% solution of boric acid, and replace the bandage. In three or four days it may be well. If the eruptions are on the limbus and the symptoms slight, the scraping may be omitted and the ointment of yellow oxide of mercury, gr. ij. ad ʒ i., may be rubbed well into the eye once daily. The boric acid and the bandage as before.

Sol. potass. chlorat. 3% is much commended both as "drops" and a lotion. Cleanliness and exclusion of germs are the important considerations.

Should the eruption be deep and central the liability to iritis is to be borne in mind, and sol. sulph. atropiæ, gr. ij. ad ʒ i., is to be instilled three times daily. The ulcer is to be cleaned with the spud. Some touch the spot with pure stick of nitrate of silver, which is greatly risky, or with a fine brush dipped in a solution gr. x. ad ʒ i. More skill is needed for these proceedings than for the spud, and the latter can be made effective. One may employ chloroform and be comparatively safe against injuring adjacent cornea with the sharp caustics. In most cases cocaine muriate 4%, or if need be, 10%, will suffice. If the eruption be on the edge of the cornea, and especially if it tend to penetrate we will use sol. sulph. eserine, gr. i. ad ʒ i., two or three times daily. It is not contradictory treatment to employ at the same time, once daily, an atropia solution to guard against danger of pupillary adhesion.

The chief remedy against photophobia is cocaine, which may be used several times daily. Besides cold water, a solution of boric acid will be grateful for the more robust, while to the weakly it must be used warm or tepid. It is of the utmost importance to heal up ulcerations of the skin of the face—at the nostrils, the mouth, and especially at the angles of the lids. Touch them with a sharp point of pure nitrate of silver and keep them well greased with vaselin or white precipitate ointment or with yellow precipitate, etc.

Should the infiltrations become deep and more distinctly purulent, one may resort to the actual cautery, using great care, because in most subjects the power of reaction is poor. The free use of chlorine water diluted so as not to be irritating, is a most valuable and helpful remedy. The eye may be washed out once an hour.

Digitized by Medical Heritage Library

Known as Labarraque's solution, it should be diluted with seven or ten parts of water. Care must be given to its purity. To carry out this treatment requires patient, resolute nursing. One person will have to hold the child, while another uses the remedies. A weak and over-tender mother will never cure one of these cases. If the child has gotten the moral victory in the struggle, and refuses to endure any light or permit any applications, Graefe's recommendation to put his face into a bowl of water until the need of breathing makes him open his eyes is a good one. Not often will a thorough sousing have to be repeated. The dropping of iced water upon the closed lids and gradually coaxing them apart so as to bring it upon the cornea, is a valuable proceeding practised in the N. Y. Eye and Ear Infirmary by Dr. Oppenheimer.

As more acute symptoms abate and especially during the stage of vascularization, the yellow oxide of mercury in vaseline or amyloglycerin, gr. ij. vel viij. ad ʒ i., is to be commended. With decided hyperæmia of the palpebral conjunctiva, a solution of nitrate of silver, gr. v. ad ʒ i., may be brushed over the everted lids, and this is proper at an early stage. Chloroform may be needed and tends to break the pernicious nervous irritability, besides affording the opportunity for effective remedies.

Constitutional and hygienic measures are never to be neglected. The domestic surroundings are often bad and may possibly be remediable; a few elementary instructions about cleanliness and pure air and suitable temperature may be needed. The necessity of cleanliness of person and clothing, and attention to food and exercise and sleep, must be strenuously enforced. Strict regard must be paid to digestion and diet. The secretions of the bowels must be regulated and the food must be easily digestible, plain and nutritious, and given at proper intervals. Milk, meat, bread and butter, oatmeal, rice and baked potatoes, are to be directed, while candy, sweetmeats, and miscellaneous food are to be prohibited. Among those who are both able and willing to provide proper food, instruction will be needed about its preparation and the frequency of its administration. The aim is to build up and invigorate tissue. Often a change of air will be helpful.

Among things of little value are tincture of iodine to the forehead, blisters, leeches. Indeed the last are to be avoided. Mild purgatives, as rhubarb and soda are sometimes useful. Cod-liver oil and iron, either as chocolate iron lozenges for children, or the syrup of the iodide of iron are standard remedies. To control the violent cases of blepharospasm, the tincture of conium maculatum has been used. In doses of two drops once in two hours it will sometimes relax spasm of the lids in a remarkable way after a few doses. But the remedy is cumulative and treacherous. Poisonous

symptoms of a serious quality are easily produced and the remedy must be used rarely and with great watchfulness. In some extreme cases cantholysis is employed to relieve the irritation of the cornea as it is squeezed by the lids. But the free use of cocaine, and atropine, sometimes of minute doses of morphia or better still of Tully's powders in doses of three or five grains, viz. ℞ Morphiæ sulph., gr. i.; pulv. gum. camphoris, ʒi.; pulv. rad. glycyrrhizæ, ʒi.; cretæ preparat., ʒi., will, aided by constitutional measures and other suggestions, above given, commonly bring this symptom under control. Everything depends on the health of the subject, on the surroundings and on the fidelity with which the measures prescribed are carried into effect. Cases sometimes continue for months, and relapses are not infrequent. But perfect and prompt cures are possible when the conditions are favorable.

Herpes Corneæ.

This affection, which is to be sharply distinguished from phlyctenula or eczema, is much rarer than the latter and presents itself under two forms. We have herpes corneæ febrilis, seu catarrhalis, seu labialis, and herpes zoster ophthalmicus. The former follows acute affections of the respiratory tract from the nose downward, or catarrh of the stomach and bowels. Horner has seen it after whooping cough and intermittent and typhus fevers. It attacks adults of middle life and not often children. There may be a single vesicle or as many as three, over any part of the cornea. Seldom will the observer chance to see the perfect vesicle; what is found is an ulcer whose margin is fringed by the torn edges of the epithelium, which has ruptured. Not alone the epithelium, but the anterior basal membrane and the outer layers of the cornea may be lifted (Haab[1]). The spot will be nearly transparent, yet in severe cases lines of grayish infiltration will radiate into the surrounding cornea (see Fig. 128). There will be active conjunctival congestion and perhaps muco-purulent secretion, extreme lachrymation, and sharp pricking pain. The surface of the ulcer, but not the rest of the cornea, will be anæsthetic. Usually, but not in all cases, there will be herpetic spots on the lips, nose, face, or eyelids. Should the case be duly appreciated and cared for, it may get well in a week or ten days. Should it occur during the progress of some serious malady which absorbs attention, it may go on for weeks. The edges may grow opaque, the ulcer extend—hypopyum and iritis ensue. It also presents a fair field for secondary and mycotic infection.

This disease has been noted by Graefe and Mooren, but the

[1] Ziegler, Haab, "Pathologische Anatomie des Auges," S. 773, 1884.

Digitized by Google

merit of distinct and forcible delineation of it belongs to Prof. Horner[1] who described it in 1871 in the transactions of the Heidelberg Congress.

Treatment.—If the vesicle has not broken, or if its base is not infiltrated, the chief indication is protection and disinfection; should there be much conjunctivitis, the lotion of boric acid, both in and upon the eye, solution of nitrate of silver 1% to the everted lids, and cocaine solution as the pain compels, will comprise the treatment. By these means I have just come through the management of one of these cases. If grayish infiltration have occurred, the base of the ulcer is to be disinfected by scraping, by touching it with a 2% solution of nitrate of silver, or with chlorine water. Atropia solution will be proper and the eye should be kept under a close band-

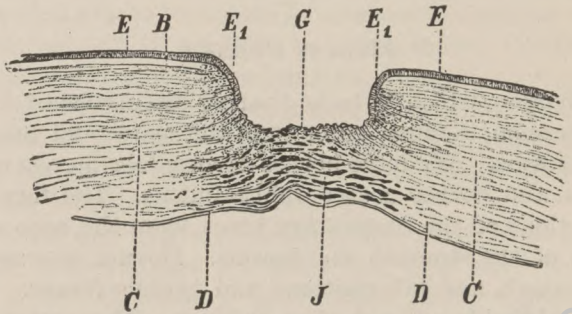

FIG. 128.—*Herpes Corneæ.* Ulcer healing—14 days since its beginning. *C*, cornea; *B*, Bowman's membrane; *D*, Descemet's membrane; *E*, epithelium covering the sides of the ulcer; *G*, base of ulcer with infiltration; *J*, infiltration beneath bottom of ulcer. × 20.

age, except as the necessities of cleansing and of the above treatment require its removal. Sometimes it will be taken off once in two hours; sometimes only twice daily. If hypopyum and iritis appear, warm fomentations of boric acid will be necessary, with atropia and other measures to be subsequently mentioned as suitable for these conditions. The disease seldom recurs, although Arlt and Horner have seen instances.

A somewhat rare and peculiar complication of superficial inflammation has recently attracted attention under the name of *filamentous keratitis* (faedchen keratitis). Small shreddy threads grow from the surface of the cornea, usually quite short, but in one instance (Czermak) 4 mm. long. They appear after erosions or wounds, and also spontaneously. They present a broad or sometimes funnel-shaped attachment; the little filament is twisted like a cord and usually terminates in a coil or knob. Leber described

[1] "Krankheiten des Auges im Kindesalter," p. 333, 1883.

Digitized by Illinois College of Optometry

them in 1882, and Czermak,[1] Nuel,[2] and Hess[3] have given drawings and microscopic studies of them. Hess presented specimens at the Heidelberg Ophthalmological Congress in 1892, and the pathological character of the outgrowths was generally conceded to be an excessively active proliferation of epithelium, which could find no other mode of expansion, and begins either from a vesicle as in a herpetic process, or from a wound or an ulcer; for example, several observers noted them upon corneæ specked with powder or dynamite granules springing from the minute ulcers during the period of acute inflammation. Sometimes the filaments disappear in a few days, sometimes they obstinately persist and grow, according to the nature of the etiological process. They have been seen in the puncture made for discission of cataract and mistaken for prolapse of capsule or of vitreous. Microscopic examination would decide the diagnosis. No special treatment is to be employed on their account.

Under the name of *herpitiform keratitis,* Decker (*Klin. Monatsblätter für Augenheilkunde,* Oct., 1890, p. 409) brings together various but kindred types of inflammation, which have been described within recent years by various authors, characterized by isolated, nodular, or rounded spots in the parenchyma, sometimes with vesicles on the surface. There is often bad nasal catarrh and constitutional dyscrasia; the rate of progress is slow, the subjective symptoms may be acute or torpid. In some instances they have followed erysipelas or some distinctly neuralgic affection.

Fuchs in his text-book, p. 189, and also in *Wiener Klin. Wochenschrift,* No. 44, 1890, describes a usually chronic disease, lasting months or even two years with exacerbations, situated in the superficial layers and presenting numerous small spots with intervening haziness. Stellwag described what seems to be a different affection, "*nummular keratitis,*" with larger spots, perhaps 1.5 mm. in diameter, situated at various depths, sometimes attended by ulcerations, sometimes by iritis. It runs its course within two or three weeks and may have acute symptoms (see *Oph. Rev.,* March, 1890, p. 78).

Pemphigus Corneæ, Keratitis Bullosa.

Yet another form of eruptive disease appears on the cornea, as it does also on the conjunctiva (see page 336), which, notwithstanding its rarity, may be briefly referred to. A well-marked case was described by Hasner[4] in 1860, in a patient who had had severe

[1] Klin. Monatsblätter, July, 1891.
[2] Archives d'Ophthalmologie, October, 1892.
[3] Graefe's Archiv f. Ophth., xxxviii., 1, 160, 1892.
[4] "Beiträge über Augenheilkunde," p. 196, Prag.

Digitized by Illinois College of Optometry

kerato-iritis. A paper by M. Landesberg[1] cites the literature and describes seven cases seen by himself. In one of these, as well as in cases described by other authors, glaucoma preceded this affection. In all of Landesberg's cases increased ocular tension attended the acute stage. He regards the disease as a peculiar phase of parenchymatous keratitis of which the lifting of some corneal layers and the epithelium is an incident. Intense pain and photophobia, great rapidity in development, a tendency to recurrence, acute congestion of the eye, immunity on the part of the iris and choroid, and deep ulceration with dense grayish opacity, are features of the disease. Arlt[2] describes the disease as a variety of *keratitis interstitialis consecutiva*, thereby meaning that some other disease, such as irido-cyclitis or glaucoma, or deep corneal lesion must precede this outbreak. In this respect he differs from Landesberg. Brugger[3] had the opportunity of examining an eye in which this disease supervened upon glaucoma. He shows that the first step is infiltration of the corneal substance with serum and nutritive fluid which cannot escape by the usual channels at the limbus. New tissue is formed between Bowman's membrane and the epithelium, which speedily degenerates, and the lamellæ of the cornea are dissevered and the fluid pushes forward the superjacent layers into one or more vesicles.

Treatment of these cases has consisted in the usual antiphlogistic remedies, to which have been added, excision of part of the infiltrated cornea (Hasner), incisions into the base of the ulcer (Landesberg), iridectomy and sometimes enucleation. The nature of each case will suggest the appropriate remedies.

Keratitis Vasculosa.

Under the above title we may designate a condition which is not primary, but secondary to some other form of disease. We meet it so often that a special designation is convenient. The surface of the cornea is rough with erosions and proliferations of epithelium, has a grayish hue and is covered by a meshwork of fine blood-vessels. The vessels (1st) may appear in a streak and run to a spot of infiltration or ulceration; (2d) they may form a well-defined fringe at the margin occupying a part or the whole of the periphery and stopping abruptly at about two millimetres from the edge; (3d) they may cover the upper half, or constitute a patch on some other part of the cornea; (4th) they may overspread the

[1] Archives of Ophthalmology and Otology, vol. vi., p. 135, 1877.
[2] "Klinische Darstellung der Krankheiten des Auges," S. 125, 1881.
[3] Monatsblätter für Augenheil., xxiv. Jahrgang, S. 500, 1886.

Digitized by the College of Optometry

entire surface. In some of the above phases there will be conjunctival and scleral hyperæmia. Persistent phlyctenular inflammation, and granular conjunctivitis are the chief causes of the conditions described. Commonly the disease is of long duration. In certain cases, especially when in isolated streaks or patches, the blood-vessels are significant of, and adjuvant to a process of repair. By their aid an ulcer is being filled up with new tissue, or the opaque elements of an infiltration are being absorbed.

In other instances the blood-vessels and the attendant lesions merely denote the irritating effect of some severe provocation—such as inverted eyelashes, the roughened palpebral conjunctiva, exposure to the air by imperfect closure of the lids, etc. When the cornea is vascularized extensively, we may have a partial, a total, a dense or a thin form of pannus.

It is common enough to have the curve of the cornea distorted in old cases of pannus; often the adjacent scleral and conjunctival tissue will be thickened and vascular; sometimes in advanced stages a yellowish dense opacity creeps into the cornea from its edge, seeming to involve its entire thickness and assimilating both sclera and cornea to each other in appearance, and is designated as *sclerosis* of the cornea. In the severe forms of vascular keratitis, iritis is common, and naturally the deeper structures will not always escape. As a matter of course vision is seriously damaged and may be reduced to perception of light; there will be pain, lachrymation, photophobia, etc. The condition is necessarily chronic.

Treatment.—It will be understood that in the above description a distinction must be made between the conditions of vascularity which are reparative in their nature and those which are not. It may not be necessary to interfere with the milder forms of reparative vascularity, while in certain cases the blood-vessels continue long after they have fulfilled any useful purpose. This we find when a leash or streak of vessels runs from the sclera into the cornea after an attack of phlyctenula. Excision of the vessels or scarification of them has been practised, but with not much advantage. Dusting calomel into the eye is useful in mild cases; but rubbing into the cornea the yellow oxide of mercury ointment once daily and with rather severe friction for several minutes is the most efficient remedy. The strength will vary from gr. i. ad ʒ i. to gr. viij. ad ʒ i. In some cases eserine sulphate, gr. i. ad ℥ i., decidedly aids the healing, used once or twice daily. But one must be watchful against pupillary adhesions and occasionally use atropia. If the vascularity is severe, atropia will be exclusively used. To the above treatment warm fomentations for a half hour, three times daily, will be helpful. The eyes will be guarded from extreme light and the general health will be well attended to. The useful effects

Digitized by Google Original from University of California

of cocaine will not be forgotten, and it may be used three or four times daily in a 2% or 4% solution.

For the extensive and dense forms of pannus, the yellow oxide ointment and warm fomentations are beneficial, but the first consideration is to remove, if possible, the cause. We must pluck offending eyelashes; cure by operation entropium of the lid; we may have to do cantholysis or canthoplasty (see p. 357), to relieve the pressure of shortened eyelids. In a large number of cases we can do nothing directly for the cornea, but give attention to the care of granular conjunctivitis.

The division of the tarsus vertically through its middle without going through the skin is available in extreme cases. We are on the same ground now as was discussed under trachoma (see p. 357). A remedy not mentioned in that connection is in obstinate and insensitive cases of pannus to apply to the cornea a drop of turpentine.

The proposals of curetting the cornea, of peritomy, of inoculating with infusion of jequirity have been already made.

Should the cornea have become soft and be inclined to develop a staphyloma, an iridectomy may be performed, despite the existence of pannus, and it should be broad. The existence of granulations is not a contra-indication, provided they are not very luxuriant—as is not likely to be the case under such circumstances, and the situation will, of course, be serious, if not desperate as to the chances for useful vision. The effect of iridectomy in mild cases of either opacity or vascularity of the cornea is to hasten decidedly the restoration to a better state. But the enlargement of the pupil is disadvantageous to sharp sight, and inasmuch as some opacity or want of homogeneity is most likely to remain, the ultimate effect of the iridectomy becomes hurtful. It must not, therefore, be resorted to while by other means the cornea may be made to clear up, and one must have signs of increased tension and developing staphyloma, before resorting to it in the cases above referred to.

A form of *superficial keratitis* dependent on *malaria* has attracted my notice for many years. Some of my cases were published by Dr. Jas. L. Minor in *Am. Journal of Med. Sciences*, 1881. The lesion is confined to the epithelium and anterior layers, it is attended by ulceration, rarely by much infiltration, although this may become suppurative. The conspicuous feature is the *blunted sensibility of the cornea* and the consequent slight photophobia. The touch of a lock of cotton will scarcely be noticed. There will almost always be tenderness of the supra-orbital nerve at its notch and pain in its radiations. There will also be a history of malaria and probably of the chronic type. Dr. Kipp, of Newark, N. J., has

Digitized by Google

reported observations of the same character and like myself is firmly persuaded of the malarial etiology of the disease. He has called attention to peculiar irregular streaks, which he has seen in some of these cases which correspond exactly to lesions published by Emmert under the name of keratitis mycotica dendritica (see below). The same type of disease was published by Hansen Grut, and is represented in Fig. 138, p. 376. I recognize the disease in the cornea and doubt not its mycotic character. That it is pathognomonic of malaria seems to me improbable, because I have seen many cases of malarial keratitis without it and have seen one extremely typical case in which the cause certainly was not malaria, but exposure to a fearful snow storm. An Irishman was engaged in digging out the Long Island Railroad from the snow-drifts of the famous "blizzard" of March, 1888, and after working three days was brought with several comrades to the N. Y. Eye and Ear Infirmary suffering with so-called snow blindness. I found the above streaks running through both his corneæ. Under cocaine I applied a very fine galvano-cautery, and relief from the intense photophobia and other symptoms speedily followed; while a weak bichloride solution procured healing of the furrows and subsidence of the inflammation within less than a week. This case was purely local. But true malarial keratitis, while it may have the nodular branching streaks, will not be cured without quinine or arsenic. Local and if mycotic striations occur, antiseptic methods and remedies will be added (see Kipp, Trans. Am. Oph. Soc., 1889, p. 331).

Keratitis Interstitialis, Diffusa, Parenchymatosa.

In this affection the substantia propria is the part of the cornea primarily involved, although the posterior layers, including the endothelium, very often are implicated. But there is no impairment of the epithelium save that in some instances it has a dull, finely molecular appearance, like the surface of ground glass; ulcerations and purulent infiltration are absent. The disease belongs to the early periods of life. It commonly appears about puberty, yet often shows itself at a much younger age, and I have seen a case whose appearance was delayed until thirty-three years of age. The cases may be mild or severe; they begin gradually, and their duration may be from several weeks to many months, or even five years (Mooren). One eye alone may be involved, or both simultaneously or successively.

Etiology.—The disease has a constitutional origin, and in the larger number the cause is hereditary syphilis. It is probable

Digitized by the Boston College of Optometry

that a few cases owe their origin to secondary, *i.e.*, to acquired syphilis. My own conviction is in favor of acute interstitial keratitis as a symptom of secondary syphilis, but I admit the difficulty of proof and that the cases are rare. More will be said on this point. It is also true, that a contingent of cases of interstitial keratitis show no distinct indications of syphilitic taint, but are classed as scrofulous subjects. In them we cannot always discriminate or know, how far unhealthiness of tissue is owing to bad hygiene, or to remote ancestral syphilitic lesion or to other hereditary dyscrasiæ. In all cases we have to do with unhealthy subjects, notwithstanding that many do in certain particulars show signs of blooming health. Not a few young girls with unmistakable signs of hereditary syphilis have plump and well-rounded forms and rosy cheeks and declare that they feel entirely well. Without actual statistics to support the statement it is my strong belief that girls are more frequently affected than boys. (Hutchinson in his original paper, I find, made this statement, founded on statistics giving the ratio as boys 1 to girls 1.8. *Oph. Hos. Reports,* ii., p. 94.) The proportion of cases which have a syphilitic origin has been indicated by Horner.[1] Among fifty-one cases, twenty-six had hereditary syphilis; two had acquired syphilis; in ten, syphilis was strongly suspected, making nearly two-thirds of the whole number. Among the remainder a scrofulous constitution accounted for a large proportion, and Arlt relates a few cases in his long experience which were due to malaria. On this point something more will be said. There remain other cases of traumatic and rheumatic, or gouty origin and we also have interstitial keratitis resulting from chronic irido-choroiditis.

Symptoms.—The outbreak is usually in haziness of the cornea, beginning either at the margin or at its centre, and it may be confined to a portion or overspread the whole surface; it is likely to be in minute spots. The polish is not perfect, because of minute depressions like pin punctures which give a dull or grayish hue. The circum-corneal hyperæmia is much less than the degree of opacity would seem to demand. Gradually the opacity grows more dense and at an early date vision is extremely reduced. Photophobia and pain will often be moderate, there is no sticky secretion and lachrymation is slight. Such are the features of mild cases. Under more severe types, we have blood-vessels appearing in the deep and also in the superficial parts of the cornea; they form a close network and sometimes the whole structure is absolutely red. The tissue softens and may yield its curve under the pressure of

[1] Thesis by Jackowlewa Pulcheria: "Ueber keratitis interstitialis diffusa," Zurich, 1873.

Digitized by the Internet Archive of Ophthalmology

the lids. There will be more intense pain, ciliary injection, and photophobia, and copious lachrymation. An abundance of vessels in the cornea bespeaks a protracted case. Often iritis adds its quota of misery and mischief. One may sometimes discern through the fog by the ophthalmoscope, dark streaks and numerous dots which denote the participation of the deep and posterior layers. Seldom can the pupil be illuminated, even in mild cases. A few days may suffice for the whole cornea to become hazy. The duration is from three to twelve months. Perfect recovery may occur or a most damaging opacity may remain. Seldom in the fortunate cases, is the cornea restored to a perfectly normal structure, even though it appear clear.

The symptoms which indicate a syphilitic taint are glandular enlargements, epecially in the neck, nodes on the bones (the tibiæ, clavicles, sternum, ulna), a peculiar facies in which the nose is sunken and the upper jaws are imperfectly developed. The teeth will command careful inspection. The incisors will be small, coni-

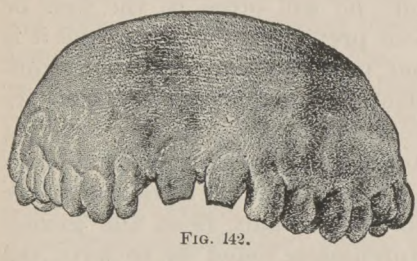

FIG. 142.

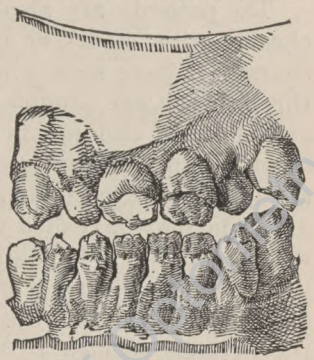

FIG. 143.

cal, with wide interspaces, and the edges either bevelled off or notched at the middle. The central incisors of the upper jaw are the distinctive teeth. They are not apt to be carious, but while often of bad color, they may be very white. The lateral incisors may be similarly affected. The incisors of the lower jaw may or may not be affected. No absolute uniformity is to be predicated of the characteristics of the teeth, but they are ill-developed, may be irregular, by their notches show a crumbling disposition, or if regular are dwarfed. The cut, Fig. 142, is from a plaster cast of teeth belonging to a young girl in whom the syphilitic symptoms were unmistakable, and the keratitis of the typical sort. In scrofulous children the front teeth sometimes look as if part of the crown had been filed off at about the middle and parallel to the gum, leaving the distal end much thinner than the basal part with an abrupt transverse ridge running across it. They have been described as terraced. They are dark, are seamed and soft, but

Digitized by the Internet Archive of Medicine

they do not indicate syphilis. They are declared by Horner and others to denote rickets or scrofula: while this may sometimes be true, it is not the only explanation. The accompanying Fig. 143 is taken from a plaster cast of the teeth of a young lady who never had keratitis, and her father, a physician, knows that there has been neither syphilis nor scrofula nor rickets, or any hereditary taint in the family for three generations. The deformity of the teeth was caused by an attack of sickness during the second dentition, by which their development was arrested and impaired.

Radiating fissures or scars are apt to be found on the lips or at the angles of the mouth. The skin is usually coarse and flabby, although exceptions occur. There is generally anæmia. The flattening of the nose is noteworthy. There is nasal catarrh, often amounting to ozæna. The vault of the hard palate is narrow and the roof of the mouth is thrown into a high and narrow arch. We may be told of the existence during childhood of snuffles and perhaps of eruptions about the anus or elsewhere.

The patients are also prone to deafness, either by subacute or chronic otitis media, or by suppuration of the middle ear with discharge. I have seen a patient become totally deaf after passing through the eye trouble with fortunate result. If the patient be one of many children in the family, he will often be the first or second born. There may have been previous still-births, and it is always important to inquire about miscarriages, and about children who may have died young. Hutchinson found that 53 mothers who had borne 371 children whose average age was 9½ years, had lost 192. Sometimes a clear statement and admission of syphilis can be obtained from the parents. Mooren[1] found instances where the syphilis seemed to have been derived only from the grandparents. Out of 64 cases, Mr. Hutchinson found 53 to have the attack in both eyes, although more frequently in succession and not together. Although seldom, a second attack may happen to the same eye. My belief that *acquired* syphilis can cause parenchymatous keratitis is corroborated by Alexander,[2] who mentions, p. 41, having seen thirteen cases and others have reported isolated cases; see Mauthner and others in the literature quoted by Alexander. It comes as a late symptom, viz., two or three years after the initial lesion, and resembles that due to hereditary disease. Ulceration does not occur, but by the softening of the corneal tissue it may undergo serious change of curve and even become staphylomatous (Symons, Oph. Soc. United Kingdom, 1886, July 2d). The disease will yield only to antisyphilitic treatment.

Prognosis turns much upon the general state of health and

[1] "Fünf Lustren Ophthalmolog. Wirksamkeit," p. 111, Wiesbaden, 1882.

[2] "Syphilis und Auge, Wiesbaden," 1888.

upon the intensity of the syphilitic symptoms. Should the case belong to the scrofulous rather than to the syphilitic type, the outlook is scarcely more favorable, perhaps it is less favorable. It is surprising how notably a densely opaque cornea may clear up, but the contrary is too often the result. A highly vascular cornea with yellow or buff infiltration of its deep layers, is not likely to give useful vision. A word as to the next generation. I have seen the child of a mother who had had interstitial keratitis with characteristic symptoms of hereditary syphilis, not have any tokens of syphilitic taint. But its health was delicate, digestion feeble, nervous system highly excitable; these conditions were aggravated by the indiscreet indulgences of the mother, regarding the child's habits of eating and living.

Treatment.—Both local and constitutional methods are essential. Local treatment is the steady, prolonged, unvarying use of hot fomentations or poultices for three hours to eight hours daily; making periods say of two hours each, or of one hour each at equal intervals. The more severe the case the longer must be the duration of fomentations. A bunch of absorbent cotton, or of soft rag wrung out of water whose temperature is 104° F. or 108° F. (39° C. to 49° C.) is to be held on the eye until it feels cool and then dipped and replaced. Much higher temperature will be accepted, or even demanded, after prolonged use. I have known a young girl to insist on having the water at 120° F. No treatment can take the place of this. It is wearisome, but the patient can have no other occupation, even if only one eye be concerned. It is wise to use atropia to guard against adhesions of the pupil, but it does little good to the cornea. No irritating remedies are in order, until the hyperæmia of the ciliary region has greatly declined, and then the yellow oxide of mercury ointment will do good service, rubbed in once daily.

Anti-syphilitic treatment must in the proper cases be instituted at the outset. If there be a doubt as to the existence of this taint, it is often safe to assume its presence. Mercurials are well borne by children and in my judgment they are more important than iodides. With them, iron, cod-liver oil, and other tonics are to be combined. The best and most nutritious food, and attention to the digestive functions, the use of meat and milk, and in suitable cases insistance on outdoor exercise, protecting the eyes with smoked glasses, are all matters to be cared for. Mercurials are best given by inunction, using either the blue ointment or the 20% mixture of the oleate of mercury. The latter is more energetic than the former and more liable to irritate the skin. In some cases a strip of flannel smeared with blue ointment may be worn about the body. Hydr. bichlor., gr. i.; aquæ, ℥ viij., a teaspoonful

three times daily, is an easy formula for children. Most writers advise the addition of iodides to the mercurials, but for many years I used the latter without the former and with satisfactory results. Ptyalism must be carefully avoided. Syrup of the iodide of iron, Blancard's pills of iodide of iron, a combination of mass. hydrarg., gr. iij. vel v.; ferri sulphat. exsiccat., gr. i. Fiant pilulæ, one three times daily, are all useful remedies. In very feeble subjects quinine and pyrophosphate of iron or similar combinations are indicated. Only when a certain degree of strength is present can solutions of iodide of potassium or sodium be borne. Mr. Hutchinson was in the habit of prescribing mild mercurial ointment to be rubbed into the axillæ, on the neck, etc., at bedtime, and also a mixture containing iodide of potassium, iodide of iron, and tincture of nux vomica.

It must be remarked that very weak or cachectic subjects will not bear specific remedies. For them vigorous tonic and nutritive measures take the first and exclusive place. In deciding upon the line of proceedings, one must take all the conditions of the patient into consideration. This holds good even though syphilitic taint be certain.

For cases which exhibit no specific symptoms, local measures and attention to general health will alone be required.

Keratitis Suppurativa and Ulcerations of the Cornea.

The conditions spoken of do not invariably accompany each other, but are so usually coupled together as to make it convenient to discuss them under one head. Suppuration most frequently begins at the surface and leads to ulceration. If an ulcer exist, the loss of substance has in many cases been preceded by suppuration. Besides superficial suppuration, we meet with purulent infiltration originating in the deep layers, and we also have cases of total suppuration of the whole structure.

The process may be traumatic, it may come from purulent conjunctivitis, it may be derived from an active suppuration in deeper parts of the eye, in some cases it comes with great rapidity in a marasmic child (kerato-malacia), it attends upon anæsthesia of the cornea and is combined with ulceration, and it may be both traumatic and infectious. Within a few years we have learned the immeasurably momentous influence of micro-organisms in causing corneal suppuration. They are its immediate promoters in the large majority of cases. This is eminently, if not exclusively, true of the superficial varieties. We cannot always account for their presence, but we have no difficulty in accounting for them in many cases of injury by foreign bodies, or when the eye is exposed to the air through anæsthesia of its surface, or when the secretions

Digitized by Harvard College Library

of an inflamed lachrymal sac flow over the eye, etc. They may be conveyed by metastasis through the general circulation, and this occasions the most intense and overwhelming forms of suppuration. In 1873, Stromeyer[1] published experimental researches into the causes of hypopyon-keratitis. In the same year Leber[2] wrote on inflammation of the cornea by septic infection. In 1875 Horner[3] presented specimens of an ulcer of the cornea which had occurred in a case of erysipelas of the face and which were filled with bacteria, and he called the disease mycotic keratitis. Two years later he exhibited to the Heidelberg Congress a similar lesion from a child with marasmic ulceration of the cornea

He did not venture then to call the bacteria the exciting agents of the process, but since then we have accumulated abundant evidence in favor of this belief. It has been repeatedly shown that the inoculation of the cornea with pure cultures of certain bacteria, will surely bring on suppuration and ulceration. It has been shown that this occurs if putrefying matter is used, if diphtheritic exudation is used, and with the aspergillus glaucus (Leber[4]) which ranks higher in the scale of life than the cocci. A wound made by a knife tainted with certain bacteria will suppurate, if made with a sterilized knife it will not. Erysipelas is occasioned by a micrococcus in the skin, the same can cause ulceration of the cornea. See Haab, l. c., p. 777, who gives an illustration of such a mycotic keratitis. It is also true that a suppurative action may be set up by organisms floating in the blood, as in cases of pyæmia and similar diseases. The subject is most suggestive and practical in its nature and leads to important conclusions both as to prevention and treatment. Bearing these facts in mind, we are greatly aided in understanding and in dealing with ulcerations and suppurations of the cornea.

In depicting the various phases of corneal suppuration we can refer to only a few conditions; such as; 1st, small specks of superficial infiltration; 2d, hypopyon-keratitis, or *ulcus corneæ serpens* (Saemisch); 3d, neuro-paralytic keratitis; 4th, kerato-malacia; 5th, keratitis xerotica; 6th, consecutive ulceration as in conjunctivitis or in deep inflammations of the eye.

---

[1] Graefe's Archiv, xix., Abth. 2, S. 1.

[2] Centralblatt für die Mediz. Wissenschaft., S. 129, 1873.

[3] Klin. Monatsblatt für Augenheilkunde, xiii., p. 442.

[4] Graefe's Arch. für Oph., Bd. xxv., Abth. ii., S. 285, 1879.

Digitized by the Internet Archive

1. *Small superficial Infiltrations. Keratitis superficialis purulenta discreta.*

We frequently see purulent deposits on the cornea which are from one to three millimetres in diameter with a yellow centre, a hazy border and sometimes with whitish streaks running into them. Severe forms of phlyctenulæ take on this type and are most frequent among children, but we find them among adults as the result of infection.

The most common cause assigned for them by patients is the intrusion of foreign bodies; but while they may often enough do the mischief, other sources of infection are plentiful; such as wiping the eyes with dirty fingers, with soiled rags and handkerchiefs; the patients will sometimes have ozæna or ulcers of the septum nasi, or will have lachrymal trouble, etc., etc.

There will be circum-corneal redness, pain, photophobia, and lachrymation, and dimness of sight. The subjective symptoms vary greatly in intensity. When they are severe, the frequent use of 4% or 8% solution of hydrochlorate of cocaine gives great relief, and to this atropia sulphate, gr. ij. ad ℥ i., may be added once or twice daily. Hot fomentations are grateful. But the effective treatment consists in scraping out the yellow infiltration with a spud after the full effect of cocaine has been procured and then occluding the eye with a pressure bandage. (Sometimes the yellow oxide of mercury ointment may be immediately rubbed in.) Keep this on so long as it feels comfortable, say for six or twelve hours, and then foment for half an hour with a warm 3% solution of boric acid or of corrosive sublimate, 1 to 5,000, or with warm water. The warm applications may be renewed for one-half hour every two hours. The loss of substance soon shows signs of repair and recovery sets in. A similar effect is obtained, though less easily and perfectly, by touching the yellow spot very carefully with a fine brush dipped in solution of nitrate of silver 6% (gr. xxx. ad ℥ i.) or of carbolic acid 20%, or of corrosive sublimate 1 to 2,000. By these chemical methods, the germs are destroyed, but a risk of injuring healthy cornea is incurred which does not attend mechanical removal of the yellow deposit. To promote healing of the ulcer the yellow oxide ointment, gr. ij.–vi. ad ʒ i., may be rubbed in once daily, after the irritation has subsided.

Digitized by Illinois College of Optometry

2. *Hypopyum Keratitis. Ulcus Corneæ Serpens.*

The condition thus denoted is more serious than the preceding. Besides purulent infiltration, ulceration attends it, and in most cases (*i.e.*, 80%) there will be pus in the anterior chamber (hypopyum). While it has various grades of intensity, it is always a grave disease. Vision is rarely perfectly recovered, and the proportion of cases in which the eye is entirely lost may be as high as 19.2%.[1] In Arlt's[2] clinic, the total loss was 9.5%; in Horner's,[3] it was 14.2%. Young persons may have it, but a large proportion of its subjects are above middle life; it chiefly appears among the old and feeble. It may have an acute and sthenic character, but it commonly is torpid in its behavior, although none the less destructive.

Etiology.—In many instances there has been an injury, especially by chips of stone or metal flying from a workman's hammer. The traumatism gives opportunity for infection by microscopic germs. If they are not introduced by external agencies, they are in many cases furnished by the secretions of dacryo-cystitis. The striking fact has been proven that from 20% to 32% of the cases have this complication. Still more direct proof of infectious origin is found in the fact that the disease in all its phases can be artificially produced in rabbits by inoculation of pure cultures of the coccus pyogenicus aureus, and other germs. Stromeyer[4] established the same fact in 1873 by the application of putrescent material and showed that the reaction after the infection was much more intense, although the wounds were trifling, than when the wounds were clean, even though they were extensive.

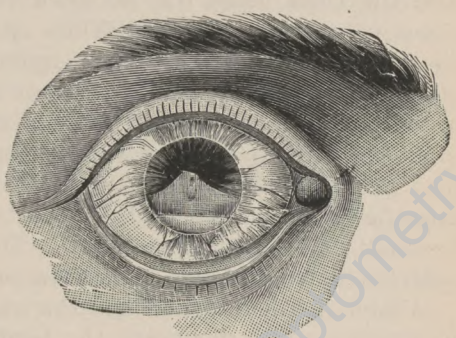

FIG. 144.

The presence of pus in the anterior chamber as well as in the cornea is explicable in several ways. It may find its way through the posterior surface of the cornea, or may creep down between the membrane of Descemet and the corneal substance, and filter

[1] Lucanus, "Ulcus corneæ serpens," inaug. dissert., Marburg, 1882, p. 21, Clinic of Prof. Schmidt-Rimpler.

[2] Bergmeister, Klinische Monatsblätter, 1874, pp. 78–87.

[3] Bokowa, Inaug. dissert., Zurich, 1871.

[4] Graefe's Archiv, xix., 2, S. 26.

Digitized by Illinois College of Optometry

through the ligamentum pectinatum. In addition, the exudation comes from the iris, because inflammation of the iris and ciliary body is the usual accompaniment of the disease. Sometimes a distinct streak of pus can be traced from the ulcer to the bottom of the cornea. The quantity of hypopium is in a measure proportionate to the severity of the attack. A considerable collection of pus between the corneal layers (*onyx*) is not so frequent as hypopium, and may be distinguished from the latter by focal illumination and by the circumstance that it will not alter its form or situation when the patient lies upon his side or hangs the head well forward.

The *course and symptoms* are as follows: In the sthenic cases the attack is sharp, there is acute, sometimes agonizing pain and photophobia. The hyperæmia is not extreme; it is confined to the vicinity of the cornea; there is no chemosis or swelling of the lids; secretion is chiefly watery, but as the disease advances becomes puriform. Very often the middle of the cornea is the spot attacked and the chief lesion will be upon the lower half. At the outset there will be a small bright yellow spot with ulceration, surrounded by a hazy areola. The aqueous humor will be a little turbid and a slight yellow precipitate soon shows itself at the bottom of the anterior chamber. If not already visible it may be brought to view by letting a drop of water brim over the edge of the lower lid. Rapidly the ulceration and infiltration spread, and pain shoots into the brow and temple, besides attacking the eye. The pupil will be small and the iris discolored. The illustration, Fig. 131, shows both extensive purulent infiltration of the cornea and hypopyum.

Under asthenic conditions the onset is not so distressing; the hyperæmia quite moderate, the tendency to ulceration is more decided than to infiltration, although the bottom of the ulcer is a yellowish gray. A patient may permit the process to go on until a considerable part of the lower half of the cornea is involved before applying for aid. Such an occurrence is, in fact, frequent, and during the one to three weeks which have elapsed, the suffering has not been intense. Meanwhile pus has been accumulating in the anterior chamber, and it may be half full. The material is fibrinous and plastic as well as puriform. If the process be unchecked, perforation occurs with prolapse of the iris and general suppuration of the eye. If this be not the turn of affairs, the cornea bulges as the iris protrudes in a black bead, pus finds vent, perhaps the lens escapes; a staphyloma corneæ is formed. It is not necessary to try to depict the various phases of the destructive stage of the disease. We see it often in old people under the guise just sketched.

Treatment.—If seen early, when the ulcer is small and the hypopyum slight, great relief will be afforded by fomentations with

Digitized by Google

hot water and by solution of sulph. atropiæ, gr. ij. ad ℥ i., once in three hours. Hot water may be used for half an hour, and the eye closed for half an hour. If pain be severe, give an anodyne, perhaps hypodermatically. The ulcer, if small, may be scraped with a sharp spud or curette. If it be more than two millimetres across and the purulent infiltration extend for a considerable space around, the best remedy is the actual cautery. A special electrode has been made for this purpose, and the thermo-cautery of Paquelin has been reduced to such fineness as to be eminently suitable. If these implements are not at hand, a knitting needle heated by an alcohol lamp may serve passably well. The cautery, if limited accurately to the infiltration gives no pain. It will, however, be proper to use a 4% solution of cocaine, or with children an anæsthetic. With the galvano-cautery great care must be used not to let the point go too far, although all the infiltrated tissue must be burned.

In case a suitable cautery is not available, I can fully coincide in the suggestion of the late Dr. E. Williams,[1] who recommends pure carbolic acid to be applied "by means of the bulbous end of a very small probe and confined rigidly to the ulcerated surface." Dipping it *very* lightly in the acid, all parts of the ulcer are touched until they turn white. Minute adjacent abscesses are also touched or rather bored out by the probe. Such an application may be made once a day until the ulcer is checked. The cautery will not need repetition so often. Some prudence is necessary in the choice of cases, because an additional amount of opacity may be produced by the cautery. It is in the early and progressive stage that it may most confidently be employed.

All the measures suggested for treating the ulcer, viz., scraping it, the actual cautery, and the carbolic acid, are similar in intent because they destroy pernicious germs, and thus check the spread of the disease.

In moderate cases hypopyum will spontaneously disappear. Often paracentesis will give great relief from pain, and it may be done at the lower edge of the cornea or better through the ulcer. If the ulcer be deep, and nearly central, reaching almost to the membrane of Descemet, but is not more than three millimetres across, a very fine cautery may be pushed through its bottom and will evacuate not only the aqueous humor, but bring the hypopyum to the opening, where it may be pulled out by forceps. It is usually tenacious from the admixture of fibrin. One will not always succeed in this manœuvre, and it is better, when there is considerable pus, to make a broad incision to be sure to bring out the exudation.

[1] Report of the Fourth International Ophthal. Congress, p. 102, London, 1873.

Digitized by Google

The treatment of ulcus corneæ serpens by a free incision across the whole ulcer, as formulated by Saemisch, was a great advance upon previous modes of treatment. But if seen early, the necessity of the extensive incision across the whole cornea may be avoided by the cautery.

Should the ulcer be large, say six millimetres, and the pus copious, we have the choice of two methods. The one is to cut across the cornea with a Graefe's knife through the middle of the ulcer and evacuate the pus (Saemisch). The wound will usually not need to be opened again; the secretions flow away continuously. The eye must be washed out with antiseptic fluids, preferably with diluted Labarraque's solution of chlorinated soda, 1 to 5, or with corrosive sublimate, 1 to 3,000, as often as the formation of secretion requires. Similar antiseptic lotions are suitable in the milder cases just mentioned. Hot fomentations will be alternated with a pressure bandage. The details of management will be controlled by the facility with which the eye can be kept clean. Immediately the necrotic tissue is eliminated and healing begins, although sometimes the ulcer will for a time extend. Usually, but not always, the iris is caught in the wound.

The case will require several weeks for complete healing. There may be sufficient clear cornea left to permit an iridectomy. On the other hand, a staphyloma may be formed which may need occasional puncture to restrain its growth, and it may subsequently require iridectomy or other operation. Still another termination is that the whole cornea may be ravaged, may leave no opportunity for improvement of sight, and may flatten down into an opaque cicatrix.

The alternative to the treatment by Saemisch's incision is to perform an iridectomy, as advised by Graefe, and at the same time take out the hypopyum. The wound must be large, and preferably it will be above; yet one may be obliged to choose another locality. If the secretion be cohesive it can be readily removed. But sometimes it has no tenacity and must then be washed out of the anterior chamber. This may be done by a rubber bulb syringe, using a 3% solution of boric acid, or solution of biniode of mercury 1 to 20,000, or of corrosive sublimate 1 to 5,000. The last two fluids have the great advantage of coagulating the secretion, but may possibly cause opacity of the endothelium. Forcible irrigation of the wound will carry the fluid into the anterior chamber. Panas has a special piston syringe whose point is carried through the wound and of course acts more directly, but demands great care. Ordinarily one must also resort to forceps.

For the most severe cases the complete division of the ulcer will be preferred. If the quantity of pus is moderate, the ulcer deep but limited, and a considerable part, perhaps one-half of the

Digitized by Google

cornea clear, a broad iridectomy with irrigation of the anterior chamber will both check the disease and provide an artificial pupil.

Since the value of the actual cautery has become known, it will not be so often needful to resort to an operation, or a less extensive paracentesis will suffice. An important practical point is to know when the cauterization should be repeated. When the cornea has grown very thin and new spots of infiltration appear, one may fear to employ so potent a remedy; nevertheless, several applications may be needed, each being done with caution. The reaction is slight. It is not safe to use it upon a prolapsed iris projecting in the middle of an ulcer. Extension of suppuration into the interior of the globe has thus been produced (Knapp[1]). So long as the edges of the ulcer are infiltrated with pus they may be burned until the process ceases. But upon the surface of a deep ulcer after one good cauterization, one may be content to apply sol. corrosive sublimate, 1 to 2,500, or 1 to 2,000, or the aqua chlori or liq. sodæ chlorinatæ diluted, 1 to 7. Such topical dressings, limited to the ulcer by a small swab, may be repeated two or four times daily and weaker solutions with much greater frequency. Iodoform has undoubted value. It must be in extremely fine powder and dusted upon the cornea twice daily. It may be mixed with vaseline. Aristol will serve the same purpose and is void of objectionable smell. Pyoktanin has failed to justify the warm encomiums of Stilling. Known as methyl blue and methyl violet it has been extensively tried, and while by some it is much praised in treating purulent conjunctivitis, phlyctenula, and corneal ulcers, the weight of opinion is that it is not better than remedies already in use. It is not poisonous, is a true antiseptic, and is used in sol. 1 to 1,000 (see *Centralblatt für Augenheil.*, Supplement, 1892, pp. 504, 505, etc.). Tincture of iodine to the ulcer is much praised by Chibret.

Application of pure carbolic acid by a probe is likewise, as I can testify, effective. It must be accurately used to the infiltrated puriform edges and spots, and the surface drenched with sol. boric acid, etc. (Dr. E. Williams).

In spite of treatment, sometimes because of extreme debility, or because of neglect to apply seasonably for aid, suppuration may extend to the interior of the globe. It may take on a chronic comparatively painless course ending in shrinking, or there may be great swelling and chemosis, orbital cellulitis, exophthalmus, violent pain and constitutional reaction. Under the latter circumstances, the eyeball should be freely opened, the lens evacuated and the vitreous allowed to escape. Many times have I wiped out the contents of the sclera with a sponge (*evisceratio bulbi*) as I stated in

[1] Transactions American Ophthal. Society, 1885, p. 44.

Digitized by Google Columbia University

1872.[1] This will not always relieve the orbital infiltration, and it may be needful to divide the deep part of the sclera to give vent to the fluids. Enucleation gives more complete relief, but it is attended with much bleeding, is a severe and unwelcome operation and is not without risk to life (see on Enucleation of Eye). The age and condition of the patient must be well considered before resorting to it. Evisceration will in the end afford a better stump for a glass eye, than will be left after enucleation. In hospital practice enucleation will be more frequent, because the patients are more quickly enabled to return to work. Still another mode of dealing with suppurative panophthalmitis is proposed by Chibret,[2] viz., to make a large incision in the cornea, to open the capsule and let out the lens—the fluid pus escapes; to pick out with iris forceps all thick and cohesive purulent material; to inject a solution of corrosive sublimate, 1 to 2,000, repeatedly, until the fluid returns perfectly clear and until by picking and washing all pus is removed. Then to stuff the eye with absorbent cotton smeared with iodoform ointment and cocaine; over all a compressive bandage (a sterilized sponge would be better because less likely to need removal). The bandage to be changed once in twenty-four hours, and for two or three days the injections to be repeated. Chibret declares this proceeding much superior to those above described, and it deserves a trial. If the suppurating eye is left to itself, the case goes on slowly and painfully; the sclera perforates in several places, the discharge is copious and offensive, the health suffers, and after weeks or months the eye shrinks to a stump.

Neuro-Paralytic Keratitis.

By paralysis of the fifth nerve or of its ophthalmic branch both the cornea and conjunctiva lose sensibility. In consequence ulceration and suppuration of the cornea occur. It has been proven both experimentally and clinically that the immediate cause lies in the diminution of the impulse to winking, and the consequent drying of the surface of the cornea, the shedding of its epithelium and the penetration of foreign particles and germs. If the cornea alone have become anæsthetic, as happens after optico-ciliary neurectomy, the sensibility of the conjunctiva and the function of the lids remain and no harm ensues. If total anæsthesia of the front of the eye exist, and the lids be kept closed, the cornea remains intact.

Formerly the cause of the lesion was thought to be due to im-

[1] Report of Fourth International Cong., London, p. 27, 1873.

[2] Archives d'Ophthalmologie, quoted in The American Journal of Ophth. (Alt), Feb., 1887, p. 55.

Digitized by the Internet Archive of Optometry

pairment of trophic fibres which preside over the nutrition of the cornea and which accompany the sensitive fibres of the nerve. Even now we cannot utterly refuse to admit such an influence, because in some cases not only has the cornea become inflamed, but ulceration of the skin of the forehead has occurred (Higgins).[1] The process is very slow and naturally painless. Ocular tension is usually slightly reduced. The striking feature is that severe conjunctival and corneal disease displays itself, with perhaps copious purulent secretion and infiltration, without pain or photophobia. The disease is happily not frequent, but if not understood is very destructive.

There may have been severe neuralgia preceding the anæsthesia. The cause will be some lesion of the fifth nerve or of its first branch either below or above the ganglion of Gasser: by an injury, a tumor, syphilis, tubercle, etc., etc. See E. von Hippel, Graefe's *Archiv*, XXXV., 2, S. 217, who attributes the lesion to the loss of the stimulus which the fifth nerve supplies, to production of moisture from conjunctiva and lachrymal gland; also, de Schweinitz, *Archiv für Augenheilkunde*, XXV., 1, 2, 152. Gaule (*Centralblatt für Physiologie*, V., 15, 409, and 22, 689) saw lesions of the epithelium and of the corneal corpuscles under the microscope in fifteen minutes after section of the ganglion of Gasser; of course the want of moisture could be contributory to such lesions, but not essential and primary. His experiments are very suggestive and leave us still uncertain as to the true meaning of the process (see p. 161, where a lesion almost certainly in the pons caused mild neuro-paralytic keratitis). See Knies, "Die Beziehungen des Sehorgans," etc., p. 214, Wiesbaden, 1892.

Treatment consists primarily in protection of the eye. To this will be added warm fomentations, antiseptics, paracentesis, iridectomy, and other means already mentioned. I have not used the actual cautery in such a case. The use of vaseline on the cornea will be sufficient in mild cases, and is always worth trying. A striking illustration of the importance of protection was as follows:

A man, aged 66, had a tumor behind the angle of the lower jaw which had been growing for more than 50 years. It caused total paralysis of both the seventh and the fifth nerves of the right side. He was unable to shut the eyelids, and the insensibility of the surface affected not only the eye, but the cheek, the lids, the forehead, the cavity of the mouth and the nostril of the right side. There was conjunctivitis, ulceration of the cornea, and hypopyum. Closure of the lids by india-rubber plaster brought some improvement, but to make the protection effective the outer halves of the upper and lower lids were pared just within the lashes and united by sutures.

[1] Medical Times and Gazette, ii., p. 856.

Digitized by Illinois College of Optometry

After they grew together the destructive process in the cornea was subdued. The patient died not long after from erysipelas. It is worthy of remark that in spite of the trigeminal anæsthesia there was at times severe pain in the forehead and temple of the same side.

Besides protection of the eye, electricity has in some cases seemed helpful, that is, by the constant current: Nieden[1] reports benefit from hypodermic use of strychnia in two cases which were due to injury of the head.

When an acute attack has passed and left an opacity of the cornea it may become necessary to perform iridectomy for restoration of vision, and by proper precautions any further trouble may be prevented. For a patient who had paralysis of the fifth and seventh and other nerves of the right eye and atrophy of the optic nerve of the left, and in whom acute keratitis occurred, vision was partially restored by iridectomy, and was secured by wearing a bandage at night and using vaseline upon the conjunctiva and cornea several times daily. In another case for whom I performed iridectomy to arrest the active process, the patient aided me in the operation and felt no pain until section of the iris, which exhibited its usual sensibility.

Kerato-malacia.

This term describes a rapid and destructive suppuration of the cornea, not preceded by paralysis of the fifth nerve, but ensuing after very debilitating diseases. It occurs chiefly in children after scarlet fever, or exhausting diarrhœa, or typhoid fever; in the marasmic; it has been seen in hereditary syphilis; it has been described as occurring after encephalitis. A state of torpor and insensibility with imperfect closure of the lids invites the entrance of foreign bodies and of infectious germs, and thus practically puts these cases under the same category with those described in the preceding section. Adults may also be affected, as in cholera or scurvy, or low fevers, etc., etc. Naturally there will be little or no pain, and the conjunctiva will show at the outset but little vascularity. The conspicuous symptom is the infiltration of the cornea. This may at first be circumscribed, and be confined to the inter-palpebral opening and gradually enlarge both in surface and depth—or in some cases the whole cornea may be rapidly involved and within two or three days become a yellow slough. One eye alone or both may be involved. Such a condition has been observed in connection with that form of mycotic conjunctivitis described by Leber as conj. xerotica, which is characterised by small, scaly, glis-

[1] Arch. f. Augenheilkunde, xiv., ii. and iii., S. 249 (German ed.).

Digitized by University of Michigan Library

tening white patches upon its exposed ocular surface, and which are colonies of bacilli.

A similar purulent destruction of the cornea sometimes follows operative wounds, as after cataract extraction. Whether infection from without will explain all of these cases is doubtful; they occur in spite of antiseptic precautions, and among the very feeble and the very fat.

Prognosis is bad, and often death ensues. All that is to be said about treatment has been previously stated.

Ulcers of the Cornea.

Reference has already been made to ulceration of the cornea as an accompaniment of acute inflammations, but we meet with it also as a primary affection, and even if it is secondary to some other disease, it often is the subject of anxiety and attention. We may deal with ulcers as progressive or stationary or regressive. Their position is of importance; if within the pupillary region they inevitable implicate vision; if near the limbus, they are less liable to damage sight, but if they go deep they may give rise to dangerous cyclitic inflammation. Severe ulcers are apt to be attended with iritis.

A progressive ulcer usually has a grayish bottom and steep or undermined edges; it will cause pain: when stationary it is apt to be shallow, semi-transparent and with sloping edges and not painful; when healing it is apt to be vascular and there will be vessels running into it from the adjacent parts; it may not be clear, but color will be a bluish white instead of a dirty gray. There may be many minute ulcers. Sometimes a torpid facet remains for months with very little change. The healing process always requires weeks or even months.

A progressive ulcer may advance either in depth or extent or both. If it go deep the posterior elastic lamina always offers the most resistance and will sometimes bulge as a vesicle before it gives way. Perforation may occur at one point, or, rarely, at several. As the aqueous humor escapes, the iris presents in and adheres to the opening, forming *anterior synechia*. This attachment is generally permanent, and if the ulceration is large, when healing occurs, there will be an opacity, a change of curve in the cornea and distortion of the pupil, *leucoma adhærens*. When perforation is exactly central and small, the lens falls against the cornea, proliferation of the capsular epithelium takes place, adhesion continues for a time and as the normal state returns the lens recedes, leaving a white mark at its anterior pole and sometimes a delicate thread leading to the

Digitized by Harvard College Library

scar on the cornea to denote the exudation which has been thus stretched out, and perhaps has been broken.

In certain, not frequent, cases where the pupillary edge has been caught in a perforation, the hole is not fully occluded by exudation, its sides become lined by epithelium, and a permanent aperture remains, a *fistula corneæ*, through which the aqueous constantly leaks.

After large perforations we may have escape of the lens, or perhaps of the vitreous, and the end may be either *phthisis bulbi*, or *staphyloma*. In most cases, whether the lens do or do not escape, the iris prolapses, and partial or total staphyloma ensues.

An ulcer in some cases increases in extent and not in depth; an instance is the so-called *ulcus rodens* (Mooren) which begins at the margin and creeps centripetally over the whole cornea. It has a grayish bottom and undercut edges; blood-vessels quickly come into it. It makes steady and rather slow progress and it obstinately resists treatment. Mooren[1] describes four cases, in all of which the sight was lost. Sattler has used the galvano-cautery to advantage; Schmidt-Rimpler brought one case through, by antiseptics, warm fomentations, and scarification of the vessels. One case under my care was vainly treated by occlusion and other means and finally yielded to Saemisch's incision. For such cases (see Jany[2]) scraping the bottom and edges, the actual cautery, antiseptic lotions, occlusion, and perhaps paracentesis, will offer the best chances of success; these being aided by other means to be presently mentioned. Another kind of progressive ulcer begins at the edge of the cornea and ploughs a furrow around its periphery; often strangely transparent. It is called the ring ulcer. It occurs in the feeble, especially the old, and it can make rapid havoc of the eye. There will be little pain and not much hyperæmia, but prolapse of the iris and loss of the eye too quickly come to pass. The feebleness of the subjects makes treatment of little avail against a process which probably is of infectious origin, although no investigations on this point have yet come under my notice. Fortunately such cases are not common, and to them the same rules of treatment will be proper as to the preceding. Sometimes the disease is more slow and then gives a chance for treatment.

In general it may be said that to check a progressive ulcer we must resort to antiseptics: sol. sodæ chlorinatæ, 1 to 7, or corrosive sublimate, 1 to 1,000, or iodoform in powder or ointment 10%, or sol. nit. arg. 2%, with a small fine brush to the bottom of the ulcer. The edges may be scraped or touched with the actual cautery; all dead

[1] Ophthalmiatrische Beobachtungen, 1867, p. 107.
[2] Centralblatt f. Augenheilkunde, June, 1885, p. 162.

Digitized by Google

tissue is to be removed. We may use pure carbolic acid on the tip of a probe with a steady aim and light touch. We may do paracentesis more or less free; iridectomy may be suitable if iritis is already established, but the simpler operation of paracentesis, as a rule, is better at first. If the ulcer be near the middle of the cornea atropia should be used; if it be marginal, sulphate of eserine, gr. ss. or gr. i. ad ʒ i., is to be preferred. The latter remedy sometimes provokes iritic adhesions and should not be used in strong solutions. One may even use sulph. atropia once daily and sulph. eserine twice or three times daily in certain cases. Sol. cocaine 4% and eserine, gr. i. ad ʒ i., are to be highly commended. To the above we may add warm fomentations for periods of an hour several times daily and a bandage.

It is not intended that all the above category of proceedings should be applied to every case. Good judgment must select what is suitable. When a prolapse of the iris becomes prominent paracentesis may be done. Pinto (*Ann. d'Oculist,* April, 1892, p. 246) makes the happy suggestion to treat the exposed boss of prolapsed iris by first loosening it from its attachment if needful, using a fine probe under the corneal edge, excising it, and then cover the wound with a little graft of the ocular conjunctiva. Bandage both eyes for three days. A firm white scar eventually ensues which excludes infection. He does this during the early period of prolapse and secures a more speedy healing than when the ulcer is left to itself.

The treatment of torpid and stationary ulcers is by stimulation. An old remedy is tr. opii diluted with water 1 to 5, but the yellow oxide of mercury in vaseline, gr. ij. or gr. x. ad ʒ i., well rubbed in once daily or every second day, is to be commended. Sometimes touching the congested palpebral conjunctiva with nitrate of silver solution, gr. v. ad ʒ i., or a solution of tannin in glycerin, gr. x. ad ʒ i., is to be preferred. For these cases when very chronic one may have to employ a variety of collyria, while the most important factor is time (*tinctura temporis!*).

Keratitis Postica.—Uveitis Anterior.

Inflammation of the deep layer of the cornea (sometimes called the uveal layer) is produced by inflammation of the choroid, ciliary body, and iris. Two forms may be referred to. One which is common exhibits numerous minute dots on the posterior surface and chiefly on the lower half of the cornea. These dots are in part precipitations from the aqueous and in part proliferations of the endothelium. The disease is primarily a serous iritis or cyclitis and was formerly called by the inelegant name of Descemitis.

Digitized by Illinois College of Optometry

There will be faint circum-corneal injection, discoloration of the iris, probably adhesions of the pupil and slight turbidity of the aqueous fluid (see Fig. 145).

Another lesion of the cornea appears during or after cyclitis as a brownish spot on its centre and in its substance, which under a low magnifying power is resolved into a cluster of molecules. It stays for some weeks or months and may not wholly disappear. The treatment will be included in that of the original disease, with the addition of hot fomentations. The conditions now alluded to will be again mentioned under the head of serous iritis. We have, in fact, a disease in which the corneal manifestation is subsidiary to a larger process. But of these post-corneal opacities, which have always excited much curiosity, we have late investigations by Fontan,

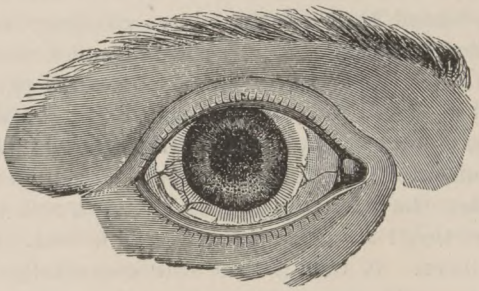

FIG. 145.

who examined two eyeballs thus affected. The more valuable case had traumatic irido-cyclitis. The membrane of Descemet was normal—its epithelium was not proliferated, but the new deposits were heaped upon them in little hillocks, and consisted of cells, some of which were young and active, others crenated and deformed. They were regarded as migrated and altered lymph corpuscles, and between them were granular particles supposed to be cement. Similar cells existed on the iris and on the anterior capsule, and in the anterior chamber was coagulated fibrin, which near the iris became fibrillated. In the iris and the canal of Petit[1] was fibrinous exudation, and the ciliary body was similarly infiltrated and was atrophic. The deep part of the choroid as well as the retina and optic nerve had suffered a degree of atrophy, and the arteria centralis was blocked by a clot. The corneal lesion evidently was only an outlying indication of a deeper lesion and not a disease *per se*. Whether all cases of keratitis punctata may be so regarded remains to be learned. Further discussion will be found in pp. 442, 466.

To the pathological conditions of the cornea already described various phases of disease might be added which are rare, or which

[1] Recueil d'Ophthalmol., Nov., 1888.

Digitized by Illinois College of Optometry

do not fit into ordinary classifications. In fact, the pathology of the cornea is a large field of study and is not compressible into any ordinary treatise. The following may be referred to:

A. A chronic hypertrophy of the epithelium at the limbus which in time encircles the entire cornea with a dense whitish band, which encroaches for a width of two to four millimetres upon the transparent structure. Its free border is a little elevated and abrupt. There is no ulceration and no vascularity. Sometimes attacks of more or less catarrhal conjunctivitis occur and are apt to last several weeks. During the spring they are said to be more frequent, and from this cause the disease has been styled vernal catarrh. It is described at length by Saemisch[1] under conjunctival affections, and is perhaps less frequent in this country than in Europe. I have seen it occasionally, and it has been previously mentioned (p. 362).

B. Keratitis dendritica exulcerans mycotica. By this title Emmert[2] describes cases which begin with a small superficial ulcer and extend in a dendritic or branching form close under the surface

FIG. 146.

making a figure resembling a twig of a tree. The lines are white, and the epithelium is soon shed, leaving open furrows. Subjective symptoms are severe and if the case when first seen is well advanced, it will be obstinate; recovery occupying six or more weeks. Investigation found bacilli in the infiltration.

The only successful treatment was washing the eye with corrosive sublimate, 1 to 1,000 (how often is not stated), and repeated use of eserine-vaseline ointment, 20%. There is no tendency to iritis. For months after recovery the white streaks could be discerned. Hansen-Grut[3] describes cases which in many respects are similar, but in which the subjective symptoms were not so severe and ulcer-

[1] Graefe and Saemisch, "Handbuch," Bd. iv., S. 25.
[2] Centralblatt f. Augenheil., Oct., 1885, S. 302.
[3] Congrès périodique internationale, Copenhagen, 1886, B. iii., p. 38.

Digitized by the Internet Archive of Optometry

ation did not take place over the lines of infiltration. He believed them to be mycotic, but was not able to prove it. See case quoted on page 358 (see Fig. 133).

C. In old cases of glaucoma and similar forms of degenerative disease of the globe, a chronic inflammation attacks the cornea along the line of the lid opening. Opacity begins at each side within a millimetre of the limbus, as minute specks which multiply and finally after long duration compose a band or zone across the structure from two to four millimetres wide. It sometimes happens that, besides minute yellow dots which are common, calcareous specks and scales appear within the stripe and may even compose a continuous film. Of this quality are certain cases described by Nettleship [1] in which the eye had not lost vision and for which iridectomy was available after removing the scales. Such stripes running horizontally across the cornea were described by Graefe as accompaniments of glaucoma and irido-choroiditis, but there are evidently varieties in their quality and relationships. I have seen this band well marked in an eye lost by sympathetic ophthalmia. I did iridectomy and the whole vitreous was found fluid and escaped. The cases rarely admit of benefit by any method.

D. Sclerosis of the cornea is a dense yellowish opacity of its substance which follows upon some chronic affections and looks like atheromatous patches of the arteries. It ensues on prolonged and profound disease of the inner structures and may involve its entirety. We also meet a gray opacity coming down from the limbus affecting both the epithelium and parenchyma, and showing a few vessels in its midst; unattended by injection of the ciliary vessels or photophobia or pain—very slowly progressive and rebellious to remedies. It behaves like a sclerosis, but doubtless is a kind of inflammation, in default of any accurate knowledge of its true nature.

E. Arcus senilis, or *gerontoxon,* appears as a grayish-white line at about one millimetre from the limbus; begins usually above; it may encircle the whole cornea; it occurs chiefly and frequently after middle life, but sometimes appears before this period. It consists of fatty degeneration of the cellules and fibrillæ, and has no special importance. Its presence does not contra-indicate operations.

In addition to the above-mentioned conditions reference may be made to p. 366, where several forms of herpetiform disease are alluded to, and besides these we have other lesions. One of them, called by Stellwag nummular keratitis, is referred to in *Centralblatt für Augenheilkunde,* Dec., 1890, p. 362. I have seen an instance of it, and it has affinities with the interstitial forms of keratitis.

[1] Archives of Ophthal. (Am. ed.), vol. viii., 3, 293.

Digitized by the Internet Archive

SEQUELÆ OF KERATITIS.

We shall consider *opacity, fistula,* and *staphyloma of the cornea.*

Opacity.

The attempt has been made to classify opacities according to their density, by the names nubecula, macula, leucoma, albugo, etc., but the terms have no exact value. It is of great importance to recognize how great is the disturbance of vision which almost invisible opacity will cause, if it overspread much of the pupil. This is often brought to view among patients with strabismus. To discover a very faint opacity one must use oblique illumination in a dark room or examine with the ophthalmoscope and feeble light. A plane mirror having behind it a convex glass of three inches focus will do the best service. One may also realize the injury to vision on attempting to see the fundus by the upright image through a small pupil. Distant vision is always more disturbed by faint opacities than near vision. An object will be held at short range and no complaint may be made, but no glass will greatly improve distant sight. Sometimes a cylinder may be helpful, because of astigmatism, and it frequently is of a mixed variety, but much improvement is not often obtained. The use of a stenopaic slit (Donders) is seldom accepted, because the field of vision is so greatly reduced. A well defined opacity partially covering the pupil is much less damaging to vision even if dense, than a faint haze with filmy edges.

The cure of opacities depends on their density and their extent. The more recent, the more likely are they to improve. So long as blood-vessels remain in their vicinity the improvement will continue. The restorative action will go on for months, and naturally with more energy in young than in old subjects. Treatment consists in stimulating applications, or, in popular speech, in using "something to cut the film." The most serviceable are, very finely powdered calomel dusted daily into the eye and which is especially suited to children. Ointment of the yellow oxide of mercury, gr. ij. vel x. ad ℥ i., to be used every night, or once in two or three nights, according to susceptibility; astringent drops in various strengths, viz., sulphate of zinc, alum, sulphate of cadmium (not nitrate of silver because prolonged use stains the conjunctiva); tannin in glycerin, ℥ ss. ad ℥ i.; tr. opii. diluted, 1 to 10; sol. iodide potass., 1 to 3 or 1 to 2; common salt, 1 to 5 or 20; hot fomentations; powdered sugar, molasses, etc. None have any specific value, and one may choose and vary according to the susceptibility of the case. There

will be extreme variety in this regard. The object is to irritate and cause hyperæmia, not to last longer than a patient can tolerate. It may be assumed that opacity will grow fainter for at least a year and sometimes longer. In some extreme cases of pannus with very torpid cornea the crystal of sulphate of copper may be applied to its surface.

When no further absorption is possible and a dense opacity exists, two proceedings remain, and they are often combined, viz., iridectomy and tattooing. An artificial pupil should, as a rule, never be made during the recent stage of an opacity unless very dense and extensive. Its effect is to promote transparency of the cornea, and the vision is damaged by the enlargement of the pupil. When, however, the pupil is covered or the iris is prolapsed and a marginal part of the cornea is more or less clear, an iridectomy will be in place. Sometimes a large piece of iris should be excised, as when considerable cloudiness covers the part of the cornea where the opening in the iris must be made; at other times a small pupil must be made in case the cornea at the site to be chosen is relatively or really clear. It is often difficult to do the operation when there is anterior synechia or partial staphyloma. With a shallow anterior chamber a narrow Graefe's knife should be chosen and cut at a tangent to the edge of the cornea. A narrow iris knife will serve the purpose in most cases. In some instances of central opacity with free pupil, incision of the sphincter iridis by Wecker's scissors (pince ciseaux), or by a fine scissors invented by Mr. Carter, may be possible and sufficient. To make a small pupil the corneal wound must be small, it must not be very oblique, else the internal wound will not lie at the desired point, and a Tyrrell's blunt hook is better suited to the removal of a small piece of iris than forceps. The shank of the hook must be soft to permit bending at any angle. Good judgment and considerable technical skill are often required in dealing with the cases we are now considering. The spot at which a pupil is to be placed is frequently not a matter of discretion, because there may be only one clear region If, however, a choice is possible, the lower segment of the cornea is to be preferred to the upper; downward and inward, or downward and outward are the best localities. If there be only one available eye and the upper part of the cornea must be chosen for the pupil, a free division of the superior rectus muscle will both turn the globe some degrees down and help the lifting of the upper lid by co-ordinate action so as to bring the pupil to bear for vision. This must not of course be done, if the other eye have good vision or if there be any attempt at binocular vision.

The degree of sight gained by an artificial pupil is rarely good. The curve of the corneal margin is always irregular, it is usually

Digitized by Illinois College of Optometry

made more so by the attending inflammation—we often must deal with a hazy structure, and it happens sometimes that the lens is partially or perhaps wholly opaque. It is not often that a patient is enabled to read except at a very short distance. But the ability to go about alone, to see large objects, and emancipation from absolute blindness or helplessness is a great boon. The enlargement of the field on the side which otherwise would be blind is ample justification of the operation. It may be remarked that because in one eye the pupil is central and in the other it may be at the margin of the cornea, this condition does not involve diplopia. Patients will seldom use two such eyes in combination, because they differ greatly in acuity, but if diplopia occur it is due to want of proper direction of the eyes, not to the optical disagreement.

Very dense opacities which are a blemish both to sight and to personal appearance may be tattooed with India ink, as was suggested by Wecker. Some improvement of vision is gained by doing it where an artificial pupil has been made, because the quantity of diffused light entering the eyes is reduced. The most favorable conditions are when the cornea is normally or abnormally thick.

FIG. 147.

The ink will not lodge in a thin and staphylomatous cornea, and in such cases the operation sometimes sets up disagreeable reaction. Recent cases must, of course, be avoided. Sometimes the pigment is introduced into the transparent cornea to diminish the injurious influence of a large iridectomy upon vision; it acts as a kind of diaphragm.

The fine (and expensive) quality of ink is to be used. The end of the stick should be soaked for an hour in water to make it pasty, and a bit of the paste equal to the size of the spot to be colored placed upon the cocainized cornea. Perfect anæsthesia can be procured by using a 4% solution of muriate of cocaine, two or three times. Fixation of the globe by forceps which have no teeth, or whose tips are made of tortoise shell, avoids wounding the conjunctiva (although not the possibility of tearing it), and the consequent chance of staining it by overflow of the pigment. Numerous and rather forcible pricks with a bundle of needles driven obliquely in various directions will force the ink under the epithelium, and if it be thick enough one sitting may suffice (see Fig. 147). If needful the proceeding may be repeated. In some cases, especially if the cornea is thin and vascular, the pigment is absorbed and disappears in a year or a few months. It has been found in remote parts of the cornea, whither it had been carried by the wandering cells. On the other hand, I have recently seen a patient in whose eye the blackened spot remains eight years since I made it. These

deposits have not been known to cause any irritation, although, as stated, the operation sometimes causes reaction. A series of needles arranged side by side is preferable to a single grooved needle. It occurs to me that a case of sympathetic ophthalmia after tattooing has been reported.

A *calcareous deposit* sometimes forms upon the exposed part of the cornea in eyes degenerated after irido-choroiditis, after injuries, as well as upon staphylomatous corneæ; the tissue may otherwise be clear. The deposit occurs beneath the epithelium in irregular specks and lines and slowly increases during years. It causes no irritation until it attains considerable size and causes erosion of the epithelium; then it acts as a foreign body and should be scraped away under the influence of cocaine.

Fistula of the Cornea.

If perforation take place so that the pupillary edge of the iris is caught in the hole, it sometimes happens that occlusion does not occur, but the canal becomes lined by epithelium and remains permanent. A leakage of aqueous goes on, the eyeball becomes soft and irritable. Usually this happens after severe and extensive ulcerations. The point of perforation is denoted by a black spot, at which a little of the iris may be seen and the cornea will be very thin. The accompanying conditions may be various; I have known an instance in which a fistula remained for seven and a half years and resisted all treatment. The whole cornea was opaque and iridectomy was impossible. Several attacks of inflammation occurred and I performed enucleation.

Treatment.—The attempt should be made in recent cases, to cause adhesive inflammation by touching the fistula with the actual cautery, using a fine point, or with a sharp point of nitrate of silver. The latter will cause more reaction than the former. If, after fair trial this method fail, an iridectomy will generally succeed. Besides the surgical measures, rigorous occlusion by a bandage should be enforced and sometimes this alone will suffice. Pinto, *Ann. d'Oculist.*, April, 1892, p. 249, suggests transplantation of a conjunctival graft after loosening the iris from the cornea (see p. 407). In very few instances will removal of the eye be demanded. It should not be practised if any useful sight can be secured.

Staphyloma Corneæ.

This deformity is a usual outcome of extensive ulceration, and is explained by the pressure of the intraocular contents upon the fresh reparative material before it has gained strength for proper resistance. For a period lasting sometimes for weeks, while the neoplastic structures are young, they have a certain translucency

Digitized by Illinois College of Optometry

which deludes the patient into supposing that useful sight will remain, and the inexperienced physician may share the same belief; but gradually, as the tissues gain thickness, discernment of objects becomes more vague, and finally nothing but quantitative perception remains. The new membrane, which takes the place of the destroyed cornea, as it bulges forward acquires more resisting power, and finally an irregular conical or rounded prominence of more or less opaque hue remains, which constitutes a corneal staphyloma. In some cases, where the whole cornea melts away, the transparent lens with undamaged capsule presents itself, and persuades the patient that the sad prognosis which had been given cannot be true; but a veil of opaque tissue slowly forms which shuts off sight.

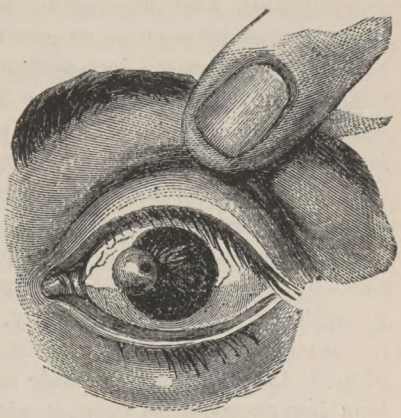

FIG. 148.

The term staphyloma simply signifies a bulging, and we may have a great variety of forms. The shape may be conical with its apex central or lateral; it may be globular, it may have a lobulated surface (likened to a bunch of grapes); it may be limited to the cornea or involve the ciliary region, or be accompanied by distention of the whole globe (see Figs. 148, 149). It may be densely white or bluish, and traversed by large vessels: it may be thin and dark colored. The iris is commonly adherent to and incorporated

FIG. 149.

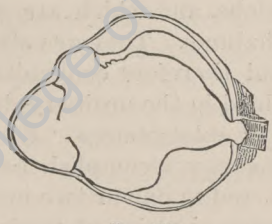

FIG. 150.

with the cicatrix. The lens is generally opaque or may have escaped, or have been wholly or partially absorbed. The deeper structures may have undergone morbid changes; but often perception of light remains.

The tension is usually in excess, but the yielding of the tissues commonly averts serious glaucomatous symptoms. But in Fig. 150 the optic nerve is deeply cupped and the retina detached.

Digitized by Illinois College of Optometry

Complications, however, arise, in case, as is not infrequent, acute inflammation occurs. Then there will be intense injection and extreme pain, and serous effusion in the lids and other tissues. Suppuration and ulceration may attack a corneal staphyloma. The outgrowth may be so great as to push the lids far forward, and it may become impossible to close them during sleep. It is noteworthy how the upper lid adapts itself to an advancing staphyloma and succeeds in protecting it. On the summit of a staphyloma calcareous deposits sometimes form and cause extreme irritation. We meet the deformity oftenest as the result of ophthalmia neonatorum, or small-pox or gonorrhœal conjunctivitis.

Treatment.—With a large perforation, if staphyloma threatens and considerable clear cornea remains, we may retard or reduce its growth by a broad iridectomy. This will be feasible when there is no considerable conjunctival secretion. If during the acute stage of an inflammation the whole cornea has been swept away and the lens lies exposed to view, it will be well to open the capsule and permit its escape, thereby promoting a tendency to collapse of the eye, rather than to the formation of staphyloma.

During the formative stage of a staphyloma repeated puncture, especially while the cicatrix is thin, will check or prevent its growth.

When a staphyloma has been fully established, it is often needless to do anything with it, especially if the subject be very young and if it be practically stationary in size, and not large. When because of its size or for any reason improvement is desired, we may in some cases perform iridectomy provided the cornea is alone involved and is in part transparent (see Fig. 148). Care must be taken not to confound with these cases those in which the projection may be semi-transparent and large, including the whole anterior part of the globe, and which are sometimes called by the name of megalophthalmus. They are often instances of intra-uterine irido-cyclitis and therefore congenital. The same pathological process may be added in the ordinary development of staphyloma and issue in a similar enlargement. For such conditions a succession of iridectomies may accomplish reduction. Sclerotomy is sometimes practised, and in one or two instances I have effected the desired result by entire avulsion of the iris. Reference will be made to this matter in the chapter on iritis.

When complete and obtrusive, the purpose of treatment is to reduce its size, and make possible the wearing an artificial eye. In some instances, where no visual improvement is expected, it is better to attempt iridectomy rather than to remove any portion of the cicatrix. There may be only a bluish semi-transparent corneal margin, through which the atrophied iris is visible. A narrow Graefe's knife, supplemented by sharp-pointed scissors curved on

the flat, will make an adequate marginal wound and shreds of iris may be torn out. There is danger of loss of vitreous, but by great care a result may be obtained which will avoid the risks of an excision operation. The proceeding amounts simply to sclerotomy, and the abatement in size is gained by the procurement of a thin filtration cicatrix. Such a proceeding admits of repetition.

For many cases we are obliged to choose between excision of the staphyloma and removal of the globe. In favor of the former is the much better stump on which to rest a glass eye; and a careful regard to personal appearance is extremely important. It often has great influence in the procurement of employment, especially among clerks, seamstresses, etc. In children enucleation must, if possible, be avoided, because the soft tissues of the orbit may not keep up a proper development during the child's growth. When all proper allowance is made for these considerations, in a certain number of cases enucleation will be practised. This will be done when there is a tendency to attacks of inflammation, when there may be irritation of the other eye more or less sympathetic in character, and this may be superficial, *i.e.*, conjunctival, or more deeply seated. I have known myopic persons for whom enucleation of a staphylomatous globe was the only suitable proceeding, because no risks could be taken of the integrity of the remaining eye. This principle applies of course to all persons, and if there be reason to apprehend sympathetic trouble of a good eye, the diseased eye must be removed *in toto*. It also happens that patients cannot afford the longer time and greater attention required for the healing process after partial removal. To them a better appearance may be less important than quick recovery and absolute immunity from future risk or annoyance.

Partial removal is done in various ways according to the shape and size of the staphyloma. If very thick and conical the apex may be sliced off, the lens evacuated, the parts thoroughly cleansed with sol. corrosive sublimate, 1 to 5,000, and the eye closed with a bandage and absorbent cotton. Keep the latter moist with sol. corrosive sublimate, 1 to 3,000. The wound will slowly cicatrize and there may be no unpleasant reaction.

If the mass is more globular a sector may be excised like a quarter of an orange, by transfixing with a Graefe's knife and completing the removal with scissors; then draw the edges together with from one to three fine black-silk stitches. When the incisions and punctures do not go beyond the limbus this proceeding is entirely safe. For greater security the base of the staphyloma may be transfixed by one or two common discission needles which serve to prevent loss of vitreous and to handle the globe. The incisions in the cornea may be vertical (see Fig. 151).

Digitized by the Internet Archive of Ophthalmology

When we have a larger distention to deal with, including the ciliary region, a more serious method has to be used. A large wound opening the eyeball is liable to be followed by intraocular hemorrhage, because all the tissues have degenerated and grave inflammation may follow; free loss of vitreous is inevitable. To prevent it Mr. Critchett proposed to pass three needles vertically across the globe behind the point where abscision is to be practised, and then remove the staphyloma. The threads of the needles should then be drawn through, and the eye may be shut without loss of its contents or much risk of bleeding. The sutures pass through the ciliary region, which is objectionable both on account of liability to immediate inflammation and also to possible sympathetic trouble in the future. To avoid this risk Dr. Knapp dissects the conjunctiva away from the base of the staphyloma, passes through it the threads, abscises the cornea and draws the conjunctiva over the opening. In either case one may remove the lens if it be present. I have seen serious reaction follow both the above methods of operating, and seen it extend to severe orbital cellulitis. This experience took place when antiseptic methods were not in use, and I can well believe that at the present time very different results may be the rule. I should rigidly keep the eye occluded from contamination with germs, by irrigation with sol. corrosive sublimate both during the operation and for all the period of healing, which would be ten to fifteen days.

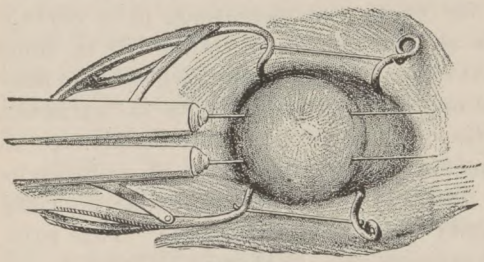

FIG. 151.

Retention of the vitreous is aimed at in the above operations, as a means of avoiding intra-ocular hemorrhage. But the walls of the globe may be so thin in cases of very great enlargement that one may better excise the anterior half of the globe, wipe out its contents, and waiting until all bleeding ceases, may put in stitches to draw together the edges of the selera; then apply cotton and bandage and soak continuously with sol. corrosive sublimate. In all the above operations, if the eye is extensively opened it will be prudent to use ether or chloroform rather than cocaine to insure quietness of the patient.

Mr. Mules proposes to put a hollow glass sphere, which he calls an artificial vitreous, inside the sclera after all its contents are removed, and let this remain. He claims advantages for wearing a glass eye. The healing requires some weeks and the method will be described in greater detail hereafter (see p. 774).

Digitized by Google

Cornea Conica, Staphyloma Pellucidum.

The cornea sometimes changes its curve to such a degree as to become visibly deformed yet transparent. This process is not inflammatory, but seems to depend upon atrophy of the substance. Because the conspicuously conical condition was the first to be noticed the disease is known by this name. The shape may be more or less globular or of some irregular type, and if conical the apex may be central or is more usually below the centre of the cornea because influenced by the pressure of the border of the upper lid. The disease belongs chiefly to the juvenile period of life, *i.e.*, between ten and twenty-five, although it may be set up much later. It progresses slowly during several years, seldom rapidly; it ordinarily comes to a stand, yet progressive cases are seen in which an extreme elongation takes place. Such are figured by Von Ammon and Dalrymple and others. Rupture has been reported, but this is excessively rare. At its beginning and during its progress there will be pain and marked symptoms of asthenopia. Distant vision will grow bad, objects will have to be brought close to the eye, and if the attempt is made to correct the near-sightedness by ordinary glasses there will be little or no success. All such glasses cause pain, and if they improve sight do not bring it up to standard.

Diagnosis.—For pronounced cases recognition is easy because there is a peculiar brilliancy in the reflex from the cornea and the form may be conspicuous whether viewed in face or in profile. Seen from the side the top of the cone looks dark because of total reflection of light. As a fact if very thin, the summit of the cone is sometimes a little opaque. During the incipient stage we make the diagnosis by the mirror of the ophthalmoscope, by Placido's disc, and by the ophthalmometer of Javal and Schiotz. Illuminated by a feeble light and viewed with the ophthalmoscope from twelve or sixteen inches, as the light is made to play from side to side over the cornea a shadow appears at the summit of the curve which comes and goes, and may assume a vortex-like shape as it varies in extent; if the vessels are seen they will be broken and twisted and not of the same size as viewed through different localities. Inspection of the fundus by the inverted image displays irregularity in the refraction which becomes very noticeable if the objective lens be moved from side to side. Inspection by the upright image is unsatisfactory, because it is impossible to see a continuous field with one correction and often no glass will afford a proper view. The vessels appear distorted and broken, and one calls to mind the effect caused by looking through bad window glass. The optic nerve is irregularly elongated and its image shifts with the point of view. If a patient faces the gas light and this is condensed by a

Digitized by Illinois College of Optometry

two-inch lens upon the axis of vision, an observer looking at the eye from the side, *i.e.*, at right angles to the line of illumination, will in marked cases see a red reflection of light from the concave surface of the apex of the cone. It will glitter as does the pupil under the ordinary mode of illuminating the eye. This observation I have made for the first time within two years. It had not been previously noted.

Placido's disc, referred to on page 126, gives a simple and striking exhibition of the deformity.

If the cornea be examined by the ophthalmometer, the images of the test objects will undergo various distortions, the sides becoming curved, and it will be impossible to give any accuracy to the measurements. There will be the most irregular forms of astigmatism, and it will attain very large degrees, often ten or more dioptries. An interesting fact revealed in this examination is that I have seen the images pulsate synchronously with the pulse, which is evidence of great thinness of the cornea. It is also noticed that the curve of the cornea constantly changes under the pressure of the lids, especially of the upper.

In using trial glasses, while astigmatism may be readily made out the symptoms are variable, the lines in Green's card seem to be curved and the patient makes contradictory answers and cannot be made to accept any combination which fully corrects the error.

Treatment.—During the early period we must find the glass which shall be the best approximate correction. The stenopaic slit placed in the meridians of greatest and least curvature does good service. With it we use only spherical glasses. Better than this is Dr. Thompson's way of employing Scheiner's experiment (see p. 82). For this a large pupil is required and one may have to use atropia. The patient looks through two minute holes in a black metal disc which are either three or four millimetres apart, at a small gaslight, not more than one-half inch high, at twenty feet in a darkened room. Over one of the holes a red glass is placed. By such an arrangement a patient sees two lights when the holes stand in a meridian of the eye whose refraction is ametropic. If the meridian be myopic the red light will be seen on the side which agrees to the position of the hole covered by the red glass. If the meridian be hyperopic, the red light will be found upon the side opposite to the position of the hole covered by the red glass. The holes are to be placed in meridians which cause the widest and least separations respectively of the images. The disc is inserted in the trial frame, and by noting the behavior of the images as it is turned, and the place occupied by the red light, one may with spherical glasses bring the images together, in each principal meridian. One will often find myopia in one meridian and hyper-

Digitized by the Internet Archive Open Library

opia in another. The principal meridians are not always exactly at right angles to each other. The difference in optical value of the meridians gives the proper cylinder, and vision may then be tried by the test letters.

It is by no means rare that simple convex cylindrics are to be preferred without spherical correction. In some cases concave cylindrics placed at right angles to convex cylindrics give a flatter field and better vision than spherico-cylindrics. In all cases the extent of field is quite limited. The curve of the cornea is inconstant and a slight turn of the eye alters the refraction. We must not finally depend on the result as found with atropine, but correct it by future trials and let the experience of the patient control the ultimate choice. One may test the patient as he faces the light to get the result with a small pupil. Eserine and pilocarpine may be tried with or without glasses, because with a small pupil the optical error is less hurtful; the myotic may be used continuously if helpful. The glass which serves for distance will not always suffice for near work. Much latitude must be allowed for personal peculiarities and only persistent and intelligent trial can decide what will serve best.

Raehlmann[1] proposes hyperboloid lenses for correcting the error. He makes two systems called respectively A and B. In system A the axis of the hyperbola is one-third of a millimetre. In system B the axis is two millimetres. In each system are eleven numbers. Each glass is thirty millimetres in diameter. It has not been my fortune to meet a case to which these glasses have been peculiarly adapted, but Dr. Hay, of Boston, has found them. In theory such glasses ought to be a complete correction for some cases, but there is clinically no regularity in the type which they assume, hence, no regular curve is applicable to all. The choice of the best hyperboloid glass must be made experimentally, and its position must be shifted until the most useful spot is discovered. When successful a larger and flatter field as well as better vision are gained.

When a case has gone too far for correction by glasses, surgical measures may be employed. Paracentesis, unless repeated a great number of times, has no value. Iridectomy has been employed with a view to diminish the deformity, but in this respect it has little value; by displacing the pupil and supplementing it by tattooing the apex of the cornea, it is said that useful results have been secured, aided by suitable glasses. But the cornea is too thin to admit of being colored and without doing it the artificial pupil confers very moderate benefit, or it may prove detrimental to sight. The

[1] Klin. Monatsblätter, July, 1881, p. 303; Berliner Klin. Wochenschrift, 1880, No. 34.

Digitized by the Internet Archive

operation of iridesis (Critchett), by which the pupil is drawn to one side of the cornea and made to adhere by tying a fine thread around the little prolapse, has in some cases provoked cyclitis and sympathetic trouble of the other eye. Its optical effect is good, but its risks have caused it to be laid aside. Mr. Critchett insisted that if the wound were placed not in the limbus but at an appreciable distance inside the margin of the cornea the injurious after-effects would not occur. But other methods are available to which such objections do not apply: they consist in removing portions of the cornea either mechanically or by setting up ulceration. Excision of the apex by a Graefe's knife and scissors and drawing the wound together by fine sutures has been practised. It is a very delicate proceeding, but entirely feasible, as my experience testifies. The stitches must be of the finest filaments obtained by unravelling twisted silk, and the curved needles both very small and sharp, made expressly for the purpose. The whole corneal tissue is included and the stitches must come out in two days. There need be no prolapse of iris and the scar may be very small.

Mr. Bowman removed a disc from the summit of the cornea by a trephine or sharp punch which cut its way through by rotation, and the opening was left to close by granulation. Prolapse of the iris ensued and generally iridectomy became necessary.

Graefe caused ulceration by shaving off the surface of the apex and touching the spot with solid nitrate of silver for successive days until an ulcer was caused with suppuration. This was treated in the usual way, and after it had healed the cornea would be flatter. Several months later iridectomy, tattooing, and glasses completed the treatment. This method, it is evident, is attended with some risk and requires considerable time for its accomplishment.

A method less dangerous and more prompt (Hirschberg) is to touch the apex with the actual cautery over a small surface which can be easily defined and the burning may be repeated until a suitable effect is gained. Perforation of the cornea must occur and prolapse of iris. When the cicatrization is complete, iridectomy, tattooing, and glasses will be in order.

It has been proved that the effects of prolapse of the pupillary portion of the iris are far less important than of its peripheral parts. Moreover, as the prolapse takes place near the centre of the cornea the drag on the iris is a minimum. Care must, however, be taken to render the prolapse as small as possible, because it large it may cause mischief. My own preference is for excision of a small piece and uniting with sutures.

Transplantation of the cornea has been tried in cases of total opacity, but not with any satisfactory results. Von Hippel has

Digitized by the Internet Archive of Canada

devised a spring trephine for its accomplishment and reported enough success to stimulate further trials. See also Strawbridge. The insertion of a bit of glass shaped like a shirt-stud has also been employed, but with little encouragement.

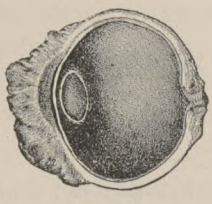

FIG. 152.

The cornea is the seat of *morbid growths.* We have congenital *fibroma* (Graefe), also *sarcoma,* both white and pigmented, and the tumor may be highly vascular. Fig. 152 shows a specimen of *epithelioma* from the museum of the N. Y. Eye and Ear Infirmary.

Papilloma is reported by Dr. Ayers. *Tubercular disease* and *cancerous ulceration* may attack it.

Digitized by Illinois College of Optometry

CHAPTER VI.

THE SCLERA.

Anatomy.—The sclerotica (sclera), which constitutes the greater part of the outer tunic of the globe, is characterized by toughness, resistance, and a little elasticity. Its structure is very like that of the cornea, except that it possesses blood-vessels, while its fibrillæ are coarser and less regularly arranged. They are gathered into bundles, and cross each other in various ways, and are united by a homogeneous cement. There are lymph channels and fixed corpuscles, and also wandering cells, and a little pigment which in the African race becomes considerable. Its greatest thickness is behind, viz., 1 mm., while at the equator it is re-enforced by the tendons of the muscles, and just behind their insertions we find its thinnest portion, viz., 0.4 mm. In front it is covered by the conjunctiva, and beneath this, is a loose episcleral connective tissue. Behind, fifteen degrees to the inner side of the macula lutea, and a little (three degrees) above the horizon, it is perforated by the bundles of fibres of the optic nerve. The place of entrance constitutes a sieve-like perforation called the lamina cribrosa. The sheath of the optic nerve joins the sclera. The inner surface of the sclera is lined by endothelium, which has an imperfect layer of large polygonal cells and pigment. On its outer surface the layer of connective tissue constitutes part of the capsule of Tenon (oculo-orbital fascia). The posterior part of the sclera, for a space about ten to twelve millimetres in diameter, of which the optic nerve is nearly at the centre, is pierced by blood-vessels and nerves known as the posterior or short ciliary. Immediately around the entrance of the optic nerve a few vessels anastomose, and compose a circle which forms the only medium of connection between the blood-supply of the retina and that of the choroid. Exceptionally vessels known as optico-ciliary are found. The ciliary vessels go to the choroid, ciliary body, and iris (uvea). At the front the sclera is penetrated by the terminals of the muscular twigs known as the anterior ciliary vessels. The nerves penetrate the sclera behind, in the same region with the vessels. They are twigs from the ciliary ganglion, whose roots of origin are the oculo-motor (3d), the ophthalmic (5th),

Digitized by Illinois College of Optometry

and the sympathetic; it lies nearly at the orbital end of the optic nerve to its outer side. Besides the short ciliary nerves we have the long ciliary nerves, two or three in number, given off from the nasal branch of the ophthalmic, which mingle with the short ciliary nerves and are distributed to the ciliary muscle and iris. The junction of the sclera with the cornea is by continuity of fibres, which have no distinct line of demarcation.

Episcleritis, Scleritis.

Inflammation of the sclera is not frequent, is more apt to be chronic than acute, is seldom extensive, but occurs in patches; these have a long duration and are likely to come on in successive spots, giving rise to the epithet *migrans.* They may be confined to the sclera or be complicated by attacking the cornea or the ciliary body and iris and deep structures of the eye. We have *episcleritis,* and *scleritis.* The latter may be general, *s. diffusa,* or it may be in spots, *s. circumscripta.*

Episcleritis

Is an inflammation of the subconjunctival connective tissue, which occurs in patches, most generally at the region of the inner and outer angles, and may be either acute or chronic.

Usually it presents an area of pink made up mostly of fine vessels on some spot between the insertion of the recti and the margin of the cornea; it is broadly elevated and may or may not be painful on pressure.

In the beginning, the conjunctiva may be a little œdematous, but there is no eruption upon it and no sticky secretion. The red spot persists with varying degrees of discomfort for weeks, and on disappearance often leaves a gray or leaden colored surface. It may have no successors, but unfortunately this is not the rule. Other patches, either in the vicinity, or on other parts of the sclera, present themselves, and go through a similar evolution. There may be intervals of weeks or months or perhaps years. A persistent spot of chronic episcleritis, at the outer and inner portions of the palpebral opening, is common among those who are greatly exposed to wind and weather, like seamen and laborers, and especially in later life. There will be decided thickening both of the conjunctiva and sub-conjunctival tissue. The above conditions are comparatively harmless although annoying.

Treatment of episcleritis varies according to the conditions presented. There are mild cases of a fugacious character in which almost no subjective symptoms exist, and the person is aware of his disease only by seeing a bright pink area of redness over the

insertion of one of the recti. This passes off in a day or so without treatment. In the pertinacious varieties there may be in the beginning some pain and heat, when cold applications will be chosen; we generally are called on to prescribe after this stage has passed. If the sclera alone is involved we may use atropia to allay uneasiness and be certain that the iris escapes, and warm applications will be grateful. If there be pain not thus controlled, a compressive bandage may give relief, and scarifications have been practised, in case there is local œdema and sensitiveness on pressure. In the torpid state mild stimulation is applicable, by dusting calomel on the spot, by friction with ointment of the yellow oxide of mercury, gr. ij. ad ʒ i., and by simple massage.

Sometimes iodide of potassium is appropriate, and other general remedies to be spoken of presently, because this condition shades into scleritis circumscripta, which is liable to be a diathetic disease. Pterygium is frequently developed upon episcleritis.

Scleritis Diffusa Acuta.—In its acute form, including all the anterior portion of the globe, this is a rare disease, and must not be confounded with conjunctivitis or iritis. So rare is it that extreme care must be taken to exclude both the above maladies, viz., conjunctivitis by the absence of secretion, iritis by the clearness of the aqueous humor and want of pupillary adhesions. It is eminently of rheumatic or gouty origin; it is extremely painful. There will be diffused bright pink injection, with only watery secretion, and intolerance of light and little reduction of sight. It may be less severe in attack and pursue a mild course during several weeks. On the other hand, I have seen a case which seemed to originate in scleritis and which developed acute inflammatory glaucoma. The patient had gouty kidney as subsequently shown by autopsy.

Treatment will consist in using atropia as an anodyne several times daily, cold water if agreeable, more often dry warmth is preferred, or hot fomentations. To this add proper constitutional treatment according to the diathesis. It is always needful to examine the urine for indications. For the rheumatic cases, Rochelle salts or salicylate of sodium will be chosen; for gouty cases iodide of potassium, or colchicum, or both combined. The general habit of the patient, whether plethoric or anæmic, must always be taken into account. A combination of conjunctivitis and scleritis, catarrho-rheumatic ophthalmia (see pp. 292–296) sometimes arises in which pain is a conspicuous feature. Antifebrin, gr. v. every four hours, or phenacetine, gr. v.–x. every four hours, or antipyrin, gr. x. *pro re nata,* are welcome substitutes for ordinary anodynes.

Scleritis circumscripta resembles in some degree episcleritis and may result from it, yet a correct appreciation of its occasional results and complications makes its separate description appropriate.

Digitized by the College of Optometry

It is usually a chronic affection, and if while confined to the sclera it is unpleasant and obstinate, nothing need be added to what has been said above to afford a suitable idea of the measures proper to its management.

Where, however, it is not limited exclusively to the sclera, a more serious situation arises. It may extend to the cornea or to the subjacent structures, viz., the ciliary body and iris, and either without or with implication of them, it may bring about staphylomata; in some instances after a protracted course in which the sclera has become thin and bluish, the anterior part of the globe becomes elongated to a pear shape, while the margin of the cornea, from its haziness, can hardly be defined from the sclera, and perhaps the whole of it has been rendered cloudy. One or more staphylomata may arise in the ciliary region.

Sclero-keratitis denotes the invasion of the limbus or of the sclera very near to it. A dense opacity creeps into the cornea accompanied by vascular injection of the sclera and sometimes too of the corneal substance. There may or may not be thickening of the sclera; the disease may remain on one spot or spread around the limbus. The corneal opacity may be thick and yellowish and indelible (sclerosis) or it may be of the usual type and become fainter or disappear. Iritis or cyclitis may or may not co-exist.

The process is apt to engage the iris, because of the high vascularity of this region and the vicinity of the canal of Schlemm, and so it readily reaches the ciliary body. If this occur, the globe begins to lose tension, pupillary adhesions appear, the vitreous begins to be hazy. With advancing progress the phenomena of iridocyclitis become pronounced, there may be intra-ocular hemorrhages and marked reduction of the globe and of sight, or with occlusion of the pupil the opposite conditions of secondary glaucoma and increased tension may develop.

Staphyloma of the sclera sometimes occurs as has been remarked, and it is difficult in old cases to decide whether the morbid process has begun from without or from within. It may begin from the sclera, but more frequently it begins from the ciliary body and iris. By either method the shape of the eyeball may be badly distorted. When the lesion concerns the region of the limbus chiefly, the pear-shaped elongation occurs; when it attacks the ciliary region there may be one or more decided bulgings of dark blue color with a few large vessels running to them and their walls are extremely thin. In some instances a row of them encircles the globe in front of the tendons of the recti (intercalary staphylomata) and the form reminds one of the seed capsule of the poppy. When a single protuberance occurs, there may be considerable sight or none at all. When there are many, there will be occluded pupil,

Digitized by Illinois College of Optometry

the lens may be opaque or shrivelled, the iris bulged forward to the cornea, or the anterior chamber may be very deep and the cornea thin and distended, and no vision.

The morbid conditions above alluded to occupy years in their progress and are associated with some faults of nutrition, which it is not always easy to appreciate. The anæmic, the gouty and rheumatic, the chlorotic and scrofulous are the chief victims. Both children and adults may be affected. One severe acute case required large doses of quinine to control profound malarial infection, and to this was added salycilate of sodium. Obstinacy and long duration are signal features.

Treatment will be both local and constitutional.

If the case be complicated with deeper troubles, as acute keratitis, and do not yield to atropine and hot fomentations and suitable constitutional means, I have in a few instances practised iridectomy with benefit. The case must, however, be urgent to warrant it.

When iritis appears, we employ atropine to secure mydriasis. If any tendency to staphyloma occur, a pressure bandage may be of some avail. Its development is due more to local weakness of structure than to increase of intraocular tension, hence, iridectomy is not indicated. For a quiescent and fully formed staphyloma its excision may be practised instead of enucleation, and the edges of the wound united by fine sutures. When there are many staphylomata and the deformity is conspicuous, enucleation may be the only resource. If, however, the distention affects the ciliary region uniformly without exhibiting particular prominences, sclerotomy may be tried and repeated. The cases referred to merge into those known as hydrophthalmus, whose beginning is by internal inflammation of the eye, and for which a large iridectomy is sometimes useful. I have also brought about the diminution of the eye by total avulsion of the iris. To do this a wound about six millimetres long is made at the edge of the anterior chamber, a slender pair of straight forceps with blades of unusual length is passed to the opposite side of the chamber and seizes the iris at its periphery. Dragging gently and with a to-and-fro motion, it may yield without laceration and gradually it tears away from its insertion and is drawn out of the eye. Only a small number of cases will lend themselves to this proceeding.

The use of a seton to induce suppuration of the globe is not to be advised. Preferable to this is evisceration of the eye after removing the cornea, or so much of the anterior part as may be needful. Strict antiseptic treatment may prevent suppuration. The contents of the sclera may be wiped out with a sponge. Reaction will be greater after this proceeding than after enucleation, because there is always some orbital cellulitis, as I have had occasion to

notice. It is, however, most desirable to avoid enucleation if possible, because the tissues of the orbit have been reduced by pressure of the enlarged globe and a yawning chasm is left which an artificial eye cannot suitably fill. For young persons and females this consideration is most urgent.

Constitutional treatment in cases with active symptoms is of value. Recognizing the uncertainties of the choice of a proper remedy, inquiry must be made into the diathesis and regard paid to the general condition. With feeble subjects, tonics and quinine and arsenic do good service. I have often relied on the last, and find that Horner speaks well of it as having been advised by Critchett. In scrofulous persons, cod-liver oil and iron will be given. To the gouty a careful regulation of diet and habits, the use of baths, of mineral waters, especially of the lithia waters, and best, taking them, if the season suit, at the springs where they flow; the careful trial of iodide of potassium in small doses, the cautious use of colchicum, are serviceable suggestions. Salicylate of sodium, and alkalies like Rochelle salts or citrate of potassa may be given to the rheumatic. I have known a gouty subject of delicate health much benefited in the later stages of a protracted and distressing attack by hypodermic injections of muriate of pilocarpine about one-eighth of a grain. In all cases great care must be taken to protect the eye from irritation by light and wind and dust and over-work. The general hygiene must be cared for intelligently and in detail. Change of climate and trial of various resorts will often have to be summoned to our assistance.

Digitized by Illinois College of Optometry

CHAPTER VII.

THE IRIS.

THE structure which we meet next in order is the iris. We have to take up its consideration separately, but this does violence to its anatomical and pathological relationships. It is continuous with the ciliary body and choroid, which unite with it to form the vascular tissue, called as a whole the *uvea*. Together they are supplied by the same nerves, and morbid action often, if not generally, affects the whole to a greater or less degree, beginning at one part and going from behind forward or beginning at another and going from before backward. Among children, especially, does this involvement of the whole uveal tract in inflammations, prevail. The nutrition of the aqueous humor, of the crystalline lens, and the vitreous depends upon the uvea; while we often find the ciliary body affected immediately, and the vitreous remotely, by its inflammations. For the sake of convenience we are nevertheless obliged to parcel out the structures, and discuss the iris and its diseases as a separate topic.

Anatomy and Physiology.—It is a highly organized structure, composed of muscular fibres, pigment, epithelium, connective tissue, blood-vessels, lymphatics, and nerves of every type, and ganglia. It is a curtain whose periphery is attached to the sclera at the edge of the endothelium of the cornea by the fibres of the ligamentum pectinatum (pillars of the iris). This locality is the angle of the anterior chamber and sometimes is called the angle of the iris. The membrane is perforated by a round opening, the pupil, which appears to be in the centre, but is really a little to the nasal side. It rests upon the anterior capsule of the crystalline, over a large area. Between it and the lens a circular space is formed, called the posterior chamber. In section this has the general form of a triangle, into whose base the ciliary processes project. In front is the iris, behind is the lens-capsule and the suspensory ligament or zonula of Zinn. Between the iris and the cornea is the anterior chamber. The anterior and posterior chambers compose the aqueous chamber, and in its fluid the iris floats, giving the most perfect chance for its muscular fibres to exert their force. They are flat,

Digitized by Illinois College of Optometry

arranged in bundles, and are of the unstriped variety. Certain fibres are arranged in curves about the pupil, constituting the sphincter, which is rather nearer the back than the front surface, and can be readily recognized, while other fibres run in radii and are more deeply situated, and have been called the dilator pupillæ; the muscular character of the latter is denied (Grünhagen, Eversbusch, Fuchs).[1] In favor of a dilating muscle, see a later article by Ewing.[2] The sphincter fibres join each other near the pupil in curves or arcades which are often conspicuous. The sphincter is under the control of the third cerebral nerve, the motor oculi. The stroma of the iris consists of layers of connective tissue and blood-vessels, amid which are found spindle and wandering cells and fibres. Its cells do not contain pigment, and have been confounded with the muscular fibres. On the front of the iris is a layer of endothelium, whose edges overlap, and on the back of the iris is a much thicker layer of endothelium deeply charged with pigment, and called in a restricted sense the uvea. This word should, however, be reserved to describe the whole internal pigmentary structure of the globe, viz., iris, ciliary body, and choroid. Schwalbe calls this layer the retinal part of the iris and divides it into two layers. For details see Fuchs, l. c. The front of the iris is checked by numerous threads and pits, and is, therefore, quite rough. Beneath the anterior endothelium is a limiting membrane, and numerous blind openings or crypts (Fuchs) are scattered about, not lined by endothelium, and they communicate with clefts which constitute a system of spaces which surround the middle layer of vessels. The brown pigment is scattered upon it irregularly and the differing hues of its surface are to be explained by referring them to interference phenomena. (See Rood, "Modern Chromatics," pp. 55 and 58.) The pigment is of the same quality and quantity, no matter what may be the effect of its distribution in causing the iris to seem blue, brown, hazel, pied, etc.

When the pupil contracts the iris broadens and grows thinner, its tissue stretches in a radiating manner, which produces diminution of the pupillary openings of the lymph spaces and simultaneous expansion of the peripheral lymph openings. When the pupil dilates the iris grows both narrower and thicker, its tissue is relaxed, the lymph clefts near the pupil are enlarged, while the ciliary or marginal openings of the lymph vessels and the crypts become smaller. The method of dilatation is not fully understood; ascribed by some to the reduced calibre of the vessels, this is denied by Fuchs and assigned to the anterior limiting membrane, but with hesitation. In the movements of the iris the anterior layers slide

[1] Graefe's Arch. f. Ophth., Bd. xxxi., Abth. iii., S. 69.

[2] Graefe's Arch. f. Oph., Bd. xxxiv., Abth. iii., S. 1, 1888.

Digitized by the Internet Archive in 2007 with funding from Microsoft Corporation

over the posterior, and this is facilitated by the existence in its middle of a loose tissue containing large spaces. Hence its permeable character and capacity for absorption.

Most of the prominent lines upon the front of the iris are blood-vessels. They are extremely plenty, and their walls are thick. The sensibility of the iris is acute, and the sensibility of the cornea may be totally lost through paralysis of the fifth nerve, while the iris twigs are unaffected, as I have seen demonstrated by iridectomy in a case of trigeminal paralysis.

The iris is under the control of the ciliary (lenticular) ganglion which lies upon the outer side of the optic nerve about three-quarters of an inch behind the globe, and has three roots—the sensitive from the ophthalmic branch of the fifth nerve, the motor from the third, and the sympathetic from the carotid plexus. The efferent twigs are numerous and fine and surround the optic nerve as they pass to the posterior part of the sclera, and are called the *short ciliary.* There are other nerves called the *long ciliary* which have no connection with the ciliary (lenticular) ganglion, but proceed from the naso-ciliary branch of the ophthalmic (first division of the trigeminus) as it crosses the optic nerve very near the canal. They are usually two, rarely three in number. They must receive twigs of sympathetic fibres from the carotid plexus. They enter the sclera in company with the short ciliary nerves and go forward to the ciliary body upon the horizontal meridian. They seem to control the consensual contraction of the pupil—*i.e.* its concurrence with the behavior of its fellow—also the contraction due to convergence; and they confer sensibility upon the cornea (Querenghi, in Knapp's *Archives,* XX., No. 3, p. 428). These functions seem to be transmitted directly from the brain, and without intervention of the ciliary ganglion.

The iris acts as a diaphragm to cut off the marginal rays of the cornea and lens which could not be correctly focussed, and the size of the aperture varies with the quantity of light. The pupil serves to sharpen the image upon the retina, and it regulates the quantity of light received. Its action is reflex, the afferent nerve being the optic and the efferent nerve the motor oculi. The cerebral centre is the corpora quadrigemina, and the third nerve, just behind the centre for the ciliary muscle has a special nucleus for the sphincter iridis (see p. 152, Fig. 72). See for an account of the action of the pupils, "Die Entstehung der reflectorischen Pupillen-Bewegung," Magnus, Breslau, 1889. Contraction of the pupil is an active force, while dilatation occurs less promptly. The diameter, with repose of accommodation, varies from 2.5 mm. to 5.8 (Woinow), but the differences among individuals are very great. The pupil is larger in children than in adults and in old age it becomes small.

Digitized by Google

The pupils of the two eyes act consensually. If one eye be shaded and the other exposed to bright light, the pupil of the covered eye acts in harmony with that of the other. Contraction of the pupil occurs from stimulus of light, from convergence of the visual lines and from efforts of accommodation.

The pupils, the accommodation, and the convergence of the visual lines possess activities both in co-op ration and separately, which need to be clearly understood. Consensual contraction will occur in a blind eye when light falls upon its seeing fellow. If both eyes are blind and do not react to light, they will both contract upon convergence of the visual lines. Efforts of accommodation cause contraction in eyes insensitive to light; *i.e.* blind. Pupils may contract sluggishly to light and actively to convergence. If there be homonymous lateral hemianopsia, the pupils will contract if light be thrown exclusively on the blind halves of the fields if the lesion be behind the corpora quadrigemina, and will not contract if the lesion be in front of or at these optic lobes (see p. 708).

The explanation of these facts is found in the anatomical arrangements. The pupillary centres are linked with the centres for convergence (see p. 154), and their influence comes down the oculomotor nerves; so with the accommodative centres. The light reflex goes up the optic nerve and by the anterior quadrigeminal bodies is transferred to the oculo-motores. Still further[1] it seems established that the short ciliary nerves from the lenticular ganglion in the orbit control the accommodation, the pupillary contraction upon illumination, and the sensitiveness of the cornea to pain, while the long ciliary nerves control the contraction of the pupil to consensual action and upon convergence and give the tactile sense to the cornea. Dilatation of the pupil, apart from the cessation of contraction on suspension of the producing cause, occurs from many causes, viz., irritations of the surface by galvanism or tickling, psychical emotions, such as fright, with deep inspirations and expirations, etc. Myopes often have large pupils. On the other hand, severe irritation of the cornea, as by a foreign body or a blow on the eye, causes strong and spasmodic contraction which will often resist repeated use of atropia. The passive state of the pupil is moderate contraction, and this we find in sleep. In nervous and excitable persons the pupil is large.

The separation of the pupils from each other varies with age and sex, and with the form of the face. In adults it has a average of 58 mm. The inter-pupillary distance used by Nagel[2] in his tables, respecting the metric angle of convergence, varies from 50 to 75 mm., and he takes as a general basis of his calculations 63 mm.

[1] See Querenghi quoted in Knapp's Archives for Ophth., July, 1891, p. 428.
[2] See G. and S., Bd. vi., S. 481.

Functional Diseases of the Iris.

We have variations in size and activity of the pupil due to irritating and paralytic causes and these may be either local or remote. There may be permanent or temporary enlargement (*mydriasis*) or diminution (*myosis*), or the conditions may alternate (*hippus*). A strictly ocular affection will usually concern but one eye, while it also happens that monocular mydriasis of moderate degree may depend on incipient brain disease, which may be the precursor of insanity—such is sometimes the fact in general paresis.

1. *Mydriasis*, dilatation of one pupil of slight amount with preservation of its activity, is sometimes seen as an unimportant affection which may continue for years. Its cause is unknown, but is probably local to the iris. 2. Large and permanent dilatation is caused by sudden increase of intraocular pressure as in acute glaucoma, and a similar result belongs to the advanced stage of chronic glaucoma. 3. When the retina or optic nerve are so far diseased as to greatly reduce the light sense, dilatation becomes permanent and extreme. In glaucoma the mydriasis is due to impairment of the motor fibres and reduction of the reflex sensibility; in amaurosis it is due to interruption of the reflex action. 4. Mydriasis is sometimes the result of a blow on the globe. 5. Mydriasis ensues sometimes after diphtheria and is a local paralysis, while more frequently paralysis of the ciliary muscle and loss of accommodation without dilatation of the pupil is the sequence. This will get well in a few weeks and is benefited by electricity. 6. Paralysis of the third nerve causes mydriasis which can be increased by atropia; the cause may be orbital or intra-cranial. The anterior pair of the corpora quadrigemina preside over the contraction of the sphincter pupillæ and between them and the origin of the third nerve communicating fibres (Meynert's) pass, and here we have the centres for pupillary contraction, for convergence, and for accommodation, close togther, but distinct (see p. 147 et seq.).

Mydriasis from irritation of the pupil-dilating centre, is moderate in degree, is consistent with mobility of the pupil and occurs: "*a*, in hyperæmia of the cervical portion of the spinal cord, and in spinal meningitis; *b*, in the early stages of new growths in the cervical portion of the cord; *c*, in cases of intra-cranial tumor and other diseases causing high intra-cranial pressure, according to Raehlmann, although Leeser points out that these may also give rise to paralytic mydriasis; *d*, in the spinal irritation of chlorotic or anæmic people, after severe illness, etc.; *e*, as a premonitory sign of tabes dorsalis; *f*, in cases of intestinal worms and some-

Digitized by Google

times in other forms of intestinal irritation; *g*, in psychical excitement, *e.g.*, acute mania, melancholia, progressive paralysis of the insane (often then unilateral with myosis in the other eye)" (Swanzy). Irritation of the side of the neck will dilate the pupil.

2. *Myosis.*—Contraction of the pupil, as said already, may be caused by a blow or by a foreign body on the cornea. When the aqueous humor is evacuated the pupil contracts. Hyperæmia of the iris causes contraction of the pupil. Myosis from *irritation* of the cerebral centre is found in, "*a*, the early stages at least, of all inflammatory affections of the brain and its meninges, in simple tubercular and cerebro-spinal meningitis. When in these diseases the medium myosis gives place to mydriasis, the change is a serious prognostic sign, indicating the stage of depression with paralysis of the third nerve; *b*, in cerebral apoplexy the pupil is at first contracted, according to Berthold, who points out that this contraction is a diagnostic sign between apoplexy and embolism, in which latter the pupil is unaltered. *c*, in the early stages of intracranial tumors situated at the origin of the third nerve or in its course; *d*, at the beginning of an hysterical or of an epileptic attack; *e*, in tobacco amblyopia, from stimulation, probably, of the pupil-contracting centre by the nicotine; *f*, in persons following certain trades as the result of long-maintained effort of accommodation (watchmakers, jewellers, etc.) the pupil-contracting centre being subject to an almost constant stimulus; *g*, as a reflex action in ciliary neurosis; consequently in many diseased conditions of those parts of the eye supplied by the fifth nerve" (Swanzy).

Paralytic myosis occurs in diseases of the spinal cord, *i.e.*, its cervical portion (cilio-spinal centre): *e.g.*, injuries, and inflammations especially of the chronic form. Spinal[1] myosis appears under two forms, one of which is simple, and the other is known as the Argyll-Robertson pupil who first called attention to it, 1869. In the simple form there is medium contraction, and the pupil reacts both to light and to visual convergence. We find this in gray degeneration of the posterior columns of the cord. The very minute pupil sometimes seen in tabes dorsalis is probably due to secondary contraction of the sphincter pupillæ. The Robertson pupil is one which is contracted and responds very feebly or not all to light; but actively responds to convergence. Put the patient before a window and let him fix on a distant object, like a tree or house. Shade his eyes with the hand. If the pupils react little or not at all, bid him fix the finger at 10″, and the resulting prompt contraction, whether the eyes be shaded or exposed,

[1] "Eye Disturbances in Tabes Dorsalis," Schmeichler, Arch. für Ophthal., vol. xii., p. 335, 1883; Am. Ed.

Digitized by Google

indicates the symptom. That convergence and not accommodation causes the myosis can be proved by putting on glasses, —4. D if the patient be emmetropic, and observing the pupillary effect as the eyes fix with parallel axes and again fix at 10″. The centre for convergence is anterior to that for accommodation. (See Magnus, "Anleitung zur Diagnosis von Störungen d. Central. Ophth. App.," Breslau, 1892).

Sluggish reaction to light, with prompt response to convergence, is due to extension of spinal disease to the communicating fibres of Meynert from the tubercula quadrigemina to the pupillary nuclei of the third nerve, or to disease of fibres from the optic tract to the pons Varolii. It is a symptom of locomotor ataxia and of multiple sclerosis.

Lesions due to Disease of the Cervical Sympathetic (reference has been made to this condition on p. 432).—Disease of the cervical sympathetic is either irritative or destructive, and as its functions are dependent on integrity of the spinal cord, disease of the latter [1] or of the vertebræ between the fourth cervical and the second dorsal (cilio-spinal centre of Budge) may cause symptoms closely resembling those primary to the sympathetic. Reflex symptoms from the brain of an emotional character simulate some of the symptoms to be referred to, and we find them likewise to some degree in progressive muscular atrophy.

The symptoms of *irritation* of the cervical sympathetic which were conspicuously pointed out by Horner [2] (1873) are, dilation of the pupil, widening of the palpebral fissure, slight protrusion of the globe, pallor of the side of the face and head, with slight fall of local temperature, sometimes increase of perspiration, and acceleration of the heart's action. Usually the only symptoms are enlarged pupil, pallor of face, and rapid pulse—the exophthalmus and wider palpebral fissure are, however, added to the picture in most of the cases noted by the ophthalmologist. *Destructive* disease of the sympathetic occasions symptoms the converse of the above, viz., marked contraction of the pupil, which irresponsive to change of light or to irritation of the side of the neck, slightly increased by accommodation, and resists the action of mydriatics. The vessels of the iris, choroid, and retina disposed to be dilated, the upper lid droops and the lower lid is slightly lifted, owing to paresis of Müller's muscle. Retraction of the eyeball is a late symptom and not often noticed. The vessels of the face, conjunctiva, nostril, ear, and scalp are dilated, giving a flush to half the face and head, with sense of heat and rise of temperature by 1.5° F. measured in the nasal or auditory meatus. This congestion has

[1] Ross: "Diseases of the Nervous System," 2d ed., 1, 686–688.
[2] Klin. Monatsblätter.

Digitized by Internet Archive

been known to last three years, in other cases for nine months, followed by a return to normal conditions more or less perfect. The contrast of the states above described has led to the division of the disease into two stages, but in the condition of recovery the half face may remain paler than the other side and be less sensitive to changes of external temperature.

Increase of tears and perspiration is an inconstant symptom, and the opposite states have been observed. Palpitation of the heart is often an annoying symptom and may be associated with a slow pulse, viz., to 74 or 66. At a later stage the pulse may rise, but never higher than 88 (see Möbius' [1] case). Slight atrophy of the face is a late occurrence, and glycosuria [2] has been observed.

Causes are various, viz., tumors pressing on the sympathetic cord or ganglia, such as enlarged glands, aneurisms, or abscess; cicatrices of old wounds; extension of inflammation from the apex of the pleura in phthisis or chronic pleurisy; injuries and wounds in the neck,[3] and, as above said, any lesion of this region of the spinal cord or vertebræ calculated to provoke irritation of the sympathetic.

Pathology.—In the very few cases where an autopsy has been made there has been found (1) parenchymatous inflammation of the cells of the ganglia, attended by swelling, loss of nuclei, granular and fatty degeneration and by atrophy, together with degeneration of the fibres issuing from the cells. (2) A sclerotic process in the connective tissue in and about the ganglia and in the nerves, resulting in such an increase in the interstitial tissue as to compress and injure the cells and axis cylinders. These may be observed in the later stages of the diseases. (3) In a number of cases the vessels within and about the ganglia have been found dilated, tortuous, and varicose, and hemorrhages from them are not rare.

Prognosis depends on the cause and upon the estimated amount of injury to the nerve or its ganglia.

Treatment.—Removal of any curable causes, as tumors, etc., attention to general health; sources of reflex irritation are to be eliminated. If the nerve has been severed its ends may be united by a stitch, although there are no precedents. Electricity and galvanism have been tried and abandoned as useless by all good authorities.

The above account has been abridged from an article by Dr.

---

[1] Berlin. Klin. Wochen., 1884, No. 16.

[2] Gerhardt: Volkmann's Sammlung. Klin. Vortrage, No. 209, "Ueber Angioneurosen," p. 11.

[3] Hutchinson: Ophth. Hosp. Reports, v., 138, 1865.

Digitized by Illinois College of Optometry

M. A. Starr, on vaso-motor and trophic neuroses, and his references are as follows:

Ogle, Med. Chirurg. Trans., xli., 397-440, 1858, 27 cases; Porteau, "Le Nerf Sympathetique," Thèse de Paris, 1869, 19 cases; Eulenberg and Gutmann "Die Pathologie der Sympathicus," 1873; Nicati, "Le Paralysie du Nerf Sympathique Cervicale," 1873, 25 cases; Seeligmüller, Inaug. Dissert., 1879; Mitchell, "Injuries of Nerves;" Möbius, "Pathology der Sympathicus," Berlin. Klin. Wochen., 1884, Nos. 15-19.

Paralytic myosis is found in general paralysis of the insane. Myosis also occurs from paralysis of the cervical sympathetic. If it be divided (Claude-Bernard), the pupil contracts, the eyeball is retracted, the palpebral opening becomes smaller, the temporal artery is dilated, the corresponding half of the face becomes congested, warm, and moist with perspiration. Similar results have followed cases of injury.[1] Horner has called attention to this condition occurring spontaneously. Willbrand published a case where such symptoms were caused by the pressure of a lymphatic gland in the neck.[2] The pupillary fibres of the sympathetic leave the cord at the upper dorsal and lower cervical vertebræ and going through the superior cervical ganglion enter the carotid plexus; they then pass through the ciliary ganglion in the orbit; but not the whole of the fibres take this course to the eye, because it is found that if the ciliary ganglion is extirpated, irritation of the trunk of the sympathetic will dilate the pupil. The ophthalmic branch of the fifth nerve, and probably other nerves also furnish channels of access for sympathetic fibres (Hensen and Volckers).

3. *Hippus.*—Alternate contraction and dilatation of the pupil occurs sometimes in cases of nystagmus, but as a symptom of disease of the nervous system it has been seen in multiple sclerosis, after epileptic attacks, in hysterical spasms and in nervous persons, and the oscillations persist under exposure to bright light. During the phenomena of the Cheyne-Stokes respiration something similar, but less intense, is observed; at the beginning of the cessation of breathing the pupil contracts and ceases to respond to light, at the first movement of respiration or a little before, the pupil will dilate. Rhythmical contractions have been seen in typhoid fever during the stage of brain trouble.

Treatment of the above conditions requires but few words. Seldom will any measures be required, because the constitutional malady will be the object of attack. For mydriasis of a purely local character, which is very rare, weak eserine solutions may be given,

[1] See Archives Générale de Médecine, tome xiv., p. 286, 1869, also Hutchinson, Ophth. Hospital Reports, vol. v., p. 138, 1865.

[2] Graefe's Archiv f. Ophth., Bd. 1., S. 319, 1854.

Digitized by Google

but what is to be said at this point will be deferred to the section on paralysis of accommodation.

Irido-donesis or *Tremulous Iris.*—A partial or total dislocation or absence of the lens, will permit the iris to oscillate in sudden waves. It is sometimes seen in hydrophthalmus. It depends upon want of support, and may or may not be accompanied by fluidity of the vitreous. Nothing is to be done for it.

Regarding the effect of medicines on the iris, see pp. 218, 221.

Congenital Defects of the Iris.

1. *The want of pigment* which characterizes albinoes gives to the iris a silvery whiteness seen in white rabbits or a tinge of red or a reddish-brown color when there is not total lack of pigment.

2. The iris is sometimes entirely absent, a very rare defect, *irideremia.*

3. *Coloboma,* partial or complete and affecting either one or both eyes, is not very uncommon. It is almost always vertically downward, in rare cases it is lateral. The iris alone may be divided

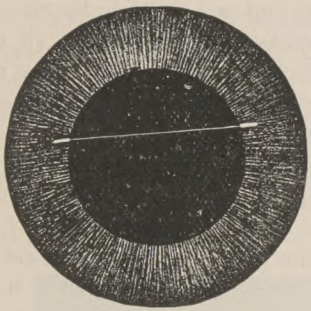

Fig. 153.

Fig. 154.

or the fissure may also run through to the choroid. In other respects the eye is apt to be imperfectly developed. It may be too small (*microphthalmus*), there may be partial cataract, generally vision is amblyopic. The pupil remains contractile.

4. *Membrana pupillaris perseverans* describes what usually consists in the presence of one or more threads running across the pupil, attached not precisely on its edge, but a little outside of it, and which is the remnant of the membrane which during fœtal development is differentiated into the choroid behind and the membrana pupillaris in front. Various kinds of this defect may occur, and they have been well indicated by Dr. Collins[1] in diagrammatic sketches. In certain types there is adhesion to the lens capsule as I

[1] Royal London Ophthalmic Hospital Reports, vol. xii., July, 1885, p. 195.

Digitized by Illinois College of Optometry

have seen and sometimes this might be mistaken for inflammatory adhesion. See case by Seggel, *Klin. Monatsblatter,* Aug., 1890.

Polycoria is a rare anomaly indicating a multiplicity of pupils. The supernumerary pupil may be close to the normal pupil or at the periphery. The congenital defect must not be confounded with perforations due to atrophy. See Schweinitz, Trans. Am. Oph. Soc., 1891, p. 59.

Inflammation of the Iris.

The signs of *iritis* are objective and subjective. The former are found in change of color and texture of the membrane, and in the abnormal behavior of the pupil, and in the usual tokens of injected blood-vessels and external effusions. Change of color of the iris in the early stage will consist in loss of the brilliancy of its surface, the tracery and pattern are blurred, the tone becomes darker, and with increase in the inflammation a marked difference appears between the two eyes, if one remains unaffected. If both are implicated a blue iris will change to a dull gray, a hazel to a dirty brown, and in advanced cases a greenish hue is often seen. The tissue is swollen and infiltrated, under a lens or by the naked eye hemorrhages may be seen, and spots or even masses of exudation. The aqueous humor is turbid and this is best seen by noting that the pupil is smoky instead of a clear jet black; condensed light will bring out this fact. The pupil will be small, it will not respond to variations of light. Adhesions or deposits of pigment may be seen at its edge, and their formation (*posterior synechia*) takes place at a very early period.

If not readily discernible, adhesions will become apparent upon dropping a solution of atropia into the eye. They are the decisive and most constant indication of iritis. The smallness of the pupil results from the swelling which pushes the membrane into the space which is free for it to occupy, and hence both the earliness and the constancy of adhesions to the lens.

The cornea may be clear, and its reflex bright, but in bad cases it becomes dull, its surface steamy, and upon its deep layer pigment deposits will be seen. The turbidity of the aqueous humor sometimes gives rise to yellow precipitate in the anterior chamber (hypopyum). The globe is painful to the touch, its tension may be normal or sometimes increased; a state of minus tension indicates the complication with cyclitis and belongs especially to chronic cases.

We have also hyperæmia of the ciliary vessels; in the mild cases or as the disease abates, there will be a corona, limited to the vicinity of the cornea, composed of pink, fine, nearly straight vessels

Digitized by Harvard College Library

radiating outward, and forming a zone about six millimetres wide, with prolongations running out toward the recti muscles (see Fig. 155). This is sometimes called the iritic zone. Let the disease be severe, and the conjunctival as well as deeper vessels will be engorged, the whole front of the eye will be intensely red, there may even be a little sub-conjunctival effusion. The secretion will be lachrymal, not mucoidal nor purulent, the eyelashes will not be stuck together, the lids will be imperfectly opened.

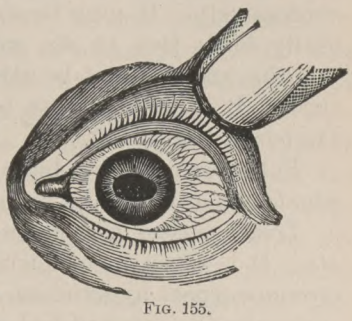

FIG. 155.

Subjective symptoms will be, impairment of sight, which occurs very early, and often becomes extreme, intolerance of light, and pain. The pain is a conspicuous feature from the outset. Situated first in the globe, it soon radiates along the branches of the fifth nerve, chiefly the supra-orbital and malar. Tender points will be at the supra-orbital notch and at the vertex. It spreads sometimes to the side of the nose and the inner side of the orbit, but the usual complaint is of the forehead and top of the head and the temple; the pain is most severe toward night, or early morning, and often robs the patient of sleep.

Adhesion of the pupil has been said to occur at an early period, and the reason is that the aqueous quickly is saturated with plastic material, and readily glues together surfaces which are already in contact (Arlt). If atropia is used very early, these adhesions, being soft, will give way in part or wholly. If the pupil should become

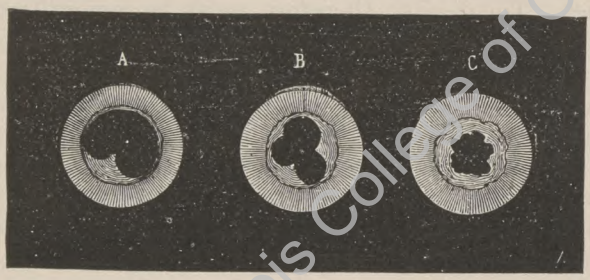

FIG. 156.

round and fully expanded, it may again acquire adhesions in its enlarged condition. If the adhesions only yield in part, the pupil acquires most irregular shapes according to the number and breadth of the attachments. It will be festooned in various ways (see Fig. 156). The plastic exudation becomes firmer and better organized as the disease advances. If treatment is inefficient, the

Digitized by Illinois College of Optometry

pupillary space becomes choked (*occlusion* of pupil), the edge becomes wholly adherent and communication between the anterior and posterior chambers will be cut off (*exclusion* of the pupil).

Iritis may attack one eye, or both, and either simultaneously or successively. It may be so slight as to pass in a few days, it generally lasts two to six weeks, if neglected it may continue for months, and the end be atrophy of the globe and hopeless loss of sight. It is not a disease to be treated expectantly, its tendencies are toward mischief.

Pathologically we have several varieties, viz., *serous, spongy, plastic* or *gummy,* and *suppurative* iritis.

Iritis serosa was formerly called Descemitis, aquo-capsulitis, etc. It is often inconspicuous in symptoms; there will be slight circum-corneal hyperæmia, vision will be reduced but perhaps not seriously, the eye will feel uncomfortable. By close inspection the posterior surface of the cornea is found dotted with specks of pigment, especially upon its lower third, the aqueous is cloudy and may be in large quantity, the iris is pushed backward and dull, the pupil acts sluggishly and may have some synechiæ. Iritis with abundant *serous* effusion, as shown by the fulness of the anterior chamber, may be an *acute* and painful disease, while the condition now mentioned is a *chronic* affection, with inconspicuous symptoms, which may last for weeks. Dr. Knies in 1879 reported an autopsy of such a case and found that the whole uveal tract was involved, as well as the sheath of the optic nerve up to the chiasm. The optic nerve was inflamed and also the retina, for a small area around the papilla. The deep part of the vitreous was liquefied and detached; its anterior part permeated by granular cells and membranes. The disease, therefore, must be generalized, as much more than iritis, and might perhaps be called *uveitis serosa* or *uveitis anterior* (see p. 407), cyclitis serosa.

The changes which iritis produces in the aqueous humor have been referred to, especially that it becomes highly albuminous or fibrinous. It seems likely that its chemical alteration has some effect in dissolving the pigment of the iris and thus favors its deposit upon the back of the cornea. The turbidity of the aqueous arises from the presence of lymphoid cells, pus, and red blood-corpuscles. They become disorganized into molecules, and may precipitate as hypopyum. They form groups and masses deposited on the cornea and they will be felted in a web of fine fibrillæ.

The most marked illustration of turbidity of the aqueous appears in a condition which has been called *spongy* iritis (Knapp). I have seen it a few times. The iris is pushed far back, is very much obscured by the muddy aqueous. As the fluid grows clear, beginning at the edge of the anterior chamber, the material seems

Digitized by the University of Michigan

to have a semi-solid form and has been mistaken for a dislocated lens. It may seem to come from the iris like a cyst; usually it is absorbed completely, shrinking to a thin membrane covering the pupil and finally disappears without synechia. Arlt has examined the material and describes it as sero-fibrinous and hemorrhagic, in which the fluid and cell elements tend to separate, and the fluid also separates into a network of very fine fibres like the exudation of croupous pneumonia, and a formless gelatinous mass.

While plastic exudation is the rule in iritis, we have a type in which yellow nodules and masses, one or many, project from the surface of the iris, and are called *gummata or condylomata*, a name given because of their very generally syphilitic origin. They are a brownish-yellow, or streaked with blood, or may form a deposit at the bottom of the anterior chamber. When absorbed they leave a grayish discolored spot where the iris will be adherent and atrophied; sometimes such changes are very extensive. The same deposits occur in the ciliary body and choroid and a large mass may soften the sclera and project in a considerable tumor. Similar nodules are occasionally seen in rheumatic forms, and the resemblance to tubercular deposits must not be forgotten (see below).

Suppurative iritis is generally the effect of wounds or of operations, or of infectious diseases. It is usually only a part of general suppuration and need not be specially described.

A most insidious and rather rare form of iritis occurs with almost no signs, either subjective or objective, save dimness of sight and posterior synechiæ revealed by atropia. I have seen it, and Mr. Hutchinson describes cases, Trans. Oph. Soc. United King., Vol. VIII., pp. 95, 117, under the name of *quiet iritis*.

Complications.—Supposing the disease to have apparently started in the iris, we have already referred to the possibility of faint haziness of the cornea and to the deposits upon its posterior surface. It is proper to emphasize the intimate connection which subsists between all parts of the uveal tract, and that the iris is often only the middle factor in a morbid process which may reach in both directions, forward or backward. The iris is acted upon by inflammations of the cornea and sclera, as well as by inflammations of the choroid and ciliary body. On the other hand, one must be vigilant to note when iritis passes into irido-cyclitis or irido-choroiditis. There will always be hyperæmia and some tissue changes of the deeper uveal structures, but lesions which demand attention often appear and will be referred to later.

It has been asserted that during iritis the retina and optic nerve may be inflamed without concomitance of the ciliary body and choroid (Schnabel), that a gray or yellowish infiltration may appear in the retina near the optic disc, that the latter may be hyperæmic and

Digitized by Harris College of Optometry

swollen, and that this condition may last longer than the attack of iritis, and account for persistent dimness of sight. It is difficult to decide the existence of such lesions while the media are hazy, and it is true that the disc if discernible will sometimes be red, and at other times free from hyperæmia; careful observation has enabled me to note this difference. When, however, the media are clear enough to permit accurate inspection by the ophthalmoscope, one may sometimes find co-existent retinitis and neuritis. Such a case with plastic exudation into the papilla I clearly remember.

The haziness of the vitreous is occasioned by the presence of minute particles and threads and perhaps membranes. It may be partially or even wholly liquefied. In chronic cases it undergoes serious disorganization, which will be hereafter referred to and which remains. Much of the alteration caused by acute attacks will pass away.

Sequelæ of iritis are: 1st. Adhesions of the pupil to the capsule of the lens, and if they have been torn by atropia, pigmentary spots remain. 2d. The exudation may become organized into a membrane filling the whole pupil, and it is sometimes vascular. If it be very dense it will be indistinguishable from cataract and has been called spurious cataract (see Fig. 157). The pupil is always small in such circumstances. The complete adhesion of the pupillary border

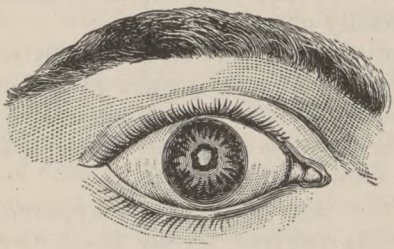

FIG. 157.

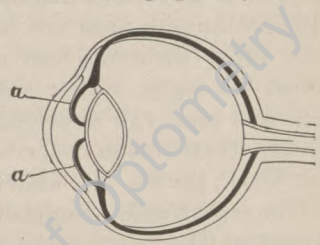

FIG. 158.

forming an annular synechia is called *exclusion* of the pupil. If, in addition, the pupillary area is occupied by a membrane we have *occlusion* of the pupil. 3d. In consequence of the conditions just mentioned, the posterior chamber sometimes becomes distended with fluid and the iris bulges forward, while the pupillary edge is drawn deeply backward, and the periphery pushed against the cornea (see Fig. 158). If at certain parts the iris is more adherent or atrophied, its surface will project in cyst-like forms. It may even be pushed forward so far as to be in almost complete contact with the cornea. The eyeball will be hard and we shall have the conditions known as secondary glaucoma. 4th. The posterior surface of the iris may be more or less completely glued to the lens, taking the contour of its surface, and its periphery may be deeply retracted,

Digitized by Illinois College of Optometry

forming a circular furrow, which indicates that it has acquired adhesions to the ciliary processes. The tension is apt to be reduced.

The evil effects of pupillary adhesions are proportionate to their extent, apart from obstruction or opacity. Broad adhesions which may not be complete, sometimes occasion relapses of inflammation, but this tendency is not so great as was at one time supposed. They render the eye irritable and may require an operation, iridectomy, but not until the necessity for it has by experience been demonstrated. A few small adhesions will not occasion trouble in most instances. Much depends on idiosyncrasy. If, however, the pupil is extensively or wholly adherent, the above-named results become very threatening, if not destructive to sight, and demand interference.

5th. The capsule of the lens may become thickened by proliferation of its epithelium, for a space corresponding to the pupil. Deeper and more serious lesions of the lens occur in chronic and complicated cases, causing so-called inflammatory cataract. The lens is densely white or yellowish, may be chalky, is small, the capsule shrivelled and very thick and the iris will be atrophied. Atrophy of its tissue occurs in many chronic cases, and is recognized by extreme thinness of its structure, often in patches, which will seem to be frayed out and gray and permit light to pass through when viewed by the ophthalmoscope or under oblique illumination.

Causes of iritis are local and constitutional. It may come from functional strain, from injury, from operations, from penetration of foreign bodies, by extension from adjacent structures, viz., the cornea, the choroid and ciliary body, from a swollen lens, detachment of the retina, etc., and we have it also by communication from the opposite eye as sympathetic ophthalmia. More frequently it is due to constitutional causes, especially syphilis, both secondary, tertiary, and hereditary, and sometimes intra-uterine. Rheumatism and gout are next in potency as causes, and the attacks which they cause are obstinate, painful, and recurrent. Syphilitic iritis is of the plastic tendency, rheumatic and gouty are more serous. Gonorrhœa occasionally causes iritis. The arthritis of gonorrhœa is due to the presence of the gonococci (diplococci of Neisser) in the joints, and the same explanation is probable for iritis. Other causes are, malaria, febris recurrens, variola, scrofula, tuberculosis, diabetes mellitus, and conditions which are unknown. Syphilis stands for the cause in about 60% of all cases (Alexander).

It is impossible by the quality of the inflammation to declare what may be the constitutional cause, except in a restricted sense, as for example, that gummy exudation is almost certain to be syphilitic; etiological deductions must come from inquiry into general symptoms.

Digitized by the Internet Archive in 2010 with funding from University of California

Prognosis.—The duration will depend not only on the severity and cause of the attack and upon its complications, but very largely upon the nature of the treatment. If the pupil is freed from adhesions at an early time or these are few, this is a most favorable circumstance, if not, the duration will be long and the result more or less damaging to sight. The rheumatic and gouty types, while less likely than some others to inflict harm to vision, are apt to be tedious and painful. The duration and injury belonging to syphilitic forms, are in proportion to the quantity of exudation and to the complications with deeper parts. Seldom will an attack yield in less than two weeks and it may go to eight weeks or in case of complications to many months. In simple cases vision will be perfectly restored.

Treatment.—A patient must be kept in more or less seclusion in a room moderately dark and avoid use of his eyes and all sources of irritation. In some severe cases he will be confined to bed. It is true that patients, especially in dispensary practice, go out of doors and sometimes do not interrupt their avocations, but the effect is unfavorable, even though the sore eye be bandaged or shaded.

The essential and master remedy in iritis is sol. atropiæ sulphatis, from the beginning onward to the end. The prevailing fault is to use it with too much caution. Its potency when the iris is inflamed is far less than when the eye is normal; the reasons are as follows: The activity of endosmosis through the cornea is impaired because its tissue is surcharged with fluid, and the tension of the globe is increased. The swollen condition of the iris, the inaptitude of its muscular fibres to contract, the hyperæmia and the adhesions combine to oppose its effect, even when the solution has entered the aqueous chamber. For these reasons, a solution, gr. iv. ad ℥ i., must be used in such frequency as will effect the purpose. This will vary in different cases. It will be dropped in four to six times daily, or once in two hours; or it may be put in six times an hour three times daily, or four times an hour three times daily. For iritis after extraction of cataract, I use a solution, sixteen grains to the ounce—the condition not permitting frequent instillations, and for this reason the strength is increased. So long as certain pernicious effects presently to be described do not occur, the effort to dilate the pupil is to be perseveringly pushed until it is actually accomplished. But there are certain possibilities of harm in atropia, not to be overlooked: viz., its poisonous constitutional effects. Patients may quickly complain of dryness of the throat, and it will be seen to be red and the saliva scanty—this is not to be heeded as dangerous; but when a flushed face, a quick and feeble pulse, nausea, prostration, and fainting appear, and when, as sometimes

occurs, delirium, at first talkative, afterward with delusions and violence, shows itself, the situation is sufficiently alarming. Some persons are specially susceptible, and are disturbed by small quantities. When such signs arise, the atropia must be stopped, alcoholic stimulants given, and, if violent delirium exist, hypodermic injections of sulphate of morphia, gr. $\frac{1}{4}$ to $\frac{1}{6}$, repeated as needful. To prevent poisonous symptoms, care should be taken to drop the solution into the outer rather than into the inner angle, and hold the head so that the fluid does not readily flow toward the puncta; pressing with the finger over the puncta and sac is of service to hinder passage of the solution into the throat. Another, but less frequent and less serious effect of prolonged use of atropia, is that it causes a form of granular conjunctivitis. It is now believed that the presence of germs in the solution accounts for this effect. Cohn, Hirschberg, Franke, and Ruppell all concur on this point. It is better to sterilize the solution by boiling, and to change frequently. Atropia may be mixed with vaseline and so employed. If atropia must be abandoned, we have a substitute in duboisia, to be given in the same strength of solution, or hyoscyamine; but both these are in a degree liable to cause like constitutional effects. Usually all mydriatics must be renounced until the toxic symptoms subside, and then resumed in such degree as may be tolerated. One need not expect the full effect on the pupil at the beginning, and if there be great hyperæmia, the use of leeches to the temple will promote its absorption; if the anterior chamber be deep and the eye tense, paracentesis will greatly aid its effect. It is a common experience that as soon as the pupil enlarges to a considerable degree, say to about six or eight millimetres, the symptoms speedily give way and recovery sets in. This will take place even though some adhesions remain. Yet in rheumatic iritis this happy sequence does not always appear. The aqueous remains turbid and in large quantity, and pain continues. It will be well to apply two leeches to the temple, and paracentesis may be admissible. It is also efficient to give a hypodermic injection of morphia. Another remedy to aid in bringing about dilation is the hypodermic injection of muriate of pilocarpine, gr. $\frac{1}{6}$ or $\frac{1}{10}$ (Schweigger). Iritis may occur in persons of gouty diathesis as the first token of their constitutional tendency. If it appear when there is great depreciation of health, the disease may not be violent in intensity, but is likely to be most pertinacious in duration, and aggravating in its ups and downs. Nothing but general hygienic measures will in some cases be of any value—except, always, atropine.

An additional application is warm water, and the temperature such as the patient prefers. Sometimes for suppurative iritis, es-

pecially traumatic, water as hot as can be borne is to be kept continually applied for two or three hours, and this repeated three or four times daily. To less severe cases dry warmth is grateful—a heated napkin, or a bat of cotton and bandage. Cold lotions usually disagree with iritis, except the traumatic kind, and in vigorous persons. For a large proportion of cases the local proceedings will control the attack. For the nocturnal pain, hot fomentations are to be used, and morphia or some kind of opiate administered. Ten grains of antipyrine or of phenacetine will often be very effective, and may be repeated. Rubbing into the forehead the oleate of morphia is a resource when the pain is not very severe. Friction over the forehead and temple, with extracts, and ointments, is uncleanly, yet is in vogue as anodyne. Chloroform liniment, cautiously applied to avoid its getting into the eye, may be comforting. A mixture of chloral hydrate and camphor to which a little oil of wintergreen is added is valuable. In severe cases, especially with tendencies to relapse, confinement in the room is indispensable, until the intensity markedly abates. In debilitated subjects this rule also applies, but may need modification in the use of a thick bandage, and permitting them to walk on a piazza or where, protected from wind, fresh air can be emjoyed.

Constitutional treatment will, in some cases, be indispensable, while even in the syphilitic cases, providing their type is mild, mercurials are often not given until the local symptoms subside. They are not the great weapon of success, while atropia and the above proceedings are, and only need skilful use. But if the attack be severe, if the pupil remains closely adherent, if there be gummy exudation, if the syphilitic poisoning be profound or there be hereditary syphilis, mercury must be given in the most effective way. Inunction is, in many cases, the best method—rubbing into the arms, sides of thorax, or inside of thighs, about half a drachm of blue ointment. If for any reason this is to be avoided, the proto-iodide of mercury, gr. i. ter in die, may be given, while a rapid salivation is to be had by gr. $\frac{1}{24}$ of calomel every hour. Oleate of mercury, twenty per cent, is sometimes, with delicate skins, to be preferred to the blue ointment. Hypodermic injection of corrosive sublimate or of the tannate of mercury has been employed and praised, but I have no disposition to resort to it. In all these cases salivation is to be carefully avoided. At its first sign, a gargle of tannin, or of chlorate of potash, and diligent use of a soft tooth-brush, are to be insisted on. Mercurial vapor-baths, viz., ʒ i. of black oxide of mercury upon a red-hot iron, added to the usual arrangements for a vapor-bath, is an admirable way of getting in the mercury without disturbing the stomach; using it once daily. These proceedings are directed against a case of severe inflamma-

Digitized by Indiana University

tion. But it is very common to give patients the so-called mixed treatment of biniodide of mercury, with iod. potass., and keep it up long after the eye has recovered, to counteract the constitutional poison. For special details as to the treatment of syphilis, I must refer to other treatises. Syphilitic iritis usually comes with a papillary or roseolar eruption, about four to six weeks after chancre, while it may be delayed to the second year or to the tenth year, and it may come as a tertiary symptom. For children the mercurial ointment is the best treatment, combined with careful attention to nutrition, cod-liver oil, healthy and clean skin, etc.

Rheumatic or gouty iritis calls peculiarly for correct constitutional treatment, viz., alkalies in full doses—Rochelle salts, liquor potassæ, lithia water—and especially useful is the Turkish bath. Sometimes colchicum, combined perhaps with iod. potass., will prove its superiority, and, in general, regard must be paid to the phases of the constitutional diathesis, and to the remedies which have proved useful for other symptoms. Salicylate ten-grain doses every two hours until its effects are secured. Pilocarpine muriate given hypodermically is sometimes of value, but regard must be paid to its occasional depressing effects on the heart; the dose will be gr. $\frac{1}{10}$ to $\frac{1}{5}$. Turpentine oil in doses of five drops in capsules, three times daily, has been recommended. I must also insist upon the proper appreciation of a patient's general condition, whether sthenic or asthenic. In the former, purgatives and sweating and diuretics may be exhibited with freedom; in the latter they must be most cautiously given, and often *quinine* will be the potent remedy, and stimulants be needful to build up strength.[1]

Gonorrhœal iritis will be found to keep step with the success of the treatment of the urethra. I have known iritis to follow the introduction of a sound in treating urethral stricture, the same patient having had iritis with gonorrhœal attacks.

Iritis is often cured with perfectly normal pupil, but synechiæ may remain. As has been said above, this fact has been held to account for the tendency to relapses which many cases exhibit. That this is measurably true must be believed. That this is so frequently the case as has been claimed, is not true. Many cases of extensive posterior synechiæ are to be remembered, in the experience of every practitioner in eye disease, which have not had relapses. The operation of *corelysis* was devised by Streatfield and modified by Passavant, to detach such adhesions. The former used a notched spatula, which was inserted between the iris and

[1] Elix. sodæ salycil. co. (Warner) sometimes is more effective than the simple salt both in this and the following type of iritis. It contains iod. pot., fl. ext. cimicifugæ, and tr. gelsemini.

the lens, to pull away the attachment, as with a blunt hook. The latter used a pair of fine forceps to pull off the iris at the adherent spot. In both cases the wound should be in the cornea and oblique, so that while admitting the instrument, the loss of aqueous should be a minimum. Care should be taken not to permit the iris to be caught in the wound, and not into injure the lens capsule. The iris tolerates such an interference well, and the operation may be as many times repeated as the number of the attachments may require; but it has not seldom happened that the synechiæ were re-established. It is wise to wait to learn whether, in a given case, there be need to interfere, and then to choose corelysis or iridectomy, as the condition may dictate. For close and numerous and broad adhesions, iridectomy at the place of attachment should be chosen; for a single or two broad synechiæ, with an irritable eye, or with tendencies toward neuralgia, corelysis with fine forceps may be tried, viz., Passavant's method. Both before and after the operation, atropia must be freely used. At present the operation is less frequent than it was ten years ago.

For severe serous iritis with deep anterior chamber and much pain, paracentesis will be effectual. In the cases with copious precipitations on the posterior surface of the cornea, some of the deposits may thus be evacuated. Horner attempted to rub them off by massage of the eye.

Sometimes we have to deal with chronic iritis with extensive synechiæ, and we find the local and constitutional means almost ineffective. The eye remains hyperæmic; the globe is perhaps tense, perhaps soft. If tense, we may conquer the trouble by iridectomy; if soft, the operation may be attended by excessive hemorrhage and followed by phthisis bulbi. Yet this is not always the issue; at any rate, if left to itself, the eye will be lost, and the operation gives the best chance. Such cases involve the ciliary body and choroid, and are always of grave significance.

What to do when the pupil is extensively adherent is a question which merits still further consideration. The reasons for interference are to improve sight or to control relapses of inflammation or persistent irritability. We now consider the condition which remains some time after acute symptoms have subsided. It may be premised that in chronic and extensive adhesions, instillation of atropia often causes irritation, because ineffective, and only teases the iris. On the contrary, with only a few synechiæ its prolonged use will in the end sometimes rupture obstinate attachments and it may sometimes be alternated with eserine. When mydriatics fail and the pupil is much bound down, iridectomy is the remedy. But when to do it? Not every case of exclusion of the pupil demands it. If only a small aperture permit interchange of aqueous in front of

Digitized by the Internet Archive

and behind the iris, experience shows that many eyes escape trouble. With occlusion of the pupil the dimness of sight may require relief. But unless sight is very poor, there will be not enough gain to justify the operation. In case both exclusion and occlusion exist, an operation will be needful. One must be careful to find out, if possible, the probable state of the deeper parts of the eye, by noting the tension and degree of vision, and the perception of light, and by careful inspection of the iris. If it be atrophied, or much discolored, if it project in bosses or be pushed as a whole toward the cornea, as above described, it may be assumed that considerable mischief has befallen the deep structures and the visual effect of the operation may be disappointing. Benefit may in time accrue, and the operation is justified, because without it the state of the eye would grow worse. It is not always easy to get out a suitable bit of iris when it is atrophied, and sometimes it may even be difficult to push a knife into the anterior chamber without transfixing it. Increased tension is an imperative reason for operating.

Should only the pupillary border be attached, the operation will be technically easy; but cases occur where most of the surface of the iris is glued to the lens and lies flat upon it with retraction of its periphery and atrophy of its tissue. It is difficult to bring out a piece of the membrane, and one may seem to have gained the desired pupil, but no better sight ensues, and on inspection by oblique light it may be found that only the front layers of the iris have been removed, while the pigmentary layer remains sticking to the lens and looks like black velvet. It will be necessary to remove the lens, and probably afterward to deal with a membranous obstruction before a clear opening can be secured. Cases such as these are apt to show diminished tension, and are prone to hemorrhage into the anterior chamber and also into the vitreous, and hemorrhages are liable to occur during the healing, so that their outlook is not promising. An operation may light up chronic irido-cyclitis which had been in abeyance, and issue in phthisis bulbi.

While, therefore, we are ready to give a patient the benefit of iridectomy, it appears that in some cases it is unnecessary, in some it is hurtful, in some the result is disappointing, but it is a valuable resource in the greater number.

Tumors of the Iris.

Tumors rarely occur in the iris; the principal varieties met with are tubercular and sarcomatous, and cystic.

Digitized by Illinois Eye and Ear Infirmary

Tubercles[1] appear chiefly in children, as grayish red, irregular nodules, commonly at the periphery of the iris, accompanied by signs of moderate inflammation, viz., peri-corneal redness, haziness, especially of the lower half of the cornea, photophobia and lachrymation. They become larger and multiply and may in a few months fill the anterior chamber, render the eye hard and painful and end in perforation. Their progress may be more chronic, and without forcing its way through the sclera, the tumor may, after reaching a certain stage, be arrested and shrink, and the front of the globe become phthisical. These growths were formerly described as *granuloma*, but their true nature is better understood and is perfectly identified by recognizing the characteristic bacilli.

Sarcoma is by no means so frequent in the iris as it is in the choroid. The pigmented form is more common than the white. There is usually but a single tumor and it may grow upon any part of the iris. It occurs at any age. When melanotic, its cancerous nature is obvious; if white, the absence of inflammatory irritation, the slowness of its growth, that its form is more or less rounded and not aggregated, will distinguish it from tubercle during its earlier stage, while the later progress of the disease is wholly unlike that of tubercle. The diagnosis between a solitary tubercle and a sarcoma is founded upon the irregular, yellowish-red, dirty-looking quality of the former with injection of the neighboring parts of the globe, while sarcoma is more smooth and regular in contour and less likely to have hyperæmia of the exterior of the globe. Only a considerable experience can make the distinction clear.

Treatment.—When very small, sarcoma of the iris may admit of excision, including a piece of the iris, but seldom will such an opportunity occur, and the only suitable proceeding will be enucleation. An isolated tubercular mass has been excised with no return for seven months (Terson, *Rev. Gener. d'Ophth.*, p. 203, 1891); but for numerous small deposits or a single large one and the eye painful enucleation is advisable. There is danger of general infection in both sarcoma and tubercle of the iris.

There are some other neoplasms which have been found in the iris, such as *vascular growths* (Roosa[2]); *lymphomata* in leucocythemia, *lepra* in cases where this disease of the skin exists.

Cysts of the iris are the effect either of sacculation in consequence of a wound or operation, or they result from the proliferation of cells introduced into the anterior chamber. For instance, if cilia should fall in through a wound, cells from the sac of the hair may originate a cyst. In all cases it is very transparent; it may

[1] See Horner, "Krankheiten des Auges im Kindesalter," p. 367. Also, Michel, "Augenheilkunde," p. 492, 1884, and p. 318, 1890; and Knapp, Helmholtz Festschrift, 1892.

[2] Trans. Am. Ophth. Soc.

be in the substance of the iris, or simply lift its epithelial layer. It is lined with cells, and expands gradually, pressing back the iris, and may disturb vision seriously. If not dealt with, it will set up internal inflammation and destroy the eye. The *treatment* is excision; puncturing is ineffectual. To make an incision of proper size a preliminary cut may be made with a Beer's knife, large enough to enter a scissors-point, and by this, with successive clips, each of which shall not cut more than two millimetres, the wound may be made as large as needful. I have seen the wound completed without puncturing the cyst, and the same might possibly be done by a very narrow Graefe's knife. Iris-forceps then grasp the cyst, and with it the iris to which it is attached, and then it will rupture. Care must be taken to remove the whole sac, and not to leave any tissue lying in the wound. Healing occurs kindly. A relapse is sometimes observed. If the case be allowed to go too long, the eye may require enucleation, because the cyst may invade the ciliary region, or set up sympathetic inflammation.

Sometimes a *cysticercus* has been found in the anterior chamber. The movements of the animal betray its true character. Its removal is not difficult. I once removed a *filaria* from the anterior chamber of a horse.

Digitized by Illinois College of Optometry

CHAPTER VIII.

OPERATIONS ON THE IRIS.

Iridectomy, Iridotomy, Irido-Rhexis, Corelysis, Iridodesis.

The most frequent operation upon the iris and one which has a wide range of applications is iridectomy.

The indications for it are: 1st, therapeutic, and 2d, optical, or both may be combined. It is done for *therapeutic* purposes to diminish intraocular tension, as in cases of staphyloma or in general hardness of the eye, as in glaucoma of various types; in cases of sclero-keratitis; also, it has application for adhesions of the pupil, or with unyielding or recurrent iritis, or for rapidly increasing ulceration of the cornea; sometimes for keratitis with hypopyon and for rapid swelling of the lens after injury; it may be coupled with linear extraction of cataract, and with the removal of foreign bodies on the iris or in the lens; it may be preliminary to extraction of cataract. For *optical* purposes it is done for opacity of the cornea, for occlusion of the pupil, for central stationary opacity of the lens or its capsule, for luxation of the lens, and as part of the operation for extraction of cataract.

Before doing iridectomy for *visual* purposes, it must be ascertained that there is perception of light—enough to warrant its performance, and next, that the visual field is not too greatly encroached upon as by detachment of the retina. The choice of place for the new pupil is in many cases determined by the region where the transparency of the tissues will give the best sight. If the opacity of the cornea or lens be central, the choice of place is at the lower part of the cornea, below the horizon. When an artificial pupil is made, for enlarging the field of sight, it is often best to place it outward. Should both eyes be operated on, the pupils ought to be symmetrical, *i.e.*, both inward, or both outward, or both downward. Should the upper part of the cornea be selected, the pupil may be made more available by cutting the superior rectus tendon, provided the patient has but one eye. The place of election in therapeutic iridectomy is determined in many cases by the lesion, but if the locality be optional, it should be made up-

Digitized by the College of Physicians

ward, that the upper lid may cover it as much as possible. The distance of the incision from the corneal margin will vary with the case. The rule may be thus stated: for an optical purpose it should be kept as near the centre, or the best portion of the cornea, as may be possible; for therapeutic purposes, it should be laid in the scleral edge, even one and one-half millimetres from the transparent cornea. A pupil for optical purposes should be small, *i.e.*, from two to four millimetres wide at its base. For therapeutic purposes it should be broad, from five to eight millimetres wide. The thickness of the cornea must always be remembered: that the inner orifice of the wound is smaller than the external opening, and that it regulates the size of the iridectomy.



FIG. 159.

The instruments to be chosen are the following: a spring-speculum, fixation-forceps, an iris-knife (see Fig. 161), iris-forceps (see Fig. 159), scissors, and a curette or spatula; a bit of muslin with a mass of cotton upon it, to be used to check spasm or hemorrhage, is to be at hand in every operation which opens the eyeball. If anæsthetics be used, a Desmarres' lid-elevator of large size must be ready for instant use to pull forward the tongue by slipping it over its base and hooking it up. The patient may sit in an operating-



FIG. 160.

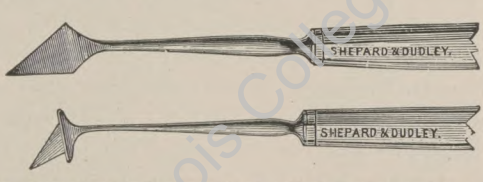

FIG. 161.—One of the Iris Knives has a Stop, which is convenient in special cases.

chair, but it is better for him to be on his back on a table or hard bed. Instillation of 2% or 4% solution of cocaine will in the great majority of cases render ether or chloroform unnecessary. But with children or very timid persons general anæsthesia at least to sufficient degree to secure quiet behavior, will be necessary. Deep anæsthesia will be seldom called for, except perhaps in acute and

Digitized by Illinois College of Optometry

severe glaucoma or where an operation is technically very difficult. The kind of knife depends on the size and situation of the iridectomy. For a very narrow one, a broad needle, straight or bent, is the best. For a wound of five millimetres, a lance-knife, straight or bent, is suitable, and it can be used in the transparent cornea or at the limbus. For very peripheral, and also for large incisions, a Graefe's knife is to be preferred with which to make puncture and counter-puncture. Lance-knives should be held perpendicular to the cornea until the point is seen to be inside; then depress the handle, that the blade may become parallel to the iris, and press steadily forward. Such knives penetrate hard, and a to-and-fro movement of the handle assists their entrance. They must be very thin in order to be sharp, and the point may even bend on light pressure on the thumb nail. If a Graefe's knife is used it should be very narrow. With it the inner opening is apt to be considerably smaller than the outer. This may be obviated by entering nearly perpendicularly and after the point has entered

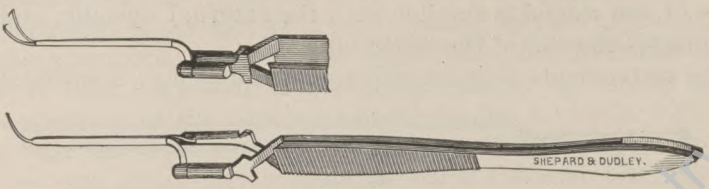

FIG. 162.

far enough, bring it up to the place of counter-puncture and instead of advancing, draw it back for a millimetre, and then push forward and complete the cut. This little manœuvre opens the inner edge of the entrance wound and permits the knife to glide easily forward. Much less pressure is made upon the globe by using a narrow cataract knife than with the lance and for this reason it is often to be preferred. Forceps may be straight or curved, according to need. With a small wound the forceps in Fig. 162 (Liebreich) will be useful, because the points spread more widely after being entered than is possible with the usual model; they are also useful for some forms of membranous cataract. When a very small pupil is desired (an optical pupil) and the iris is not adherent, Tyrrel's hook is to be preferred to any form of forceps (see Fig. 160). Scissors should be curved on the flat, and sharp-pointed. Another form, with a bend at the joint in the plane of their spread (Maunoir's), is sometimes useful.

In operating, the performance is as follows: Syringe out the conjunctiva with a weak antiseptic, viz., sol. acid. boric., 4%, or sol. corrosive sublimate, 1 to 5,000. If anæsthetics be used, two assistants are better than one. With cocaine there will be pain when

Digitized by Illinois College of Optometry

the iris is cut. Put in the speculum with blades closed and held by the screw-head; open the lids by turning the screw, apply fixation

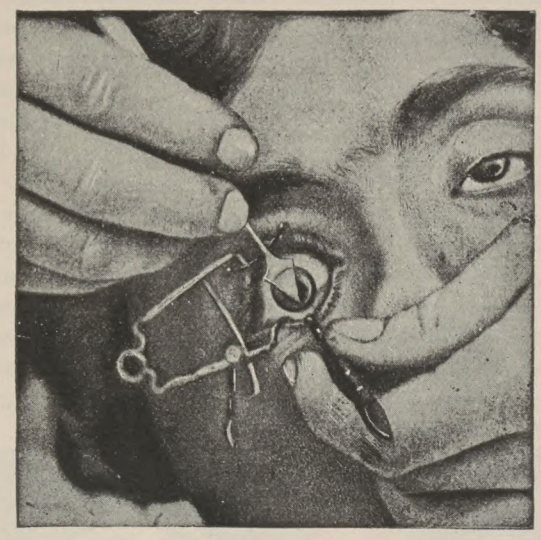

FIG. 163.—Iridectomy Upward: Incision.

forceps opposite the point where the incision is to be made, and close to the cornea. The operator will himself hold the eye, and

FIG. 164.—Iridectomy: Excision of Iris.

with the other hand make the incision. He then has entire control, and his hands act consensually. Watch the point of the knife, and

Digitized by Illinois College of Optometry

go forward steadily to the depth required (see Fig. 163). Withdraw with care, and avoid pressing on the wound, that aqueous may leak as little as possible. Pass the fixation-forceps to the assistant by dropping it down to him, and he must avoid all pulling on the eye, remembering that it is to be rotated, not dragged. His hand must be light, and he must see that he does not make the wound gape. If the iris has prolapsed, the iris-forceps need not be thrust within the eye, but will gently draw it out to the required extent. If it should not present in the wound, insert the forceps with blades closed, and when the margin of the pupil is reached let them spread to the full, and with a little backward pressure close the blades and draw forth the iris. The traction must not be too sudden, if there are adhesions. For a small iridectomy one clip of the scissors, held parallel to the wound, suffices, pressing firmly against the cornea (see Fig. 164). For a large incision two cuts are better, the points of the scissors being used, and the forceps drawing upon the

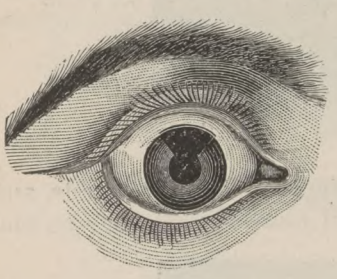

FIG. 165.—Iridectomy completed.

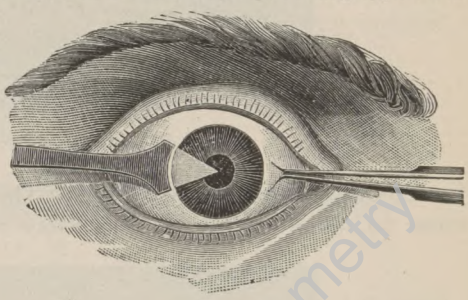

FIG. 166.

iris as it is cut. Hemorrhage is now apt to occur. Its escape from the wound is favored by keeping up slight pressure with fixation-forceps, and at the same time gently pressing on the posterior lip of the wound with a curette or spatula. If it do not fully flow out, a bit of muslin folded to a corner rubbed along the wound, may accomplish it. Irrigation with a small bulb syringe, using sol. acid. boric. or sol. corrosive sublimate, 1 to 5,000, will clear out clots. The greatest pains must be taken for the complete return of the iris to its normal position, if not adherent. To leave a little blood in the chamber matters nothing, but there must be no approximation of the pillars of the coloboma toward the wound. This rule is imperious. If needful, a spatula may be cautiously inserted. Loosen the fixation-forceps, shut together the speculum and slip it out gently, lay upon the eye the pad of cotton, holding it firmly. After a few moments open the lids and carefully remove clots. Then cover both eyes with a bandage and put the patient to bed. Fig. 165 shows how the coloboma should appear after an iridectomy upward. The angles of the pupil are returned to their proper place,

Digitized by Illinois College of Optometry

and the pupil has the correct inverted "key-hole" shape. The amount of iris withdrawn and excised of course limits the size of the pupil. Fig. 166 shows the introduction of a straight knife for an iridectomy outward.

Iridotomy, or, as sometimes called, *iritomy*, is required chiefly in cases of absence of the lens, when the pupil is closed and the iris is adherent to a false membrane or to the lens-capsule. It is usually a sequence to an operation for cataract. It may be done by a knife or needle, with a single incision, or by Wecker's forceps-scissors.

Iridotomy after cataract extractions may be done by a very sharp and narrow Graefe's knife, by pushing it through the cornea a little inside the limbus and through the iris at a point as far distant as can be reached. By sawing movements, during which the back of the blade presses firmly against the corneal puncture, an opening is made in the iris or capsule with little loss of aqueous.

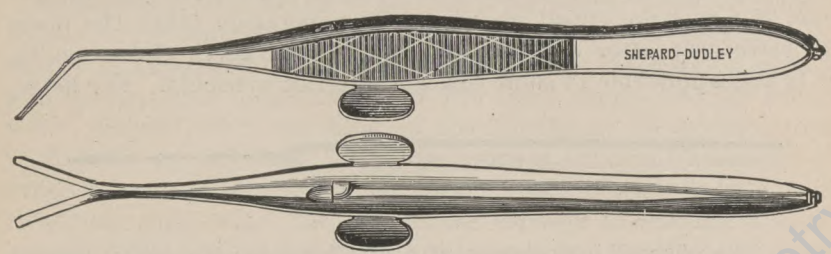

FIG. 167.

The blade is pushed in and out two or three times until a proper opening is secured (Loring).

There are knives of several forms, straight and bent, narrow and wide, which by simply thrusting them through the cornea and iris make the needed opening (see Figs. 168, 169, 170). The incision should be made at right angles with the direction of greatest tension of the iris. A knife is thrust through the cornea a little inside of the limbus, and through the iris, and possible inflammatory membranes, and the cut made as large as possible by a to-and-fro movement, the corneal wound being the fixed point. A double-edged blade is usually to be preferred (see Fig. 170).

When larger openings are required, or there is not tension enough in the tissues to make a proper opening, the method by Wecker's scissors (see Fig. 167) is amply adequate. It has been in my hands very satisfactory. The patient is anæsthetized to the full degree, an incision four to five millimetres long is made in the cornea near the limbus by an iris-knife, or a stop-knife (see page 455) can be used which shall give the exact length. Push the blade forward to its shoulder, then withdraw about half-way to let aqueous ooze out, and bring up the iris; then push the point again

Digitized by the Internet Archive of Optometry

forward to pierce the iris and membrane. This manœuvre brings the wound in the cornea and that in the iris at a little distance from each other, although parallel. Next carry in the scissors flatwise with blades closed, slip one blade through the iris opening, and canting the instrument a little, let the other blade come in front of

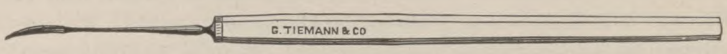

FIG. 168.

the iris, thrust down the blades as far as the cut is to go, shut them and withdraw. The cutting being done across the line of traction of the tissues, a good and clear pupil results. But if the tissues be loose and not retractile, two cuts in the shape of an ∧ must be made, and the pupil will become arrow-headed in form, thus, ∧, with certain variations. Loss of vitreous is not uncommon, but does not entail mischief. This operation takes the place of iridectomy after cataract operations, and gives clean results. It is also applicable to some cases of anterior synechia. For divid-

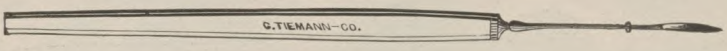

FIG. 169.

ing a limb of pupil in prolapsed iris, and for some traumatic lesions in which a dense band traverses the anterior chamber, it is invaluable.

Irido-dialysis, or *iridorhexis,* is not often done. It means tearing away the periphery of the iris when only the extreme margin of the cornea is available. For most of such cases a peripheral iridectomy by Graefe's knife is better, especially if the cornea be opaque. Desmarres did it for adhesion of the whole surface of the iris to the lens, where iridectomy often fails. A sharp hook is employed. It happens not infrequently by a blow on the eye.

FIG. 170.

Iridavulsion denotes total removal of the iris, by tearing it from its periphery. It is done for certain special cases, and I have found it have a remarkable effect in two cases of hydrophthalmus. The whole iris may be drawn out with a hook or by forceps, or by both in succession. If forceps are used, they must have long, straight, and slender blades to reach across an enlarged anterior chamber, because the iris must be seized at the spot diametrically opposite to the wound of entrance. Of course care must be taken

Digitized by Illinois College of Optometry

not to wound the lens, and the operation is done, not for restoring sight, but to improve the health of the eye by opening free communication between the anterior and posterior chambers, and by unclosing the lymph-channels and vessels at the margin of the anterior chamber.

Corelysis.—The separation of pupillary adhesions is done by Streatfield's hook or by a fine pair of toothless forceps. By either method the adhesions are liable to be re-established and the lens injured; by the latter method less often. Consequently, and because the operation has not been fully approved by experience, it need not be described in detail. Streatfield's hook is to be slipped underneath the pupillary edge, close to an adhesion. By the forceps, risk of rupture of the capsule is avoided, and one simply needs a broad needle or narrow lance for an incision in the cornea near the adhesion, to permit entrance of the instrument.

Iridodesis, as a means of making a peripheral pupil for conical cornea, or for central opacity of the lens or cornea, has been already said to be objectionable, because it has in some cases led to cyclitis and sympathetic ophthalmia. It has been superseded by iridectomy, coupled with tattooing of the cornea at its middle, when needed for opacity; and for conical cornea spherical, cylindric, or other lenses, and Graefe's or Bowman's operation are to be substituted (see page 422). The proceeding consists in making a small wound at the limbus, through it to pass a fine forceps and catch the iris at its middle, to draw this into the wound, to inclose it in a loop of fine silk previously laid around the wound and leave it there to grow fast. The pupil is displaced, and may be made quite small. On behalf of Mr. Critchett, who devised the proceeding, it may be said that he punctured the cornea in its transparent part, while others have gone through the sclera, and he seized the iris in its breadth, not by the pupillary edge as others have done and he did not meet with disastrous after-effects.

Digitized by Illinois College of Optometry

CHAPTER IX.

THE CILIARY BODY, CORPUS CILIARE.

BETWEEN the iris and the anterior edge (*ora serrata*) of the retina lies the ciliary body, a belt which is from five to seven millimetres in breadth, narrower on the nasal than on the temporal side. Firmly adherent near the sclero-corneal junction, it has behind but a loose connection with the sclera. In Fig. 2 its structure and relations are seen, and while it is the bond of union between most of the membranes of the eye and is the source from which the lens and vitreous derive much of their nourishment, it is composed of two portions which have distinct functions. One of these is the vascular and pigmented part, and the other is the muscular part known as the ciliary muscle. The latter lies next the sclera, while the former is mostly in contact with the vitreous. Its peculiar arrangement is shown in Fig. 3, p. 5, where are seen its ridges, which are blood-vessels convoluted and massed together. There are between seventy and eighty of them. They come with a gentle slope from behind, and in front are thrown out into projecting tips called the ciliary processes. The surface of the folds or ridges is corrugated, and is both penetrated and overlaid densely with pigment (*pars plicata*). Behind the ridges or processes is a narrow flattened part which is smooth (*pars non plicata*) and passes into the choroid. The tips of the ciliary processes are slightly in advance of the rim of the crystalline. They do not touch it, and from their posterior surface passes a transparent structure called suspensory ligament of the lens or zonula of Zinn (see Fig. 1, p. 3). This is composed of numerous minute fibres crossing at acute angles, and derived from the hyaline layer on the surface of the ciliary body, and may be considered a prolongation of the hyaline lamella of the retina. On the ciliary body it is arranged in a peculiar net-like form and covered by pigmented cells. The fibres which compose the suspensory ligament have many cells scattered among them, and as they pass to the lens border they separate, leaving a small triangular interval, called the canal of Petit. This space can be inflated with air and sometimes blood is extravasated into it. Through this structure transfusion easily goes forward from the vitreous to the aqueous humor, the lymph escaping by

Digitized by the Internet Archive

the canal of Schlemm. The tips of the ciliary processes project into the posterior chamber and do not touch the lens. They are not erectile, but necessarily they enlarge or shrink with variations of blood pressure.

The *ciliary muscle* is composed of unstriped fibres which take various directions in different parts of the structure. The most exterior

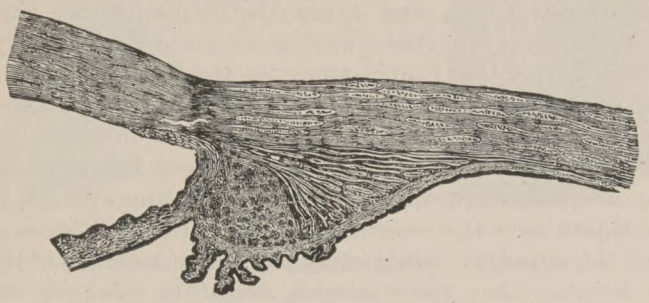

FIG. 171.

(Fig. 171) are meridional, beneath them the fibres radiate in oblique lines, below these and more forward, are bundles which make a kind of sphincter running in a transverse direction, the fibres of Müller. The meridional and radiating fibres compose the tensor choroideæ, or muscle of Bowman, or Brücke. The whole makes a triangular mass whose origin is at and near the canal of Schlemm and the root of the iris, and whose insertion, so far as concerns the tensor choroideæ, is on the choroid about the region of the equator. Some fibres have been said to go as far as the entrance of the optic nerve. There are great variations in the form and development of

FIG. 172.

the muscle. Fig. 171 shows its character in hypermetropic eyes, while Fig. 172 is characteristic of myopia. In the former the circular fibres predominate; in the latter the meridional. Its appearance is grayish white, and on this account it was formerly called the ciliary ligament. It is the active agent of accommodation.

The vessels which supply the ciliary body are the long and short

Digitized by Illinois College of Optometry

posterior ciliary and also the anterior ciliary. The nerves are from the long ciliary, which, after taking a long route between the choroid and sclera, enter into an intimate mesh-work in which are found many multipolar ganglion cells, and we, therefore, have here a local nerve centre, or ganglion. From this plexus fine fibres proceed to the iris, to the ciliary muscle, and to the cornea. They include sensitive, motor, and sympathetic filaments. The short ciliary nerves come from the ciliary ganglion and are mainly motor and preside over the contractions of the ciliary body and iris. The long ciliary come directly from the ophthalmic division of the fifth and are chiefly sensory. The ganglion presides over the function of accommodation. It also controls the pupillary constricting fibres and reflexes of the corresponding eye. It presides to some extent over the sensibility of the cornea. It does not preside over the pupillary constricting fibres and reflexes of the opposite eye, because they come directly from the brain by the long ciliary nerves. (See *Ophth. Review*, July, 1891, p. 206, Querenghi.)

The function of the vascular and pigmented part of the ciliary body has within late years been studied with considerable success. Collins[1] gives a valuable description of his examinations after bleaching the tissues, and the following paragraph summarizes his results (l. c., p. 62): "There are situated in the region which experimental evidence has proved to be the part from which the aqueous humor and nutrient fluid of the vitreous are secreted, numerous little tubular processes of epithelial cells which can be nothing else than glands concerned in their elaboration; that the nature of these processes has been hidden by their pigment and is only evident in bleached sections. That these glands are, like secreting glands elsewhere, subject to attacks of catarrhal inflammation which gives rise to the group of symptoms generally included under the term serous iritis. That as the result of chronic inflammation there may be considerable overgrowth of their tissue, which overgrowth preserves a glandular type, and that they may be the seat of tumors, either adenoma or glandular sarcoma." See also Nicati,[2] and various quotations in Collins' article.

A forcible confirmation of the above views of Lanford is seen in the illustrations from Alt[3] (see Figs. below) exhibiting plastic cyclitis and an extraordinary enlargement of the tubular processes.

Cyclitis.

While describing inflammation of the ciliary body it must be borne in mind that cyclitis is not to be looked upon as an isolated

[1] Trans. Ophth. Soc. United King., vol. xi., 55, 1891.
[2] Archives d'Ophthalmologie, vols. x. and xi.
[3] "Lectures on the Human Eye," p. 107, Fig. 52.

Digitized by Illinois College of Optometry

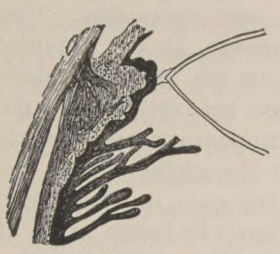

FIG. 173.

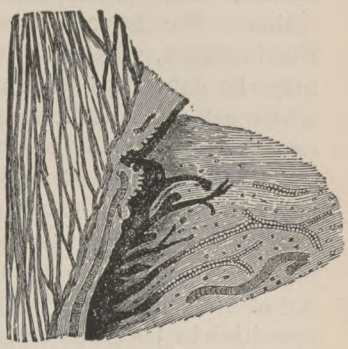

FIG. 174.

FIG. 173.—Plastic Cyclitis.—Tubular excrescences of the pigmented layer of the ciliary body.

FIG. 174.—Plastic Cyclitis.—The same tubular excrescences.

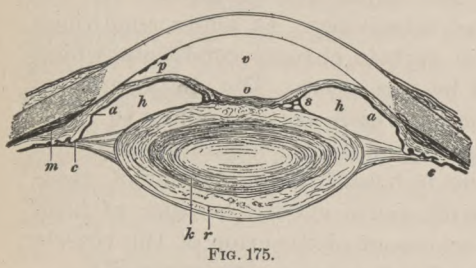

FIG. 175.

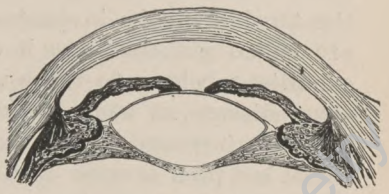

FIG. 176.

FIG. 175.—Irido-Cyclitis.—*Seclusion* and *occlusion* of the pupil. Pupil occupied by false membrane, *o*; edge of pupil totally adherent to lens, *s* (*synechia totalis*); periphery of iris adherent to cornea, *a*; posterior chamber distended, *h*; anterior chamber reduced in size, *v*; proliferation of corneal endothelium, *p* (deposits on membrane of Descemet). The ciliary muscle *m* and the ciliary processes *c*, flattened, atrophied, and adherent; nucleus of lens, *k*, unchanged; its cortex, *r*, liquefied. Fuchs.

FIG. 176.—Sero-Fibrinous Cyclitis.—Amorphous fibrine containing numerous round cells lies upon the posterior lens capsule.

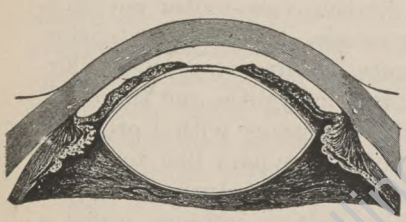

FIG. 177.

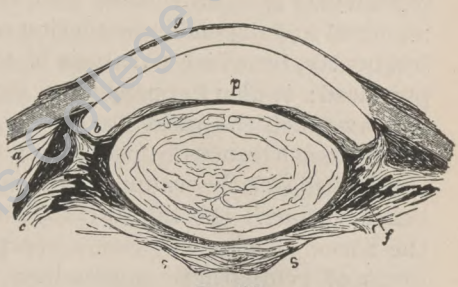

FIG. 178.

FIG. 177.—Plastic Cyclitis.—Cyclitic membrane behind lens. Posterior chamber obliterated. Lens and iris pressed forward.

FIG. 178.—Irido-Cyclitis.—Adhesion of the whole iris to the lens, retraction of its periphery, *r*; occlusion of the pupil by false membrane, *p*; anterior chamber distended and deepened; posterior chamber abolished. Periphery of iris adherent to ciliary processes. Pigment of ciliary processes proliferated. *f* (compare Fig. 174). exudative membrane on posterior surface of lens, *s s*; lens swollen and opaque, soft cataract. Contraction of exudation, *s s*, has dragged inward the ciliary body and opened spaces in the supra-choroidea, *a*. Fuchs.

Digitized by Illinois College of Optometry

disease, because contiguous structures are simultaneously involved, viz., the cornea, iris, choroid, vitreous, lens, and even retina. We have different degrees and phases of combination. For instance, what was mentioned on page 407 as "serous iritis" may be catarrhal (serous) cyclitis (Collins) or uveitis anterior when all the pigmented membranes are concerned. Usually, except in cases of wound, cyclitis appears as an extension of iritis or choroiditis. Seldom, so far as we can tell, does the process originate here. We cannot see the structure, and our diagnosis rests on the hyperæmia, the appearance of the iris and of the aqueous humor, on the tension of the globe, on the sensibility of the ciliary region to pressure, on the pain, on the presence of opacities in the vitreous. The phases may be acute and chronic. We also have types which are serous, plastic, and purulent. The causes are constitutional and local. The former the same as for iritis, the latter, very frequently, are traumatic; both from accidents and from operations. The important symptoms are the state of tension and the state of sensibility. In acute conditions the tension will be in excess; in certain chronic conditions which are called glaucomatous it will be the same. The glaucomatous conditions belong to those varieties which are secondary to some other disease, as wounds, tumors, sympathetic inflammations, etc. It is not intended here to argue in behalf of any theory of glaucoma, but plus tension occurs with acute cyclitis because of high vascularity and effusion and because of obstruction of the vessels about the canal of Schlemm and of the anterior ciliary vessels.

Diminished tension (*hypotony*) occurs because of atrophy of the vessels and reduced nutrition of the vitreous, and by aggravation and extension of the lesion, the globe may shrink to a state of atrophy (phthisis). There is a condition called essential phthisis bulbi which goes on without pain or visible hyperæmia (ophthalmomalacia) and depends upon lesion of the cervical sympathetic most frequently, by which paralysis of the dilating vaso-motor nerves is produced; it also happens from other causes. Diminished tension follows much the most frequently, acute or chronic cyclitis. Exquisite sensitiveness to pressure is the rule in cyclitis, and there are chronic, especially traumatic cases, where pressure with a probe or pencil through the lid starts a shock of severe pain like touching the nerve of a tooth. Some exceptions occur, as during the progress of sympathetic ophthalmia, where with a softened globe a deep dimple may be made without causing pain.

With *acute serous cyclitis*, we have pericorneal injection, hazy aqueous, minute deposits on the posterior surface of the cornea, discolored iris, pupil small, periphery of iris retracted, sometimes showing a furrow, the anterior chamber deep. There may be

pupillary adhesions. I have noticed with a deep anterior chamber that, if while the eye looks at a gas-light a condensing lens be held in front of it, an observer viewing the cornea in profile from the temporal side and a little from behind, will catch rays of light reflected from the posterior surface of the cornea as in conical cornea. The gleam is fainter but similar to that seen in the pupil by ordinary ophthalmoscopic illumination. Vision is dull and opacities exist in the vitreous which may or may not be visible. Tension will be supra-normal and pain considerable.

With *plastic cyclitis,* we have in addition a more turbid aqueous, and a yellow exudation which may again disappear or may produce hypopyum—the pupil and perhaps the whole iris will be adherent. The vessels of the iris will be enlarged. Cases occur where a mass of plastic exudation (a gumma) forms in the ciliary body and pushes its way in a tumor through the sclera. There may or may not be a similar production in the iris. The choroid will be involved. A bluish prominence, *staphyloma sclerœ,* will be left permanently, or the globe may atrophy. A less abundant but more diffused plastic effusion leads sometimes to a girdle of ciliary staphylomata, to which reference has been made (see p. 427).

Purulent cyclitis will, in many respects, resemble phases of plastic cyclitis, but, as a rule, it passes into more or less general suppuration of the eye. The aqueous, and especially the vitreous, will be turbid. In subacute cases the globe may be soft, but as a rule we have increased tension and fulminating panophthalmitis. In all these types of acute inflammation there will be hyperæmia, pain, lachrymation, and in most instances vision will be lost.

Chronic cyclitis causes softening and reduction of the eye, often without altering the clearness of the cornea, although diminishing its size; the iris is discolored and atrophied; it lies glued to the lens with a deep furrow at its periphery, due to adhesions to the ciliary processes; the lens may or may not be opaque or it may become calcareous; behind it, is often a dense layer of false membrane; the vitreous is shrunken and opaque; the retina detached and disorganized; the choroid likewise disorganized. Regressive changes into fibrous tissue, with chalky concretions, and in the false membrane sometimes osteoid formations, are often seen. The literature of these lesions is copious because such eyes are often enucleated.

Fig. 179 shows an eye removed while a large mass of acute exudation was fresh and the retina also became detached. Fig. 180 shows an old case of cyclitis with disorganization of the eye, which was phthisical and cuboidal. Fig. 181 is similar, but the globe enlarged. Retina in both the last figures reduced to a cord.

Cases like those figured, sometimes closely simulate intraocular tumors, such as glioma. They will be mentioned again.

Prognosis of cyclitis is very grave. It may not only involve loss of sight, but loss of the globe, and in some instances the other

Fig. 179.

Fig. 180.

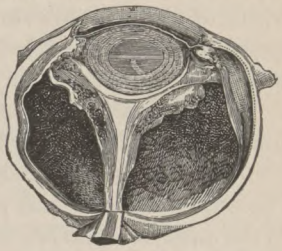

Fig. 181.

eye is put in peril. This point will be considered under the head of sympathetic ophthalmia. In mild cases early treatment will lead to recovery. Softening of the globe during the progress of an inflammation, especially after a cataract operation, is always an ominous sign. (For pathology see Alt, "Lectures on the Human Eye," p. 106, 1880.)

Treatment.—The indications are much the same as for iritis. We employ leeches, hot fomentations, atropia, anodynes hypodermically and otherwise; with increased tension paracentesis will be useful. A case of subacute cyclitis or rather of general uveitis may linger so long as to make enucleation desirable to terminate the process. On the other hand, sometimes a protracted irido-cyclitis will permit a broad iridectomy which may be the salvation of the eye. This will be possible under exceptional conditions, and only during the chronic stage, and must be aided by good nursing. For shrunken globes in which repeated outbreaks of inflammation occur, enucleation must be practised. Many irritable stumps upon which a glass eye cannot be borne must be similarly dealt with. It is often, however, noticed that a stump may be tender under firm pressure and yet tolerate the presence of a glass eye. No operation is then called for. Constitutional indications must be attended to, especially syphilis.

Traumatic cyclitis, especially when complicated by the presence of foreign bodies, will be discussed in another place.

It may be well just here to consider briefly a group of cases characterized by reduced tension of the globe: *hypotony,* a condition incidentally mentioned in speaking of cyclitis. Some of them are as folllows:

Hypotony: Ophthalmomalacia, Etc.

We have cases of microphthalmus in which, though the eye is small, it is not soft. These cases are not now in question.

Instances occur in which reduced tension appears apart from

Digitized by Illinois College of Optometry

acute inflammations such as cyclitis, or as diffused keratitis. For example, a blow on the eye which will sometimes cause marked myosis, may be accompanied by severe pain and hypotony. The eye may soften under prolonged and firm bandaging. The same has been seen after strabismus operation; and it is the common condition with detachment of the retina. A reflex irritation upon the vessels must be assumed in these cases.

There are also remote causes acting for the most part through the nervous system, especially on the eye belonging to the side affected by hemiplegia, or progressive muscular atrophy, etc. Section of the cord between the occiput and atlas causes this effect, which has also been seen in a case of luxation of the upper cervical vertebra (Michel). Acute myelitis of the upper part of the cord may have the same effect.

Section or paresis of the sympathetic in the neck will produce hypotony. Horner[1] called attention to a group of symptoms consisting of imperfect ptosis, myosis, reduction of ocular tension, capillary redness of one side of the face, and sometimes one-sided perspiration, all of which are explained by lesion of the cervical sympathetic on the corresponding side. The following case, I think, is of this type:

Miss T., æt. 26, came to me in January, 1864, saying that two months previously she had noticed a slight droop in both upper lids. There was no diplopia, no headache, no tenderness about orbits or brows, no signs of exophthalmic goitre. No satisfactory diagnosis was made, and the trouble passed away. One year later had pain in eyes and went to another oculist, who employed atropine and gave + 1 D; but this gentleman thought the case obscure. In 1886 there was pain in the orbits and partial ptosis. Has a skin eruption, and is being treated for gouty diathesis. There seemed to be insufficiency of externi, and abductive prisms were tried, but with no advantage. She was seen three times within five months at this period. In January, 1891, came to me on behalf of another person, and then the following symptoms were elicited which seem to decide the nature of the case: She has no pain and very little trouble with her eyes. Can use them at will. When very tired the upper lids droop, especially of the right eye. Frequently has marked flushing of the face and has had for years. Pupils small, and both to light and to convergence become extremely small. Sometimes gets very nervous and must even retire from the table. Is then unable to control herself, and "can't be civil to anybody." Feels perfectly well, exercises much. Has supra-orbital tenderness. No swelling in the neck. Tension not tested.

See description of enophthalmus and ptosis, etc., p. 748.

[1] Klin. Monatsbl. für Augenk., vol. vii., p. 193, 1869, "Ueber eine Form vom Ptosis," Nicati, Lausanne, 1873. La Paralysie du nerf sympathique cervical. See also "Zur Pathologie des Hals Sympatheticus," Berliner Klin. Wochenschrift, 1884, Nos. 15, 16, 17, 18. Bärwinkel, Deutches Archiv. f. Klin. Med., Bd. xiv., p. 445.

Irritation of the fifth nerve will cause increase of tension and its paralysis cause reduced tension of the eye. We must assume that this is only an indirect route to the vaso-motor centre which controls the tension of the vessels. In the cases referred to, vision is not impaired and sometimes there is severe neuralgic pain, in other cases there is no pain. Reduced tension may be intermittent or permanent. Cases of the latter kind were described by Graefe as *essential phthisis bulbi*, or ophthalmomalacia.

Treatment for these various conditions must be determined by the cause, when it can be discovered. For pain, hypodermic injection of morphia in the corresponding temple may suffice. In the cases described by Horner, there is often a glandular tumor pressing on the cervical sympathetic, or there may be degeneration of its ganglia. For spontaneous ophthalmomalacia of Graefe treatment must be founded on general indications. We know nothing of the cause, and while the condition may appear and again disappear, the prognosis is not necessarily bad.

Morbid growths occur in the ciliary body similar to those found in the rest of the uvea. Their nature will often be difficult to determine prior to enucleation and their presence is of itself sometimes not easily discovered. A patch of local hyperæmia, a slight deformity in contour, perhaps a dark spot on the sclera; a little bulging of the iris or enlargement of its vessels; it may be more pigmented or decolorized at a certain spot; the pupil may not be circular and yet free from adhesions, the lens either clear or opaque and is sometimes luxated—such are signs of a small ciliary tumor. An instance of sarcoma is represented in Fig. 1., p. 295, Sixteenth Internat. Ophth. Congress, Heidelberg, 1888. Dr. Lange. Epithelial growths deeply pigmented are found, and their true nature is only ascertained after bleaching them (Collins, Trans. Ophth. Soc. Unit. King., XI., 61, 1891). Alt gives a similar one (l. c.).

Digitized by Illinois College of Optometry

CHAPTER X.

THE CRYSTALLINE LENS.

Anatomy.—The crystalline lens is a biconvex body whose equatorial diameter is from 8.1 mm. to 10.3 mm. (Merkel), and its axial thickness is from 3.6 mm. to 4.7 mm. Its edge is not in contact with the ciliary processes, while its front surface touches the iris over a considerable area. It is inclosed in a capsule, of which the anterior half has an endothelial lining on its posterior surface, while the posterior half is thinner, and has no cells. It is very elastic, and if divided the cut gapes. The lens is made up of long fibres or cells whose cross section forms a flattened hexagon with serrated edges. They bend upon themselves at its margin, and their extremities terminate on certain planes arranged in radii in a peculiar manner. The result of the arrangement is to divide the mass into sectors, whose planes, seen from the front, have a star-like form, and, seen from behind, the limbs of the similar star are intermediate in position with those in front. The lens is also divisible into concentric lamellæ. The fibres are in reality very elongated cells. Their nuclei are arranged in irregular rows near the lens margin. The nuclei are most conspicuous in young and especially in embryonic lenses.

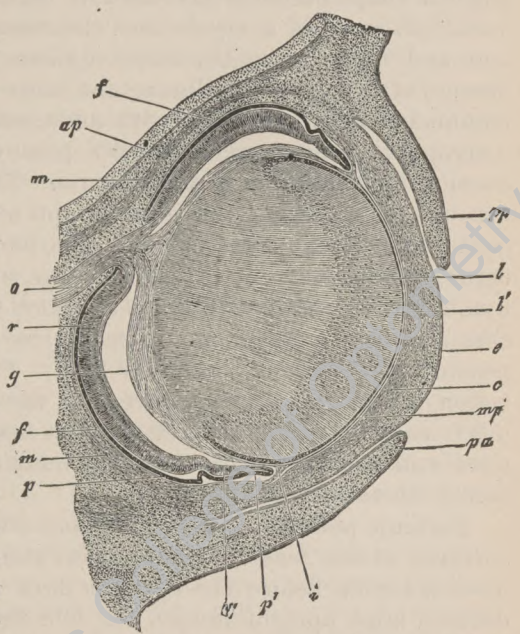

FIG. 182.—*pp*, lower lid; *pa*, upper lid; *m*, mesoderm not yet differentiated; *c*, cornea; *mp*, *membrana pupillaris*; *i*, place of iris; *chc*, chorio-capillaris; *g*, vitreous; *p*, pigment layer or proximal lamella of the secondary eye vesicle; *r*, its distal lamella, composing the retina.

Digitized by Illinois College of Optometry

They form an arc to which Becker especially has called attention. The lens at a certain stage of development occupies much of the space within the eye and its nuclei and fibres are readily seen. The figure from Kölliker (182) displays the eye of the calf at the third month. See "Development of the Crystalline Lens" by Richmond Lennox, *Brooklyn Medical Journal,* June, 1889, with plates. Being inclosed in a capsule, and new fibres being laid down only at the edge, the interior and older fibres become compacted by pressure into a firmer mass which is called the nucleus. In early life the lens is small, soft, and globose. Priestley Smith has shown that it continues to grow to the end of life, that it increases both in weight and volume. For example, from 20 years to 70 years, the weight increases from 174 mgr. to 245 mgr.; the volume from 163 cub. mm. to 227 cub. mm., and the diameter from 8.67 mm. to 9.64 mm. By accretion upon its edge, and increase of density the shape becomes flattened, its transparency diminishes. The youthful lens has a crystalline clearness; in middle life a smoky tint and later, an amber tinge appears. With loss of pliability, change of shape becomes more and more difficult, and range of accommodation is shortened with advancing years; in time hypermetropia becomes associated with presbyopia. A reduction in visual acuity also occurs. These changes account for the smoky hue of the pupil in elderly persons under focal illumination. The lens fits into a depression in the front of the vitreous, known as the hyaline fossa, *fossa patellaris,* to which the posterior capsule closely adheres, and is supported by the suspensory ligament or zonula of Zinn. The space between the front and back layers of the suspensory ligament, formerly called the canal of Petit, is now asserted not to deserve the name canal, because intersected by numerous very fine and interlacing fibres (Gerlach).

FIG. 183.

Purkinje pointed out the reflections which may be seen from the surfaces of the lens, if with a moderately dilated pupil we slowly move a candle before the eye in a dark room. The front gives a diffused faint upright image, viz., *b* in Fig. 183, and from its posterior surface, which acts as a concave mirror, we get a small, sharp, and relatively brighter image *c,* which is inverted. The image from the cornea is the brightest, *a.* By the ophthalmoscopic mirror the same images can be seen if we look from the distance of about a foot. They may also be seen with + 20 D near at hand, if only one-half the pupil be illuminated. Their detection is sometimes important when attempting to decide upon the presence of the lens. Their use in diagnosticating cataract has been supplanted by the ophthalmoscope. They enabled Helmholtz and Donders to

Digitized by the Boston Medical Library Ophthalmometry

measure the exact curvature of the surfaces of the lens and its changes during accommodation. The corneal reflex with parallel rays is at the distance from its front surface of one-half its radius, viz., about 3.9 mm., which is about on the anterior surface of the crystalline, *i.e.*, 0.3 mm. behind it, and almost on the plane of the reflex from the back of the lens (see *a* and *c*, Fig. 183). This reflex is always seen in the direction of the radius of the cornea, whose centre of curvature is just behind the lens, viz., 0.6 mm. If the observer change his point of view the image moves across the pupil, but always remains projected to the centre of curvature of the cornea. Hence it seems to lie at that point, but so long as it remains within the pupillary area it will be noticed to move away from the apex of the cornea as the eye moves. An opacity on the posterior pole of the lens will consequently always be covered by the corneal reflex, no matter how the globe moves, and will seem stationary when its relation to the reflex is regarded. An opacity in front of the corneal axial centre will move as the observer changes his line of sight, going in a sense the reverse of his movement, and in the same sense with the movement of the examined eye. The centre of motion of the globe lies 13.5 mm. behind the corneal apex and 5.7 mm. behind the centre of its curve. An object situated at the centre of rotation cannot move with the rotation of the globe, but in estimating its position we cannot make any use of the corneal reflex.

Another point brought out by Dimmer is that the darkness of the border of crystalline seen by transmitted light depends not upon total reflection of light, but because the extreme angle under which the rays are deviated prevents them from entering the hole of our mirror. When the lens is luxated into the anterior chamber its border becomes a luminous ring, because now the light which illuminates from neighboring parts undergoes total reflection. If luxated so as to present its edge to the observer, this becomes luminous. If luxated laterally, *i.e.*, in a frontal plane, the edge remains dark. Dimmer, Graefe's *Archiv*, XXXVIII., iv., 19, 1892.

In old age the lens sometimes becomes marked by short linear marginal opacities, which are known by the name of *arcus senilis lentis*. They are only visible with dilated pupil.

As a very rare congenital anomaly the edge of the lens has the form as if it had been cut off (*coloboma lentis*). Usually the defect is below. I have once seen it on the outer side. (See Collins' Royal Lond. Ophth. Hosp. Reports, XIII., I., p. 87, 1890, and Heil, Trans. Fifth Internat. Ophth. Cong., p. 16, 1876.

Dislocation of the Lens.

The lens is liable to dislocation both from violence and from disease, and as a congenital condition. It may be tilted into an oblique

Digitized by the Internet Archive in 2007 with funding from Microsoft Corporation

position, and may swing back and forth, as on a hinge—the zonula being only part torn—or it can be pushed slightly out of place in a vertical plane, or in any direction. It may fall backward entirely out of the pupil into the vitreous, and it may be lodged in the anterior chamber. It may lie obliquely across the pupil as in Fig. 184. Sometimes, in old choroiditis, being very small and the capsule generally much thickened, it passes forward and backward through the pupil. In all these displacements the lens may be either transparent or opaque and perhaps calcareous. By severe violence it may be pushed partially or wholly through a rupture in the sclera, and either be entirely extruded from the globe or lodged under the conjunctiva. Displacement is most frequently caused by disease. The vitreous humor has become diffluent. The suspensory ligament has become stretched and atrophied, and gives way in whole or in part. Extreme myopia is a condition which favors this occurrence, and it may present all the varieties of luxation. If the lens is out of position so that a part of the pupil is uncovered, a person has monocular diplopia, or at least two different qualities of refraction in the same eye. A myope in this condition will sometimes seek a dim light, that the expanded pupil may give him the benefit of the part not occupied by the lens. Sometimes a patient uses both pupillary regions.

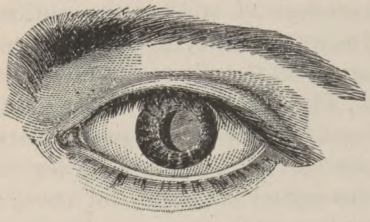

Fig. 184.

The lens of each eye may be situated out of the visual axis as a congenital condition (*ectopia lentis*). The displacement may carry the lens border inside the margin of the pupil. Generally it is very small. It may be clear or partially opaque (*laminated cataract*). This form of luxation usually affects both eyes. It can occur in several members of a family. The direction of displacement is often curiously symmetrical, as upward and outward or directly outward. Nystagmus and decided amblyopia often coexist. The eye may be truly myopic in addition to apparent myopia due to dulness of sight. There may be other defects of development such as coloboma. See Collins, loc. cit.; Bowman, Ophth. Hosp. Reports, V., p. 1, 1886. Morton, ditto, IX., p. 435, 1879. Graefe's *Archiv*, XXXI., 4, 53, Schiess-Gemuseus. There is usually marked amblyopia.

Symptoms and Diagnosis.—Displacement of the lens, whether from disease or from violence, produces great hyperopia, unless pre-existing myopia is considerable, and abolishes accommodation. The iris sinks, the anterior chamber becomes deep, the pupil is generally small. Often the iris seems pulled back by some fibres, yet

Digitized by the Internet Archive

adherent to it. When produced by chronic inflammation, as happens perhaps most frequently in myopia, we find disease of the choroid with patches of atrophy, and diffuse opacity of the vitreous, sometimes its entire obscuration by floating bodies. Chronic irido-cyclitis is sometimes the beginning of the process, but more generally it starts from the ciliary body, and slowly advances to the iris. In old cases the vitreous may be dark and no reflex be obtainable from the fundus. If the media are clear, as may happen in traumatic, as well as in other cases, diagnosis of luxation of the lens is sometimes very obvious, and again close attention is required. In a partial luxation, if the rim cross the pupil, it will be recognized by the dark border which it always presents, because of the total reflection of light. Again, if part of the pupil be unoccupied by the lens, the ophthalmoscope will give a double view of the fundus; one may see two images of the optic nerve—one image seen through the lens and the other beyond the lens. This, of course, is only possible by the indirect method. The difference in refraction is at once recognized, according to the part of the pupil which is utilized. To determine the entire absence of the lens we look for the images reflected from it, this being what is called the catoptric test. Purkinje observed the images, and Sanson utilized them for diagnosis (see figure, page 434). A candle is held to one side of the eye, in a dark room, and moved about. The brightest image is from the cornea, and upright; the smallest is from the posterior surface of the lens, and inverted. If all or two images are visible, the lens is *in situ*. The ophthalmoscope will give us the same information.

The lens may by a slight blow be thrown more or less completely out of position and no other injury be inflicted. On the other hand the structure of the globe may, in traumatic cases, be severely damaged; there may be rupture of its outer tunics, of the iris or choroid, with internal hemorrhage and perhaps entire collapse of the globe. Seldom is the lens thrust entirely out of the eye. After extensive ulceration of the cornea, as in purulent conjunctivitis, the lens often spontaneously escapes.

Prognosis.—In *congenital* cases the condition usually remains unaltered, and although defective, vision may not become materially worse. There may be other defects, such as microphthalmus, or cataract partial or complete, the subjects may be albinos; several members of a family may be affected. When the *result of disease*, sight is very bad and may be expected to grow worse. In *traumatic* cases in which there is no other severe injury, the lens seldom will continue transparent for a long period, even though it remains in the hyaline fossa. If luxated into the anterior chamber, severe inflammation of a glaucomatous type

Digitized by University of California Ophthalmology Library

generally follows, but I have witnessed the contrary in a case where it remained for years in this position, became opaque and adherent to the cornea. If lodged in the vitreous, disorganizing changes generally take place which in time destroy sight and may compel enucleation. The amount of concurrent injury has, of course, an important influence, but the statement holds good, even in the case of intentional luxation of the lens into the vitreous, as by the operation of reclination of cataract.

Treatment.—When in the anterior chamber, the lens should be extracted by a peripheral cut. The wound can be made by a very narrow Graefe's knife, and, if insufficient, can be completed by scissors. A small space will remain, through which the knife may pass without piercing the lens; this will be above, if the lens is left to itself; while, if impaled on a needle, it may be lifted up and the cut made below, as is the most desirable. I have in some cases been obliged to transfix it by a needle passed through the sclera to prevent its slipping back through the pupil. The capsule should not be ruptured. There is much liability to loss of vitreous. When luxated under the conjunctiva, removal is very simple.

Partial dislocation should not be meddled with so long as the lens remains clear. The resulting astigmatism may be measurably relieved by a cylindric glass. If the lens becomes opaque its extraction may be practised, and in doing this, it may be removed inclosed in the capsule. It is understood that the capsule does not rupture in dislocation, otherwise the lens would at once opacify. For some illustrations see Trans. Am. Ophth. Soc., 1891, p. 207, Theobald.

For congenital dislocation, *ectopia lentis*, usually nothing more is done than to attempt correction by glasses when this affords any visual improvement. The accompanying amblyopia is often so serious as not only to discourage the use of glasses, but likewise to forbid surgical interference. I have never operated upon these cases nor have I found records of such operations in literature. Should the lens be opaque discission might be justified. Luxation into the vitreous when the result of chronic inflammation is usually attended by liquefaction of the mass, and there may be such degenerative changes as to render restoration of sight hopeless. The alternative will be between extraction of lens and enucleation. If there be much pain the latter may be preferable. If the luxation be recent, and no adhesions tie down the lens, its removal may be worth trying even when acute inflammatory symptoms have been set up, to avoid mutilation, even in cases where no vision is to be counted on. Again in some traumatic cases extraction may be attempted, although a vitreous of normal consistence is an obstacle to the proceeding not presented when it is fluid.

Digitized by Google

If extraction be attempted, the first indication is to bring the lens to or through the pupil. A depending position of the head will sometimes bring it about, and while the patient is in this posture (head hanging over the edge of a high table), a long needle may be carried across the globe behind it to fix it. Another method is to attempt to fish up the lens and use the same needle to hold it by transfixion. A single needle will rarely give success. Better results may be gained by a double needle or bident (Agnew) held by fixation forceps and left *in situ* when the lens is brought to position. Subsequently a section of the cornea is made by a Graefe knife and the lens expelled. Usually vitreous escapes and an iridectomy may be advisable.

A much simpler method of operating (Knapp, Bull [1]) is to first make a corneal wound at the limbus of about one-half the circumference and bring the lens out by pressure of the thumb or a spoon applied at the equator well behind the lens. The globe collapses, but well-directed pressure will bring the lens through the pupil and out of the eye, with no more copious loss of vitreous than by other methods, and possibly without its escape at all. The iris prolapse will be returned by a spatula and the eye lightly bandaged. I have recently practised this method with success, and find it devoid of any more risk than the old way and much less circumstantial. Reaction may or may not be severe.

It is important to remember that serious inflammatory changes may have been set up in the ciliary body and choroid, perhaps also detachment of the retina, and that there is risk of sympathetic trouble in the fellow-eye. This risk may be so great as to negative the propriety of any operation to extract the luxated lens, and point to the necessity for enucleation. One must be governed by such symptoms as tenderness of the globe, the occurrence of inflammatory attacks, of pain, and of signs of discomfort or lesion in the other eye. See chapter on Sympathetic Ophthalmia.

Luxation by injury may be followed by severe glaucomatous symptoms, and the tension may be so great as to press the iris against the cornea. This renders iridectomy, and sclerotomy of the usual type unavailing. Under these conditions I have seen posterior sclerotomy, that is, an incision into the sclera between the insertions of the inferior and external recti muscles, in an oblique direction beginning as far back as the vicinity of the equator, and making a meridional wound about eight millimetres long, effect complete relief of the plus tension; and leave the luxated lens to be subsequently dealt with. See case by Priestley Smith, for which he did enucleation (*Ophth. Review*, Vol. I., p. 273, 1882).

[1] Trans. Am. Ophth. Soc., 1891, p. 398.

Digitized by Google

CHAPTER XI.

CATARACT.

We may have opacity of the lens or of its capsule or of both; *i.e.*, lenticular or capsular cataract. Opacity of the capsule occurs in dots or patches and results from proliferation of its endothelium. It shows a preference for the pupillary space and sometimes the structure is thickened; especially in so-called inflammatory cataract, *i.e.*, when resulting from uveal lesions, do we find the capsule opaque and thickened. In ordinary lenticular cataract the capsule is usually clear.

In anterior polar cataract, caused by perforation of the cornea, the opacity exists in the capsule and in the subjacent lens substance and the same is true in cases of posterior polar cataract. In advanced cases of lenticular cataract, there may be specks on the capsule by cell-proliferation; or, if the lens have undergone great degeneration, its detritus may be precipitated on the capsule. In former days, stress was laid upon the distinction between capsular and lenticular and capsulo-lenticular cataract; but this is a matter of small consequence. Deposits on the capsule give an idea of the stage to which an opaque lens has arrived, and suggest lesions of the deeper tissues of the globe. Capsular, or as it is often called, membranous cataract, will be considered under the head of secondary cataract, it being generally the sequel of removal of the lens.

Pathology.—The lens is not regarded as being the seat of inflammation, and the changes which it undergoes are of the nature of degenerations.

Lenticular cataract is to be classified in a variety of ways, namely; according to the extent to which the lens is invaded, into partial and total; according to its cause, into traumatic and spontaneous; according to its density, into soft and hard and fluid. We also have congenital, juvenile, and senile cataract; we have it unattended by any other disease of the eye, so far as we can discover, viz., simple; and we have it as the result of many internal ocular diseases, viz., complicated cataract. We also have cases in which it depends on constitutional disease.

The pathology of cataract varies with the kind and cause. The simplest is *traumatic*, where the direct violence and the imbibition

Digitized by Harvard College Library

of aqueous humor swells and disintegrates the fibres. In "*inflammatory*" cataract exudation of fibrin and round cells with areas of granular detritus are found; even spots of organized fibro-cellular formation may occur. Calcareous deposit and spicules of bone are seen in the neoplastic tissue. The capsule may be wrinkled and adherent to an iritic membrane. (Embryologically the lens is an epithelial or cuticular structure derived from the epiblast.) The cataract of *diabetes mellitus* is due to the density of the eye fluids, and experiments upon frogs have produced cataract by injecting sugar and salt into the blood which made its way into the aqueous humor. In *soft* cataract there is an excess of fluid, the fibres appear swollen and may be varicose. They show degeneration, containing molecules and globules and are partly destroyed, fatty débris being set free. Some of them have irregular transverse striæ; and there are drops of clear material occasionally with acicular crystals apparently of margaric acid (Pollak). *Hard* cataract takes its name from the sclerosis which occurs in the central mass of the lens, the so-called nucleus, by which the fibres become closely packed together and difficult to isolate; they are irregular in outline and between the nucleus of a senile cataract and that of a senile lens which is not cataractous, there is very little difference in clearness. But the alteration in transparency appears in the cortical layers whose fibres are swollen and granular and disintegrated, and separated by fissures and spaces. Between them are vacuoles and globules of coagulated material. The primary cause of the alteration is the irregular shrinkage of the nucleus. During its incipiency the lens swells by increase of fluid, and after this has subsided, further degeneration may occur in the cortex, reducing it to a molecular semi-fluid substance (Morgagnian cataract). Want of uniformity in the hardening of the nucleus is supposed to cause the alterations in the cortical layers, which become disrupted and degenerate, while the extent to which the process of sclerosis involves the lens, varies greatly in different subjects. It may take in the whole substance, or only a comparatively small central part. In the one case, or in the other, the physical condition and appearance of the lens will be very different. A cataractous lens is smaller as well as harder than the normal lens of the same age (Priestley Smith). Cataract appears at every age. It is congenital, it occurs during youth and middle life, and is most frequent after fifty. Its causes are local and constitutional. Among the first are the traumatic, and senile, and inflammatory; we find it following irido-choroiditis, detachment of the retina, glaucoma and extreme myopia. Constitutional causes are obscure, except diabetes mellitus; injection of naphthalin will cause it in rabbits; atheroma of arteries and albuminuria are not causative.

The rate of progress is extremely variable. Traumatic cataract develops within a few hours or days or weeks. Senile cataract demands months and usually years. In some cases the process of sclerosis goes on ten or twenty years. The posterior polar cataract of myopia is likewise very slow in its advance; sometimes after making little headway for several years, complete opacity of senile cataract comes within a few days. Partial cataracts, viz., the laminated, remain long stationary, perhaps for life. Soft cataracts develop more rapidly than hard. They tend to fluid degeneration and are sometimes partially absorbed. Similar degeneration takes place often in the cortex of senile cataract, which gives it the name of hypermature or Morgagnian cataract. A lens which is totally opaque is called mature or ripe, in contrast to the incipient or unripe.

Practical distinctions are, stationary and progressive; ripe and unripe; soft, hard, and mixed and hypermature; simple and complicated; traumatic and idiopathic; partial (lamellar) and congenital.

Symptoms.—With senile cataract the chief *subjective* symptom is slowly developing dimness of sight, which obscures distant objects and forces the book or work unusually near. Blame is often laid upon the glasses the patient is using. If an effort be made to find better, frequently astigmatism will be detected, which a cylinder will partially, but not wholly, remedy. A true myopia may develop because of the increase in refracting index. This does not commonly exceed −1 or − 1.5 D, but I have seen it as high as −3 D. This is the so-called "second sight" of old people. Sometimes patients complain of phosphenes and of photophobia—they will generally choose to sit with the light behind them. Frequently they find comfort in light smoked or blue glasses. Slight palpebral conjunctivitis is common. The amount to which vision will suffer by a given amount of cataractous opacity can never be predicted. A few streaks will greatly disturb some persons, while there may be remarkable acuity when the lens is full of striæ and an ophthalmoscopic view of the fundus impossible. Opacities near the periphery naturally interfere with sight but little, while the molecular nuclear opacity is very damaging. At the same time a well-defined posterior polar opacity does not greatly impair vision —provided the fundus is normal—because close to the nodal point.

The *objective* symptoms can be very completely studied, thanks to the ophthalmoscope. But apart from its use, we sometimes find the anterior chamber shallow, which implies either swelling of the lens or an increase in tension, perhaps both. A deep anterior chamber means a small lens. The pupil may be small and active, or sluggish both to light and mydriatics. The color of the pupil

Digitized by the Internet Archive in 2010

varies with the quality and stage of the cataract. In most cases of mature cataract the color is gray or dull and on the lens will be seen radiating streaks. If the cortex is not fully opaque and a light be thrown upon the pupil from the side, the shadow of the pupillary edge will be seen upon the deep opacity of the nucleus. There are cases in which to the unaided eye the pupil seems black, while the patient's vision is reduced to fingers at a few feet, and upon focal illumination the light will not penetrate deep into the lens, and the reflex from it is smoky, reddish, mahogany, or like tortoise shell, and in a colored man on whom I did a preliminary iridectomy, it was a deep bottle-green. Extreme cases of this kind have been called black cataracts. Viewed with the ophthalmoscope these lenses permit a certain amount of reflex from the fundus. The cases now referred to are comparatively infrequent. Their peculiarities are due to the gradual and extensive sclerosis of the lens, which reaches almost to, if it does not include its surface layers. It is highly important to recognize them. The usual condition of a mature senile cataract exhibits an opaque cortex which is as stated, gray or dull white, with streaks, and on focal illumination an amber tinge is reflected from the nucleus.

With incipient cataract no change of hue is seen in the pupil, although the dull color of age contrasts strongly with the deep black of youth. Sometimes a streak or several streaks are found pushing inward. A proper examination requires a wide pupil, and a solution of atropia, gr. $\frac{1}{4}$ ad ℥ i., or a 4% solution of cocaine, may be necessary. Focal illumination will often reveal opacities, while the ophthalmoscope will search out the whole lens. The light should be feeble and the view should be taken at the distance of about a foot. Make the light play across the pupil by slight movements of the mirror and have the patient look in all directions so as to bring the periphery of the lens in view. Opacities appear mostly in streaks coming from the edge. It will be remarked that striæ visible from one angle disappear when the direction is changed, or sectors of the lens from one point of view are opaque, and from another are clear. This proves that the opacity depends on irregularity in refraction and answers to the fissures known to occur in the cortical layers, and to the condensation of the substance. We may find a patch of opacity in one place and the rest of the lens clear; or the nucleus may be hazy and the periphery clear; a multitude of specks may be scattered through the lens. A great variety of appearances is possible. To complete the inspection put a short-focus lens, + 12 D or + 15 D, behind the mirror and come close to the eye; nothing in the lens can now escape observation.

The symptoms of idiopathic soft cataract need no special addi-

Digitized by Illinois College of Optometry

tional remarks, except to speak of their tendency to swell, and that the urine should be examined for sugar.

Traumatic cataract exhibits a great variety of conditions according to its cause. According to the degree to which the capsule has been lacerated will be the extent and rapidity of the swelling and the irritation of the eye. A blow or explosion may cause cataract without lesion of the capsule by rupture of the suspensory ligament, or disturbance of the lens structure. Sometimes this appears like a well-formed star on the posterior layers. A penetrating wound and the presence of a foreign body give rise to complications which cannot now be fully described.

There are certain special types of cataract to be mentioned; viz., the anterior polar and posterior polar cataracts; zonular or lamellar cataracts; congenital cataracts.

Anterior polar cataract has already been referred to; that it is caused by perforating ulcer of the cornea and it may be a minute white dot upon the capsule, or there may be a conical mass projecting forward and perhaps an inverted cone penetrating the lens. There will be a hazy spot, perhaps a distinct scar, upon the middle of the cornea and sometimes a thread runs from it to the lens-spot. The condition is stationary and the effect on vision is damaging.

Another pe of anterior polar cataract results from pathological alterations in the fœtal pupillary membrane (Mules, Trans. Ophth. Soc. United King., XI., 70, 1891. See also p. 439, Fig. 154).

Posterior polar cataract is the result of choroidal disease. It is associated with hyalitis and myopia. Opacities will be found in the vitreous and if the spot be not too large, the fundus will be visible and oftentimes lesions be discovered. The location of the opacity is determined by noting that it changes position very slightly as the eye looks in various directions, because it is situated near the centre of rotation of the globe, which is about four millimetres behind the posterior surface of the lens. Moreover, the apparent motion of the edge of the pupil relative to the opacity gives us a gauge by which to measure the depth at which it is situated. Such opacities do not in themselves greatly deteriorate vision, because they lie so close to the nodal point, the optical centre of the eye. But the subjects see badly because of the concomitant lesions. With this kind of cataract there may also be striæ, but it remains unchanged for a long period. In the end the lens grows more opaque. The added opacity is sometimes a cloudy obscuration increasing the area of the original spot, or it may consist in innumerable dots scattered through all the lens, etc.

Lamellar or zonular cataract (Schichtstaar) is the most frequent variety of *congenital* cataract. It often presents little to be seen by the naked eye, although on close attention a gray blur may be noticed in the pupil. The patients hold objects very close,

Digitized by Google

they shun the bright light; as they peer about they manifestly see imperfectly. They are commonly thought to be only near-sighted; it is possible for genuine myopia to coexist. To the ophthalmoscope a sharply defined opacity will appear in the axis of the lens. It may be more or less dense, it may have knobs or rays on its edge; generally circular, it sometimes has a symmetrically angular form; there may be other dots in the otherwise clear periphery of the lens. I have seen a beautifully defined triangle with a knob on each point. The real nature of these cases consists in opacity of certain layers of the lens, while adjacent parts are clear. Some varieties are shown in Fig. 185. They show how one or more layers may be opaque and explain the difference in density often noted between the central and marginal parts of the opacity. See p. 484.

An interesting circumstance in the etiology of these cases is that they depend upon constitutional causes, such as scrofula or rickets or hereditary syphilis, and that the patients have had convulsions. Arlt first called attention to the fact of convulsions; he found that among twenty nine cases, twenty-five had been thus affected, and to the violent disturbance of the lens while its growth

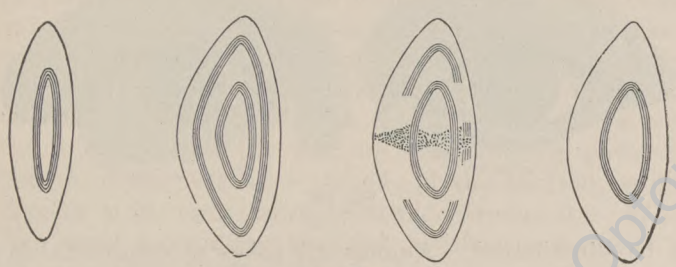

FIG. 185.

was incomplete, he attributed the production of lamellæ of opacity. Another co-ordinate fact is that so-called rachitic teeth are common (see page 391). They are terraced, the enamel is seamed and pitted; the tooth is apt to be broken off. There may be also defective cerebral development. It almost always affects both eyes; it may be hereditary. Generally, but not always, the perceptive capacity of the eye is good, and herein is an important contrast to other forms of congenital cataract. It makes its appearance during the last weeks of fœtal life or in the first months of extra-uterine life. Having reached a certain degree it may acquire more intensity, but does not enlarge, except rarely.

Congenital cataract appears in other forms, and may or may not be associated with other abnormal states of the eye, such as coloboma, microphthalmus, irido-choroiditis, choroido-retinitis, amblyopia, etc. One or both eyes may be affected and the whole of the lens be opaque. Sometimes deposits appear on the capsule, for

Digitized by the Internet Archive of Ophthalmology

instance, a white star with three radii and other forms. Often the pupil dilates imperfectly even with atropia. The lens is often small, generally it is soft, but the contrary condition of great density has been observed. There may be only a thin membrane;

FIG. 186.

FIG. 187.

when caused by irido-choroiditis the pupil may be adherent, the lens very white and calcareous.

In very many cases there is poor perception of light and it often follows that removal of the cataract is not productive of good vision. Sometimes the vitreous is found opaque and the fundus

FIG. 188.

cannot be illuminated. Among all cases of congenital cataract nystagmus is frequent.

Diagnosis.—What has already been said about symptoms will suffice to make known the existence and many of the characteris-

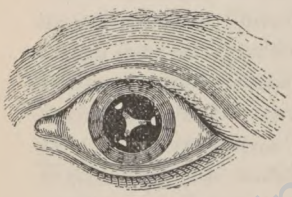

FIG. 189.

FIG. 190.

FIG. 191.

tics of cataract. The facts which must be learned preliminary to treatment are, the density and size of the lens, whether perception of light is normal, and projection normal, *i.e.*, whether the field is correct. We must take note of the behavior of the pupil, whether free, or active, or sluggish. We must also feel the tension of the

Digitized by Illinois College of Optometry

globe. Most senile cataracts have soft cortex and hard nucleus. The amount of cortex is important. The first question to be settled is whether an operation is to be done. This turns upon the stage of the cataract and upon the functional examination. Is the eye in other respects healthy?

Special attention must always be given to the degree of *light-perception*, because it is the most important factor in the case. It may be premised that qualitative perception of light, that is, ability to see objects or to count the fingers—not his own, but of another—precludes the idea of operating. The patient should wait; unless it should be seen that the lens is of the sclerosed variety mentioned on page 481, in which case the patient may continue to count fingers within six to forty inches, for years, and should not be refused an operation.

With uncomplicated mature cataract a patient should recognize the light of a candle in a dark room at forty feet with perfect ease. A more ready way is to use the ophthalmoscopic mirror with feeble light, and hold it two to six feet away, to make its illumination extremely faint; this the patient should promptly recognize, and also be able to indicate the direction from which the light comes; this tests what is called the projection of the retina, as well as its perceptive power. Any abatement of this quick response to light, and inability to recognize the direction from which it comes, awakens suspicion of internal lesion of the eye, which clouds the prognosis. Marked limitations of the field or of projecting power indicate detachment of the retina, or atrophy of the choroid, or disease of the retina or of the optic nerve, or turbid vitreous, etc. When these facts are made known, one may feel justified or bound to operate, but the probability of success and the gain in vision are put at a level, which ought to be correctly appreciated both by the surgeon and the patient. It is sometimes desired to have a cataract removed, when in only one eye, to get rid of the blemish, without regard to improvement of sight. This is admissible, if not contra-indicated by extreme tension or tendency to hemorrhage or presence of a foreign body, or other serious intraocular lesion, and often succeeds.

Is the lens mature? As already said, absolute opacity is not always demanded, but the lens must separate easily from the capsule and not leave transparent substance behind. Sclerosed lenses which are partially transparent will come out clean, while immature cataracts which have only a hard nucleus and whose cortex is in process of opacification leave remnants behind to awaken trouble. When the striæ upon the surface are fine the lens is hard, when they are broad, and satiny and white, the cortex is soft and abundant. If the opacity lies close to the iris, and the edge of the pupil casts no shadow upon the lens under oblique illumination, the cat-

aract is mature and fit for operation. The cataract may be hypermature; *i.e.*, the cortex has become liquefied. This will be known by the gruel-like look of the surface; it will be bluish white or creamy; the yellow nucleus may have dropped out of the axis of the eye and its rim may lie visibly across the pupillary field. It will change position as the head is inclined for a few minutes forward or to one side.

A *soft* cataract is whitish, bluish, with broad striæ, gives forth no yellow tint, may push the iris forwards. It belongs to the earlier period of life, *i.e.*, under thirty years. There are cases of purely fluid cataract which are degenerated soft cataracts, and the color and appearance suggest a mixture of white meal and milk. Such cases may be followed after operation by very severe reaction.

The signs of *complicated* cataract have been partially referred to in speaking of the functional examination. Adhesions of the pupil will not escape notice. Discoloration of the iris, atrophy of its tissue, softness of the globe, tenderness about the ciliary region, tell of cyclitis or choroiditis. A very yellow or chalky white lens, or one in which cholesterin is seen, or with many spots of distinct capsular opacity, signifies more or less serious deep-seated trouble. A shrunken or deformed lens, or one reduced to a wafer, indicates extensive choroidal and vitreous disease. If the iris and lens flutter, this is a warning of fluidity of the anterior part of the vitreous, or loosening of the suspensory ligament. An eye with absolute glaucoma will often have cataract. Inquiry should be made as to pre-existent myopia, and attention be directed to possible detachment of the retina. The existence of *muscæ volitantes* is of uncertain importance, in most cases they are of little consequence.

Prognosis.—The first question relates to the probable behavior of the opacity—whether it will disappear, remain stationary, or increase, and if it increase, at what rate? Under the description of special types (see p. 482) much has been said regarding particular varieties. We are specially interested in the prognosis of what is called senile, *i.e.*, ordinary cataract. A few streaks at the periphery small and well defined, and with advanced age, above sixty, are unlikely to make serious progress. At a similar age a hazy (sclerosed) nucleus will often remain practically unaltered for many years if the health be good. Lenticular opacities in myopic eyes of elderly people often remain stationary. I have watched such cases seven years and found no serious visual impairment. It is not asserted that all nuclear cataracts will be stationary even in old people. Cortical cataracts with broad streaks approaching the axis, and especially with minute molecules between the fissures, indicate a tendency to increase, and swelling of the lens is especially suggestive. *But*—and the word is emphasized intention-

Digitized by Google

ally—it by no means follows that sight is to be quickly lost even in unpromising-looking cases. A stage of irritation often attends the beginning of cortical cataract, and as this subsides vision improves and may continue better during many months. In fact, there may be more opacity and equally good or a little better sight. There is a personal equation in such cases which we do not understand. Observations concurring with my experience have been made by Brailey.[1] He notes the behavior of thirty-one cases for periods varying from three months to eight years—fourteen remained stationary, thirteen grew worse, either slightly or seriously, four got *slightly better*, and this slight improvement may last a few months or be permanent. If the first eye become blind the advance is likely to be more rapid in the second. Rest and improvement of health have much to do with retarding the advance of cataract (see Risley).

With mature and uncomplicated senile cataract, the needful factors for successful treatment are a smooth and correct operation and a patient of quiet temper, hopeful and obedient. A bad cough or very great weakness are unfavorable. But the state of health is not so dominant a condition as has sometimes been supposed. Very fat persons are not good subjects. The existence of diabetes does influence the result, but not to a very serious degree.

The operator must make a wound of adequate size, smooth, properly placed, and preclude all conditions unfavorable to prompt healing. There should be an active pupil, the anterior chamber of proper depth, the tension normal; an eye set very deep in the orbit makes the operation difficult, one which is prominent does not get on so well in healing. Conditions which are unfavorable are catarrh of the lachrymal sac, chronic conjunctivitis, and pterygium. The first is always very serious, and if the condition cannot be satisfactorily relieved by probing, one had better resort to destruction of the sac by the actual cautery. Probably it would be better if the latter proceeding were generally adopted. It is certainly advisable to remove pterygium if it be of any size, *i.e.*, if it reach more than a millimetre into the cornea. We cannot always control chronic conjunctivitis and must sometimes take the chances. A very thin cornea will wrinkle, sometimes the sclera is very rigid and the cornea collapses after the section—both these conditions are unfavorable to accurate coaptation and healing of the wound. We are to prevent all sources of septic poisoning of the wound. Hence, beside the conditions mentioned, we must guard against bad sewage and plumbing, uncleanliness of the patient's person and surroundings, of the instruments, of the surgeon's and

[1] Trans. Ophth. Soc. United Kingdom, xi., 66, 1891.

Digitized by the Internet Archive

assistant's and nurse's hands. Ozæna, ulcers of the leg or body may cause contamination. Prophylaxis therefore has much to do with prognosis.

The results of operations for senile cataract have been elaborately compiled. If vision amounting to $\frac{1}{10}$ is secured, the results have been called fully successful; vision less than $\frac{1}{10}$, but permitting discernment of objects (qualitative vision), is called partial success; mere perception of light and worse results are failures. On this classification the failures in 10,094 cases of flap extraction by 35 operators were 10.4%; the failures in 10,661 cases of linear extraction by 110 operators (Graefe's operation with iridectomy) were 5.8%. These statistics were made in 1879,[1] and since that time the general adoption of aseptic precautions gives even better results. The success achieved by operators of large experience is, moreover, considerably greater. It must also be remarked that vision $\frac{1}{10}$ is not considered by all surgeons good enough to be called unequivocal success; they prefer the standard $V = \frac{1}{6}$. Again, the period at which the degree of vision is taken is important, because it improves for three months after healing is complete. Slight capsular obstructions are common and their removal will often greatly benefit the vision.

Treatment.—Spontaneous cure does not take place, except by absorption of the lens, viz., in traumatic cases ("Bericht über Augenheilkunde," Wien, 1867), and in some other soft cataracts (it has been recorded in several cases of diabetic cataract and a few times in hard cataracts without lesion of the capsule; Brettauer, "Bericht Ophth. Gesell.," Heidelberg, 1885, p. 47), or by spontaneous luxation, which can happen in hard cataracts and in cataracts of myopic eyes when the vitreous is fluid. Sometimes a blow does this suddenly, to the great joy and astonishment of the patient.

The disappearance of incipient opacities has been at various times claimed to be effected by massage of the globe. Successes thus attained have been recently reported by Dr. Kalish. The evidence is not convincing and the success has been very partial. Massage is a two-edged weapon, because in many cases instead of retarding the growth of cataract it has hastened it—vide infra (see Seabrook). The claims of galvanism and electricity have no reliable foundation. In the early stages of the disease something can be done to mitigate accessory symptoms. The chief consideration is strict attention to general health, removal of all causes of indigestion or of feeble nutrition, exercise in the open air when the weather permits, cheerful surroundings, and rest of the eyes,

[1] See Trans. Am. Ophth. Soc. for 1879. In that paper an error in the calculation of percentages was corrected by Geissler with the results above given.

Digitized by Google

sometimes aided by blue glasses. I have, when health seemed good, and when the vitreous was hazy, given iodide of potassium, gr. v. ter in die, for several months. Whether *post hoc vel propter hoc,* the sight has often become better. Sal Rochelle might perhaps have been as good. So, too, mild tonics and bitters, strychnia, phosphoric acid, acid phosphates, and such remedies, have fit use. These measures may be aided by soothing lotions to the eye to allay conjunctival irritation, viz., borax and camphor-water, etc. A very weak solution of atropia, gr. $\frac{1}{25}$ ad ℥ i., will be of use to some cases, but strong solutions are unpleasant, because of the great glare of light. Moreover, encouraging words as to the future mean much to a blind person.

It remains to take up the *surgical* treatment of cataract. But some preliminary matters are to be considered. Shall the operation be done upon one eye while the other is perfectly good or has useful vision? For soft, including traumatic cataract, the answer would be yes, because it involves little risk; for hard cataract there is a difference of judgment, but my own practice is in favor of it. I admit that some have been annoyed by squint, and have complained of confusion of sight, but the greater number have enjoyed real benefit. The gain is in the enlargement of the field of vision, in the stronger mental impression, because of a greater impulse of light-stimulus to the central ganglia, and because, notwithstanding the correcting-glass was not worn by the operated eye, a degree of stereoscopic vision may be secured which the patient finds of great advantage. One man about forty years of age, with monocular cataract and the other eye with $V = \frac{20}{20}$, was so much distressed by losing binocular sight, that he demanded an operation, and acquired in this eye, when corrected, $V = \frac{20}{20}$. Without wearing a glass he recovered his former ability to locate objects, could grasp correctly, go up and down stairs with assurance, and was loud in praise of the benefit he received.

Should both eyes be operated on at once? To this my experience leads me to say no. Both eyes may be lost, as has once occurred in my experience by intraocular hemorrhage after the patient had been put to bed. Seldom will both eyes do equally well; and when the possibility of loss of one, and the entailment of sympathetic ophthalmia in the other, are considered, the argument to me is imperious. In cases where the first eye does well and the second is fit for operation, the latter may, in urgent cases, be dealt with in eight to ten days after the first. Usually, several months are allowed to pass.

We have to choose between two methods of curing cataract, the one by *absorption,* the other by *extraction.* Absorption is practicable only with soft cataracts and in young persons; extrac-

Digitized by Illinois College of Optometry

tion has many varieties, according to the consistence of the lens and to the method which is preferred. The old method of reclination or depression into the vitreous has deservedly become obsolete. It is still practised by the aid of a long sharp thorn, among the native operators of India.

Absorption is brought about by opening the capsule with a fine spear-pointed needle and permitting the aqueous humor to soak into the lens. The operation is done almost exclusively on persons under fifteen years of age. Those who are older are sometimes thus treated, but with increasing age absorption takes place more slowly, and if fragments are broken from the lens, they are more apt to provoke irritation. For congenital cataract there is no urgency for an operation under one year old, although it may be done at three months. The development of

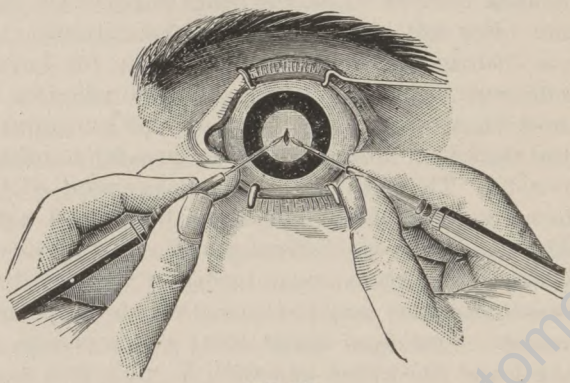

FIG. 192.

the child will decide. It is important to note the dilatability of the pupil. A small zonular cataract will be most wisely treated by a very small iridectomy, oftener by discission, and, in many instances, by letting it alone. The density and extent of the opacity must be carefully studied. The latter course will be adopted for small, central, well-defined lens opacities. If the pupil will not expand well by atropine, there is reason to suspect other abnormal conditions, and iritis may be easily excited. Under these circumstances iridectomy may precede discission by eight weeks, and this will be equally advisable in persons over twenty irrespective of the activity of the pupil (Graefe). If the cataract is more or less fluid a broad needle will be used to evacuate as much as will escape.

The method of *discission* is as follows: Instil several drops of 2% solution of cocaine and of a ½% solution of atropia. Separate the lids by a wire speculum, and steady the globe with one finger, or with the index finger lift the upper lid and let an assistant de-

Digitized by the College of Optometry

press the lower lid. The patient should lie on a table. The needle will enter the temporal side of the cornea just beyond the pupil in a direction nearly perpendicular and reaching to the opposite side of the pupil will cut the capsule by a lever motion, using the cornea as a fulcrum. A second cut may be made at right angles to the first, but at a first operation, care must be taken not to disturb the lens too freely, and it should not be displaced *en masse*. If it be very small these precautions are not so important. At a second operation greater freedom is permissible in stirring up the lens matter, but the iris is to be avoided. If not much substance remain two needles (see Fig. 192) may be simultaneously introduced aiming for the centre of the pupil, and the handles being inclined toward each other, the cutting points pushed deeply into the lens, separate from each other, and open a chasm which gives sight at once. Whether one needle or two are employed they must be lightly handled and inflict no undue violence. Iritis with adhesions, or even irido-cyclitis may be excited. At the close of the operation a few more drops of atropia are put in and the eye bandaged. Generally there is little reaction. On the other hand the cataract sometimes rapidly swells, and if there be any pain within twelve hours the eye must be examined, and atropine put in. If the lens has begun to swell inordinately and fragments push through the pupil and circum-corneal hyperæmia appears, repeat atropia every two hours and apply cold compresses. Horner, who among the Swiss had a very large experience with congenital cataract, was in the habit of keeping the dressings wet with cold water from the time when they were first applied. Should the symptoms increase in severity, the pain not abate, the quantity of protruding lens matter increase, the aqueous become hazy, the iris discolored, and decided ciliary hyperæmia with possible chemosis occur, a free paracentesis must be done with a narrow lance knife. Not only must aqueous humor be evacuated, but the wound will be pressed open by the tip of the lance, as it is withdrawn, and lens matter allowed to flow out. An anæsthetic should be given and a good assistant is desirable. One ought not to defer interference under these conditions very long, because relief is prompt. The older the subject the more likely will be such reaction. While discission is very simple and slight as an operation, it may be followed by violent reaction, with plastic iritis, advancing to suppuration, and panophthalmitis. It is sometimes difficult to understand how the presumable infection has arisen, but the deplorable possibility occurs.

The above remarks apply to all cases of soft cataract in young subjects, whether spontaneous or traumatic. The period required for absorption varies considerably, say from three to twelve months. Several operations may be required and the intervals ought not to

be less than three months. It will be prudent to use atropia during most of the treatment. Care must be taken to make the incisions so as to leave a clear opening in the capsule, and this always grows tough as the case progresses.

Respecting *zonular* or *laminated* cataract, it may be remarked, as already said, that both the extent and density of the opacity must be carefully considered before deciding what to do. If small and thin, perhaps nothing should be done. It is often wise to omit doing anything until the patient shall be old enough to permit examination of the degree of vision. Iridectomy is of very inferior value, because the refractive properties of the periphery of the cornea and lens are extremely irregular. The operation of iridodesis is attended with risk of sympathetic ophthalmia. For some special cases iritomy may be practised by Wecker's *pince-ciseaux* or by scissors devised by Mr. Carter. A wound four or five millimetres long is made opposite the border of the dilated pupil, and one blade of the scissors slipped behind the iris, and with one cut the membrane is slit for two-thirds of its breadth. Much delicacy is required to avoid bruising or rupturing the capsule, and full anæsthesia will be demanded. The larger number of cases of zonular cataract will gain the most satisfactory vision by resorting to discission and the use of proper glasses. It sometimes happens that they have satisfactory vision for all distances near and far, with only one pair of glasses.

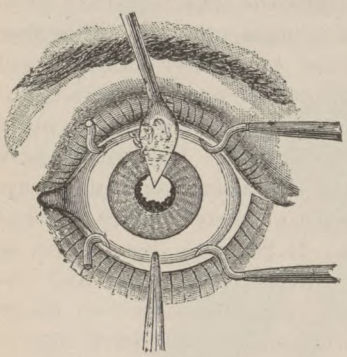

FIG. 193.

Extraction may, in special conditions, be employed for *soft* cataract and is known by the name of *simple linear extraction.* The operation has been referred to when remarking upon extreme swelling of the lens after its discission. It may be employed in any case where the lens substance will flow through a small corneal incision. The suitable degree of softening may occur spontaneously, but generally it is caused by injury. The whole lens must be in this state and not merely its surface, as in hypermature cataract. The operation is applicable to any age, but by persons of middle life its manipulations are not so well borne as by those under thirty, and it may in them be substituted by the method for hard cataract, provided the capsule has not been ruptured. It may be done either without or with iridectomy, and the iris operation may be coincident or precedent. If no iris be removed, the lens-matter must be small in amount and very soft. Under such conditions

Digitized by Illinois College of Optometry

(using *anæsthesia,* a speculum, and fixation-forceps, which are to be applied at a point diametrically opposite the intended place of puncture), a narrow lance-knife (see Fig. 194) is thrust almost vertically through the temporal side of the cornea, just at the apparent edge of the fully dilated pupil. It is carried into the lens so as to open the capsule freely. The operator may increase the capsular wound by lateral, lever-like movements of the handle. Then withdraw the blade until its point just projects within the wound, and open it by pressure backward; the lens-matter comes out, and its exit may be aided by slight counterpressure with the fixation-forceps. See Fig. 193 where the wound is above and at the limbus. The knife is partially withdrawn and lens-matter is escaping. Let the exit go on slowly to avoid prolapse of vitreous, and keep up pressure very gently, until the pupil clears. Before the first glimpse of vitreous prolapse, pull out the knife and close the eye, even if some lens-matter remain.

Another way is to withdraw the knife quickly after it has made the wound in the cornea, and by a sharp cystitome open the capsule very freely, then evacuate the lens by the point of a curette laid at the wound to press it open (see Fig. 194). The fixation-forceps may be taken off, and counter pressure made by a rubber

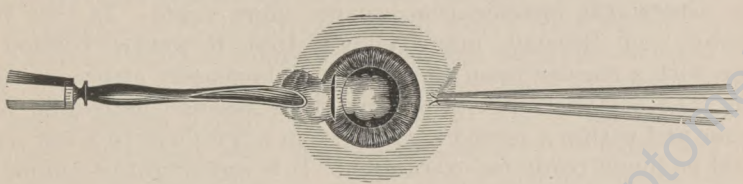

FIG. 194.

scoop, which shall be passed over the cornea, squeezing out and following up the lens-matter. In Fig. 193 the wound is above, at the limbus corneæ, no iridectomy has been done, the capsule has probably been opened by the traumatism which caused the cataract, and lens matter is escaping under light pressure of the lance on the posterior lip of the wound.

If the operation be done with iridectomy, the wound is made, ½ mm. inside the limbus, with a lance knife, and will be about five millimetres long. Introduce forceps to draw out the iris, and cut it close to the cornea; with a sharp cystitome open the capsule as freely as possible, for this is a most essential step. The expulsion of the lens-matter may be done by the curette, aided by counter-pressure with the rubber spoon. Cocaine reduces tension and retards expulsion of soft matter; general anæsthesia is desirable. There is danger of loss of vitreous, because the inner wound lies near the circumlental space. Sometimes lens-matter must be left

Digitized by Illinois College of Optometry

behind. It seldom makes any trouble. Entanglement of capsule in the wound is to be specially guarded against. Atropia, gr. iv. ad ℥ i., is instilled, both eyes bandaged and the patient put to bed. The well eye will be released in twenty-four hours, and the operated eye washed with solution boric acid, and atropine, gr. iv., put in. The bandage may be kept on for two or three days and later a shade over both. Atropine to be used twice daily after the first twenty-four hours, and later, when the bandage is off, three times daily. Keep the patient quiet for seven to twelve days. Bowman at one time practised the removal of soft cataracts by a syringe of special construction. McKeown has more lately revived the method, and Lippincott has practised it extensively, but it is not without special dangers, and is not recommended.

Before discussing the extraction of hard cataract, it will be proper to speak of what may be done for an *immature* hard cataract. A lens with many deep and broad streaks and much clear substance, and which causes inability to read, is in a proper condition for *ripening* by massage. Especially advisable is this when both eyes are involved, and one more than the other. It has not been uncommon to perform preliminary iridectomy under these conditions, and it has been noticed that afterwards opacification became more rapid. In 1881 Prof. Förster,[1] of Breslau, made known that if gentle friction be made with a curette upon the cornea immediately after an iridectomy, the cortex would in a short time become more and more opaque and within a period varying from a few days to a few weeks would be found ready for extraction. It is important to confine the movements within the area of the pupil and coloboma. The friction or massage acts mechanically upon the cortical layers and both loosens their cohesion and disintegrates the fibres. Iridectomy is not essential to success, as the result has been attained after complete escape of aqueous humor by paracentesis (Pooley).[2] But success is more prompt and complete after iridectomy, and this is advisable. Iritis with adhesions may be produced, and sometimes the eye is rendered irritable for several weeks. The amount and firmness of the friction must not be too great and the iris must not be squeezed. The surface of the cornea must be kept moist and it is rare to produce epithelial opacity, yet this may occur. Cocaine should be used sparingly. It is a proceeding which in properly selected cases has great advantages, and exempts a patient from many weary months of waiting.

It is not applicable to cases of slowly sclerosing lenses in which the cortex shows few and very narrow striæ. It does no good

[1] Bericht der Ophth. Versammlung, Heidelberg, 1881, p. 133.
[2] N. Y. Medical Record, Dec. 26, 1885, p. 703.

Digitized by Google

in the slowly developing cataract sometimes found in myopia; nor in posterior polar cataract. Extraction will not be done until all hyperæmic tendencies disappear. There will always be considerable cortical substance to be removed, and special pains must be taken to guard against iritis. After this proceeding, the extraction becomes a very simple performance, but there is unusual liability to loss of vitreous. Hence the speculum may wisely be laid aside when the section is made; all manipulations must be very gentle and the lens coaxed, rather than forced out. The extraction incision should be inside the iridectomy wound, *i.e.*, in clear cornea.

The attempt to hasten the maturity of cataract by needling is preferred by some able operators (Mooren), but in my experience it has in some instances caused unpleasant reaction.

Extraction of Hard Cataract.

No operation in surgery has been more carefully studied and elaborated in every detail than that which we are now to consider. Especially within thirty years have numerous modifications been employed. Up to that epoch the prevailing method was "flap extraction" either upward or downward, without iridectomy and accompanied by cystotomy. The wound was corneal, about one or two millimetres from its transparent edge, and included half its circumference. It was proposed to facilitate expulsion of the lens and diminish liability to prolapse of iris by an iridectomy. The most important and radical modification ever made was the so-called linear extraction of von Graefe, which placed the wound in the sclera as near to the iris as possible and involved iridectomy. The genius of its author and his success beyond previous methods led to the almost universal adoption of this proceeding. The occurrence of irido-cyclitis, either early or late, and the liability to error in correctly proportioning the length of the wound to the size of the cataract, and the occasional occurrence of sympathetic ophthalmia, conspired, among other causes, to lead surgeons to bring the wound closer to the corneal edge and increase its length to ten or twelve millimetres. Even thus modified the operation was still called by Graefe's name—chiefly because the knife which he introduced was retained, viz., a straight blade of two to three millimetres in width. Some surgeons used scoops to deliver the lens; by some the lens was forced out if possible with unbroken capsule. The wound has been made across the cornea at the junction of its upper and middle thirds (Lebrun) and also at the junction of its middle and lower thirds (Liebreich) or thereabouts, and both with and without iridectomy Within re-

cent years there has been very general adoption of the transparent edge of the cornea, above, and for about two-fifths of its periphery as the place and extent of the wound. An idea of the topography of the parts according to the site of the wound is gained by Fig. 195, where four different sections are given. The nearer the sclera the more urgent will be excision of iris. Another phase has been given to the question by the advocacy of stricter precautions and methods for antisepsis. Most surgeons indorse and adopt such measures. The question of anæsthesia has been in this country variously decided; in Europe it is seldom thought of. At present, a solution of cocaine supersedes all other kinds of anæsthesia almost without exception.

Certain measures hold good for every kind of operation as follows: the patient must be known to be clean; if in hospital he should have a warm bath and great pains taken to clean the head, hair, face, beard, and hands; soap and a brush must be freely used. His clothing must be clean, likewise the bed and its covers; the room be free from all sources of impurity; carpets and hangings are objectionable. All sources of infection must be excluded, such as proximity of suppurating wounds or caries of bone, or erysipelas: in fine, whatever promotes the presence of pyogenic germs. As already stated, the existence of ozæna, of ulcers or fistulæ, of eczema, the presence of catarrhal conjunctivitis, of disease of the lachrymal sac, or of pterygium must be noted, and provided against. A severe cough, asthma, incontinence of urine, etc., must be controlled, so far as possible, and the health must be as good as may be possible. A good night's sleep should be secured, and if in spite of hopeful words and assurances, a patient be excitable and tremulous, a dose of bromide of sodium, ℈ij., and chloral, ℈i., or a larger quantity, may be given an hour before the operation. The bowels should be cared for.

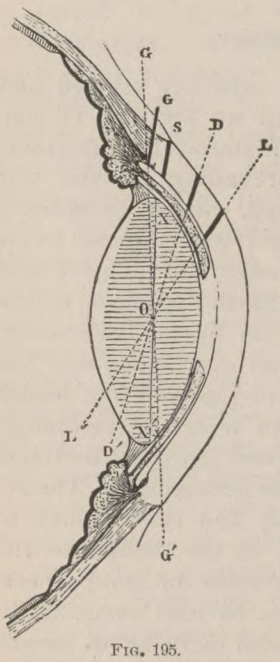

FIG. 195.

At the operation the patient should be upon his back, his head resting on a hard cushion, and for the right eye the operator will be behind, and for the left eye he will, unless he can use both hands equally well, place himself at the right side of the table or bed; a table is to be preferred; in hospitals an operating chair is sometimes carried to the patient's room. The lids and eyebrow and adjacent parts of the face will be washed with solution of corrosive sub-

limate, 1 to 2,500. See that the eyelashes and lid borders are clean. So strong a solution must not enter the eye, and I have once known it to excite severe erythema of the skin in a patient who had been subject to eczema. Open the lids by a wire speculum and lifting them from the globe irrigate the conjunctiva with sublimate solution, 1 to 5,000, or boric acid, 4% solution, by a bulb copiously.

The instruments have been soaking for twenty or thirty minutes in 5% solution of carbolic acid. The points of the iris forceps and of the cystitome have been examined under a lens to see that no foreign matter adheres to them. The knife is liable to lose a little of its keenness by the carbolic acid, and it, as well as other

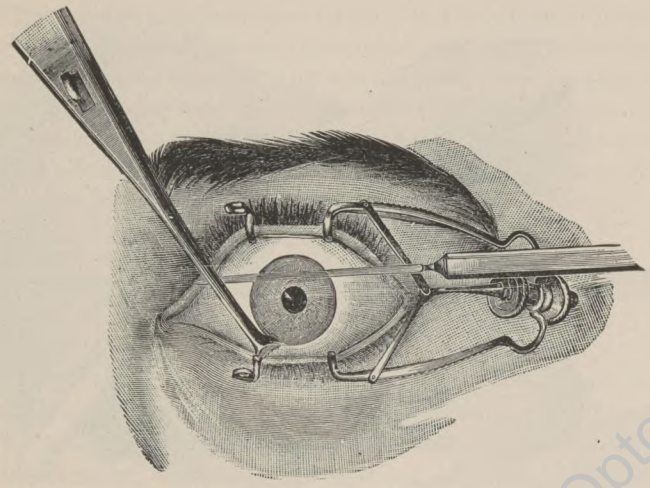

FIG. 196.

instruments, might be immersed for ten minutes in boiling water. However this may be, the blade may be rubbed off between the thumb and finger by a bit of soft rag soaked in alcohol, and examined under a lens. The operator and his assistants will scrub their hands with soap and brush, and to cleanse the nails effectively powdered borax upon the soapy brush is an admirable detergent. All these are antiseptic precautions and they are comprised under the term scrupulous cleanliness. A solution of muriate of cocaine, 2% or 4%, will be dropped on the cornea twice or three times with an interval of ten minutes.

Extraction with Iridectomy.—1. The operator seizes the conjunctiva just below the cornea, on or a little inside of the vertical meridian by the fixation forceps and bids the patient look down. The knife is entered at the edge of the cornea about three milli-

Digitized by the Internet Archive of Optometry

metres below a line laid horizontally tangent to its upper edge. Sometimes a wide arcus senilis causes embarrassment. Some operators endeavor to lift a conjunctival flap, but one must then contend with hemorrhage, which is an offset to the asserted gain in healing capacity. The point is pushed across the anterior chamber to a spot diametrically opposite, and care must be taken that it does not go too deep and emerge nearer the iris than was the entrance (see Fig. 196); if it does, withdraw and try again. If counter-puncture is hit correctly, push forward with a tendency upward so as to cut as the point advances. From three to four millimetres will be cut before the blade is arrested. In withdrawing let the heel cut the temporal side of the wound, and by this

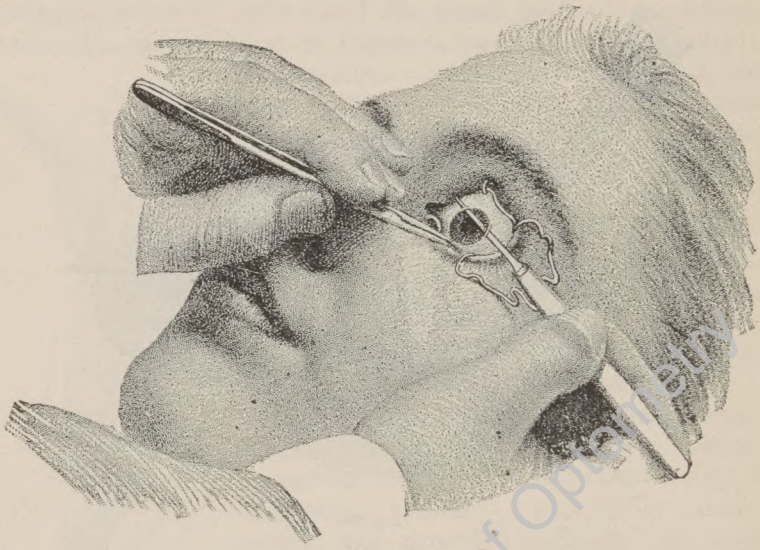

FIG. 197.

manœuvre the iris will be kept from falling over the edge; the middle part will be slowly severed by to-and-fro movements, keeping all the time upon the corneal border. At completion the edge of the knife may be turned a little forward to obviate undermining the conjunctiva. As above said, a conjunctival flap is not essential, and has some inconveniences, especially in the bleeding. The wound must be made smoothly, if possible in one plane, and must be fully two-fifths the corneal circumference. The estimated size of the cataract will determine the length of the wound, remembering that its available dimensions are to be measured upon its interior not its exterior line. The older the person the larger will be the lens; the amount and consistence of the cortex will be borne in mind; a sclerosed lens may have ten millimetres diameter, while in hypermature cataract the nucleus may be only six to seven milli-

Digitized by the College of Optometry

metres. There is no fault so disastrous as to make too small a corneal wound. In Fig. 196 the operator is behind and using his left hand. The amount of cornea included by the knife is rather small. A millimetre lower down would be more correct. See Fig. 197 where the operator is in front and using the right hand.

At this point the behavior of the patient is extremely important. If he squeeze the eye or turn it forcibly up, let the assistant take off the pressure of the lids by lifting the speculum, or let it be removed.

2. If iridectomy is to be done, proceed quickly lest hemorrhage interfere. The iris may prolapse, if not, catch it with curved forceps, and cut off with scissors what presents without special traction. The curved scissors may be held in the vertical meridian, the convex side pressed down on the wound, and one cut suffices. This may not always be feasible, and the excision may be done with two or more cuts along the line of the wound, but close to it. In the case of a tractable patient and with no hemorrhage into the anterior chamber, restore the iris to its place by the spatula inserted at the angles of the cut and proceed to open the capsule.

FIG. 198.

3. The cystitome may be sickle-shaped, or if toothed it must be sharp and have a cutting edge and not be too long. The intention must be to cut, not tear the capsule, and dislocation of the lens must be avoided, while a large opening is made. During the iridectomy the assistant has held the fixation forceps, the operator now takes it himself or will perhaps remove it. If the speculum has been lifted it should now be allowed to fall in place, because its pressure aids in expelling blood and puts the capsule on the stretch. The cystitome, whose shank may be bent for the right and left eyes respectively, is carried down to the lower edge of the pupil and makes a horizontal cut by a series of small scratches and when this is done, a vertical cut at its middle like an inverted T. All movements must be very gently performed, to avoid dislocation, and in withdrawing lift up the point so as not to draw tips of capsule into the corneal wound. The satisfactory opening of the capsule is denoted by the coming forward of the lens to the cornea.

4. To expel the lens, a curette or narrow spoon is laid upon the lower edge of the cornea while the eye looks strongly downward, and makes pressure backward to tilt the edge of the lens toward the wound, and so soon as it opens, the lens is shoved up and as its edge becomes engaged, the pressure follows it steadily,

Digitized by Illinois College of Optometry

seeking not only to force out the nucleus, but to secure with it as much cortical matter as possible. In doing this the cornea sometimes will be deeply depressed and expulsion take place slowly, at other times the lens comes out with suddenness. With nervous patients it is often safer to remove the fixation forceps and speculum, while the operator controls the upper lid with his finger, or by a wire retractor (see Fig. 198); or even by a strabismus hook, he can more easily guard against a gush of vitreous by some unexpected pressure by the patient. Difficulty in delivery of the lens will depend on deficient size of the corneal wound, or of the capsulotomy, or upon displacement of the lens or upon adhesion of the cortex to the capsule. If the wounds are all adequate and the border of the lens will not enter, close the lids and make slight pressure with a pad of cotton. The lens is probably a little luxated. In a few minutes it will often resume its place. If it do not, introduce the cystitome and push the lens a little downward, because it may have slipped past the corneal opening. Repetition of the preceding effort will probably succeed. Sometimes a second curette is placed above the wound for counter-pressure. Expulsion may also be effected by pressure above the wound coaxing or attracting the lens out, while the fixation forceps at the opposite side makes pressure.

Very often an operator will with an uneasy patient or with one whose muscles are held tense in his effort at self-control, remove the fixation forceps and perhaps the speculum, before attempting expulsion. He will trust to his control over the patient to induce him to turn the eye down. It may be well at this stage to put in additional cocaine, wait, and if the patient is very unmanageable, press gently upon the eye with absorbent cotton.

Removal of fragments and of cortical matter (which the French call the *toilet* of the eye) is done by very gentle pressure on the cornea with the back of a spoon or curette, squeezing the substance toward the centre of the pupil and the wound. The thumb pressing on the lower lid will often do good service. Much tact and delicacy are requisite, and the attempt must be made to get the pupil perfectly black. Artificial illumination by condensed light is of great value to show the state of the pupil. Great assistance is gained in removing cortex by irrigating the eye with the tepid boric-acid solution, 3%, by the bulb. The stream may be directed at the wound and will not only wash out what is between its lips, but will to some extent penetrate the anterior chamber. Introduction of instruments demands the utmost caution, and to thus syringe out cortical remains (Panas, Lippincott, Andrews) adds another peril and cannot be commended (Trans. Am. Oph. Soc., 1891).

That the pupil is clear will be shown by the ability of the patient to count fingers at a few inches. Before closing the eye, one must

Digitized by the College of Physicians

be sure that the iris is fully restored to its place, and the pupil must be unequivocally *in situ*. To reduce the angles of the coloboma, or the iris, stroking of the wound by the spatula may be practised or the instrument inserted into the wound to smooth out the iris. At this stage all manipulations must be most carefully managed, because vitreous is liable to be expelled.

Should the capsule be very thick or have a thick central deposit, a piece of it may be pulled out by forceps whose teeth incline downward and backward. Some operators, chiefly Knapp, incise the capsule near the edge of the lens. This leads of necessity to the formation of so-called capsular cataract, which Dr. Knapp is in the habit of dividing soon (within four to six weeks) after the case has recovered, and makes such an operation an almost uniform practice. I have found that two oblique cuts, each beginning below the pupil and forming the letter A, with the opening below, open the capsule well and do not offer tags to be caught in the wound. Should the lens refuse to come to the wound because of its very small size, as in hypermature cataract, one may have to use a hook, or a ring curette. If it drop out of sight into the vitreous, it can only be fished out with a spoon, and this is not always possible.

Extraction without iridectomy differs in no essential particulars from the above description, except that the size of the wound must be greater, taking in almost one-half of the periphery. It is more difficult to deliver the lens, because a sufficient opening of the capsule is not so easy and to bring the lens through the pupil requires it to be tilted much more strongly upon its horizontal axis, and rigidity of the iris may hinder expansion of the pupil (see Fig. 195). A satisfactory riddance of cortical matter is not so easy. It follows that extraction without iridectomy may involve more violence to the eye than with iridectomy, yet when correctly done is simpler. The special objection is the liability to prolapse and permanent entanglement of the iris. On this point we are assured that large experience greatly reduces the risk (Panas, Wecker, Knapp). It is, nevertheless, true that despite an operator's skill it does occur in a percentage of cases not yet well ascertained, perhaps four to ten. Galezowski says that in the last 200 cases, he had only one prolapse. Schweigger in 451 operations had 8% (*Archives of Ophthal.*, XX., 3, p. 312, 1891). Knapp had 6%. There is less "blinding" by diffused light and the peripheral vision is better with the small pupil. It is true that excision of iris is a mutilation, and the burden of proof in its favor would logically belong to those who practise it, did we not have a large clinical experience to justify it. We may fully accept Schweigger's assertion that excision of iris is not an "antiphlogistic measure," although it may in certain cases be a means of preventing

complications and accidents which would lead to inflammation. We may sum up the question as follows:—

Extraction without iridectomy has been gaining ground because omission of iridectomy makes the operation less complicated; the indirect vision is better, the eye looks more natural. On the other hand, we have to contend with prolapse or incarceration of iris, and the astigmatism of the cornea is often extreme because the wound is larger and may be less peripheral. The writer has practised this mode of operating more frequently within two years and offers the following suggestions: It is unadvisable to use eserine before operating. It is advisable to use cocaine on the preceding day to learn how much mydriasis it will cause and to gain its hypotonic effects. The contra-indications to operating without iridectomy are as follows: a pupil which is inactive or rigid, and which does not dilate readily to cocaine; a detectable degree of plus tension; abundance of cortical substance; indocility of the patient, especially by forcible contraction of the orbicularis muscle and tension of the ocular muscles. The precise site of the wound varies among operators. Knapp places it at the limbus, is careful to make it in one plane, and raises a conjunctival flap. Bull brings the wound within the cornea, its extremities at the limbus, and the apex 1½ mm. below the vertex. Each operator claims that his method ensures greater protection against prolapse. I cannot find that immunity is gained in this way. I am sure that a sufficiently large wound made smoothly and without violence is indispensable, while the exact site is not a controlling factor. I prefer the limbus generally and do not raise the conjunctiva. I have seen the iris incarcerated in the angle of a very low corneal wound where the healing had been exceptionally prompt. It is a just conclusion that only selected cases are suitable for the so-called simple extraction, and the above considerations seem to me dominant in making a choice. It is right to add that iridectomy is not always a safeguard against prolapse. There are numerous cases in which the angles of the iris are caught in the extremities of the wound, either with or without cystoid cicatrix. This happens sometimes even when the iris has been duly returned to its place at the close of the operation, and is a consequence of the same causes which have been above referred to, viz., plus tension, squeezing, imperfect union, etc. Kerschbaumer, in the same number of *Archives of Ophthalmology* that contains Schweigger's article on cataract, viz., Vol. XX., 3, p. 353, reports on 200 extractions with iridectomy and gives 13 cases of incarceration of the iris, viz., 6.5%. Out of these 7, or 3.5%, had cyclitis with damaging results. Incarceration in extractions with iridectomy stands in line with prolapsus in simple extraction. Its effects are

Digitized by Google

more liable to be disastrous. Many operators insist on eserine immediately after the operation. I have a growing doubt about its efficacy, and in this view Schweigger concurs. He also (1891) attributes the occurrence of prolapse in the majority of cases to traumatic causes, viz., squeezing or touching the eye or straining at stool. For this reason he insists on confinement to bed for three days. But it must be admitted that if prolapse most frequently happens within three days, it can happen as late as the sixth day by secondary opening of the wound. If prolapse be small it may be let alone without risk. If of medium size it may be left to itself until the tenth day and then if needful be abscised. It is by no means imperative to cut off a moderate prolapse, in fear of supposed future risks.

There is much less liability to entanglement of a tag of capsule in the wound in the simple operation, than after iridectomy. The summary of results may be fairly taken from Schweigger's statistics, l.c., 1891, p. 319. He takes $V = \frac{1}{6}$ as success, not $V = \frac{1}{10}$, and reports on 371 cases *with* iridectomy:

Success,	278=75.1%
Secondary cataract,	71=19.2%
Loss,	22= 5.7%
	371= 100%

Upon 450 cases *without* iridectomy he gives:

Success,	346=76.5%
Secondary cataract,	84=19.1%
Loss,	20= 4.4%
	450= 100%

The difference is not great and certainly is not against the simple operation. Schweigger employs a broad knife resembling the old Beers knife, whose blade is 7 mm. wide at 30 mm. from the point. He makes the section either downward or upward, and has the lids separated by elevators, until the section is complete. If the section be upward he uses fixation forceps; if downward he resorts to a bident needle. Out of 400 successive cases of extraction of hard cataract he employed iridectomy in 65, viz., 16%.

As to instruments, Fig. 199 represents the form of Graefe's knife which is usually to be preferred, both in width and length.

Fig. 200 shows cystitome and spatula. The former must cut, not tear; the latter may be bent and is sometimes made not of metal, but of tortoise-shell. Fig. 201 represents a bident to be preferred sometimes with very restless patients to fixation forceps. It is placed astride of the horizontal meridian within five millimetres of the cornea in the sclera on the nasal side of the globe. It is useful in other operations.

Digitized by the New College of Optometry

The usual dressing is to lay a bit of muslin smeared with vaseline over both eyes, upon this a mass of absorbent cotton smoothly laid and nicely adjusted so as to be perfectly even under pressure, and then a flannel roller about one and one-half inches wide and three yards long. In warm weather a gauze bandage



FIG. 199.

is better. Moderate and even pressure must be made which will keep the eyes steady and not cause pain. The patient goes to bed and is enjoined to keep quiet. It is better to lie on the back, but a position on the side may be allowed to relieve weariness. There is usually smarting pain for two or three hours; if this should not subside within six hours a dose of phenacetine, grs. x. to xx., or if not contra-indicated a hypodermic injection of morphine may be given. It is important to have good sleep the first night. Food should be simple, nutritious, and not require much

FIG. 200.

chewing. The room need not be greatly darkened. If no complaint is made, the bandage will not be disturbed for twenty-four hours; then removed, and the surface of the lids gently wiped with warm solution of boric acid to remove secretion which may adhere to the lashes. A wad of cotton thus wet may be kept on the eye for ten or fifteen minutes and will be grateful. No examination of the eye is necessary unless the muslin patch shows a considerable quantity of secretion. In that event separate the lids a little, and if there be decided hyperæmia keep up warm applications for a half-hour. There will almost certainly be pain if any trouble is brewing, but if no pain, as happens with some torpid



FIG. 201.

subjects, there will be injection and notable secretion. It is safer when such signals appear to inspect the wound, lest infiltration is threatened. We may use candle-light, and resort to hot fomentations for a half-hour every two hours. Incipient inflammation may thus be held in abeyance. As a rule a patient experiences no pain

Digitized by the Illinois College of Optometry

—his dressings are changed once a day, the lids being washed; atropia may be used at the first dressing.

Confinement to bed will be observed for one to three days. During this period the bowels may be left to themselves. The bandage will be kept over both eyes for two or five days and be succeeded by a shade, provided a patient can be trusted not to attempt to look about him. Much vigilance is often required in managing patients lest they commit imprudences—such as disturbing dressings and trying what they can see. It is not rare for a patient to injure his eye with his own finger, especially if the dressings chafe the skin. An admirable safeguard against self-inflicted injuries is a mask devised by Ring, which is applied over the bandage and in a few days takes its place.

Instead of a flannel or gauze roller and cotton pads, the lids are by some occluded by isinglass plaster, either black or white (Agnew, Chisholm), which is a return to the practice of twenty-five years ago. For this there are some advantages, no doubt, while for the general run of patients the bandage (systematically introduced by Graefe) is more to be relied upon. The habit of keeping patients in extreme darkness is objectionable, and to this and excessive confinement to bed is to be attributed the mania which has occasionally been seen among old subjects. This aggravates their already feeble condition and cerebral anæmia.

As already remarked, prolapse of iris occurs, even when iridectomy is done, at the angles of the wound by no means seldom, and is the frequent cause of cystoid cicatrix. It is probably responsible for many of the cases of sympathetic ophthalmia after extraction of cataract. The dark side of the operation with iridectomy is the large contingent of cases of irido-cyclitis and more profound inflammations which result in grave if not entire loss of sight, although perception of light may be retained. This is far less frequent when the iris is not excised. Without iridectomy the section can, if demanded by the depth of the eye, be equally well done downward, as Schweigger does. On the whole the operation without excision of iris will probably in the future be chosen for the larger number of cases, while iridectomy will be reserved for special cases.

Treatment of prolapsed iris is not fully settled; Gayet leaves it to itself and I have seen satisfactory results by so doing. Most operators excise it so soon as discovered. One must be governed by the magnitude of the prolapse and by attendant circumstances. A small protrusion may be let alone. It is wise not to disturb a very nervous patient by such a proceeding until the healing is secure. On the other hand, if suspected within twenty-four hours, because of sudden pain or a gush of fluid, I have known it successfully replaced with a spatula and remain.

Galezowski who omits iridectomy, and has done in this way one thousand five hundred and sixty-nine operations,[1] covers the wound with a strip of sterilized gelatin.

The serious complications which may take place during the healing are, first, infiltration of the wound, and secondly, iritis, which may also involve deeper structures. The first will appear within the early days, while the second may not arise for a week or more. A rare and most disastrous event is severe intraocular hemorrhage taking place at or soon after the operation. In only one instance have I see any sight remain after this accident.[2]

In case the operation has not been normally executed, especially if the delivery of the lens has been difficult, perhaps requiring the introduction of an instrument, or there has been loss of vitreous, or by maladroitness, or by the patient's indocility the eye has been severely handled, reaction will be likely to be considerable. There will be chemosis, swelling of the lids, and pain. For this leeches to the temples may be used, and hot fomentations assiduously applied; an adequate dose of morphia to be given for acute pain. Sometimes ten grains of quinine will have a most happy effect in aborting threatened inflammation. For periods of one or two hours the hot fomentations and the bandage will be alternated; the latter drawn as firmly as may be comfortable, and as the process grows less active it will be kept on for longer periods and the fomentation shortened.

Purulent infiltration of the wound is announced by undue secretion, and if a yellow color appear at its edges, measures to destroy the infection must be prompt. The eye must be washed out with sublimate solution, 1 to 5,000, thoroughly, all adherent substances wiped or picked from the wound and the actual cautery applied. If this be not available, sublimate solution, 1 to 500 may be carefully applied along the wound by a small pencil or by a spatula. Frequent disturbance is unwise, and, therefore, after one application, the eye may be washed out with the weaker solution once in two hours. The treatment will be the same as for any suppurative keratitis, but the ready access of germs to the interior makes the situation much more perilous. If there is already fibropurulent exudation in the anterior chamber it may be drawn out by iris forceps; and washing out by weak sublimate or carbolic acid solution has been practised. But if the exudation is considerable, there will be little hope of preserving sight, while the chances in favor of more extensive internal suppuration are many. Under

[1] Internat. Ophth. Congress, Heidelberg, 1888, p. 156.

[2] Van Duyse, "De l'hemorrhagie Choroidienne grave dans l'Extraction," etc., Annales d'Oculist, T. cv., Mars-Avril, 1891, p. 112.

Digitized by the Internet Archive of Medicine

these conditions, hot antiseptic fomentations are to be strenuously maintained. Vigor and fidelity in these applications will meet with reward in many cases which otherwise would be lost. With copious conjunctival secretion, sol. argent. nitr., gr. v. vel x. ad ʒ i., may be used.

Iritis may occur at any time within ten days. It will call for atropia, which should be in strong solution, gr. viij. or xvi. ad ʒ i., twice daily, unless prohibited by toxic symptoms. Often do we have the ciliary body implicated, and there may be hemorrhage into the anterior chamber. For these conditions hot fomentations are appropriate, and their duration will depend on the amount of pain. The instillation of cocaine will be grateful. Both cocaine and atropine may be dissolved in castor oil as a menstruum if watery solutions cause irritation (Green).

A moderate amount of keratitis,[1] which is probably not infectious, is not infrequent, and shows itself by streaks radiating from the wound and sometimes by a diffuse opacity. This is an early phenomenon and generally disappears without serious results; it is called striped keratitis. Irrigation of the anterior chamber during the operation by sol. corrosive sublimate, 1 to 5,000, has been followed by opaque patches on the posterior surface of the cornea in mosaic like the alligator's skin. I, therefore, reject this solution for irrigation.

In all cases of undue reaction the general welfare of the patient must be attentively regarded. Quinine, bromide, and chloral, sometimes morphia, antipyrine, and antifebrine, and especially digestible food and stimulants must be given. Leeches are to be used with discretion, and their chief indication is pain added to marked reaction. Hot fomentations are the great reliance. The advanced age of most of the patients renders such measures indispensable. Confinement to bed may be too rigidly adhered to. While in favorable cases the after-treatment will be comprised within ten or twenty days, in others it will run on to many weeks. Notwithstanding painful and tedious recovery, it will often be possible to secure serviceable vision by subsequent operation. A mild form of mania is not very rare, resulting from cerebral anæmia. It is quickly controlled by giving the patient more liberty, light, and generous food. The possible effect of atropia in this direction must not be forgotten.

Secondary or Membranous Cataract.

In a large proportion of cases, some membraniform obstruction appears in the pupil after the operation. We have every grade, and may speak of the *simple* and the *complicated* secondary cataract.

[1] Ophthalmic Review, July, 1892, p. 189.

Digitized by Illinois College of Optometry

The *simple* may be extremely thin and nearly transparent, or quite thick and opaque. The condition of the capsule, after escape of the lens, is as follows: the epithelium remains in a normal state, the torn anterior capsule is thrown into folds, adheres to the posterior capsule, and within the pocket thus formed, lens matter is shut up. Soon, by the peripheral cells, a mass of irregular and imperfectly developed lens fibres is formed, which are transparent, and mingled with them is amorphous cortical substance. The periphery is formed into a thick rim, while the centre may be very thin, even hard to see, or be broken by openings, or be thick. It is not adherent to the iris, but to the ciliary processes; the pupil acts freely. Sometimes a secondary cataract may not appear until months or a year after the operation. Peripheral section of the capsule entails a membranous obstruction as the usual result. The *complicated* varieties of membranous cataract appear immediately. The rule with them is, that they thicken and contract, and draw the adherent iris up to the wound, and may obliterate the pupil. Consecutive changes may be severe, and the eye go into atrophy with detachment of the retina, the vitreous become fluid, and the changes which cyclitis causes may ensue. From this may follow also the irritation which sets up sympathetic ophthalmia. The time when secondary cataracts may be operated on is not easily determined, but is seldom less than within four weeks or three months; never until all irritability of the eye has ceased, and this may be after six months or a year. After a normal extraction a patient must be prohibited from having glasses for a month after his cure, and atropine must not be given up too soon, say for two or three weeks after discharge; the contrary course tends to produce secondary cataract.

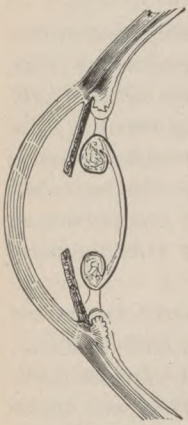

FIG. 202.

The operations for simple secondary cataracts are as follows: discission by a single straight needle or by a knife-needle which enters the cornea near the limbus, on the outer side, cutting horizontally across from the inner to the outer side. Mr. Bowman, for thicker opacities, used two needles, as Fig. 192 shows, and this method pertains to all cases where care must be taken not to drag on the ciliary region. For similar cases, Graefe's iridotomy knife is used, being put into the cornea perpendicularly and near the level of the dilated pupil (see Fig. 170).

A thick and non-adherent membrane may sometimes be best attacked by a needle passed through the sclera behind the iris, which will both cut and displace it, provided there is no ciliary irri-

Digitized by Harvard College Library

tation. Dr. Knapp, who practises discission of membranous cataract with great frequency, insists on the importance of a sharp cutting needle, which shall not permit escape of aqueous, that tough bands be avoided, and the cut made so as to cause the very least traction on the ciliary processes. Under all precautions both operative and antiseptic, I have seen disastrous reaction follow a faultless discission. Though so simple in appearance, my inclina-



FIG. 203.—Knife-Needle for Discission.

tion is not to resort to discission, until the eye does not redden under rather rough handling, and then observe all the cautions above mentioned.

Complicated secondary cataracts present extremely various conditions. We may have merely slight adhesions to the iris, or these may be extensive. In the latter case the iris is usually dragged up to the wound and the membrane may be very thick or otherwise. With a thin membrane, a knife-needle will cut the adhesions and open the membrane, and may be used to sever thin

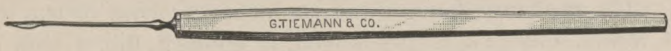

FIG. 204.—Knife-Needle for Discission,

fibrous bands which drag the iris toward the ciliary region. But such interference must be very cautiously attempted.

With a thicker membrane and broad iritic attachment an iridectomy downward may be suitable; and if a membranous obstruction is revealed a subsequent needling may be performed.

For a thick membrane with few adhesions to the iris, Dr. Agnew's method may be used. At the upper edge of the cornea a broad needle pierces the capsule and is held steady. At the opposite side on the margin a wound is made for the introduction into



FIG. 205.—Capsule Hook.

the anterior chamber of a small sharp hook (see Fig. 205) whose point is engaged in the wound made by the broad needle. Securing a good hold the hook tears down the membrane and is resisted by the needle in the operator's other hand, which also defends the ciliary region from traction. As much tissue is drawn out of the wound as possible and cut off by an assistant with scissors.

Sometimes we have to deal with very complicated conditions. There has been irido-cyclitis, and we have to deal with an inflam-

Digitized by Illinois College of Optometry

matory product composed of the iris, the capsule, and newly formed connective tissue, which will be highly vascular, tough, and often under unusual tension. The structures are matted together and bleed easily on being touched. An operation should not be attempted until all irritability of the eye has disappeared. If the globe is soft, the prognosis and the difficulties are grave. Dr. Loring has had success in some of these cases by cutting horizontally through the obstruction with a narrow Graefe's knife plunged into the vitreous and with a sawing motion dividing them freely.

In this class of cases and also for some above referred to, my own preference is to operate by the help of the forceps-scissors of Wecker (see Fig. 167, p. 459), and under general anæsthesia as follows:

A small iris knife (see p. 455), which may be furnished with a stop, makes a wound in the upper edge of the cornea one millimetre or two millimetres from its margin and four millimetres long. After the knife is fully entered it is slightly withdrawn to allow escape of a drop or more of aqueous, and make the iris bulge; its point is then thrust into the middle of the membrane and quickly withdrawn, leaving as much aqueous as possible. The scissors are now passed, with one blade behind and the other in front of the iris, and one cut made, which, if it gapes well, is enough, but if this do not occur, a second cut at an angle to the first is made, as if trying to form an inverted V. The included tongue retracts, and gives a pupil of arrow-head form. Some vitreous is usually lost, because it has generally become fluid, but this does not entail serious consequences. Very slight reaction will take place. The advantages of the method are found in the entire absence of traction on the tissues, the cleanness and certainty of the cuts and that everything is included. The place of the entrance wound should be such as to enable one to cut transversely to the line of greatest traction of the membrane, as was pointed out by Dr. Green.

Operations for secondary cataract look simple and innocent, but they involve much greater risk than the inexperienced imagine. I have had to deplore too many cases followed by cyclitis, or suppuration and loss of the eye. Trousseau[1] frankly says that he agrees with Wecker that the gravity of discission of the secondary membrane is greater than of the extraction of the lens. Out of 453 extractions he saw iritis 12 times; out of 31 discissions he had iritis 10 times. He reports two cases of panophthalmitis despite extreme antiseptic precautions.

Glasses for Aphakia.—For several months after the operation the clearness of the eye improves, and, as already said, it is not wise to begin to wear glasses at less than a month after recovery.

[1] Annales d'Oculist, May, 1892, 338.

Digitized by the Internet Archive

Even a very delicate pupillary membrane if it be in wrinkles will seriously reduce visual acuity, and it should be torn. There is often considerable astigmatism, which will vary from 1 D to 3 D and its correction will much improve vision. It will often grow less or disappear within a few months. If one eye is normal, having good sight, a patient will not wear any glass upon the one which has been operated on. The optical difference between the eyes is too great for their co-operation. The number of the glass to be chosen will of course be influenced by the refractive quality of the eye previous to the occurrence of cataract. With previous emmetropia the glass will be + 9 D or + 10 D; *i.e.*, about $+\frac{1}{4}$ for distance. For reading, about + 3 D or + 5 D must be given in addition. The patient's choice of a reading distance must be adopted, whether more or less close. If acuity be good, a strong reading glass will not be needful. It must be remembered that cataract glasses give patients larger retinal images than normal eyes have. A small pupil is an advantage in conferring a factitious kind of accommodation. Shifting the position of the reading glass materially alters its effect; for example, if a lens of 3″ focus be moved only one-half an inch from the eye, this represents a change equal to an accommodative power of $\frac{1}{20}$ or 2 D. Patients often utilize this circumstance in looking at fine print, by holding their glasses farther away. Becker[1] gives a table of the optical value of various glasses for cataract patients, according to the distance at which they are held. I have known a gentleman who preferred a $+\frac{1}{12}$ glass ten inches before his aphakial eye to an opera glass in the theatre; his other eye was normal.

If only one eye is capable of sight, the glasses are sometimes set in reversible frames, which save some trouble, but are desirable only for persons with noses suitably formed, because a reading glass must come lower down than the glass for distance. To obviate the weight of cataract glasses, Dr. Loring has had them made of small diameter and cemented on a slip of plane glass. It sometimes requires considerable time for patients to feel comfortable in wearing their glasses, especially when walking about. Not only is the displacement in apparent position of objects great and disturbing, especially in going up and down stairs, but there is also an unavoidable restriction of the field, as Berlin has pointed out, greater than happens with feebler glasses, caused by total refraction at the margin of the highly convex glasses.

[1] See Graefe and Saemisch, Bd. v., p. 456.

Digitized by the Internet Archive

CHAPTER XII.

THE VITREOUS BODY.—CORPUS VITREUM.

Anatomy.—This structure occupies the space between the crystalline lens and the retina. It is, therefore, a flattened spheroid with a depression in front, called the lenticular fossa or *fossa patellaris.* It adheres to the optic nerve and to the ciliary body, while with intermediate other parts it has no attachment. It is inclosed in a glassy membrane called the hyaloid (Schwalbe). This is plicated into the ridges and depressions of the ciliary body, and forms the walls of the so-called canal of Petit (suspensory ligament of the lens). The vitreous is transparent and jelly-like, is classed among myxomatous tissues, and its intimate structure has been much disputed, and is not yet fully agreed upon. It is said to be arranged in concentric layers. There are found in it cells of very diverse forms, most of them in its outer parts. There are no permanent cells, but what exist are leucocytes which have entered from surrounding vessels and take on various forms; some round, some stellate and spindle shaped with one or more nuclei and long filiform processes, other again have one or two vacuoli, from one to three nuclei and varicose processes (Schwalbe). It physically consists of water 98.0% with salts, extractive matter, and a trace of albumen. A canal runs through its centre, between the crystalline and the optic nerve, which is lined by the hyaloid membrane and during fœtal life contains the hyaloid artery (canal of Cloquet). The posterior end of the canal equals in area the optic nerve and may be injected from its sheath. It is called the area of Martegiani. Where it touches the capsule of the lens the hyaloid membrane adheres to its margin and not to its centre. The corpus vitreum has neither blood-vessels nor nerves, yet it must be recognized to be an organized structure, because of the cells which it always contains.

Hyalitis.

In the fœtal eye the arteria centralis retinæ sends a branch forward, through the canal of Cloquet to the posterior surface of the lens. Sometimes this vessel persists after birth. I have seen it remain in each eye. It may approach very near the lens or may

Digitized by Illinois College of Optometry

extend into the vitreous but a short distance. Occasionally a little remnant of it, occluded and shrivelled, projects from the optic papilla like the tip on a gooseberry. The Fig. 206 shows a very marked persistent hyaloid artery. No attendant vein ever occurs.[1]

There are numerous morbid conditions to be seen in the vitreous, consisting of opacities of various kinds, some mobile and others fixed, and which may either be seen as individuals or be so diffused as to render it hazy, or deeply opaque, and sometimes it is absolutely black. We find distinct membranes, loops of blood-vessels, and sometimes pus. The substance is liable to be rendered perfectly fluid, either at its anterior or posterior part, or as a whole. Sometimes it contains cholesterin, or tyrosin and phosphates. When fluid, its state is called synchysis, and if there be cholesterin in addition, the name is given of *synchysis scintillans.*

If we look at a bright surface through a pin-hole in a card, numerous semi-transparent bodies of rounded, elongated, or beaded shape, will float before the eye. They are called *muscæ volitantes.* They consist in part of mucus and epithelium, falling down over the cornea, as the movement of the lids will demonstrate, and they consist also of specks in the aqueous or vitreous humors. The vitreous is liable to be detached from the retina, and the space to be filled with fluid. It may, too, contain connective tissue, which may adhere to the retina and undergo contraction, and draw the retina from the choroid. If occupied by much fibrous tissue, it shrinks and forms a small mass, such as we find in phthisis bulbi. We have hemorrhage into the vitreous from the ciliary body, which will be found close to the lens; or, coming from some other source, it may occupy any portion of the mass, or the whole of it. Sometimes hemorrhage occurs in the "canal of Petit" alone.

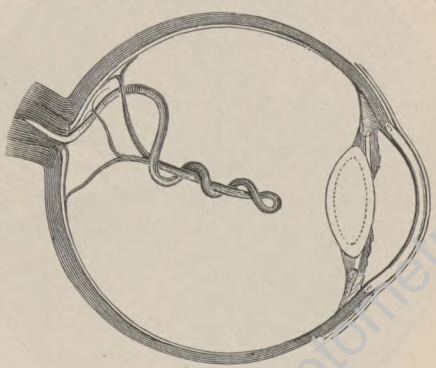

FIG. 206.

Although destitute of blood-vessels, we are justified in ascribing to the vitreous inflammatory capability, because of the cells which it contains. These undergo multiplication, manifold changes of form, and degeneration. They are depicted by Wedl and Bock[2] and by others. We find pus in it, in quantity more or less abundant, either localized or diffused. It frequently has a traumatic origin, and may proceed either from the ciliary body or the choroid. If diffused through the whole in moderate amount, the color

[1] Tangeman, Arch. of Ophthal., vol. xvii., 3, p. 270.

[2] "Patholog. Anat. des Auges," Atlas, Figs. 78, 79, Wien, 1886.

Digitized by Illinois College of Optometry

is greenish, if more copious it will be yellow. Sometimes with a clear lens and cornea a mass of pus will closely simulate a tumor, and the diagnosis from glioma may demand close observation. We find suppuration as the product of metastatic choroiditis, after cerebro-spinal meningitis, after relapsing fever, or after traumatic choroiditis. The inflammatory mass may be slow or rapid in its formation; if slow there may even be blood-vessels visible upon it. Schnabel [1] reports a case of suppurative hyalitis without choroidal lesion. We most frequently meet with it in suppurative panophthalmitis. The doctrine of germ infection explains the nature of the process.

Certain forms of inflammation of the optic nerve, retina, and choroid are accompanied by lesions of the vitreous. For example, the so-called retinitis proliferans [2] presents membranes and blood-vessels running from it into the vitreous, and they may also start from the optic nerve (see Fig. 207). In choroido-retinitis pigmentosa, pigmented spindle cells sometimes extend into the vitreous, especially at its anterior part. The hyaloid membrane may become adherent to the retina, and in cases of disseminated choroiditis it may adhere to the spots of exudation. Iritis and cyclitis are always attended with haziness of the vitreous. In syphilitic choroido-retinitis the vitreous will always be obscure, but sometimes it is densely filled with floating flakes, and it may be so black as not to permit any reflex to the ophthalmoscope. In senile cataract it is common to have isolated opacities, and sometimes a slight diffused turbidity of the vitreous. Fluidity of the vitreous, especially in its posterior part, and likewise at any part, is common in myopia, and there will also be floating shreds. It likewise occurs in many other lesions, which are mostly choroidal or cyclitic.

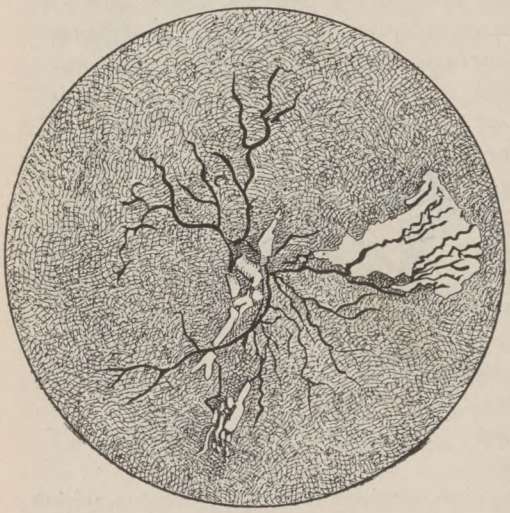

Fig. 207.

Foreign bodies may find lodgment, and the cysticercus cellulosæ here takes up its abode. The parasitic intruder has been seen chiefly among the inhabitants of Northern Germany and very rarely in this country, because our people are not much addicted to eating preparations of raw pork.

[1] Arch. of Oph. and Otol., vol. v., p. 172. [2] Manz: Graefe's Archiv, xxii., 229, 1876.

Digitized by Illinois College of Optometry

Portions of vitreous prolapsed into a wound, whether of the cornea or sclera, will sometimes retain transparency for a period, but they afterward acquire opacity or are converted into a grayish shreddy substance.

Diagnosis.—Diffused and slight turbidity is liable to be overlooked and the abnormal look of the fundus ascribed exclusively to inflammation of the retina and choroid. Usually this co-exists, but there will be lack of distinctness of all detail, especially by the upright picture, and if with feeble light and particularly from a plane mirror a strong plus glass be used, say 15 D, the minute specks will be found which denote the lesion. Seen through the haze, the optic nerve is almost always a deep red and the inverted image may be required to get any view. The deeper the opacity the more intense must be the light, and one may employ a concave mirror of large aperture and short focus in special cases. In acute iritis and other inflammations, in certain types of syphilitic choroiditis and also in hemorrhage, it may be impossible not only to see the fundus, but even to get any reflex from it.

Isolated opacities appear at any portion of the vitreous, but most numerously at its anterior and at its posterior part. If near the axis of sight, they produce annoyance and sometimes alarm. They are extremely common among myopes. An observer will not always be able to find the special one which distresses a patient. Large and dense ones will be seen by the inverted image, the smaller and thin ones must be looked for by feeble light, and with the help of a convex lens behind the mirror whose focal length will be shorter in proportion to the nearness of the object to the crystalline. Those in the front of the vitreous will be seen with a lens of + 15 D to + 18 D, provided the observer is in close proximity to the eye. The farther away he moves the greater becomes the power of the lens which he may be using. Hence the observer's distance from the eye and the strength of the lens he uses, must both be regarded because they are correlative. One will have to change his distance and his lens in order to search the vitreous thoroughly; the deeper the object the weaker must be the lens. For myopic eyes the lens will often need to be concave, and a quick succession of lenses is desirable (hence the value of rotating discs bearing correcting lenses). A patient will be told to look up and down quickly and in various directions, and the movement will perhaps fling specks, threads, membranes, etc., across the field. The inspection of a persistent hyaline artery gives a pretty exhibition of the practical side of physiological optics, as one passes from the optic nerve forward to the terminus of the vessel, continually increasing the strength of the lens which serves for the upright image.

Chronic or subacute plastic exudation in the vitreous which fol-

Digitized by Google

lows cerebro-spinal or simple meningitis, relapsing fever, etc., presents sometimes great difficulty in its diagnosis from glioma. The condition has on this account been called *pseudo-glioma*. The plastic exudation may have visible blood-vessels, may be intensely white and exhibit precisely such appearances as characterize glioma. At the same time the media may be perfectly clear. There may not be any pupillary adhesions or signs of iritis. The presence of these signs is in favor of the inflammatory origin of the mass, and a slight discoloration of the iris is not to be overlooked, yet glioma may likewise set up iritis or cyclitis. Our chief reliance in diagnosis is upon the previous history; that there has been an injury of the face or head, and this may have been six months previous, or that there has been an illness involving the brain or its membranes. Searching inquiry must be made on this point. Also endeavor to find whether there has been slight hyperæmia of the eye at an early stage of the trouble. Children are the most frequent subjects, and imperfect observation on the part of parents may add to the doubt. Slight reduction in ocular tension favors an inflammatory product. In all cases the lesion appears without pain, and the subject does not for some time become aware of the loss of sight. A preceding sickness or injury and early although faint tokens of inflammation, point to an exudative process, while the absence of such a history and of all inflammatory signs, until a late period indicate glioma. It may happen that both eyes are involved, yet oftener after inflammation than from glioma.

Treatment and Prognosis.—For single or a few opacities, no treatment is to be given, while if they appear in quantity in a myopic eye, which likewise has considerable choroidal change, they call for admonition as to strain of eyes and general hygiene and perhaps for treatment. They will not, in many cases, really disappear, but may float into some other position, where, being eccentric, they will not give annoyance. Of course they imply that the vitreous in which they float is liquefied. Many persons with normal eyes entertain some floating bodies in the vitreous for years without the slightest detriment, and they call for no attention.

Diffused haziness may be manifestly associated with other lesions, viz., of the iris, ciliary body and choroid and not call for special attention. In some instances the concomitant uveal affection is not discoverable, and we adopt treatment precisely such as this condition would indicate.

The primary disease will be the subject of treatment, but the attendant hyalitis will call for a longer continuance of remedies than would otherwise be adopted. In the early stage of cataract it is a common experience to have opacity of the vitreous. I usually order iodid. potas., gr. v., ter in die for two or three months, and

Digitized by Illinois College of Optometry

have been impressed with the conviction that thereby its transparency was promoted. I certainly have seen the vitreous grow clear, and vision improve. There are cases of soft cataract in persons above twenty-five which are attended by a great amount of hyalitis. For them extraction by Graefe's method is the best treatment, and in time the vitreous opacities may clear up. I have witnessed both their persistence and considerable disappearance.

For hemorrhage, the artificial leech may be applied to the temple from one to three times at intervals of five days, and salines given either as mild purgatives or as diuretics. In any event, weeks or months will be required for absorption if the quantity be large and deeply situated. I have seen a hemorrhage in the front of the vitreous, and which also showed in the anterior chamber, and therefore came from the ciliary body, entirely disappear in two weeks. The patient must, during the first ten days or two weeks, if not longer, be kept in moderate darkness, in bed, or in his room. It may be advisable to use a bandage.

For the dense opacities which occur in secondary syphilis, whether with or without choroiditis, iod. potas., and mercurials, *i.e.*, mixed treatment, in whatever special method, is to be steadily kept up and supported by all that the patient needs to aid his nutrition. In such cases, though at first discouraging, the prognosis is at least measurably good and may be entirely favorable.

When distinct membranes appear there is usually no probability of improved sight, and this is the more likely when accompanying choroiditis can be seen. If the tension of the globe begin to grow less, the outlook is certainly bad. In the so-called retinitis proliferans, membranes in the vitreous may be an early symptom and may be adherent to the retina or the optic nerve; spots of choroidal atrophy come, and the vitreous opacities continue but little altered Blood-vessels may be developed, extending from the vessels of the retina or nerve.

Suppuration, when of the acute type, needs no remark, nor is it any more curable in the subacute varieties, but it often raises the question of enucleation, because of the resemblance to glioma. Even in cases where the inflammatory nature of the process seems clear, removal of the eye may be advisable, because of cyclitic irritation and tendencies to sympathetic trouble. In the absence of tenderness about the ciliary region, and of inflammatory reactions, there need be no recourse to such an extreme measure. Often we may be obliged to hold our judgment in suspense, not having sufficient data for an opinion. Of course prudence will incline to enucleation, when the evidence is uncertain; because an early operation may save the patient's life if a glioma exists, while delay destroys

Digitized by Arizona College of Optometry

the chance; if a mistake be made, the loss of a sightless eye may well be condoned in view of the alternative possibilities.

Persistence of the hyaloid artery is not often seen, and there may be more or less of the vessel preserved. It may reach only a short distance from the optic nerve, or it may advance to the posterior surface of the lens and spread into several twigs. Usually there is no blood visible in it, but parts of the vessel may be very dark as its curves present to the light; most of it is semi-transparent (see Fig. 206, p. 513). In a case presented to the New York Ophthalmological Society by Dr. Kipp, of Newark, New Jersey, a complete hyaloid artery was visible in each eye.

Foreign bodies in the vitreous have already been spoken of. If recent, they should be extracted, if this be feasible, by a hook or by a magnet. If suppuration have begun about them, the attempt at extraction may be admissible, but if they cannot be withdrawn, the eye must be enucleated or eviscerated.

Cases have been seen where a minute foreign body has resided for years in the vitreous without doing mischief, but they are very rare. A cysticercus cannot remain without giving rise to inflammation and destruction of the eye. If it be recognized in the vitreous, it must be removed. A large wound not less than eight millimetres long must be made in the sclera at the point most suitable, preferably in the infero-temporal oblique meridian and the knife made to divide the vitreous up to the animal. Hirschberg insists on free division of the vitreous as essential to success. With forceps it will be extracted. The operation may sometimes be done by the help of an ophthalmoscope fastened to the surgeon's head.

NOTE.—In the occasional cases in which the vitreous is densely black and no illumination is possible, one may employ a concave mirror $3\frac{1}{2}$ inches diameter and 4″ focus with a convex lens of 6″ focus behind it, and obtain sufficient reflex to display membranes, a detached retina, and other lesions. After wounds and injuries such aid is often desirable, and occasionally is in idiopathic cases.

Digitized by Illinois College of Optometry

CHAPTER XIII.

WOUNDS AND INJURIES OF THE GLOBE.

A GENERAL subdivision of traumatisms of the eye is into contusions, simple wounds of various kinds, wounds complicated by the presence of a foreign body, and burns.

Contusions sometimes cause laceration of the tunics, perhaps all of them or only some of them; for example, we have separation of the iris from its periphery (irido-dialysis, see Fig. 208), we have rupture of the sclera, most frequently in the ciliary region and either complete or partial; it may be complicated by a retrocession of the iris, as in Fig. 209; we may have rupture of the retina or of the

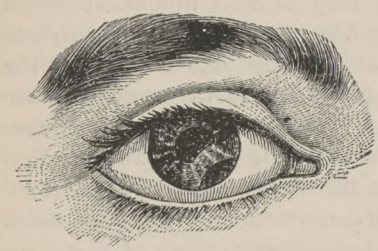

FIG. 208.

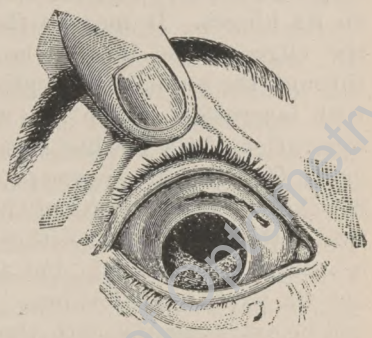

FIG. 209.

choroid. The lacerations of the deep membranes happen by counter shock, and are usually in curved lines and may be multiple. Complete extrusion of the globe beyond the palpebral fissure may be caused by a blow; a kind of paraphymosis.

In a case of this kind produced by falling down-stairs and striking the head against the banister, the eyeball was extruded, and the sclera ruptured. Ether was needed to overcome spasm of the lids and replace the globe in the orbit, and to retain it the edges of the lids were pared for their external third and stitched together.

Contusions of less severity cause hemorrhage beneath the conjunctiva, or into the aqueous or vitreous chambers. Effusion of blood under the conjunctiva alone, calls for little treatment; effusion into the anterior chamber will often be promptly absorbed, yet

Digitized by the College of Optometry

evacuation by a broad needle will sometimes be advisable; effusion into the vitreous is tardy in disappearing, seriously impairs vision, and is little amenable to treatment. It is naturally often impossible to decide whether a serious laceration of any of the tunics attends the bleeding, until absorption has taken place. Besides clots in the vitreous which will appear black, there may be imperfect membranes, and there may also occur fleecy white clouds of exudation, of a delicate flocculent appearance, and probably coming from the retina or choroid, which are more or less fixed in locality and of rare occurrence. Often a slight dialysis of the iris will be revealed, or a rupture of the choroid near the macula lutea. Often the blood comes from the ciliary body, which is beyond our scrutiny, and happily absorption goes on in this vicinity more rapidly than from the deeper part of the vitreous. Through a wound in the sclera I have known the iris to be extruded and withdrawn *in toto* from the eye. The lens was not disturbed.

Luxation of the lens, partial or total, and even its complete extrusion from the globe may occur. If only a part of the suspensory ligament is torn, the lens will flutter, swinging like a shutter on its hinges. It may be thrown backward out of its fossa into the vitreous, and it may be thrust forward partially or wholly through the pupil. Its displacement may or may not be attended with laceration of the iris, while, on the contrary, even complete separation of the iris has been observed without disturbance of the lens. Cataract may ensue promptly, generally tardily, or not at all. See chapter which treats of the lens. Severe blows may cause fracture of the orbit with or without contusion of the globe, but the lesion is rarely at its margin, but involves its sides, especially the roof and the parts near the apex. The optic nerve may suffer, and there will be extravasation into the orbit, but consideration of these injuries will be reserved to the chapter on the orbit. Laceration of the conjunctiva sometimes calls for a suture. A scratch of the cornea as by the finger-nail of a child causes exquisite pain, for which cocaine freely used will be the chief remedy, and most effective if mixed with vaselin: to this add hot fomentations, and closure by a bandage until the epithelium is restored. Severe contusion may cause opacity, or even laceration of the cornea. Injuries by small bits of stone or iron, etc., are the frequent cause of suppurative keratitis. Spasmodic contraction of the pupil which will resist strong and frequent instillations of atropine is sometimes observed after a blow on the globe.

It is needless to try to enumerate the methods of contusion of the globe, and the kinds of missiles which produce it. Among the frequent causes are blows by sticks, by toy arrows, by the cork from a soda or champagne bottle, by the head of a bolt or rivet

Digitized by the Internet Archive

struck off by a hammer, by the fist or by the thumb in the attempt to "gouge" out the eye, by the horn of a cow, etc.

The general principles of treatment will include rest, cold lotions, in very sensitive persons hot lotions, in some instances atropia or cocaine, and prognosis must be guarded if there be much intraocular hemorrhage.

Wounds of the globe have different effects according to the nature of the instrument, their position, extent, and depth. We first rehearse what is to be said respecting wounds not complicated by the presence of a foreign body.

A cut of the *cornea* with a clean instrument heals promptly under a bandage; with a rough or infected instrument more reaction and probably suppuration will follow. If the iris prolapse it may sometimes be replaced and held in position by frequent use of eserine. Usually it must be excised and pains taken to prevent adhesion to the cornea. Successful abscision may be feasible a week or even ten days after the injury. Seize the iris by opening the forceps along the length of the wound and include the overlying exudation of lymph, or first pull off the new tissue and fully expose the hernia; draw gently and loosen its attachments and when cutting it, lay the flat of the curved scissors close upon the cornea. If excision is not complete, the forceps may be carried within the wound to search for adherent iris. If from long continuance the exudation has been organized, an iridectomy may be done on one side or both sides of the prolapse by a small lance knife. Or the synechia may be divided by a Graefe's knife, which shall transfix the iris as it makes a peripheral corneal cut. In some instances Wecker's forceps-scissors introduced from the side opposite the prolapse will divide both the iris and even dense bands of fibrous tissue which may have formed. The dangers consequent upon *prolapsus iridis* increase with its extent, and with its nearness to the ciliary region. Traumatic prolapse is more dangerous than anterior synechia resulting from inflammation and perforation.

A wound through the limbus and extending into the ciliary region demands abscision of all the tissue which presents. If it be very extensive and the wound gape, the edges of the sclera may be united by fine sutures, even though there be prolapse of vitreous. The needle must be curved and very sharp, and with one at each end of the thread it may be carried from within outward and be less liable to cause increased loss of vitreous. Sutures are not always required for wounds of the sclera. If a flap is formed it may heal well under a pressure bandage. The eye must be carefully washed with antiseptic fluid, all clots and foreign substance removed and the cotton pad be kept moist with sol. corrosive sublimate. Use atropine in 1% solution. Disturb the eye as little as possible.

Digitized by the Internet Archive in 2009

There will be more or less intra-ocular hemorrhage, which will absorb slowly from the vitreous, much more rapidly from the aqueous. Prolapsed vitreous must be excised: it invites infection.

Wounds in the ciliary region are of course more serious in their possibilities than if elsewhere. But I do not concur in a prevalent opinion that in such cases no attempt should be made to save the eye lest sympathetic ophthalmia attack the other. On the contrary, with aseptic wounds and notably if made by pieces of glass, I have many times saved useful vision in the damaged eye. One may wait to observe the kind of reaction set up and whether healing takes place kindly. Moreover the trustworthiness of the patient

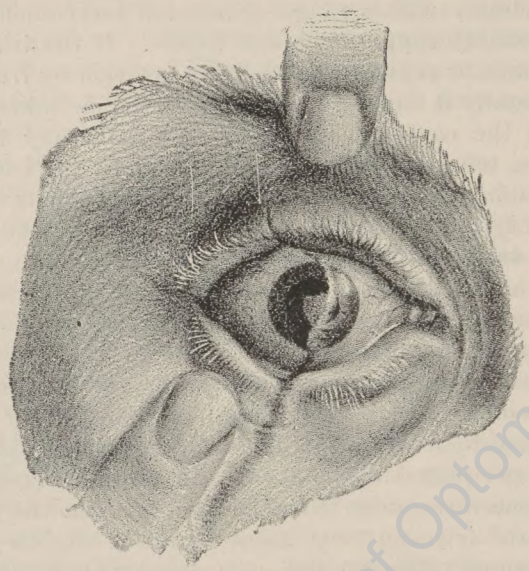

FIG. 210.

and his accessibility to good surgical help in case of trouble will determine, in many cases, the course adopted.

Penetrating wounds involving the crystalline, cause cataract and perhaps luxation of the lens. Reaction will often be severe and in proportion to the degree and rapidity of the swelling of the lens substance. There may be plus tension and the iris be pushed toward the cornea. A wound by a pin often causes grave inflammation (probably because of septic taint). Besides atropia, paracentesis, with partial evacuation of the lens, and often in combination with iridectomy, will be promptly resorted to if the symptoms are urgent. (See remarks upon traumatic cataract.) See Fig. 210, in which a razor cut through eye and cheek caused opacity of the surface of the lens which did not extend deeper for many months.

Digitized by the College of Optometry

Extensive lacerations of the globe with copious loss of vitreous, internal hemorrhage, and collapse of the eye, will usually be best handled by prompt enucleation. If any attempt be made to save the organ, not its function, a long-continued treatment must be expected. The object to be gained will be to avoid mutilation and to secure a better nidus for an artificial eye, but the risks of sympathetic inflammation are not to be forgotten. The civil status and occupation of the patient have an important bearing on the course to be pursued.

Wounds complicated with the presence of foreign bodies come next in order.

When upon the cornea, their removal since the introduction of cocaine has become very simple. A lance-pointed needle, curved on the flat, one intended for displacement of cataract (Scarpa), is often better than the usual spud; it will better dig out the soft portions of ignited steel (sparks) which workmen often receive from a grindstone. A larger body may be taken off with fine forceps, and a better grip is gained if their teeth stand forward. A few fibres of cotton upon a match, or a stiff hair used as a loop, will sometimes sweep off a small particle.

The under surface of the upper lid is a favorite place of lodgment for specks and cinders; eversion brings them to view, or they may come off by pulling the lid from the cornea. Foreign bodies entangled in the ocular conjunctiva cannot always be picked off, and one may have to snip out a little of the membrane with them. Powder burns when fresh are attended with more or less reaction, and the black particles will to a certain degree spontaneously come out, but such as are imbedded must be patiently picked out with a needle, and they often lie so deep as not to be perfectly removable from the sclera or conjunctiva. The material is soft and pasty. Accidents which happen when blasting rock, are naturally more serious than simple powder burns, of which boys are the most frequent victims.

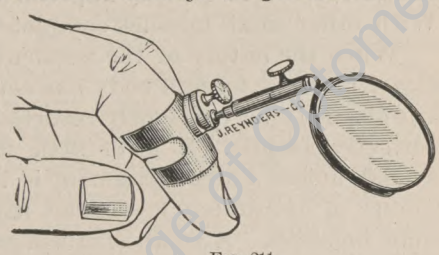

Fig. 211.

In all these manœuvres a condensing lens to illuminate the eye is almost indispensable. It may be carried upon the index finger which lifts the upper lid and pushes it into the orbit (see Fig. 211). The surgeon stands behind, and supports the patient's head against his body, his left hand controls both eyelids by the index and ring fingers and the middle finger can steady the globe.

Foreign bodies within the eye present a serious complication.

Digitized by Illinois College of Optometry

A sliver of iron, a piece of percussion cap, a splinter of wood, or thorns from a chestnut burr, may transfix the cornea and require delicate use of fine forceps, or possibly necessitate an opening at the margin of the anterior chamber, to extricate them. The question of what to do, will be decided by the size and nature of the foreign body, by its position, and the mischief it has inflicted. We must first find out, if possible, whether it has entered the globe, and whether it is lodged within it. Minute fragments of metal, chips from a hammer, will sometimes leave very faint trace of entrance, especially in the sclera or at the limbus. We must look for a scar on the cornea, or wound in the iris, or opacity of the lens. The ophthalmoscope as well as the condensing lens will be required. The visual field must be tested for limitation or scotoma. The pupil must be dilated and the interior inspected carefully in both oblique and axial directions. The object may be in the anterior chamber and if loose may drop to the bottom quite out of sight. It may then be brought into view by pushing a little water to the edge of the cornea by the lower lid. In the lens it will sooner or later cause opacity, perhaps swelling. Avoiding the lens it may remain at its place of entrance, it may cross and stick on the opposite side of the globe, it may be thence reflected and fall to the bottom of the fundus, it may be suspended in the vitreous, it may lodge in the optic nerve. Bird shot may lodge within, or go entirely through the globe; it is frequently impossible to decide which has happened. With other small missiles complete transfixion is the exception.

When the nature of the accident and the size of the wound indicate that the foreign body has considerable size, exploration with a probe may be cautiously resorted to. The instrument must be perfectly aseptic. It is of little use to enter much beyond the wound, unless a large fragment is likely to be met. Then the possibility of extracting it without sacrificing the globe may justify some boldness. A small strabismus hook is useful for examining the vicinity of the wound of entrance. Such exploration must be employed only when the foreign body is rather large.

Prognosis is always serious, the injury is frequently fatal to the eye, and in many cases the opposite eye is liable to sympathetic inflammation. The eye may recover from the immediate effects of the traumatism, and perhaps retain a degree of sight. For a period it will be tranquil, but at length slow and subtle processes of inflammation are set up. This is especially probable when the foreign body is lodged in the ciliary region. It may not have had this situation from the outset, but have stuck upon some other part of the interior surface, and in time been loosened and dropped to the bottom of the eye and set up irritation (Berlin). The eventualities possible after cyclitis have already been referred to.

Digitized by Harvard College Library

These remarks apply to cases where the foreign body penetrates behind the lens. If it is arrested in the lens or in the iris, prognosis is more favorable, because it is more accessible to removal. In general it is to be stated that the residence of a foreign body in the eye imperils its safety sooner or later, and may endanger the other one. Exceptional cases occur, of which I have seen several, in which a small foreign body has kept its position without damage to the eye for a very long time. For example, in the iris a bit of iron has to my knowledge remained innocuous for nineteen years. I have seen one suspended in the middle of the vitreous and another imbedded on the temporal side of the fundus. A number of times I have seen them adhering to the bottom of the eye, by the ophthalmoscope. There are many cases of immunity recorded, but they are greatly in the minority, and because rare are put on record. The size, the situation, the nature of the foreign body, and the amount of harm inflicted give us the elements of prognosis. If reaction be notably in excess of what the size of a wound would justify, that is to be taken as evidence in favor of the entrance of a foreign body. The septic character of the foreign body is a most important circumstance and often determines the course of events.

Treatment.—The indication is to remove the foreign body. Sometimes this is not possible, sometimes it is not immediately advisable. A very small particle may lie near the rim or in some other part of the lens, and one may wait for reaction to subside before attempting an operation. If, however, its presence provokes or is likely to provoke severe reaction, it must be removed. The means of removal are forceps, a very small curette formed into a hook (Knapp) and for bits of iron, the electro-magnet. In a very large number of instances we have to deal with iron, and the electro-magnet has become of great importance. The larger the tips the more powerful will they be. If, however, the bit of iron is caught in the tissue, it will not yield to the magnet unless near it or in actual contact. For this reason, one may fail in spite of a correct proceeding and notwithstanding the magnet has plenty of force. It has been shown that a great excess of power is necessary. The first effective employment of this method was by MacKeown, of Belfast, in 1874. I have employed the apparatus of Bradford and of Hirschberg, and because the tips belonging to the latter are larger, I prefer it.[1] It is not easy to determine where the foreign

[1] Dr. Gruening employed a cluster of permanently magnetized steel rods. See N. Y. Medical Record, May 1st, 1880. Dr. Bradford published in the Boston Medical and Surgical Journal, March 31st, 1881, the use of the electro-magnet. Hirschberg had an instrument made for this purpose in 1877. See "Der Electro-Magnet in der Augenheilkunde," p. 9, Berlin, 1885.

Digitized by Internet Archive

body is located. The attempt to localize it by a magnetic needle (Pooley) has not been satisfactory. Before introducing the instrument one must feel satisfied that the foreign body is iron or steel. As a rule when the accident happens while chipping stone, the penetrating missile will be a piece of the hammer or chisel and not of the stone. If the wound be large, say more than two millimetres long, and recent, one may enter through it, perhaps enlarging it, and preferably in a way to make a small flap. There is no objection to exploration by a probe, and the best is a very small strabismus hook, but it must not go deeply. A free aperture is requisite to prevent the foreign body being stripped off the tip as it comes out. If the wound has healed, one may choose to enter at a spot diametrically across the cornea from the point of penetration; small foreign bodies driven with force often hit the opposite side of the globe and either stick there or rebound to the bottom of the eye. One must take into account the probable direction of its flight, its velocity and its size, the position of the eye relative to its starting point and all the circumstances which may aid in localizing the place of lodgment of the missile.

If in the anterior chamber, or on the iris, removal by a wound at the limbus is usually easy. An iridectomy will not always be necessary. If in the lens, one must remove both the lens and the bit of iron. A lance knife may be made magnetic by contact with the point of the electro-magnet and be made doubly effective. The proceeding may be simply that which is ordinarily resorted to for linear extraction, or if the foreign body do not appear, the magnet point may be introduced. Here caution must be used because loss of vitreous is prone to occur and thereby seriously diminish the chances of preservation of sight. If the reaction caused by the injury compels the speedy removal of the lens, it is not always wise to attempt at the same time to secure the foreign body. One may await developments and be governed by the subsequent symptoms. The eye may become quiet, or if it continue irritable or at a late period irritation arise, an attempt may be made with the magnet, and in the event of failure to capture the offender, enucleation may follow.

It is when a bit of iron has entered the vitreous that we realize the magnet's great advantage. Salvation of sight may not be frequent, but preservation of the globe can be often secured. Strict antisepsis must be observed; the eyeball, the magnet points and the hands well washed with corrosive sublimate solution. It is advisable to give an anæsthetic. If a fresh wound is to be made, it should be placed in the interval between the recti muscles meridionally and behind the ciliary region; usually it will be at the infero-temporal side. It may be about eight millimetres long. The knife must

Digitized by the Cornell University

penetrate the vitreous deeply and must be aimed to hit the foreign body. The substance of the normal vitreous is an obstacle to the movement of the bit of iron, and, on the other hand, it may have been more or less liquefied by clots or inflammatory effusion. Put in the magnet, and when it is near the foreign body, press the button which lets on the current and hold it in position for a few seconds. The attractive power is strongest at the moment when the current begins to flow. Very carefully withdraw, and as the tip is flat turn it transversely to the wound and the iron if captured will come out on its point. Sometimes a click is felt as the iron jumps to the magnet. If the first effort fail, try again, varying the direction. In desperate cases, the magnet point may be moved about within the eye searching for its prey. It is surprising how little reaction is caused by pretty free manœuvres, provided the rules of antisepsis are rigidly enforced. Naturally the free churning of the vitreous damages or destroys the chances of vision, and if sight is to be hoped for, the magnet must be handled with great delicacy, be nicely balanced in the hand, and pass in and out on a direct course. Failure to get the iron necessitates enucleation.

A man came under my care who three months before had received a bit of iron in the globe, and the eye had recovered. A second fragment penetrated the same eye, and I proposed to remove both with the magnet, and operated with the understanding that if two bits of iron were obtained the eyeball should be spared; if only one or none should be gotten, enucleation should ensue. This course was taken because the eye was certain to be sightless, and extremely prone to cause sympathetic inflammation. One small particle was brought out and diligent fishing failed to get the other, and the eye was taken out. Only after a long search was the second fragment found sticking in the optic papilla. It was covered by exudation, and so well concealed that there was strong reason for belief that this was the first piece which had entered the eye, and a three months' residence in the head of the optic nerve had not given rise to any symptoms in either eye. The piece was found by using the magnet as a searcher as the half of the globe floated in water, and was attracted to the magnet.

When success has followed the operation, the eye will be bandaged and kept quiet for several days before renewing the dressings. Two to four weeks may suffice for healing. It cannot always be asserted that the eye will afterward be free from risk of trouble, on the contrary, we may be compelled to remove it in some instances; but such disappointments are exceptional. The globe may not in all cases preserve its proper form, but shrink through chronic inflammation, especially if a patient exposes himself too soon. Yet on the whole we are enabled by the magnet to rescue some eyeballs, possessing more or less vision and they are always preferable to counterfeits. We likewise diminish the number of cases of the

deplorable disease, sympathetic ophthalmia. Hirschberg (Graefe, *Archiv*, XXXVI., 3, p. 37, 1890) sums up 100 cases, of which 65 were vitreous operations. In 24 the magnet was used simply for exploration. Of the remaining 41, 7 gained permanent sight of various degrees, 6 preserved the form of the globe, 28 had enucleation for various reasons, either because of the great size of the piece or suppuration or failure to extract. The 24 cases of exploration resulted thus: in 6 perfect sight, in 4 some sight, in 5 preservation of the globe, in 9 enucleation. Prof. H. shows no undue disposition to avoid enucleation when it is indicated, while he gives the patient the benefit of a chance. Out of the 65 vitreous cases 37 had enucleation = 57%. His example is worthy of imitation. See cases by St. John, Trans. Am. Ophth. Soc., 1891, p. 70. Consult a paper by Neese[1] founded upon cases taken from Horner's clinic and upon others recorded in literature. Referring to the use of the magnet in the deep part of the eye he says (l. c., p. 361): "Of the 154 cases known to literature, a more or less satisfactory visual power was obtained in 47–48 cases = 30½%; while in 16 other cases, or 10⅘%, almost normal acuteness was attained. The form of the globe, without sight, was preserved in 27 cases, 17½%. Whether the cosmetic results thus obtained were satisfactory or not is questionable, but this seems to have been the case with twelve of the patients. Four other cases were not followed up, and it is not known whether enucleation was necessary at a later period. In 16 cases subsequent enucleation was inevitable = 10⅘%. Finally, in 54 cases = 37% the magnet did not capture the foreign body." Hildebrand (*Archiv für Augenheil.*, Bd. XXIII., Heft 3, 4, 1891) reports 66 magnet operations—15 times for bits of iron in lens and anterior parts of eye; 51 times in parts behind the lens. All the 15 cases except one did well. Of the 51 vitreous cases, in 13 the attempt failed. Of the 38 cases in which the foreign body was extracted, in 16 good or useful vision was permanently secured; in 6 the form of the eye was preserved; in 7 the globe shrank; in 2 enucleation became necessary; in 6 the ultimate result was unknown (1 case not accounted for). Hildebrand gathered together 328 cases of magnet operations, including his own, of which 80 involved the anterior part of the eye, and 248 the deep part. Of the 80 cases 67 resulted well. Of the 248 vitreous cases, in 74 the attempt failed. In 174 the iron was extracted and with following results: in 62 useful sight secured; in 29 the form of eye preserved; in 23 phthisis bulbi followed; in 26 enucleation became necessary (34 cases not accounted for).

The condition of the eye when wounded by shot is somewhat peculiar. Bullet wounds call for no special remark, but wounds by fine shot show very little mark, yet their effect is disastrous. They

[1] Archives of Ophth., vol. xvii., 3, p. 341.

Digitized by the Internet Archive

often perforate the globe completely. They do not admit of extraction and to probe for them is inadmissible. Frequently reaction is not serious, and no treatment but ordinary care and management is required. If panophthalmitis take place, enucleation will most promptly arrest it. A shot may glance over the outer surface of the globe and yet destroy sight. The question of enucleation or other operation, viz., optico-ciliary neurotomy, is not always easy to decide. Such proceedings are by no means always imperative, yet a wise prudence must preponderate when opinion is evenly balanced. The uncertainties of these cases are well illustrated by an instance reported by Dr. Williams, of Cincinnati, where only one wound was to be discovered, while after removal, three shots were found. Very fine shot may leave absolutely no trace of their entrance.

In dealing with cases of foreign bodies in the eye, the most sagacious surgeons will sometimes be in doubt as to the course to be adopted. Sometimes it is difficult to convince a patient that a foreign body has really gained entrance. Among the valuable symptoms are reduction of tension, dimness of sight, a scotoma, or limitation of the field. There may be seen blood in the vitreous, or it may yield no reflex, or hemorrhage may be detected upon the retina. Except when the globe is badly lacerated, immediate enucleation is seldom done. If the offending body cannot be extracted and reaction be severe, the patient will usually be glad to be rid of his pain and his eye promptly; but if, as happens generally, the ensuing symptoms are moderate, the case may be kept under observation. When this course is pursued, the patient must be notified that he lives in a state of perpetual peril and much will depend upon his care of himself and watchfulness of symptoms, and his accessibility to competent advice. Not a little consideration is to be given to the intelligence, occupation, age, sex, and social surroundings, habits of life and residence of the patient. If a foreign body is in an eye, and at any period a degree of inflammation spring up, or, if there be marked tenderness over the ciliary or on any part of the globe, enucleation must not be delayed. My own inclinations are conservative; yet, so subtle are the inflammatory processes in the damaged eye, and often so little noticed are the early signs of sympathetic trouble in the fellow-eye, that the period of curability may glide away before a patient seeks advice, and, therefore, my decision has often been cast for enucleation, when there seemed little urgency for doing it. But one of the greatest triumphs of the oculist is when he discriminates correctly the dangers of an injured eye and by skilful treatment and wise forbearance preserves to the patient his precious possession of sight or eyeball.

Burns affect, of course, primarily only the surface of the eye,

Digitized by Harvard College Library

and the eyelids, and it is not necessary to repeat what has already been said (see page 278). The secondary results to the eyeball are, as has been said, adhesions, and sometimes internal inflammation, atrophy, and rarely the need of removal because of danger to the other eye. Besides the ordinary caustics and burning methods, I have seen two cases in which fulminate of silver and fulminate of mercury respectively destroyed the eye. The peculiarity of these cases was in the remarkable amount of opaque, brawny, coagulated effusion which covered the eye and infiltrated its tissues. One patient was a manufacturer of fireworks, the other prepared the explosive compound for rifle cartridges. The possibility of sympathetic inflammation, it must be remembered, is not excluded in cases of burns, especially by caustics such as lime.

Digitized by Illinois College of Optometry

CHAPTER XIV.

SYMPATHETIC OPHTHALMIA.

THE condition thus designated presents itself under two distinct forms, of which one is called *sympathetic irritation* and the other *sympathetic inflammation.* The term *sympathetic* excludes the agency of external contagion. It is a disease principally of the internal structures of the eye. Sympathetic *irritation* is clinically a neurosis, sympathetic *inflammation* chiefly affects some part of the uveal tract, and has been designated, according to its severity, as *uveitis serosa* and *uveitis maligna* (Brailey). But the optic nerve and retina are also involved, both primarily and secondarily, while the vitreous, the cornea, both on its posterior surface, and in advanced cases, its substance, are affected, and the lens may finally become opaque. So complex are the pathological conditions, that an accurate and complete description need not now be attempted. The disease is of the gravest importance, because in its more serious types it leads to blindness, and the prevention of this disaster is only to be obtained by early surgical interference.

The causes of sympathetic ophthalmia are both traumatic and spontaneous. An imperfect enumeration is as follows: traction of the iris by an ectatic corneal cicatrix (partial or total staphyloma); prolapse of iris at the corneal margin (cystoid cicatrix); sunken or puckered scars entangling the ciliary body; rupture of the globe; operations such as extraction of cataract when complicated by entanglement of the iris, or capsule, or succeeded by irido-choroiditis;[1] iridodesis; sclerotomy; wounds of the lens; calcified lenses; luxations of the lens, whether by accident or intentional as by the reclination of cataract; foreign bodies; choroidal tumors; cysticerci; ossification of the choroid; burns of the cornea; tattooing of the cornea (Panas); the irritation of an artificial eye; puckered cicatrix of the orbital tissues following enucleation. "Evisceration

[1] See Webster, "Sympathetic Inflam. following Operations for Cataract," Trans. Am. Ophth. Soc., 1880, p. 19. Becker, Universitats Augenklinik zu Heidelberg, 1888, p. 58.

Digitized by the College of Optometry

of the Globe" (Cross, Trans. Ophth. Soc. United Kingdom, 1887, p. 149); Schiess-Gemuseus, Jahresbericht, Augenheilanstalt in Basel, 1890, p. 48.

Lesions of the iris and ciliary body, and the presence of foreign bodies constitute the majority of causes. In many cases of entanglement of the iris or ciliary body, and sometimes when foreign bodies lodge within the eye, no sympathetic effects ensue. We do not know what is the producing factor in the one case, nor the reason of quiescence in the other. An elaborate clinical summary of the condition of 110 eyes which had caused sympathetic ophthalmia is given by Alt.[1] In such eyes we find almost every tissue the seat of degeneration, in different intensities and under diverse combinations, beginning with the cornea and going to the retina and optic nerve; it is impossible to designate all the pathological conditions which occasion sympathetic trouble.

Sympathetic ophthalmia is a rare disease. Ohleman reports that out of 556 severe injuries in Schweigger's clinic only 4 cases of this kind occurred. It is a most significant fact that it is extremely rare to find the disease unless there has been a perforation of the exciting eye. I have seen it follow a burn by caustic lime within one week, but such a rare occurrence is most exceptional.

The period of latency before the outbreak of sympathetic ophthalmia is commonly between three and six weeks; exceptionally it may occur within two weeks or less, and an interval of many years, twenty or thirty, is not rare. In Alt's table, three cases occurred within eight days; within two months, 36⅓ per cent; between two months and twelve months, 15.5 per cent; between one year and ten years, 22¾ per cent; between ten years and twenty years, 12 per cent; between twenty years and sixty years, 13⅓ per cent. We find the same causes give rise to either the neurotic or the inflammatory type, and the nature or severity of the injury bears no especial relation to the quality or severity of the sympathetic effect.

As a general fact it may be asserted that the irritative type may continue with interruptions for many months or years without essential change of character. Development of the irritative type into the inflammatory has by some been denied (Donders and many others), but to this is opposed the statement of Lawson,[2] who speaks of eyes with sympathetic irritation drifting into sympathetic inflammation; of Rossander,[3] who quotes several cases, and of various writers (Mauthner, Critchett, etc.).

---

[1] Archives of Ophth. and Otology, Nos. 3 and 4, 1876.
[2] Oph. Hosp. Reports, x., p. 2, 1882.
[3] Annales d'Oculist., lxxv., 301, 1876.

Digitized by the Internet Archive

A conclusive case is detailed by Dracoulidès, *Annales d'Oculist.*, July, 1892, p. 41. Twenty years a foreign body had been in the eye. The irritative symptoms in four weeks passed into irido-cyclitis and papillitis. A bit of iron in an osseous shell was contained in the globe, and the sympathizing eye recovered two months later under treatment.

The inflammatory type sometimes presents remissions and recurrences in the so-called serous cases; the plastic variety may begin as such or as a mild serous type and commonly advances steadily to destruction of the globe. To this rule there are exceptions, both with and without treatment.

But, in general, the *prognosis* is bad, and Magnus[1] declares that in proportion to the frequency of injuries among young subjects (viz., those under fifteen years) the number who are made blind by sympathetic ophthalmia is inordinately great, viz., 4.5%. Among eighty-eight patients who had lost one eye by injury, 81.6% incurred blindness of the second eye by sympathetic inflammation, within one year.

The *symptoms* of the irritative type are weariness or incapacity for use; photophobia and lachrymation, consequent reluctance to fix the eye. Vision is often normal or may be a little reduced. There is diminished range of accommodation; although Reich[2] reports a case of spasm of accommodation, and there is slight restriction of the field. The pupil is prone to be small, the media will be clear, and the optic nerve is often faintly congested and hazy. The intensity of the symptoms varies in different persons. As has been said, they may be suspended for long intervals, but they will recur and if permitted will continue for months or years.

The originating eye is generally, but not invariably, tender under pressure, especially in the ciliary region. It has been noted that a tender spot in this eye may answer in position to a similar tender spot in the fellow-eye. Tested by a probe or the tip of a pencil the pain excited is sometimes intense.

The symptoms of *sympathetic inflammation* vary according to the severity and stage of the disease.

In mild cases designated as iritis serosa, or uveitis serosa, there will be pale circum-corneal injection; the iris a little discolored, perhaps only in part, the pupil normal or slightly adherent and small, the sight a little reduced. There will be dots upon the posterior surface of the cornea, sometimes few and again abundant, and by the ophthalmoscope one or two pupillary adhesions may be seen and the media will be hazy. The optic nerve may appear red and in-

[1] "Die Jugend-Blindheit," Wiesbaden, 1886, p. 107.
[2] Annales d'Oculistique, lxxv., p. 14, 1876.

Digitized by the College of Physicians Library

distinct, but in some cases papillitis or unqualified neuro-retinitis has been seen (Williams, Pooley, Arlt, Spaulding, and by the writer). The symptoms may not become much more severe, and I have seen an eye thus affected completely recover its normal state without any operation upon the originating eye. A similar experience is given by Miles and Frost.[1] Such experiences are, however, very exceptional, because the disease, instead of retaining what may be called the serous type, is liable to take on the plastic quality. "Serous and malignant (plastic) uveitis are closely related anatomically as well as clinically" (Brailey). The affection is usually painless at the beginning. From an anatomical standpoint the sympathizing eye may be said to be affected by simple iritis, irido-cyclitis, irido-choroiditis, neuro-retinitis, etc. But more important is the discrimination of the quality of the inflammatory action, whether serous or plastic, so far as the uvea is concerned, while the retina and optic nerve will receive special consideration.

Equally stealthy in its onset is the plastic form of the disease. There will at the outset be little hyperæmia, but dots, soon becoming numerous, appear on the corneal endothelium, the iris will be discolored, pupillary adhesion will occur and soon involve the whole circle, while infiltration of the iris, turbidity of the aqueous humor, perhaps hypopyum, recession of the periphery of the iris, followed by shallowness of the anterior chamber as the iris and lens become firmly agglutinated and press forward, show that the plastic infiltration includes both the iris and the ciliary body; later, spots of atrophy of the iris tissue will often appear. The process may be more or less active, and the subjective symptoms of pain and lachrymation, loss of sight, etc., will correspond. The ultimate changes will involve the choroid and vitreous, the retina and optic nerve, as well as the lens. Usually a stage of increased tension, a secondary glaucoma, arrives, and the anterior chamber may be annulled, and the globe be both hard and painful to the touch. In some instances the cornea becomes hazy and vascular. There may be ciliary staphylomata. The vitreous becomes fluid. With the recession of glaucomatous symptoms the globe at a late stage becomes soft and perhaps phthisical. Sometimes the lesions remain chiefly confined to the anterior segment of the globe. After acute symptoms have long been stayed, the eye will often retain perception of light with occluded pupil and opaque lens. The tension is generally minus, even if the globe be enlarged, while it may also be reduced in size. After the lapse of years, the inter-palpebral portion of the cornea becomes the seat of a band of opacity affecting the superficial layers, which has been already referred to. At first

[1] Trans. Oph. Soc. United Kingdom, vol. iii., 63 and 73, 1883.

Digitized by Harvard College Library

it appears in small thin spots or specks, which enlarge and coalesce, and grow more dense without any sign of irritation, unless calcareous deposit becomes considerable (see page 410, *C*).

Much interest has been excited by cases of sympathetic neuro-retinitis without primary implication of the iris and choroid (see paper by Spaulding [1]). Cohn [2] gives a case of retino-choroiditis thus produced and also two cases of amblyopia without ophthalmoscopic lesion, all of which were cured by enucleation. The nerve lesion may become and usually will be complicated by uveal inflammation, but there can be no doubt that in some instances the onset of the disease is from this direction, and we must, therefore, resort for diagnosis to the ophthalmoscope. Alt [3] especially called attention to this circumstance, while Leber, Snellen, Deutschmann and others have insisted that here we are to look for the usual channel by which the disease is transmitted.

Among the more uncommon effects of sympathetic trouble are conjunctivitis (Webster [4]) which I also have met, and likewise keratitis, only relieved by removal of the exciting eye. Nettleship reports two cases of whitening of some of the cilia.

The lesions of the originating eye need not be severe, although as a rule it is tender to the touch, and may or may not be sightless. Panophthalmitis does not preclude the possibility of sympathetic effects. Herpes zoster ophthalmicus, which destroyed one eye by irido-choroiditis, has been the remote cause of the loss of the other (Noyes).[5] The cases which after the lapse of a long interval awaken the disease are commonly those of osteoid degeneration, or of foreign bodies in the eye. Shrunken and painful globes, that is, stumps which cause irritation, are always sources of danger. But a shrunken globe which is only painful upon deep pressure, need not be regarded with anxiety when no symptoms are present.

The pathological conditions of the sympathizing eye have not often been examined, while literature teems with recitals of the lesions of the exciting eye. Brailey has seen a few cases of the former, while as to the latter no advantage will be gained by rehearsing the particulars, which practically cover almost every pathological condition that inflammation can produce. The opportunities for examining the sympathizing eye are necessarily rare, but the lesions are similar to those of the exciting eye.

---

[1] Trans. Am. Ophth. Soc., 1883, p. 486.

[2] "Schuss-Verletzungen des Auges," Erlangen, 1872, pp. 26, 28, 29.

[3] Arch. of Oph. and Otol., vol. v., p. 395, 1876, and in Amer. Jour. of Ophthal., Nos. 1, 3, 4.

[4] Trans. Am. Oph. Soc., 1880, p. 22.

[5] Trans. Am. Oph. Soc.

Digitized by University of Illinois Urbana-Champaign Library

The mode of transmission of the sympathetic effect has been and is now greatly discussed. Clinical observation and physiological facts support the belief that the ciliary nerves and also the optic nerves can produce the result. Mackenzie,[1] 1840, assumed the optic nerve to be the path of transfer. H. Muller,[2] after examining eyes enucleated by Graefe in which he found inflammatory changes scattered at intervals along the ciliary nerves, pronounced in favor of their influence. His great ability as a pathologist caused the acceptance of this view, although he did not deny the possible agency of the optic nerve. Goldzieher[3] gives a careful examination of a case in which the ciliary nerves were deeply implicated, and illustrates it by plates. He also refers to experimental researches in nervous pathology by Niedeke, who produced lesions in the ischiatic nerves very similar in their interrupted localization to those seen in the ciliary nerves, and, in addition, the opposite ischiatic nerve was sympathetically affected; a parallel to the pathology of eye disease which has not been extensively recognized. Brailey says that he sometimes found the ciliary nerves normal and sometimes diseased. His examinations, as he remarks, were made chiefly in the long ciliary nerves, and were, therefore, incomplete. Microscopic examinations by Alt and experimental researches by Leber and Deutschmann have within late years argued in favor of the optic nerve. The last-named especially has attempted to show that cocci are the immediate carriers of the pathological process, and that they travel along the lymph spaces of the nerve sheath. He proposes to name the disease *Ophthalmia Migratoria*. He has succeeded in producing sympathetic neuro-retinitis in rabbits by septic inoculations. With difficulty and amid many failures, Gifford, Alt, and others have likewise succeeded, and in a few instances irido-choroiditis has been added to the neuro-retinal lesions. It is true that some good experimenters have failed to cause sympathetic ophthalmia in rabbits by any kind of injury, excepting by the injection of septic material (Donders, Alt, Randolph), but this does not prove what may or may not be possible in the human subject. Alt[4] publishes a case in which he confidently expected to find bacteria in the optic sheath, and states with much candor and regret that none could be found. Knies'[5] case of iritis serosa (spontaneous) in which lymphoid cells were traced along the nerve sheaths of both eyes as far as the

[1] "Treatise on Diseases of the Eye," London, 1840, p. 532.

[2] Arch. of Ophthal. (Graefe), vol. iv., 1, pp. 363-388, 1858.

[3] Monatsblätter für Augenheil., xv., 405, 1877.

[4] Amer. Journ. of Ophth., vol. iv., No. 2, p. 29. Various important considerations are set forth, both for and against the germ theory.

[5] "Bericht Ophth. Versammel.," Heidelberg, 1879, p. 56.

Digitized by Illinois College of Optometry

chiasm, may be accepted as proof that such migration may occur from one eye to the other, notwithstanding he omitted to examine the chiasm and cannot explain how the germs find their way in the cranial cavity down the sheath of the opposite nerve. The staphyloccocus pyogenes aureus and albus have been found in the sympathizing eye of rabbits whose other eye had been inoculated (Deutschmann). In 3 rabbits out of 25, Gifford, injecting bacilli of anthrax into one eye, found that they made the passage through the lymph spaces of the optic nerve and sheath by way of the cranial cavity to the second eye, before the animals perished by general infection. The remaining 22 were thus destroyed before transfer by the optic nerves took place. See discussion in the Trans. of the Oph. Soc. of United Kingdom, Vol. V., p. 71, 1885, and Report of Committee, *ibidem*, Vol. VI., p. 170, 1886. Experiments by Randolph [1] oppose the theory of germ propagation by the sheath of the optic nerve. It is safe to believe that both the optic and ciliary nerves can produce the lesion, and the agency of germs in propagation is highly probable, although not demonstrated to be the exclusive *modus operandi*. The outbreak of the disease ten to twenty years after the primary eye was lost, and when a calcareous lens, or osteoid degeneration, or a foreign body is the immediate exciting cause, cannot easily be accounted for on the germ theory. Becker gives an autopsy where no continuity of propagation could be found along the chiasm from one optic nerve to the other, and his view was in favor of the agency of the vascular system.

It must be admitted that belief in the bacteriological origin of true sympathetic ophthalmia is gaining ground. We naturally hesitate to place full reliance upon experimental data among the lower animals. A case by Schiess-Gemuseus, in his reports for 1890 and 1891, Augenheilanstalt in Basel, has almost the value of an intentional experiment (see p. 47, 1890, and p. 40, 1891). An injured eye in a woman, æt. 65, underwent suppurative irido-choroiditis, and exenteration was done. Patient was discharged practically well after eleven days. About twelve weeks later was readmitted because of slight sympathetic trouble in the other eye. This yielded to hot fomentations, atropine and mercurials, and notwithstanding an attack of influenza was discharged again after twenty-eight days. In two weeks more a second attack occurred, and this too subsided within five days under similar treatment. Again, as reported in 1891, an attack recurred and she was readmitted April 28th, with severe symptoms—œdema of lids, exudation in pupil, etc. V = $\frac{8}{200}$. The case grew worse despite vigorous treatment, and in August, V = $\frac{1}{1000}$. The stump of the originating eye was then removed without producing beneficial effects, and this proceeding had not been sooner employed because there was no irritability or sign of mischief in its behavior. When this stump was examined plentiful colonies of staphylococcus pyogenes albus and citreous were developed from its fluid contents.

[1] Archives of Ophthalmology, June, 1888, p. 188, and *ibidem*, July, 1892.

This case proves the inefficacy of evisceration to protect from sympathetic ophthalmia, and the extreme probability of the cocci being the active agents in the process.

Discussion is still active, and opponents of the germ theory are yet unconvinced; see Randolph, *Archives of Ophthalmology*, July, 1892, p. 367, who was wholly unable to find any germs in an exciting eye. Ohlemann also failed to find germs in thirty eyes removed as exciters of sympathetic inflammation in Schweigger's clinic; but other observers have. See note, p. 547.

Treatment. — Notwithstanding occasional recovery without treatment, we are never authorized to trust to this expectation. It is claimed that palliative means will sometimes subdue the provoking irritation and effect relief in the second eye. It is dangerous to put faith in such measures, provided the case is really of the kind now being discussed. The removal of the cause is the only effective treatment, and that means enucleation of the exciting eye. The operation is by far more satisfactory in the irritative forms, and there rarely does it fail. When the inflammatory condition is once begun, an early operation may check its progress, but this is not to be absolutely counted on, even if done on the very first day (Hirschberg). Enucleation when the inflammatory process has gained decided headway has little control over it; yet it does not aggravate it, as claimed by Mauthner. Sometimes it mitigates a patient's sufferings and cases of effective relief are recorded. When the sympathizing eye is tense and painful (secondary glaucoma) iridectomy may afford temporary relief, but may not check the disease. The opening is soon filled up by exudation, and the friable iris cannot always be pulled out with forceps. Such interference is usually unadvisable. Mr. Lawson has had good results in mitigating pain by sclerotomy (*Ophth. Hosp. Rep.*, Vol. X., 8, 1882). During its active progress the patient will be kept in the dark, and everything done to enable him to resist the depressing influence of confinement. With eyes properly bandaged, he may take exercise if pain be not too intense. The chief local treatment is hot fomentations, from four to eight hours daily, in periods of one or two hours. Atropia may be injurious if irritating. To relieve pain, which is sometimes severe, hypodermic injections of morphia, the instillation of sol. mur. cocaine, 4% to 10%, several times daily, and soothing embrocations to the forehead and temple are suitable. Mercurials are not favored by all practitioners, but I have seen at least one marked instance of arrest, where salivation was induced in a robust man, and my judgment is in favor of their use under proper limitations of individual condition. Derivative treatment by injections of pilocarpine, gr. $\frac{1}{6}$ to $\frac{\mathfrak{m}}{3}$ i., may sometimes be employed, but not to be long continued. We must give tonics, and maintain the health for a long fight; its duration will be from six months to two years.

Digitized by Google

The issue may be in total loss of light perception, with atrophy of the bulb, or there may be fair perception with or without cataract. In the one case we may make a broad iridectomy, in the case of cataract its extraction will often require transfixion of the lens by the knife and removal with iridectomy by such means as may be suggested at the time, hook, spoon, curette, etc. Afterward an iridectomy may be needful. (See Fig. 212 from Lawson's "Injuries of the Eye," giving an operation done by Mr. Bowman. A broad lance is entered above and when the point is below the pupil it penetrates the iris and lens. By scissors the lateral cuts are made and lens and iris drawn out by forceps and spoon. The proceeding is much less easy of execution than its evident fitness would imply. A very fluid vitreous may utterly defeat the attempt. The consolation remains that eyes in these desperate conditions, will bear a wonderful amount of rough handling without violent reaction. If no better, they are likely not to be worse.) Mr. George Critchett[1] reported favorable results in treating cataract by repeated discissions without iridectomy. In no case is it wise to operate until all signs of disturbance have disappeared. It is better to wait six months after the eye seems to be well. Absorption may fail of accomplishment.

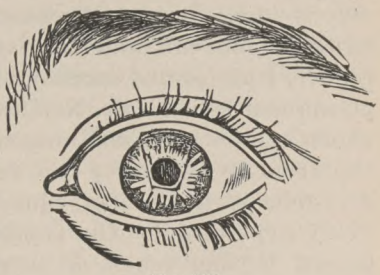

FIG 212

The problem of treatment becomes much more embarrassing when the originating eye has not entirely lost sight. It has sometimes turned out that the second eye became totally blind, while the first has become available. It, therefore follows, that removal of an injured eye which still retains vision will not be practised, except as a preventive measure before its fellow has been attacked. On the other hand, if the outbreak has already taken place, a seeing eye will be conserved and every measure taken to improve its condition, such as iridectomy for prolapsed or adherent iris, or sometimes, the removal of cataract. Hirschberg reports sympathetic ophthalmia after extraction of cataract whose visual result was satisfactory; the second eye was lost, the first continued to have sight.

The judicious treatment of injured eyes becomes, therefore, a problem of grave responsibility and demands attention, experience and skill. It is cruel to sacrifice every seriously injured eye to a possible danger, but with scant experience, and limited skill it is safer for the practitioner whose patient cannot avail himself of better advice, to practise preventive enucleation and insure at least one good eye.

[1] Ophth. Hosp. Reports, vol. x., part 2, June, 1881, p. 141.

It remains to be stated that enucleation has not always, even in apparently favorable cases, proved efficient. Dr. H. Derby[1] reported a case in which, after the operation, the already developed symptoms in the fellow-eye were abated on the second day, and recovery ensued, to be followed by repetition of the same kind of inflammation within two months. There was no tenderness in the orbit of the operated side, but the excision of the stump of the optic nerve and the surrounding tissue was followed by recovery. This relief proved to be only temporary and the affected eye was ultimately lost. In a child whose second eye was suffering from the irritative, not inflammatory symptoms which enucleation failed to relieve, I performed excision of tissues at the apex of the orbit with permanent relief. Mr. Nettleship[2] has collected fourteen cases in which sympathetic inflammation began at a considerable interval, viz., from five to forty-one days, after enucleation of the injured eye, done at the proper time. The variability in results is most easily explained by the supposition that germs have or have not passed beyond reach of surgery in sufficient numbers to cause dangerous consequences. The committee which reported in the following year collected thirty cases in which enucleation failed to prevent sympathy, and the interval between the operation and the outbreak varied from two days to two months. In the great majority it was less than three weeks (Trans. Ophth. Soc. United King., VI., 189, 1886).

Other remedies besides enucleation have been advocated. Alfred Graefe, of Halle, in 1884, proposed exenteration of the globe, because some cases of enucleation have been followed by death. This risk, which is most serious during acute panophthalmitis, is, nevertheless, small—about 1 in 4,000—and may be left out of account, while the proposed substitute is more difficult of execution and unreliable as recorded failures (Cross, Schiess, etc.) have proven.

A proceeding which has been much more generally practised is the division of the optic alone or of both optic and ciliary nerves. This retains the eye, and seems to promise protection. Section of the ciliary nerves alone by incision through the sclera on a line parallel to and at some distance behind the border of the cornea was practised by Meyer with success in 1866, in three cases of neurotic sympathetic trouble. Prolapse of vitreous ensued, and rarely has this proceeding been repeated.

The post-ocular division of both ciliary and optic nerves and the excision of portions of them have been largely resorted to. A description of the method will be given below. At present it does

[1] Trans. Amer. Ophth. Soc., 1874, p. 198.

[2] Trans. Ophth. Soc. of the United Kingdom, vol. v., p. 85, 1885.

Digitized by Microsoft Corporation

not command general approval. As a *preventive* measure before sympathetic symptoms have declared themselves it is espoused by Schweigger and by others, while as a remedy for the irritative lesion it ranks below enucleation, and against the inflammatory type it is untrustworthy. Leber has seen a case of sympathetic inflammation take place after neurectomy (Deutschmann).

The proceeding is surgically more difficult and is followed by greater reaction than excision. There is liability to severe hemorrhage, and recovery may require several weeks. If done by scissors inserted behind the globe without completely dislocating the latter, there may be but little reaction. It is found, however, that the nerves will reunite, as proved by the restoration of sensibility in the cornea, and the form of the globe is not always preserved, because of gradual atrophy and softening. Moreover, when done to control existing neuritic irritation, the relief which has been in some instances gained has proved to be temporary, and extirpation became necessary. It is not denied that it has sometimes permanently controlled neuralgic symptoms, and that, inasmuch as the eyeball is retained, this proceeding may be accepted when extirpation would be refused. It will, therefore, be resorted to under special conditions, but it is to be regarded as provisional rather than decisive, and shrinking of the eyeball is to be anticipated. It will often be needful to wear an artificial eye to conceal deformity, and sometimes the operation makes the wearing of a shell less liable to cause irritation upon a stump.

Mention should be made of a suggestion by Abadie, who has practised injection of one or two drops of sol. corrosive sublim., 1 to 500 or 1 to 1,000, beneath the conjunctiva of the originating eye with a view of arresting the disease and its propagation. He reports three successful cases in which both eyes were saved (*Annales d'Oculistique,* Mars-Avril, 1890, p. 183). He also relates a case in which the originating eye and subsequently the orbital tissues had been removed without good effect; and as the eye secondarily affected was in a desperate state, another practitioner had the boldness to inject beneath its conjunctiva a syringe half-full of a solution 1 to 100. A violent reaction ensued; for a time the sympathetic disease was abated, but blindness ultimately followed. With the solutions employed by Abadie reaction may be sharp. His suggestion is in the line of the present theory of pathogenesis, and it is fair to be considered, inasmuch as it applies to cases where sympathetic inflammation has already broken out in the good eye. For further discussion see Wecker, *Annales d'Oculistique,* June, 1892, and "Traitement de l'Ophthalmie Symp., etc.," 1891. Also Rohmer, *Ann. d'Oculist.,* Avril, 1892, and F. Boè, "de l'Ophthalmie Symp.," Congres d'Ophthalmologie, March, 1891, who oppose nerve section. Internat. Med. Congress, section Ophthal., Berlin, 1890.

Optico-Ciliary Neurectomy.

The operation may be done without dividing any of the muscles, as follows: Incise the conjunctiva at the space between the rectus internus and the rectus superior with a pair of blunt-pointed scissors curved on the flat, and clear a way to the vicinity of the optic nerve. In doing this rotate the ball downward and outward to the extremest degree by fixation forceps. Along the track thus made, carry a small strabismus-hook, catch the optic nerve, and pull forward. Over the hook insert the scissors, and, pressing their points firmly to the apex of the orbit, sever the nerve. Then with the hook drag out the optic nerve, seize it with forceps, and pull the globe around until it shall be completely reversed. It slips like a button through the hole in the conjunctiva, and presents its posterior scleral surface to view. With toothed forceps and scissors pick and cut away every shred of nerve-fibre and tissue which can be seen, and cut off the optic nerve close to the eye. A piece eight millimetres long may easily be excised. By the forceps then turn the ball around and restore it to its place. The conjunctival wound must be closed by sutures.

It is easier to perform the operation after cutting the insertion of the rectus externus or internus muscle, and then, using the hook to catch the nerve, do what has already been described. The severed muscle must be stitched to its insertion, where a small piece of the tendon has been left for this purpose. A more extensive exposure is thus made of the back of the globe, and with greater certainty the ciliary nerves can all be secured. Some strabismus is liable to ensue, and bleeding is apt to be copious. In whatever way done, we are liable in some cases to meet free hemorrhage in this operation. It can cause great protrusion of the globe. Nothing but pressure is available to restrain it, and a very firm bandage may have to be kept on for twelve or twenty-four hours. In this event reaction may be severe.

The effectual severance of all the ciliary nerves is betokened by resulting anæsthesia of the cornea. This, however, sometimes fails, even in thorough operations, because of their irregular distribution and escape from the scissors. It has also been shown that they are capable of regeneration (Krause). It is not infrequent for softening and even marked shrinking of the globe to take place, and I have seen this coupled with great tenderness on pressure, which prevented the tolerance of an artificial eye. Consequently the uses of this operation are more limited than was expected. Enucleation may in the end be required, while Leber reports one case where sympathetic inflammation of the fellow occurred despite

Digitized by Harvard College Library

of it. Therefore it is not to be relied on as preventive with the same confidence as enucleation.

It may be done in eyes not severely injured and for shrunken eyes in which there is no foreign body and which are not threatening sympathetic danger. It has advantages in certain cases, viz., slight megalophthalmus, or sometimes an absolute glaucoma, because it causes shrinking of the globe. It has some merit as a prophylactic, and Schweigger resorts to it freely, but few other surgeons do so. If a patient absolutely refuses enucleation, this operation is the best substitute. It is to be accepted that considerable and sometimes violent reaction will follow, far greater than after enucleation.

Enucleation of the Eye.

With a pair of blunt-pointed scissors, curved on the flat, and of medium size, separate the conjunctiva from the globe at the margin of the cornea, going all around it. Then, with small clips, go to the insertion of the rectus superior, thrust under it a strabismus hook, and cut it away from the globe. The hook is liberated, but serves to lift the conjunctiva and keep the wound open; then a second hook tears away the sub-conjunctival connective tissue and is slipped under the insertion of the rectus internus muscle, keeping in close contact with the globe. The two other recti are similarly divided, and the hook is swept around the equator, to be sure that all the tissues are divided. The globe, if of normal size, can now be extruded from the orbit by pressing between it and the orbital rim either with the finger or with the speculum. The closed scissors are pushed to the back of the eye by lateral movements, tearing a path until the optic nerve is struck. When in contact with it, open the blades astride of the nerve, and inclining the points backward, divide it. At this moment a gush of blood occurs. Push the eye forward, take it in the fingers, and cut away the insertions of the two oblique muscles, and all the vessels, nerves, and other attaching tissues. Push a sponge into the orbit, and make firm pressure. In a few minutes bleeding will be checked, but if it be very free, use the index finger as a compressor, bearing firmly on the apex of the orbit. Ordinarily, hemorrhage is slight. When it has ceased, draw together the conjunctival opening by a suture, which shall gather it loosely, as the mouth of a purse is puckered together. It is intended simply to prevent the formation of irregular attachments of the conjunctiva, which, by giving rise to ridges and bridles, would interfere with wearing an artificial eye.

Under ordinary circumstances the operation is easy of performance. But if the eyeball is much atrophied, it must be seized by a

sharp hook and held up while the muscles are divided and the other steps attended to. If the sharp hook be not employed, the operation will be quite troublesome, and with atrophied globes is always more difficult than when the eye has its proper size. For an eye in a state of suppuration, or in case the globe has been badly torn by a wound, its enucleation is a matter of difficulty. With panophthalmitis the tissues are matted together, are greatly swollen and vascular, the dissection is laborious and the bleeding severe. The rule is to keep close to the sclera and make small clips with the scissors. A good assistant is very important, who knows how to sponge away blood skilfully—to reduce, as much as possible, the operator's embarrassments. Reaction is always considerable. For a badly lacerated globe the dissection is tedious, and in all cases where the eye has been opened, the loss of its firmness causes trouble to the operator.

Because of the greater reaction following excision during panophthalmitis, and because some fatal cases have occurred, although their number is relatively very small, it has for years been my practice in suppurations of the eye to open it freely and wipe out the contents, leaving the sclera to shrink. This kind of evisceration is really nothing more than complete emptying of an abscess, yet it does not afford perfect relief nor arrest the inflammatory process in the orbit. On the contrary, the chemosis and congestion remain for days and pain may be severe. Sometimes, therefore, another incision through the back of the sclera will be needed for freer escape of fluids.

Exenteration of the eye, as removal of its contents is called, has within a few years been commended by Alfred Graefe and by Bunge, as a substitute in all cases for enucleation, and they do it by excising the cornea at the limbus and removing the whole uvea and inclosed vitreous by a small spatula. They claim that enucleation is too drastic, and neurotomy too conservative.

Bunge in his monograph, "Ueber Exenteration des Auges," Halle, 1887, reports upon 200 cases of all kinds, excluding tumors, and the time of healing varied from three to thirty days, and averaged ten days. Among these, were two where sympathetic trouble had begun in the other eye, and by this operation, combined with vigorous treatment, the disease was cured. Many cases were recent injuries or acute suppurations; in them there is an inducement to adopt such a proceeding, yet as a substitute for the simpler and more reliable method of enucleation this operation has not yet justified itself.

The case of Schiess (*vide supra*) where sympathetic inflammation followed evisceration is to be noted. The cases reported by Cross (see p. 532) had been treated in the manner advised

Digitized by Google

by Mules and an artificial vitreous inserted. It is not certain in the light of the case reported by Schiess whether the glass globe could be regarded as the cause of the sympathetic irritation; the failure to get rid of all the germs seeming to be enough to make the consecutive trouble. Schunk among thirty-six cases of exenteration had two deaths (Becker, l. c., p. 87).

Something more seems proper in regard to the danger to life after enucleation. Besides the articles of Alfred Graefe and Bunge, 1884, Benson, *Ophthalmic Review*, Vol. III., p. 293, 1884, we have papers by Deutschmann, 1885; Nettleship, 1886; D'Oench, 1887; Andrews, 1888; Becker, Universitäts-Klinik, Heidelberg, 1888, who have put together all the cases which bear upon the question. There have been thirty-six to forty deaths made known; almost all by meningitis, a few by general infection. Meningitis without fatal result has been several times recorded. Becker, l. c., enumerates four. About one-half the fatal cases ensued after enucleation during acute suppurative panophthalmitis. Almost the same proportion took place when no acute inflammation could be found in the orbit, and there was no suppuration of the eye. The mode of propagation to the brain is not clearly made out and evidently occurs in various ways. That an infectious process is very frequent, is certain.

In estimating the relative importance of the danger of meningitis or other serious risk to life after enucleation, we must not forget how great is the number of such operations. Becker gathered from Arlt and other clinics in Vienna and from his own clinic in Heidelberg (l. c.) more than one thousand enucleations without a fatal result. D'Oench, from Dr. Knapp's clinic, reported five hundred cases to which afterward seventy-eight were added (Andrews), and of these thirty-two were suppurative, and among them there was no fatal result. Gunn states that in Moorfields Ophthalmic Hospital more than a thousand enucleations had been done, with but a single death. At the New York Eye and Ear Infirmary there has been no death from this cause, when no additional operation in the orbit, such as removal of tumors, etc., had been done. The number of enucleations from 1868 to 1888 was 1,164. The number of eviscerations was seventeen. Among all the cases it is noted that acute panophthalmitis existed 161 times, viz., in 14%; as already stated, there has never been a fatal case. There have been cases of meningitis and some with fatal issue following panophthalmitis when no enucleation or other operation was done (Webster,[1] Trans.

[1] Man, aged 76, had had one eye removed for absolute glaucoma, a year later extraction of cataract, followed by panophthalmitis and death on twentieth day.

Digitized by Google

Med. Soc. State New York, p. 365, 1888). Also two cases by Motais (Becker, l. c.).

It seems fair to conclude that while a small risk to life is incurred by enucleation of the eye, about 1 in 4,000, the supposed increase of risk by the existence of suppurative panophthalmitis is not so far justified by the facts, as to bar its performance under these conditions. Neither, when proper indications arise, need we on this account hesitate to do the operation. It is true that in all cases free drainage must be provided; if the subject be old and feeble and the reaction severe, partial enucleation to evacuate the contents of the eye, and when necessary subsequent deep incisions through the back of the globe into the orbit, may be substituted. Should there be deep and severe phlegmonous inflammation of the orbit, besides deep incisions, irrigation with corrosive sublimate, 1 to 500 or 1 to 2,000, as seems needful, and fomentations by gauze or absorbent cotton soaked in hot sublimate solution, 1 to 2,000 or 3,000, must be practised. Iodoform in powder or upon gauze, may be forced into the incisions, and suitable constitutional treatment, bromides, leeches, mercurials, stimulants, etc., employed. It seems that severe orbital cellulitis, purulent infection, is more apt to be aggravated by evisceration than by enucleation. Yet I would call attention to the value of deep incisions and strong antiseptics, and the importance in some cases of avoiding serious loss of blood.

The following case, which has recently occurred to me, is the most serious one which I have met, and the treatment adopted indicates how a grave danger may be successfully dealt with.

A man, aged 57, who had the charge of a canal-boat carrying coal, was struck by a bit of coal in the left eye and came within four hours to the N. Y. Eye and Ear Infirmary on March 15th, 1889. There was a lacerated wound on the lower part of the cornea through which iris protruded. The iris was excised and the wound carefully syringed with sol. corrosive sublimate, 1 to 3,000, all the dirt removed and bandage applied. The man insisted on returning to his canal-boat. The next day he reappeared with acute panophthalmitis suppurativa. He was put to bed, freely purged by a cathartic, and hot fomentations applied. After two days longer, the reaction attained extreme severity both in the globe and in the orbit. Under ether, enucleation was performed, and so great was the infiltration of the orbital tissues, that the operation was very difficult. Temperature, 99° F. On the next day, March 19th, the lids were more swollen than before and the orbital tissues more infiltrated and very hard. Temperature, 101.2° F.; pulse, 55. Sublimate solution, 1 to 3,000, constantly applied. Bromide of sodium at night. The following day, temperature 101°, pulse 55; suffers severe pain, had a bad night, was a little delirious, has a haggard and anxious look. Lids and orbital tissues very tumid, skin dusky red; the parts very hard when pressed upon, slight puriform discharge. The swelling greater than before the eye was removed.

The general symptoms were manifestly cerebral and their gravity de-

Digitized by the Internet Archive

manded vigorous measures. The intense phlegmonous inflammation in the orbit must in some way be controlled. The patient was etherized; deep incisions were made vertically through the middle of both upper and lower lids, and after they were split in halves, the knife was carried on the same plane deep into the orbit along the roof and the floor; with the same freedom a horizontal cut was made through outer and inner angles and deep into the orbit. No collapse of the tissues ensuing, cuts were made in diagonal directions reaching down to the apex of the orbit. Very moderate bleeding, and little pus or other inflammatory effusion escaped. The tissues were hard, brawny, and yellowish gray. Solution of bichloride, 1 to 1,000, was freely syringed into the cavity and it was packed with gauze soaked in the same solution. After the operation, temp. 101°, pulse 52.

The following night he was more comfortable. The next day, March 21st, temp. 99°, pulse 68. Wound opened, washed out, and repacked with gauze saturated with sol. hyd. bichlor., 1 to 1,000. The same treatment continued daily, the wound being opened, cleansed, and repacked once in twenty-four hours. Tissues of the orbit became much softer and the swelling declined. During four days, until the 25th, temp. 98.2° to 99.4°. Been free from pain. March 29th, able to sit up; temp. 100°, pulse 65. April 4th, swelling and infiltration of tissues almost disappeared; temp. 98.8°, pulse 70. April 6th, discharged, and to attend as out-patient. The sublimate solution was continuously kept up and not until his discharge was its strength reduced to 1 to 3,000.

There seems to me no doubt that the patient's life was saved by the vigorous, not to say heroic incisions giving vent to secretions, and the powerful antiseptics. The general treatment consisted in moderate stimulation and a little bromide. Anodynes were not needed. The parts were so mutilated as to preclude wearing an artificial eye.

If enucleation had not been done, the orbital inflammation was severe enough to render cerebral inflammation probable, and from this cause fatal results have followed. Only the deep incisions and the powerful antisepsis could have been effective, and to give opportunity for them, removal of the eye would have been necessary. Hence, I do not regard the enculeation as contributing to the risks of the disease, much less responsible for the cerebral symptoms.

NOTE.—On the pathogenesis of sympathetic ophthalmia we have a full and searching analysis of cases and theories by Schirmer in Graefe's *Archiv*, XXXVIII., iv., 95, 1892. He concurs in the separation of the two forms and believes in the microbic origin of the inflammatory type. But he does not believe that the microbe has yet been isolated, neither does he think that the path by which the microbes travel is yet recognized (l. c., p. 246). The pus-producing microbes do not, he thinks, have any office in sympathetic trouble, in which he opposes Deutschmann. He also denies that the neurotic type can give rise to the inflammatory; but see case on p. 533. He quotes four cases to show that optic neurectomy may retard but does not always prevent sympathetic inflammation (p. 186).

Digitized by Illinois College of Optometry

CHAPTER XV.

GLAUCOMA.

THIS word designates a morbid condition which has one signal peculiarity, namely, an increase in the hardness of the globe. The name comes down from olden times, and was employed because in certain advanced cases the pupil acquires a greenish hue (*glaucus*, sea-green). Graefe (*Archiv f. Ophth.*, Bd. III., 2, 1857; Bd. IV., S. Z. 127), and before him Mackenzie ("Diseases of Eye," London, 1830, pp. 706–710), recognized that unnatural hardness was a fact characteristic of the malady, and since Graefe's time all affections in which the tension of the eye rises above the normal degree are called glaucomatous. The standard of ocular tension varies in its physiological limits. In women it is normally less than in men, in children than in adults. An average of twenty-five millimetres of mercury, or twelve inches of water, is normal. For exact measurements special instruments are used, called tonometers, of which several have been made, but they are not resorted to in practice. We must, as yet, simply rely upon the sense of touch, and one finger of each hand is to be lightly pressed upon the eye as when feeling for fluctuation in an abscess. The sense of resistance can also be appreciated, although less accurately, by a single finger pressing the globe through the closed lid. Mr. Bowman suggested a notation and classification as follows: for normal eyes, T; for those with increased tension, T_+ ?, T_{+1}, T_{+2}, T_{+3}; for those with diminished tension, T_-?, T_{-1}, T_{-2}, T_{-3}. When the sign ? is put behind T, it indicates a doubt as to the real status. Mr. Priestley Smith has experimentally given values for these expressions in columns of mercury, but they are only approximate, viz.: that while T = 25 mm., T_{+1} = 50 mm., T_{+2} = 75 mm., T_{+3} = 100 to 125 mm. Different observers might estimate the same case variously, and the sense of touch must be educated.

The following subdivisions of the disease are recognized: glaucoma simplex; glaucoma with inflammation, and this may be acute, subacute, or chronic; glaucoma hemorrhagicum; and secondary glaucoma.

Symptoms.—Glaucoma simplex is the most frequent affection. It is an insidious and very slowly progressive condition. It arises usually after middle-age, and in hypermetropic eyes. It has been

Digitized by the Internet Archive

seen in young subjects, and a contingent is found among myopes (see Fig. 213), and when found in them, the increase of tension is very inconspicuous. The symptoms are as follows: In external appearance the eye may be normal, except a notable whiteness of the sclera, with a few conspicuous and tortuous vessels coming from the recti muscles. The anterior chamber and iris may be normal, and the pupil a little sluggish but contractile. Visual acuteness may or may not be reduced. Color perception is little affected though acuity is low. The field of vision will be restricted on the nasal side to a greater or less degree, and perhaps be curtailed in the remainder of the periphery. It can also happen that scotomata are to be found in other portions of the field, and they may lie near the macula lutea. The tension of the eye will be increased. Periodic variations in tension are apt to occur which explain the occasional character of subjective symptoms, and for this reason the tension may at a particular period be practically normal, or plus tension even be an exceptional condition. By the ophthalmoscope the optic nerve will be found hollowed into a cup or excavation; it will have a white or grayish hue; its arteries will not form continuous lines, but some of them will be broken as they pass from their place of entrance to the surface of the retina. In extreme cases of optic excavation they seem to spring from the nasal side of the nerve, and the faults in their continuity will be conspicuous. (Figs. 214 and 215.) They spontaneously pulsate, or do so under slight pressure. The veins will be large and dark. In the inverted image a great degree of parallax is given to the arteries on the disc by to-and-fro movements of the objective lens; with the upright image the difference of level between the edge of the nerve and the bottom of the pit will sometimes amount to several dioptries, viz., three or even more. It may be roughly stated that each D represents rather more than 0.3 mm. in actual depth, and 3 D = 1 mm. The excavation extends over the whole of the disc and its edges are undercut, which explains the partial disappearance of the arteries as they climb, in a somewhat oblique direction, up its sides. If there has been a previous physiological excavation, this will be added to the pressure effect, and if the case chance to be one of myopia, with adjacent choroidal

FIG. 213.—Myopia with Glaucoma.

Digitized by the College of Optometry

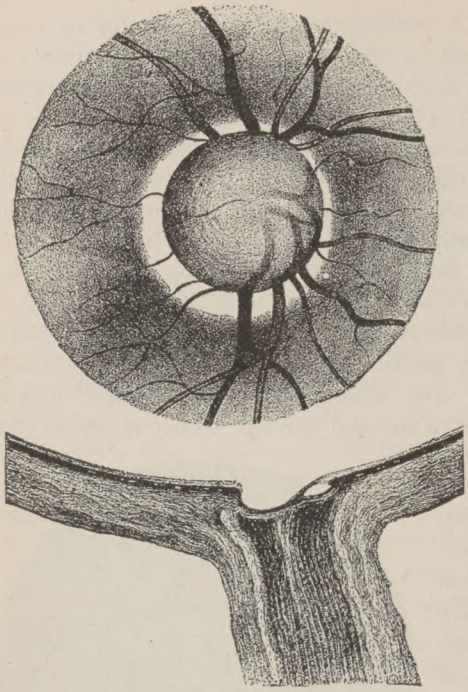

FIG. 214.

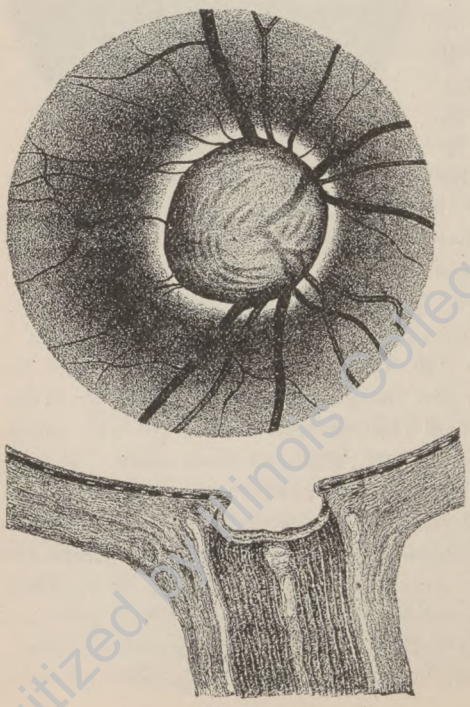

FIG. 215.

atrophy, a slope of the floor of the pit in this direction will be observed. It will be seen that the conspicuous objective facts of glaucoma simplex are increased tension, possible reduction of central vision, impairment of the field, especially on the nasal side, a general excavation and pallid look of the optic nerve, and spontaneous, or easily excited pulsation of the arteries on the disc.

Some qualifying remarks must be inserted among the statement of symptoms. In certain cases there is great difficulty in diagnosticating between gl. simplex and optic atrophy; in fact, the two are often combined. Hence color sense will in some glaucomatous cases show impairment, and in proportion to the loss of visual acuity. Michel (l. c.) notes central scotoma for green and later for green and red, while peripheral limitations may be seen. Moreover, the peripheral vision sometimes suffers on the temporal side conspicuously and not at all on the medial side. See remarks upon diagnosis.

There are subjective symptoms liable to occur, yet they are uncertain. Almost always there is a notable diminution in the range of accommodation, that is, a retirement of the near-point has taken place. Hence a resort to uncommonly strong

Digitized by Illinois College of Optometry

glasses for reading has been necessitated, or glasses have had to be adopted prematurely. Attacks of sudden obscurity of sight have taken place, when, for some minutes, everything became dark, even in good daylight. At times colored rings will be observed around a lamp or gas flame, or simple colored vision occurs. Some painful sensations have been noted about the eyes or brows. One eye may have become almost blind without awakening the patient's suspicion. It is usual for one eye to be affected for some time before the other. The disease may occupy as much as five or fifteen years for its full development. Patients often can give little account of the premonitory symptoms, although they may have long existed. When well established, it is often mistaken in old persons for senile cataract, especially because the lens of old age has a smoky hue. This explanation of failing sight is considered adequate, and a resort to skilled advice discouraged. Under this mistake the patient is told to wait until the supposed cataract shall be ripe before going for relief, while the delay is simply affording time for total loss of all chances of recovery.

The full development of glaucoma may be reached by simple continuance of the foregoing symptoms until the so-called *chronic* or *absolute* glaucoma is established. Examination of the field will then show defects upon any side of the periphery, although most often upon the nasal side, central vision may be very bad or pretty good, while a slit-like space in the field running outward from the centre may be relatively better preserved than the macula; color perception may be good. There will be greatly augmented hardness of the globe, a very shallow anterior chamber, with the pupil widely and unequally dilated and fixed, the iris discolored, the cornea more or less anæsthetic, not resenting the touch of a twisted thread, the lens may or may not be cataractous, the pupil will have a dusky or even greenish hue, the surface of the globe will be marked by tortuous and enlarged anterior ciliary arteries, which dip suddenly into the sclera, and sometimes a marked plexiform arrangement of vessels is to be seen about the front of the globe. Should the media be clear enough to permit ophthalmoscopy, deep excavation of the nerve, with absence of capillaries and reduction of the arteries to slender threads, with marked pulsation and turgid veins, denote the extreme stage of pressure. Often the choroid, immediately about the nerve, undergoes atrophy, and presents by exposure of the sclera a marked ring. The patient will have lost vision, both direct and indirect, almost or quite completely, and have considerable pain in and about the eye.

Glaucoma with Inflammation.—Inflammatory attacks may supervene upon glaucoma simplex and may be of various degrees; on the other hand, an attack of so-called acute glaucoma may take

place in eyes which have had no objective and, perhaps, few or no subjective signs of the disease just described. It is not rare that if one eye has passed to an advanced degree of glaucoma, the other and unmolested eye should have an outbreak of acute glaucoma. Moreover, both eyes may be simultaneously attacked by such an inflammation without noticeable warning or lesion.

The symptoms are as follows: the person is apt to be taken during the night with severe pain in the eye and forehead; congestion of the scleral and conjunctival vessels rapidly develops, with subconjunctival œdema and swelling of the lids; within a few hours chemosis and tumefaction become extreme, and pain in the head and eye intense. There may be serious constitutional symptoms in rise of temperature and pulse, in vomiting, and tokens of a so-called bilious attack. On inspection of the eye the cornea is hazy, although it may sometimes be clear, as I have verified; the aqueous will be turbid; the iris and lens pressed toward the cornea, reducing greatly the depth of the anterior chamber; the pupil will be obscured and dilated; the iris discolored, and diminished to a narrow ring. It is not easy to feel the tension through the swollen lids and chemosis, but after pressing through the boggy tissues, the globe will offer great resistance to touch, and pressure will be painful. A view of the fundus is often impracticable, and always imperfect, because of the turbidity of the media; but the optic nerve is often red, and usually not excavated (if the attack be the first one); pulsation of arteries on the disc can seldom be made out, but it is to be expected. The inflammatory effusions are chiefly serous, but adhesions of the iris may occur, although not so marked as in ordinary iritis. Purulent exudation and decidedly plastic exudations do not appear. Of course vision is greatly impaired, and sometimes is wholly annulled within a few hours. It is not to be expected that, under such circumstances, a careful examination of the field can be made.

Subacute glaucoma is a phase in which vascular engorgement in the ciliary region is more or less pronounced, the iris altered in texture and appearance, sometimes displaying an erratic and conspicuous vessel upon its surface, the anterior chamber shallow, the pupil enlarged and sluggish, tension augmented, the vitreous often hazy, the pit in the nerve and its pallor and the displacement of vessels, decided. The case simply exhibits moderate degree of vascular obstruction and hyperæmia and there may have been some sharp pain.

Chronic glaucoma presents a picture already mentioned as the advanced state of glaucoma simplex. We may or may not have conspicuous vascular symptoms, but we shall seldom fail to find in the vessels of the ciliary region great fulness and tortuosity of the

Digitized by Internet Archive

principal branches, and the abrupt way in which they spring from the sclera, or are convoluted, will arrest attention. Added to these will be all the tokens of intraocular pressure above stated. *Glaucoma absolutum* is the name used for the final state. There may be cataract, and in some instances there are equatorial staphylomata at this period. There may be no perception of light, or only within a small field and there is often distressing pain. Secondary degenerations may occur, in hemorrhages within the eye, ulceration of the cornea, keratitis bullosa, and sometimes atrophy of the globe.

Glaucoma Hemorrhagicum.—Under this name is grouped a class of cases which might in strictness be set down among those of secondary glaucoma. There is effusion of blood in the retina or optic nerve, and sometimes in the vitreous. It is generally true that no preliminary signs of glaucoma have occurred, but a sudden loss of sight is followed in a little time by pain and inflammatory symptoms. The point of distinction between this lesion and acute glaucoma is that the loss of sight precedes by some interval the acute inflammatory attack. On examination, the eye shows increased tension and turbid media, while, if the fundus be visible, patches of extravasation, more or less extensive, will be discerned. The pupil will be sluggish, and greater or less ciliary hyperæmia exist, but great variety may be found in the symptoms. The point to be dwelt on is, that in these cases the hemorrhage is the occasion of the outbreak of acute symptoms, and there may have been no glaucomatous signs previously. One eye alone is usually affected and the other is free, while in the forms previously mentioned both eyes partake in succession. It has seemed to me quite certain in some cases that the beginning of the morbid process was embolism of retinal arteries with consecutive hemorrhage, and that the glaucomatous outbreak ensued because in such persons the vessels were atheromatous, and could not readily adjust themselves to the disturbance of the circulation. The usual phases of glaucoma absolutum ensue, and in some instances the lens may not only become opaque but dislocated.

Glaucoma Secundarium.—By this is meant increased intraocular tension, consecutive to some other disease. It ensues upon staphyloma of the cornea; after wounds with incarceration of the iris; after total occlusion of the pupil, *i.e.*, complete posterior synechia; after operations for cataract, with false membrane filling the pupil; as the result of wounds of the lens, causing it to rapidly swell; after dislocation of the lens forward in front of the iris, or backward into the vitreous (illustrations of the latter condition are found in the after-history of reclination of cataract); it follows upon the growth of intra-ocular tumors. The conditions called *buphthalmus* and *hydrophthalmus*, which may or may not be congenital,

Digitized by Illinois College of Optometry

are specimens of secondary glaucoma. In them the whole globe is enlarged, especially its front; the cornea expanded into a bulbous form, and very thin—it may be bluish and semi-transparent, or gray; the boundary between it and the sclera cannot be defined; the ciliary region is widened and bluish, and may project in nodules. The anterior chamber is of great depth and width, the iris thinned and discolored, in spots its tissue may have sprung apart into holes. If the pupil be adherent to the lens, as is commonly the case, the iris will be pressed forward at the periphery, while the pupillary edge, being held down, will be at the bottom of a little pit. The pupillary area may be filled with exudation, and the lens be opaque. Generally, no view can be had of the deeper parts of the eye, and sight is wanting, or reduced to perception of light. I have seen a traumatic case which was caused by an entanglement of the whole pupillary margin in a central wound of the cornea, and the iris was wholly applied to the posterior surface of the cornea. The posterior chamber was enormously developed, as the anterior chamber usually is.

Diagnosis.—No words are necessary in addition to what has already been stated, to set forth the distinctive features of a well-marked case of glaucoma of any type. But there are some conditions under which the recognition of the disease may require careful attention.

The first to be mentioned is during the early period of glaucoma simplex. No dependence can be placed upon the external signs, because the eye looks healthy. Central vision may be normal, or nearly so, and subjective symptoms are obscure or have been unheeded. Tension may be doubtful. We are then shut up to two symptoms, viz., the appearance of the optic nerve, and a careful scrutiny of the visual field. As to the nerve, the excavation may be partial, involving only the temporal half, and the nasal side may be of normal level and red. There may be a vertical dip between the two levels, and the vessels climb over the steep edge partially concealed. The depressed side of the nerve will be white, dotted, and resemble atrophy, the lamina cribrosa being distinct. There may be spontaneous venous pulse, and the arterial pulse be easily evoked. To get this symptom to the best advantage, use the upright image; hold the ophthalmoscope in the left hand if examining the right eye, and use the thumb or forefinger of the other hand to both keep up the lid and make pressure. Much importance attaches to the facility with which arterial pulsation can be produced. In mapping the field, use a small bit of chalk or card about ten millimetres square, and avoid strong light. If the patient be made to face the window, a limitation of the field, which would not otherwise be manifest, may be developed by the glare.

Digitized by Illinois College of Optometry

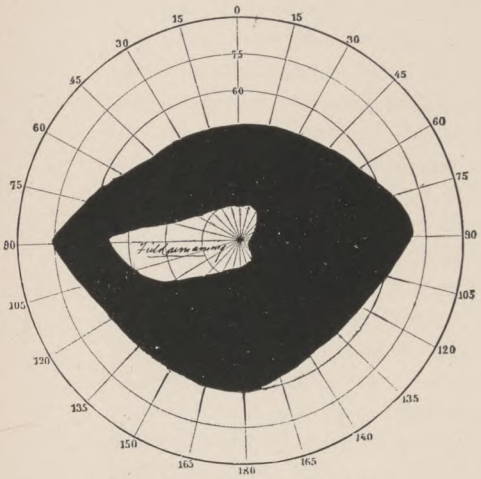

O. S. V = Fingers at 4 ft.

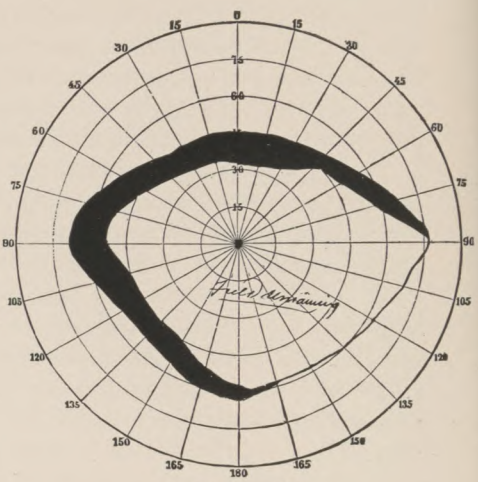

O. D. V = $\frac{20}{50}$.

Glaucoma simplex.

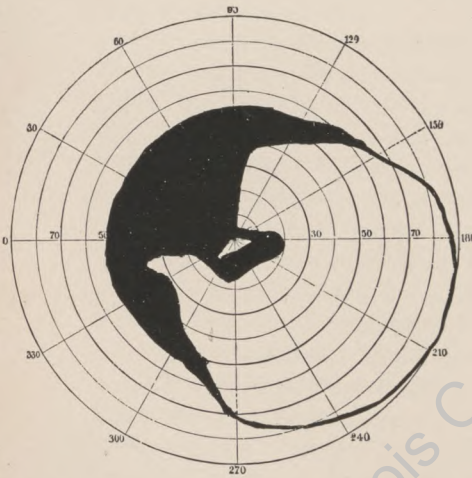

O.D. Glaucoma Simplex $+\frac{1}{48c} \bigcirc -\frac{1}{15c}$ 180° V = $\frac{20}{40}$. S. F., 63, had iridectomy five years previous; excavation covers $\frac{4}{5}$ the surface of nerve.

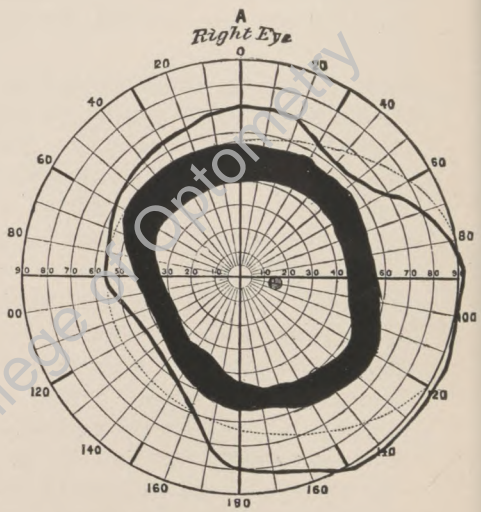

Neuro-Retinitis Orbitalis, Miss M. B. B. O.D. Ring scotoma. See p. 680.

Digitized by Illinois College of Optometry

The perimeter is indispensable, because the peripheral part is the suspicious region. Limitations occur most often on the supra-nasal side, and any region of the nasal side is more likely to suffer than the temporal. But this rule is far from being of general application. The most diverse kinds of encroachment will be found. Scotomata may exist and no peripheral limitation. These can be best determined upon a black-board, and intelligent patients will sometimes describe them better than the physician. The existence of central scotoma is not excluded by possession of vision =0.4. A patient has said to me that on lighting a kerosene lamp only the brightness could be seen, while she could not discern the flame. On making this patient face the window, a central scotoma was readily found, which was not detected with her back to the light. Bjerrum, quoted by Berry in *Ophthalmic Review*, April, 1890, 104, points out the value of examination of the field on a screen 2 metres distant for the discovery of scotoma. His test objects are ivory discs from 3 mm. to 1 mm. in diameter—the first gives a visual angle of 5′, and the field is with this small object normally diminished. By means of them the irregularities and sectorial defects can be discovered. In glaucoma Berry finds that the blind spot (the optic nerve) marks the boundary between the areas of defective sight and of good sight. Central or paracentral scotoma, which he frequently finds in glaucoma, may spread peripherically in any direction, but do not go beyond the blind spot. This points to destruction of the fibres in the papilla at the margin of the excavation as the cause of the visual disturbance. A dim light favors the success of the examination.

The liability to mistake in the cases now considered is in regard to atrophy of the optic nerve. This may further be enhanced by the presence of cerebral symptoms, such as dizziness and headache. The lesion in both cases is undoubtedly in the optic nerve, while for glaucoma the symptom to be chiefly valued is ready pulsation of the retinal arteries—of course supposing that increased tension cannot with certainty be felt; the limitation of field, if discovered, will not be decisive. The excavation which belongs to atrophy is shallow and has a gradual slope, while that of glaucoma is steep or even undercut. Physiological excavation is partial, usually central, and if extensive will not occasion hesitation if the visual field be carefully tested.

There are some cases of deep physiological excavation involving the whole disc which make a diagnosis difficult. Graefe designated the cases now considered, amaurosis with optic nerve excavation. Donders called them gl. simplex. Schweigger has written forcibly about them (*Archives for Ophth.*, Oct., 1891), insisting on a more general appreciation of Graefe's view. He thinks that many times deep physiological excavation succeeded by atrophy

has been mistaken for glaucoma. Such excavations are always bilateral. He further says (p. 497, l. c.) that we may rely on the diagnosis of glaucoma if the excavation be unilateral; the movements of the iris must be normal to convergence, and to light at least consensually; there will have been signs of irritation, halos and obscurations denoting periods of increased tension; impairment of the nasal side of the field distinguishes glaucoma, but may also occur in atrophy; a normal color sense also characterizes some cases of atrophy as well as glaucoma; during the progress of glaucomatous excavation the nerve fibres atrophy; the glaucomatous excavation is sometimes partial, not yet having covered the entire disc. Schweigger thinks it requires about six months to reach the whole papillary border. On the whole, if the full group of symptoms, increased tension, reduced sight, restricted nasal field, excavation, arterial pulsation, etc., is not present we must simply await developments and teach the patient to observe his symptoms, *i. e.*, halos and attacks of dimness. An iridectomy must not be done without decided indications.

Chronic glaucoma ought not to be confounded with senile cataract, yet this too often happens. Real cataract may coexist with glaucoma, but will be seen by oblique illumination, and certainly be discovered if the ophthalmoscopic mirror is used. Palpation will easily prove that the globe has become hard, and the pupil will generally be dilated. No reliance is to be placed on the smoky hue of the lens, because this belongs to its senile condition. There will be cause for suspicion in defective light-perception, and in impairments of the field, neither of which signs exist in simple cataract.

Acute inflammatory glaucoma may be confounded with iritis. The distinctive features will be the vehement pain, the plus tension, the sudden and remarkable reduction of sight, the intensity of the hyperæmia and œdema, with dilated pupil and the absence of adhesion. I have seen a case of subacute glaucoma with posterior synechiæ, which had arisen during an acute attack not long precedent. Such a concurrence is uncommon, and indicates that care must be given to determination of the tension as the important feature. Under such conditions the ophthalmoscope will not help us, because of the turbid state of the media.

Prognosis.—The disease tends, with more or less rapidity, to total loss of sight. The cases of glaucoma simplex progress for years, with slowly creeping failure of sight. If an acute inflammatory attack take place, sight for the time may be wholly abolished, and it may, when the storm is over, return, but in reduced quantity. It may never return. Both eyes will eventually become concerned. For hemorrhagic glaucoma no good result for vision can be expected, and the eyeball will often have to be removed. For secondary glaucoma, every case must be judged by itself; but the tendency, as in all other forms, is to a bad issue.

Digitized by the Francis Countway Library of Medicine

How far the naturally bad prognosis may be modified by treatment will be subsequently related.

Etiology and Pathogenesis.—Attacks of acute glaucoma may occur during recovery from acute rheumatism with heart lesion, as I have seen in a young woman of twenty years; the eye affected was greatly myopic and was pushed forward conspicuously by the inflammation, suggesting an infarction or embolism. I have also seen it occur in both eyes in a case of chronic cerebral disease whose precise character was not ascertained, and in which the arteries at the base of the brain were completely atheromatous. Usually we must look for explanation to the tissues of the eyeball alone, and we find ourselves confronted by a difficult problem. Innumerable skilful examinations of blinded glaucomatous eyes have been made, but the complexity of the lesions has demonstrated that the key to the whole is not simple.

Glaucoma is most frequent after middle life. Out of 332 cases, 128 occurred between 60 and 69; one at 10, one at 19 years of age (Galleuga[1]). See also Knapp.[2] Laqueur[3] gives six cases in young persons and says that in them it is apt to be monocular.

Usually one eye is affected before the other. In some cases heredity is distinctly influential (chronic glaucoma, girl æt. 17, among whose ancestry the disease was found for four generations; Harlan). Hyperopic eyes are most frequently affected, and about in the proportion of two-thirds of the whole, while myopia gives more than twice as many as emmetropia, or about one-fifth of the whole (Galleuga, l. c.). See also Bull.[4]

Neuralgia of the fifth nerve sometimes is potential (Grünhagen and Hippel demonstrated increase of ocular tension by irritation of the trigeminus in rabbits). Emotional excitement often precedes or precipitates an acute attack: anger, fear, etc. Suppression of habitual discharges, gout, arterial atheroma have their effect (Mooren). Strain of the accommodation is by Javal regarded as a promoting cause, as would be inferred from the prevalence of hyperopia in glaucoma.

We may speak with some propriety of anterior and posterior glaucoma. In the former we have opacity of the cornea attended perhaps by newly formed and tortuous vessels, and connected with conspicuous scleral vessels —the pupil large and irregular, perhaps adherent. Posterior glaucoma exhibits no or few exterior signs, but presents optic-nerve excavation in greater or less degree. Of course this lesion exists in the previous type also.

An understanding of the outlets of the fluids of the eye compels us to refer to its lymph-channels, of which the anterior have been noted, *i.e.*, the aqueous

[1] Arch. of Ophthal., xv., 241, 1886.
[2] Trans. Am. Ophthal. Soc., 1889.
[3] Glaucoma, Archiv f. Augenheil., xxi., 1, 86, 1889.
[4] N. Y. Medical Journal, Aug. 10, 1889.

chamber and its relations to the canal of Schlemm have been mentioned on page 4 and they are to be regarded as a large lymph space. It has been shown that a current comes forward from the vitreous through the suspensory ligament and also finds exit at the filtration angle into the canal of Schlemm. The ciliary body and in a lesser degree the iris are the source of the aqueous fluid. There are other lymph channels along the venæ vorticosæ and other vessels and along the ciliary nerves, and they communicate with the perichoroidal space between the choroid and the sclera and still further with that between the capsule of Tenon and the sclera. Moreover, the hyaline canal of the vitreous (canal of Cloquet), in which was lodged the fœtal hyaline artery, serves as a lymph-vessel emptying into the lymphatics of the optic disc and sheath. From all these posterior lymph-vessels escape takes place through the supravaginal and intervaginal spaces of the optic sheath (see Stilling[1]). The studies of Gifford, mainly directed to the genesis of sympathetic ophthalmia,[2] in a late article[3] give us the latest knowledge in this topic. He finds little evidence of a current in either direction in the lymph spaces of the capsule of Tenon or of the perichoroidia, and while a distinct current backward is found in the central canal of the optic nerve following the vessels out into the orbit, he has also observed a smal contrary current from the intervaginal space into the vitreous. He, however, finds that the channels at the sclero-corneal junction are more active in transportation than has ever been supposed, and that from the aqueous chamber fluid passes into the congeries of vessels called the canal of Schlemm, into the lymph spaces of the cornea, into the subconjunctival tissue, into the perichoroidia, both outside and inside of the ciliary muscle. The greatest part pours into the canal of Schlemm. He finds a current coming forward from the vitreous to the aqueous, and also says that (l. c., p. 202) it is probable that the fluid secreted by the ciliary processes posterior to the zonula divides into two portions, one part passing forward into the posterior chamber and thence through the pupil into the anterior chamber; the other passing back through the vitreous and out through the central canal of the opticus into the tissues of the orbit. The epithelium of the membrane of Descemet prevents the passage of fluid directly through the cornea. He makes the significant remark that the failure to inject the anterior chamber from the vitreous is probably due to the closure of the chamber angle from the increased vitreous tension. Gifford's article is elaborate, and in it are numerous references to the work of others. It completes and clears our conceptions on this subject.

Whatever the remote or exciting cause may be, we have to explain the exaggerated tension either by an excessive supply of intraocular fluid or by its diminished outflow, or by a mixture of both. The optic disc is the weakest spot of the fundus and naturally yields to unusual pressure, while its excavation may perhaps be promoted by special weakness or pathological softening of the structure of the lamina cribrosa, which has been experimentally proved to be possible (Laker).[4] Whatever hinders outflow through

[1] Klinische Monatsblätter, xxiv., May, 1886.

[2] Ueber die Genese des Glaucoms, Bericht Ophth. Gesell. zur Heidelberg, p. 37.

[3] Archives of Ophthal., xv., 153, 1885.

[4] Archives of Ophthal., xxi., 2, 171, April, 1892.

Digitized by Google

these channels will cause accumulation of fluid and increased tension. A natural sequence will be excavation of the optic nerve, engorgement of the emunctory anterior ciliary and other vessels, dilatation of the pupil and anæsthesia of the cornea by impairment of nerve function; and as the origin of the pressure is behind the lens, the anterior chamber becomes shallow by advancement of the lens and iris. The stretching of the fibres of the optic nerve by the distention accounts for impaired vision, both peripheral and central, and the choroidal ring around the disc is caused by the same process inducing atrophy of fibres from the choroid to the lamina cribrosa. The iridescent halos have been shown by Collins to be due to slight changes in the corneal epithelium causing diffraction of light such as may be seen on a foggy night in looking at a light through a steamy window. The limitation of the field on the nasal side may perhaps be explained by the effect of pressure on the retinal arteries, because they are displaced to the nasal side, and their distribution to the temporal side of the retina makes it more difficult to sustain the nutrition of this portion. Direct pressure on the optic-nerve fibres may account for occasional scotomata.

The *pathological lesions* of glaucoma, as has already been said, are very numerous. From the time of H. Muller (Graefe's *Archives*, III.) almost countless examinations have been made, but it will profit us little to enumerate all the morbid conditions which have been described, because every tissue is at some stage the seat of degeneration, and enucleated eyes are naturally those which have advanced far in disease. In a general way it may be said that the blood-vessels of the iris and ciliary body are degenerated, the ciliary processes engorged, and in the vessels of this region, including the canal of Schlemm, accumulation of pigment often takes place. The fibres of the ciliary muscle become atrophied. The choroid, especially in its equatorial parts, shows inflammatory and atrophic changes, and more particularly in the outer layers, *i.e.*, in the large vessels, and lesions can be traced backward to the so-called sclerotico-choroidal ring or plexus which supplies the sheath of the optic nerve near the lamina cribrosa. The chorio-capillaris may become atrophied. The venæ vorticosæ become thickened and their calibre more or less occluded by hyperplasia and outgrowths of the endothelium. We have in these choroidal conditions factors for both increased secretion and abated excretion. The sclera shows evidences of inflammatory action propagated from the choroidal vessels, and it becomes more resistant than normal; while Coccius and Wedl have observed its fatty degeneration. The supra-choroidea, which is a large lymph space, becomes more or less obliterated by adhesions.

Digitized by Google

The vessels of the optic nerve often show signs of inflammation in thickening of the adventitia; but this seems to be the effect of the inflammation of the nerve sheath (the inner sheath) which has come from the choroid by way of the sclero-choroidal ring. From the same cause it sometimes follows that the lamina cribrosa loses its resisting power in some measure.

It remains to add that the peripheral part of the retina is always diseased, showing thickening, cystoid degeneration, atrophy, immigration of pigment, disappearance of the bacilli; all of which are explained by the contiguous choroiditis. In older cases changes extend farther back upon the retina and cause thickening of the vessels, sclerosis of the connective tissue and degenerative changes of the nerve elements. The vitreous may show lesions such as follow choroiditis; sometimes it is detached, but in general its condition is normal. The ciliary nerves become diseased, especially in the equatorial region, and as they emerge with the venæ vorticosæ through the sclera. Atrophy of the ciliary muscle is common, and Schoen attempts to account for excavations of the optic nerve of whatever kind by traction of its fibres. For elaborate studies upon the etiology and pathogenesis of glaucoma, see Birnbacher and Czermak.[1] We have some examinations of eyes obtained soon after attacks of acute glaucoma, the latest by Birnbacher, Graz, 1890, pp. 44, with plates. Some of the vascular changes mentioned are described and figured. Priestley Smith[2] informs us (l.c., p. 75) that he has examined thirty-four specimens, of six of which he gives photographs. His latest monograph offers the best and most conclusive account of the process which we possess. For a full exposition the reader is referred to that. He carries out and substantiates the views first clearly set forth by Adolph Weber in 1877,[3] in which obstruction at the angle of the aqueous chamber was fixed upon as the essential factor in glaucoma. In the previous year Knies[4] drew attention to the same point, but regarded inflammatory adhesion of the iris periphery as the essential condition. Weber accepted this, but also pointed out that purely

[1] Graefe's Arch., xxxi., Abth. i., 297, 1885; Graefe's Arch., xxxii., Abth. ii., and Abth. iv., 1, 1886. Stölting, "Glaucom nach Linear-Extraction," Graefe's Arch., xxxiii., Abth. ii., 177, 1887. Schoen, "Aetiologie des Glaucoms," Graefe's Arch., xxxi., Abth. iv., 1, 1885. Schoen, "Die Accommodations-Anstrengungen und deren Folgen," etc., Graefe's Arch., xxxiii., Abth. i., 195, 1887. Jacobson, "Beitrag zur Lehre vom Glaucom," Graefe's Arch., xxxii., Abth. iii., 96.

[2] "The Pathology and Treatment of Glaucoma," London, 1891, pp. 198.

[3] Graefe's Archiv, xxiii., 2, p. 1, 1877.

[4] Graefe's Archiv, xxii., 3, 163, 1876.

Digitized by the College of Optometry

mechanical obstruction by any cause was all that was necessary. Inflammatory synechia of the iris periphery was mentioned by H. Müller (l. c.). It is figured twice in an article by Pagenstecher[1] in the number of Graefe's *Archives* preceding that in which Knies' article appears. The value and potency of this condition have been, since it was first pointed out, a fruitful subject of discussion. The variety of views held by able men is exhibited in the discussion of Heidelberg[2] in 1888. The opponents of the so-called retention theory, or those who at least regard it as unproven, are Samelsohn, Schweigger, Fuchs, Alt, and others. Among those who hold it are Leber, Snellen, Priestley Smith, Treacher Collins, and many more. Schweigger[3] and Alt[4] regard it as a late complication, and both they and others have examined glaucomatous eyes in which the peripheral synechia did not exist. Weber (l. c., p. 64) speaks of swelling of ciliary processes pushing forward the periphery of the iris and figures it, as does Fuchs,[5] and this condition may by its subsidence fail to be discovered at examination. Moreover, he proved experimentally (l. c., p. 27) that injection of oil into the anterior chamber would bring on glaucoma because it could not find exit at the angle, and in like manner he and Priestley Smith explain the exceptional cases where occlusion does not occur by supposing the fluid of the anterior chamber to be too highly albuminous to find its way out; and this occurs under inflammatory irritation which increases as well the amount of fluid as its density. The number of these exceptional cases is extremely small.

But a difficulty remains in accounting for the origin of glaucoma simplex, because of the variability of the tension and the absence of notable evidence to prove that occlusion or obstruction does really occur. On this subject Priestley Smith, in his last monograph summing up the studies of ten years (l. c., 1891), gives us a reasonable ground of explanation, by showing that the crystalline lens increases in size, both axially and transversely, up to the end of life, and thereby reduces the circumlental space and reduces the vent for fluid from the vitreous to the aqueous chamber. Add to this the changes in blood-vessels due to old age, to gout, to rheumatism, to syphilis, and we realize how the escape of lymph at the angle is retarded, and that the base of the iris, aided by the push of the ciliary processes, will tend to draw toward the angle. We must also bear in mind that the size of the lens is a fixed quantity as compared to the diameter of the cornea or globe, *i.e.*, if the

[1] Graefe's Archiv, xxii., 271, 1876.
[2] Siebenter Periodischer International Ophth. Congress, 1888.
[3] Archives for Ophthal., April, 1891, pp. 503, 522.
[4] "Lectures on the Human Eye," 1880, p. 51.
[5] Archiv f. Ophthal. (Graefe), vol. xxx., 2, 123, with plate.

Digitized by the Internet Archive

latter be small it does not follow that the lens will be in the same proportion but rather the contrary (see Priestley Smith, l. c., p. 107). This explains the occurrence of glaucoma in microphthalmic eyes, because the lens is disproportionately large. It is to be supposed that provoking causes must conspire to excite plus tension when the above conditions are present, and these will be found in the various exciting causes which have been referred to, viz., nervous irritation, accommodation strain (Javal, Schoen), congestive tendencies, and various morbid conditions which change the quality of the fluid secreted by the ciliary gland (see p. 464). The protracted duration of glaucoma and the variations in tension are by such circumstances made intelligible, and we likewise can understand how attacks of acute and subacute inflammation bring on their peculiar and sometimes vehement symptoms. Many other cases are hereby rendered intelligible, such as why intra-ocular tumors may or may not bring on secondary glaucoma; the effect of luxation of the lens, which may or may not cause rise of tension; the optic excavation of staphyloma corneæ and scleræ, and in buphthalmus. Finally, we can understand how glaucoma absolutum sometimes, but very rarely, passes into a state of minus tension, when long pressure has brought on such atrophy of the ciliary gland that secretion is suspended. The analogy of glaucoma to strangulated hernia was pointed out by the late Mr. George Critchett.

The crucial cases which have been held to be inexplicable on Weber's theory are those of glaucoma after extraction of cataract (of which at least one hundred have been reported), with or without iridectomy, and glaucoma in cases of absence of iris, either congenital or traumatic (v. Graefe's [1] reported cases of the latter). The apparent difficulties of these two classes of cases are set aside by two series of examinations by Mr. Treacher Collins, the one a study of ten cases of glaucoma following cataract extraction,[2] the other the study of three eyes without irides in which glaucoma occurred. Of the cataract cases nine had entanglement of either the iris or capsule in the wound and the periphery of the iris adherent, and the other one had attachment of the vitreous to the wound and also blocking of the angle by the iris. Similar cases have been examined by Natanson,[3] in many of which similar lesions existed; it was not found in all, and opinion regarding them must be suspended. In two cases of congenital aniridia with glaucoma [4] there

[1] Archiv für Ophth., xv., 2, 153. See also Snellen, Ophth. Congress, Inaug. Dissert., Heidelberg, 1888, p. 248.

[2] Trans. Ophth. Soc. United Kingdom, vol. x., p. 108, 1890.

[3] "Ueber Glaucom in Aphakischen Augen," Mattieson, Dorpat, 1880.

[4] Ophthalmic Review, April, 1891.

Digitized by Illinois College of Optometry

was found by Treacher Collins a stump of iris externally invisible, which had perversely insinuated itself into the iris angle, both destroying the sight and establishing the theory. In the traumatic case the ciliary processes had been pulled forward to production of the same result.

With all the positive evidences thus conspiring in a cumulative way, we may safely accept the so-called retention theory as the usual and sufficient explanation of glaucoma. That some further details will yet be added to our knowledge we must certainly expect, but we may firmly hold to what we have already. It is the true scientific attitude of mind to be ever ready to receive new as well as to hold fast proven truth.

Treatment.—We may say something about medicinal and palliative treatment which finds place under some circumstances. For example, slight inflammatory attacks, with halos and some pain and a little dimness of sight, may be controlled by quietness, going to bed, absolute rest of eyes, sleep, anodynes, phenacetine, perhaps even morphine. If there be constipation or congestive tendencies, an aperient will occasionally have good effect. More important than these and concurrently with them is the use of eserine (Laqueur, 1878, Graefe's *Archiv*, XIV., 2, 117) in *mild* doses, viz., such as contract the pupil but do not severely stimulate the ciliary muscle. The former effect relieves the filtration angle, the latter tends to obstruct it by inducing congestion and swelling of the ciliary processes, or in so far negatives the desirable effect. The dose should not be stronger than gr. ss. vel. gr. i. ad ℥ i. A still better prescription is eserine gr. i., cocaine muriat. gr. xx., aquæ ℥ i., 3 drops every half-hour until relief is procured. The combined effect of these drugs is myosis with the reduction of tension due to the paralyzing influence of the cocaine both upon the nerves and the vessels. I have found the very best results from this combination, which may be varied slightly and used in frequency as required. Again for glaucoma simplex, with no inflammatory troubles, the use of the eserine and cocaine, or of the former only, is sometimes desirable as a temporary or preliminary resource. Glaucoma simplex runs so long a course sometimes (Mr. Bowman and Priestley Smith together observed a case whose duration was twenty years before an iridectomy, and successfully, was done, *Ophth. Rev.*, 1885, p. 261) that we feel constrained to use palliatives. Again, I have had to treat a case of glaucoma absolutum of both eyes with complete blindness, in a feeble woman to whom the removal of each eye would have been a pitiful calamity, and been able to tide over the severe inflammation by rest in bed, free use of eserine gr. i. ad ℥ i. and cocaine 4% used separately, the former as often as was required for myosis, the latter to quiet pain and abate tension used

much more frequently. A most important addition to the drops is extremely hot fomentations, kept up by the hour until relief is gained; the temperature of the water must be from 112° to 120° F., and by a wad of absorbent cotton or light flannel.

On the other hand, the things to be avoided are mydriatics, of which even cocaine has been known to set up, when used alone, an acute inflammatory attack. The reason for rejecting them is obvious from previous statements. It does not, however, follow that for ophthalmoscopic examination in a quiescent eye one must never bring about moderate dilation of the pupil; on the contrary, I have done it with impunity many times. It may also here be said, and in future again, that after iridectomy it is necessary to use atropine early, *i.e.*, within twenty-four hours, to prevent adhesions from incipient iritis, and that eserine at this period is noxious.

We have thus given due consideration to certain preliminary and incidental circumstances which belong to the practical management of glaucoma, but it must now be emphasized strongly that nothing but an operation done at a proper time and in a proper manner will achieve any real good, or be able to cope with this subtle and dangerous disease.

The discovery in 1856 that iridectomy is capable of curing glaucoma stamps the name of Graefe with undying honor. Up to his time no remedy was known, and now no remedy, except an operation, is of positive value. The experience of thirty years has indicated some of the limitations of the operation and has abated some of the hopes which were at first cherished. The mode in which alone it can be effective was pointed out by Graefe, viz., that the incision must be in the extreme limit of the anterior chamber, and, therefore, either at or one millimetre behind the transparent edge of the cornea. It must be as nearly perpendicular to the surface as avoidance of the iris will permit. It should be from six to nine millimetres in length. Great care must be taken to prevent the angles of the coloboma from being caught in the wound (sometimes by inserting a spatula), and the iris must be excised close to the surface. Generally two strokes of the scissors are needful, and the iris must be well drawn out before being cut. The incision may be made with a lance-knife or by a narrow Graefe cataract-knife; the latter is better suited to cases with very shallow anterior chamber. If the knife be a lance its base should not be more than eight to ten mm. broad. It must be so thin as to bend rather easily when pressed on the thumb-nail, else the point will not be sharp, and the edge must be keen and smooth.

Another operation is sclerotomy. There are two ways of doing it: one is to make an incision with a lance-knife, but this is not to be recommended, because, if large enough to be effective, prolapse

of iris is almost unavoidable, and is disastrous. The suitable manner is that of Wecker. The pupil is brought to decided contraction by eserine, and if incapable of decided contraction sclerotomy should not be attempted because of the probability of prolapse of iris. A Graefe cataract-knife is entered at the angle of the chamber, about two millimetres above or below the horizontal meridian, is pushed across, and emerges on the opposite side at a corresponding point. The incision is carried onward by a to-and-fro motion, until the summit of the arc is almost reached. Then, by turning the edge of the knife forward, all the aqueous is allowed to escape, and the knife cautiously withdrawn. An undivided bridge of limbus about three millimetres long is left, and, by careful management, the iris is neither wounded nor prolapsed (see Fig. 216). The operation is usually done upward not downward as in the cut. With a very shallow anterior chamber, it might be impossible to carry out this operation. The efficacy of the proceeding, however performed, is not fully established, although some have written strongly in its favor. My own experience leads me to favor iridectomy and to reserve sclerotomy for exceptional conditions, as when, for example, there is great liability to intraocular hemorrhage or to cataract by rupture of the suspensory ligament.

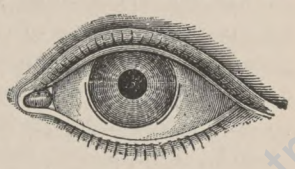

FIG. 216.

The curative value of an operation is greatest in acute and subacute inflammatory glaucoma. In these cases the result may be perfect, even though the operation be not strictly in accord with rules. The longer the delay, the less favorable the prognosis. A week, or even two weeks, has not proved too long for restoration of sight. But the gravest uncertainty attends delay, and Graefe has said that after the third day the restitution is sometimes very imperfect. It is true that an attack may pass off and sight be retained if no operation be done. In chronic glaucoma the measure of benefit will depend on the stage of the disease. If no central vision remains, but little good will be gained. If there be no perception of light and the eye be painful, an iridectomy may be unavoidably attended by loss of vitreous, or by intraocular hemorrhage, or by other accident, and lead to aggravated inflammation. In very painful cases of absolute glaucoma, enucleation is often done. But, as a less afflictive proceeding, sclerotomy may be attempted, and optico-ciliary neurectomy will relieve the pain and ultimately reduce the tension. But it is a severe operation, sometimes unsuccessful, not to be chosen in feeble or irritable subjects. An incision into the sclera upon an oblique meridian between the inferior and external recti muscles, beginning near the equator bulbi and going back about 0.3 of an

Digitized by Illinois College of Optometry

inch, has sometimes given relief. It is called *posterior sclerotomy.* In a case of acute corneal staphyloma with consecutive glaucoma, Schiess reports having divided the cornea twice and afterward done *sclerotomia posterior* six times, and finally an iridectomy, before securing normal tension and vision $_2\frac{2}{0\,0}$ (Bericht, 1891, p. 33).

Stretching of the infra-trochlear branch of the fifth nerve as it comes out near the upper and inner angle of the orbit, on the side of the nasal bone, has been employed with some success (Badal, Abadie) to relieve the pain of extreme cases. It has in some cases mitigated the suffering and appeared to abate the tension; but the *rationale* is obscure and the proceeding by no means well accredited.

For glaucoma simplex, iridectomy is the only reliable remedy. But while some cases yield a perfect result, others startle us by exhibiting worse vision after the operation than before it. This is measurably explained by the enlargement of the pupil and by the astigmatism which is very liable to be produced. On these accounts the iridectomy should be done upward, that the drooping lid may cover some of the coloboma. But cases occur in which a great reduction of sight ensues, which can be explained only by direct mischief from the operation. If the field be narrowed close to the macula, there is liability, according to Graefe (*Archiv f. Ophth.*, XV., 3, 182, 1869), to serious damage to central sight, but Schweigger gives a contrary experience (l. c., p. 503). Hemorrhages into the retina and nerve are liable to occur in all forms of glaucoma after iridectomy, and the loss of sight thus occasioned will be regained in from four to eight weeks. The exceptional cases now alluded to are few, and cannot weigh against the well-known evil tendencies of unchecked glaucoma.

Gruening (Trans. Amer. Ophth. Soc., 1889, p. 287) says that in chronic inflammatory glaucoma with degenerative changes in the iris neither iridectomy nor anterior sclerotomy gives the desired relief. Posterior sclerotomy may do it at times. In simple glaucoma iridectomy (which he does early) generally maintains the status quo ante, and is therefore indicated. In intermittent glaucoma (which seems to be a sub-variety of simple glaucoma) iridectomy is often followed by reduction of sight. The discussion following is interesting.

It remains to state, as to iridectomy, that its performance upon one eye may be the occasion of an acute outbreak in the other and hitherto perhaps unimpaired eye. Of course the second eye must then be operated on. Cases of this kind are infrequent—I have seen but one instance. But, after all, it must be emphatically declared that glaucoma knows no cure but by an operation, and that the most favorable results are gained when

Digitized by Union College of Ophthalmology

it is done at an early period. We find that, as an immediate effect, the tension is not always reduced to the normal, and the longer it continues plus the less satisfactory will be the issue. The anterior chamber sometimes remains abolished for a week, showing either leakage from the wound or continuance of plus tension; the excavation of the nerve will rarely be found much lessened. Sometimes the globe will in a few weeks regain its former state of increased tension, and for such a condition a second iridectomy should be done at a point directly opposite the first, or sclerotomy may be done. In a very few cases the operation fails to make any good impression on the tension and function of the eye, even when the case has not reached the stage of glaucoma absolutum. Graefe called this malignant glaucoma. Weber has offered an explanation and a remedy for this critical plight. He assumes that the lens, which by the loss of aqueous at the iridectomy comes forward, remains in this position, and by its edge continues to obstruct the angle of Fontana. He proposes to press the lens back, after the eye has recovered from the operation, by doing paracentesis of the vitreous, and, while the wound in the sclera is held open by rotating the Graefe knife, the finger is to be pressed on the cornea through the half-shut lid, and the pressure is to be made to bear especially over the coloboma. A successful proceeding is narrated by Priestley Smith (l. c., p. 156). Posterior sclerotomy alone has by others been found effective in correcting this deplorable condition.

One of the not uncommon effects of iridectomy is that the cicatrix remains distended. The wound closes, but after a time the tension rises, and the scar being weaker than any other part, bulges into a cystoid form. It has been assumed that this cystoid scar has much to do with abating intraocular tension, by favoring filtration through its attenuated walls. As an actual fact it is not necessary to the proper fulfilment of the purpose of the operation, but is to be looked upon as an evidence that the iridectomy has not accomplished to the full degree its purpose. For not a few cases of cystoid scar, the explanation is, that the iris has been caught in the wound, either at the sphincter, or by a surface attachment. Sometimes this imperfection in the operation cannot be prevented, because the loss of aqueous does not lower the tension enough to permit the iris to be completely returned; hence conditions favorable to cystoid scar are prepared.

Cataract may occur within a few days or weeks after an operation, because of rupture of the zonula. Undue pressure in manipulating the eye will be the cause, and a blunt knife may be responsible. This is a reason for preferring a Graefe's knife to a lance and emphasizes the necessity for the highest perfection in the instrument, whatever its form. With coexistent peripheral opaci-

ties, Dr. Bull, l. c., shows that the operation materially hastened the growth of the cataract in half such cases, viz., in twenty out of thirty-five eyes.

The formation of cataract may be attended by symptoms of irritation and the only remedy will be its extraction. If forced to this proceeding, a good result is quite possible, but naturally there is considerable risk.

With high tension and a shallow chamber and risk of causing cataract it has seemed to me better to make a narrow iridectomy, say 5 mm., and after some weeks, as circumstances indicate, to repeat the operation. I am sure that a large iridectomy entails great risk of cataract in some cases, however perfect its technical performance.

The explanation how iridectomy can effect permanent relief of tension remains somewhat obscure. Filtration through the scar, especially if cystoid, is an obvious explanation, but how the removal of a sector of iris increases the effect has been imperfectly understood. It cannot be by any direct influence upon the permeability of the canal of Schlemm, as has been supposed, because this is not invariably obstructed and the wound never reaches so far back as this point. The removal of a sector of iris has been experimentally proved to substitute for the long route of the capillaries, a direct anastomotic communication between the arteries and veins at the iris periphery, which gives relief to the circulation of the iris, and in a measure to the choroidal circulation, by the recurrent branches. From this ensues abatement of pressure, and the value of a broad excision is understood. At the coloboma there will be no iris to be pushed forward by swollen ciliary processes, which to this extent makes access to the canal of Schlemm more easy, and promotes the more direct passage of lymph from the vitreous to the aqueous humors. A very interesting case is minutely detailed and illustrated by Priestley Smith (l. c., p. 148), in which iridectomy rescued the eye for twenty years, and without any cystoid scar a minute fistula was found leading from the aqueous into an open space beneath the thickened and elevated conjunctiva. The relief of the retarded lymph circulation is evidently the method of help. Acute attacks are prevented, while a gradual re-establishment of the old obstructive conditions is retarded but not always warded off.

For acute glaucoma not only the operations referred to secure prompt relief, but an incision in a meridian of the globe reaching from the limbus across the periphery of the iris (Hancock) will suffice, and inasmuch as the lesions in this type are not likely to be profound, the explanation is easy, because all that is needed is drainage of fluids for a few hours by an efficient paracentesis. It is, however, far better to do iridectomy for even these cases.

Digitized by Illinois College of Optometry

In performing iridectomy one may properly choose to give a general anæsthetic, not merely to obviate pain, but to lessen the difficulties of the operation, and the danger of untoward complications. One may sometimes resort to cocaine, but we must be able to trust the patient during the actual excision of the iris, which will be painful, and being a mydriatic the substance partakes in some measure of the disadvantages of this class of remedies. Its effect in shrinking the blood and lymph vessels has been known to cause transudation of the aqueous through the cornea and consequent lifting of the epithelium in a bleb (Gruening).

The eye must be handled with great care, the incision be peripheral and of length varying from six to eight millimetres, and the bit of iris completely excised, and an entire return of the membrane without entanglement in the wound secured. Sometimes hemorrhage into the anterior chamber is copious. In chronic cases the lens may present in the wound and require removal.

If prolapse of vitreous occurs the effect will be bad and reaction may be severe enough to compel enucleation. If cataract show itself after a considerable period, it may not be due to puncture of the capsule, but to rupture of the zonula by undue pressure (perhaps a bad knife), or through allowing the aqueous to escape with a gush as the wound is made. Hemorrhage into the vitreous will cause severe reaction. Hemorrhages may occur in the retina which will after several weeks be absorbed and often without serious detriment to sight.

I usually instill atropine, gr. iv. ad ℥i., within twenty-four hours to prevent synechiæ and continue to do so for several days. Should decided reaction follow the operation, we may resort to leeches, anodynes, very hot and persistent fomentations, and if there be iritis we need not hesitate to use atropine freely as in ordinary iritis. The anterior chamber sometimes is not refilled for many days or even for two weeks. If after recovery the eyeball remains hard, a sclerotomy (usually anterior, possibly posterior sclerotomy) may, after a time, be done either upon the same side with the coloboma or on the side opposite. A second iridectomy was advised by Graefe, but the great enlargement of the pupil may be a valid objection if the vision be good enough to make its best preservation urgent.

In hemorrhagic glaucoma unusual risk attends iridectomy, and sclerotomy may be preferred, while enucleation may be necessary as a relief from pain.

If glaucoma take place in myopic eyes, the indications of its presence are often uncertain. The papillary excavation becomes simply an exaggeration of the form which the myopic distention has already impressed upon the nerve disc. Hence it may slope to

Digitized by Illinois College of Optometry

the temporal side and not be very steep on the nasal side nor approach very near the nasal border. The yielding of the ocular tunics in general diffuses the pressure effect, and we therefore find it less sharply concentrated on the nerve. We may, however, easily elicit pulsation of the arteries on the disc, and we note diminutions in central or peripheral vision or disseminated scotomata with especial care. If they are not explained by tissue changes in the choroid about the macula or elsewhere, we must give weight to the possible influence of glaucomatous pressure, notwithstanding the absence of pronounced plus tension capable of being appreciated by the finger. It is readily understood that a highly myopic eye with attenuated walls may be in a state of glaucoma without manifesting marked increase of tension to palpation. Happily we do not often meet this condition, because the general diffusion of pressure commonly protects the nerve from undue share of its influence. When we do come upon glaucoma in myopic eyes iridectomy should not be withheld.

A word may be added as to certain special cases where glaucoma occurs with a *deep* anterior chamber, as in cases of spongy iritis, of cyclitis, and some corneal cases. Paracentesis usually gives relief and may be frequently repeated, while iridectomy will be held in reserve. We are likewise to rely on constitutional remedies for gout, rheumatism, and syphilis. These cases are the *glaucoma anterius* of Snellen. It may be added that Wicherkiewitz (Siebenter Ophth. Congress, Heidelberg, 1888, p. 284) failed to cure a case of glaucoma by iridectomy, and afterward procured relief by antisyphilitic treatment (see also Pflüger, *ibidem*, p. 276).

The probable value of iridectomy has by Nettleship been closely hinged upon the condition of the iris; that if in a state of incipient atrophy or if infiltrated with inflammatory products, the prognosis will be relatively bad. If it act quickly to eserine, the prognosis will be good. General senile degeneration is decidedly unfavorable. Other operators recognize within certain limits the value of the study of the iris as respects operative prognosis, Gruening, Bull, etc., etc., but with less emphasis than Nettleship.

A most instructive paper by E. Treacher Collins, "on the operative treatment of glaucoma, based on the pathological examination of twenty-three eyes which had been variously operated on," is worthy of careful study, and the following passage is pertinent (l. c., p. 175): "Starting with the now almost universally accepted assumption that the tension in primary glaucoma, in whatever way it may arise, is kept up by the apposition of the root of the iris to the posterior surface of the cornea, which prevents the exit of the aqueous humor from the anterior chamber into the spaces of Fontana, I infer that an iridectomy may remedy this condition in the following ways: (1) When the apposition is recent very slight means are sometimes sufficient, the escape of the aqueous and a drag on the iris being enough. It was so, I

think, in Case 19, for in it the angle of the anterior chamber was open on both sides of the sections, though a piece of the root of the iris had been left at the iridectomy. (2) In some of the recent and acute cases I have shown that the iris tears away from its extreme root, thus leaving a large portion of the filtration area free for drainage, even should the remainder of the iris retain its faulty position. (3) In other cases a permanent gap is maintained in the walls of the globe by the prolapse of a fold of iris into the wound. This iris tissue subsequently either becomes stretched and atrophied or ruptures periodically, thus allowing the aqueous to pass through it into the subconjunctival tissue and become absorbed by the lymphatics and vessels situated therein. By these means a new channel for the exit of aqueous is formed, the normal ones remaining blocked. The tension in Case 23 was cured in this way (see also Priestley Smith's case, p. 148, and in this, moreover, recognize the modus operandi of cystoid scars).

"A sclerotomy may produce a permanent reduction of tension in the first or third of the above ways, or it may open up a fresh means of access to the filtration area by forming a permanent gap in the adherent root of the iris, so that excess of fluid could find a direct channel of exit from the posterior chamber instead of passing through the pupil into the anterior chamber. It would thus be short-circuited. I have shown that a sclerotomy incision may divide the adherent root of the iris (Fig. 2), and that it must necessarily do so when the iris is atrophied as well as adherent. An iridectomy or sclerotomy fails to relieve tension when none of the above conditions are attained. An iridectomy may also fail as the result of adhesion of the lens to the sclerocorneal cicatrix, so that it becomes displaced forward, its upper border blocking the freshly-opened-up filtration area.

"It can easily be understood," says Mr. Collins (l. c., p. 178), "why this should be. In an eye with adhesion of the root of the iris to the cornea the pupil would less readily contract than in one where no such adhesion was present. Atrophy of the iris tissue in glaucoma and ectropion of the uveal pigment at the papillary margin are usually associated. The atrophy of the iris is due to the construction of its blood-vessels from pressure of its root against the posterior surface of the cornea. When this pressure has been of long standing adhesion takes place. Hence I think it may be taken for granted that an eye having a pupil with a marked black ring to it, which will not contract well to eserine, has considerable adhesion of the root of the iris to the cornea, and is an unfavorable one upon which to perform an iridectomy for the purpose of relieving tension. (The uveal ectropion comes by shrinking of the atrophied spongy tissue of the front of the iris.) A sclerotomy performed with the intention of making a permanent gap in the adherent root of the iris would be more likely to succeed. It sometimes happens that one portion of the periphery of the iris becomes adherent to the cornea sooner than another. This is rendered evident clinically by the pupil becoming eccentric, it being drawn toward the side on which the adhesion is; also by the anterior chamber being shallower on the side of the adhesion and by there being more marked uveal pigment there. It follows, therefore, that there would be more likelihood of the iris tearing away at its root, if the iridectomy was performed where there was most iris present, where the anterior chamber was deepest, and when there was least ectropion of the uveal pigment, than if done in the opposite direction."[1]

From Horner's clinic we have reports by Sulzer of 103 cases of

[1] Royal London Ophth. Hosp. Reports, xiii., part ii., Dec., 1891, pp. 166–210.

iridectomy. Of these 22% were improved, 37% were held stationary, 23% suffered slight deterioration. In 13% vision became rapidly worse, and in 3.8% was immediately much damaged. Fuchs ("Lehrbuch," p. 388, 1889) gives 39 cases of glaucoma simplex, observed from five to ten years after operation, of which 19 gained better vision or did not lose any more; in 20 vision became worse, either with or without return of plus tension. That is, prolonged observation ascertained good results in half of the cases. Bull gives less favorable results—viz., of 154 iridectomies, vision was no worse for a year or more in 36 eyes, and temporary improvement was followed by worse sight in 10 eyes; while in 108 eyes vision grew slowly worse steadily. Statistics coming from hospital and dispensary practice are always less favorable than if taken among patients in the higher walks of life. The stage of the disease is always a most important factor. It may be truly said that nothing can be worse in most cases of glaucoma (*i.e.*, remembering the exceptions already pointed out) than to do nothing. It is, however, true that for some difficult cases where we are in doubt between atrophy of the optic nerve and glaucoma, full doses of strychnia may be employed for two to four weeks as a means of reaching a conclusion. Moreover, after iridectomy in glaucoma simplex, strychnia may stimulate the damaged nerve fibres and improve sight. The doses must be large, reaching from $\frac{1}{6}$ to $\frac{1}{2}$ grain per diem, by gradual increase.

For an admirable historical sketch of our present knowledge of glaucoma see Prof. H. Snellen (*Ophthalmic Review*, Feb., 1891, Vol. X.). The articles of von Graefe (*Archiv f. Ophth.*, Bd. III., 2, 548, and IV., 2, 127, and Bd. VIII., 2, 242, in the years 1856, 1858 and 1861) will well repay perusal as models of acute clinical observation. His first announcement of his discovery was a "Note sur le guèrison du Glaucome," addressed to the Institute of France in Paris. Numerous papers on glaucoma are epitomized in Nagel's *Jahresbericht*, 1890, pp. 349–365.

Digitized by Illinois College of Optometry

CHAPTER XVI.

CHOROIDEA.

Anatomy.—The most extensive subdivision of the *uvea* is the *choroidea,* which reaches from the ciliary body to the optic nerve. Composed principally of blood-vessels and dark brown pigment, it lies between the sclera and retina, and is divided into four layers. The outermost consists of loose connective tissue mingled with pigment cells of irregular shape either scattered or clustered together, and the whole composes communicating cavities called the supra-choroidea, which are important as lymph spaces. The tissue presents only brownish shreds when torn from the sclera and was formerly called *lamina fusca.* Within this comes the layer of larger choroidal vessels, arteries and veins; next smaller vessels and capillaries, and lastly, a vitreous basal membrane. The last-named is in contact with the hexagonal pigment epithelium which constitutes the external coat of the retina.[1]

The coarser arteries and veins form the bulk or stroma of the choroid; they are in several layers and are mingled with elastic fibres, endothelial membranes,[2] and abundant pigment cells spoken of as stellate, because of their numerous interlacing processes. The short posterior ciliary arteries, about twenty in number, enter at its posterior third, after perforating the sclera obliquely, while near the equator we have the emergence of the venous trunks, four to six in number, which are called the venæ vorticosæ.[3] The arteries anastomose behind with the vessels of the optic nerve, and in front with recurrent branches of the anterior ciliary arteries. A circlet of anastomosing vessels exists at the optic nerve which is of importance: *the circle of Haller.* They have circular muscular fibres, and the veins have perivascular sheaths. The peculiar grouping of the smaller veins as they cluster to unite into the venæ vorticosæ may not infrequently be seen with the ophthalmoscope. The capillary layer (chorio capillaris) destined for nourishment of the external portion of the retina is destitute of pigment. Its meshwork is finest around the yellow spot, and the vessels become straighter and their convolutions more open as they pass forward. They anastomose with the capillaries of the optic nerve, but nowhere with those of the retina. The basal vitreous layer is

[1] See elaborate description of choroid by Prof. H. Sattler, Graefe's Archiv, vol. xxii., 2, 1-99, 1877. [2] L. c., p. 37. [3] *Vide supra*, p. 5.

Digitized by Google

structureless and marked by impressions of the superjacent hexagonal epithelium. It becomes thickened and laminated in old age. The two or three long, and eight to fourteen short ciliary nerves after perforating the sclera pass forward, in the suprachoroidal space, to the ciliary body and iris. At the posterior half of the choroid they give off twigs, which construct a plexus among which are ganglionic cells, and serve as vaso-motor branches. It is said by Schoen that muscular fibres can be traced from the ciliary muscle back as far as the optic nerve. Müller demonstrated the muscular fibres of the arteries, both the circular and in the case of the short posterior and the long ciliary, the longitudinal fibres. The long ciliary arteries belong to the ciliary body and iris.

(The tapetum, the lustrous greenish membrane seen in the eyes of many animals, is a layer of glistening fibres outside of the capillary layer, in some cases containing flat cells.)

The function of the choroid is the nourishment of the retina and vitreous, and to dampen reflection of light by its pigment. Its vessels will be more or less visible to the ophthalmoscope according to the quantity of pigment; in all cases they can be seen as we examine the region of the equator, not the capillaries but the coarser ones.

Albinism.—When from congenital defect there is general absence of pigment in the tissues, the want of it in the uvea is the most serious abnormity. Often the iris may be tolerably supplied, while the choroid is more deficient. The iris will then have a golden-brown color, but if it, too, is very destitute, its color will be a light watery blue. The pupil is small and there will be constant effort to shun light. Often there is nystagmus, the lens may be ill-developed, there may be marked refractive error, there is always amblyopia. The view to the ophthalmoscope is very brilliant, and the choroidal vessels may be beautifully traced. There is often some deposit of pigment around the middle portion of the fundus, while it may even here be wanting. A pink or golden glare often flashes from the pupil even in daylight, as the eye is caught in a favorable position. These persons bring objects very close for inspection, both to compensate for their amblyopia and by strong convergence to abate the nystagmus. Sometimes vision may be aided by correcting refractive errors. Generally they wear dark glasses and may also want them reinforced by side pieces. The defect sometimes runs in families and was first noticed among Africans. I have known two persons who, in spite of it achieved distinction; one was a professor of music, another a chemist.

Coloboma of the Choroid.—This congenital defect may or may not be attended with cleft of the iris; it may be more or less extensive; it may be bridged over at some spot by normal tissue. It

always appears on the inferior part of the eye, running forward from the optic nerve. It presents a broad white or yellowish surface with irregular distribution of vessels, some of which are choroidal and others are retinal. Sometimes the cleft runs into the sheath of the optic nerve, and the disc is usually of an abnormal look, and the retinal vessels may be singularly distributed. Vision is always poor, partly because there may be imperfect development in the retina, and partly because the glaring reflection from the patch of denuded sclera overcasts the retinal image. Sometimes there is other evidence of arrest of development, and nystagmus is frequently seen. Search should be made for refractive errors, especially for astigmatism, and if no glass should be found available or needful, lightly tinted smoked glasses will sometimes be acceptable, and corrective glasses may have a shaded tint.

Choroiditis.

In former chapters we have had to refer to diseases of the iris and ciliary body which extended to the choroid, especially if the morbid process is acute. Such, for instance, is the so-called serous iritis (Descemitis) better named serous uveitis; another instance is acute glaucoma, and there are many other conditions. In such cases the haziness of the media or the obstruction of the pupil make it impossible to view the choroid, and we now are concerned with conditions which do permit inspection.

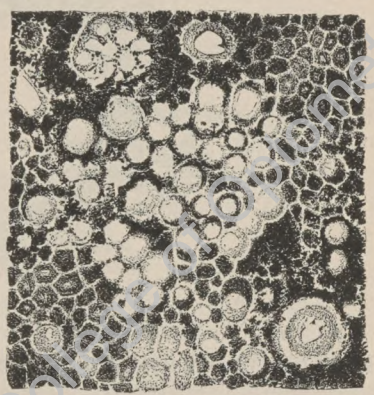

Fig. 217.

Pathology. — Degenerative changes occur both without and with inflammation. Obliteration of vessels at its anterior part is common in old age and notably in cases of senile cataract. Around the optic nerve in the senile eye is usually found a ring of atrophy. The most conspicuous senile change is what is called *colloid* degeneration of the basal membrane (see Fig. 217) (*drüsen*). It consists of nearly transparent bead-like projections of various shapes, sessile or upon stalks and variously aggregated, which push into the hexagonal epithelium and may be seen as minute yellowish-white dots. They are most frequent about the equator; they can occur in any region, are sometimes found in younger subjects, and do not impair vision. Similar structures ensue after inflammations, in larger masses, but as an uncommon occurrence, both on the choroid and on the optic nerve.

Digitized by the College of Optometry

They are smooth, solid, highly refractive, were described by H. Müller. See Sattler (l. c.), Adolf Meyer, Graefe's *Archiv*, XXIII., IV., 159, 1877; *Centralblatt für Augenheil.*, Feb., 1884; Dimmer, *Archives for Ophthal.*, XIV., 65, 1885. (See colored plate No. III., Figs. 13 and 14.)

We find *hemorrhages* in and behind the choroid, and it may be

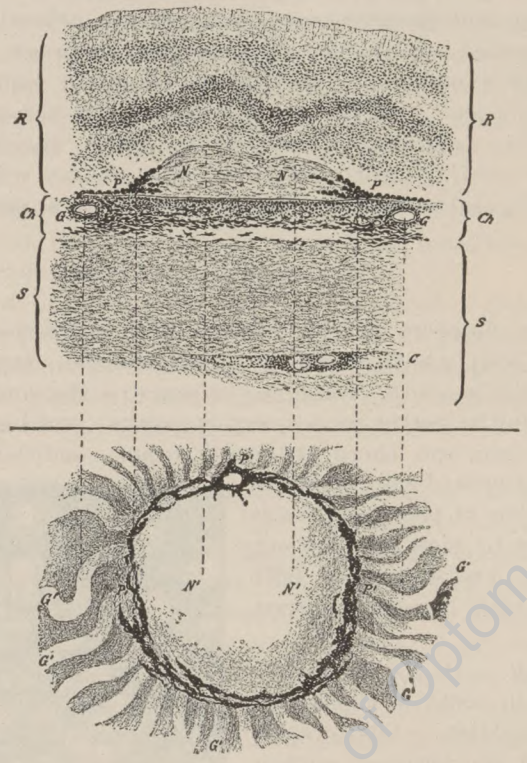

Fig. 218.

thereby extensively detached from the sclera. There is a form of hemorrhagic choroiditis (Brailey) and hemorrhage from injury is frequent. Septic embolisms are common, and micro-organisms have been repeatedly demonstrated. Infarctions, local and general suppurations, take place. Hyperæmia must naturally often arise, but we cannot diagnosticate it except by inference from the congestion of the optic nerve which usually attends it. We see extensive atrophic changes in the choroid due to distention of the globe in myopia both around the optic nerve and at the region of the macula. Similar changes occur in ciliary and scleral staphylomata. Capillaries undergo colloid degeneration.

Fibrous exudation occurs in isolated spots which afterward

Digitized by the Illinois College of Optometry

gives place to connective tissue and atrophy. The membrane may become adherent to the retina or even to the sclera. The noteworthy feature of most chronic inflammatory processes is the great proliferation of pigment, especially at the border of atrophic or inflammatory patches. These are most frequently of syphilitic origin. A succinct and lucid exposition of the pathology of syphilitic choroidal changes is extracted from Michel, "Lehrbuch der Augenkeilhunde," p. 399, 1890.

After speaking of the changes in the walls of the vessels, that they are filled with nuclei and lymphoid cells and beset with nodulous outgrowths, he refers to the patches of exudation upon the hyaline membrane of the choroid which both destroys and proliferates the pigment and gives rise to perforation or displacement of the epithelial layer. He then illustrates by a figure the anatomical character of one of the patches seen by the ophthalmoscope and describes it as follows: "(NN) in Fig. 218 is the profile of the white spot of connective-tissue exudation seen in face at ($N'N'$), while PP corresponds to $P'P'$ and shows how the pigment encircles the patch and also penetrates its edge. The choroid (Ch), and especially its innermost layers, is infiltrated with lymphoid cells. These are most abundant around the larger vessels and cause the (ophthalmoscopic) yellowish white veil which covers them ($G'G'$) and which goes as far as into a ciliary vessel (C) situated at the sclera. The neuro-epithelial (perceptive) elements of the retina (R) are disintegrated and scarcely recognizable. Because of their destruction or displacement no change of level of the retina can be discerned upon the white plaque. Connective-tissue outgrowths also spring from the chorio-capillaris and can perforate the vitreous layer and project into the retina; they may be pedunculated.

"In certain instances atrophy of the choroid may at length ensue concurrent with connective-tissue degeneration and cicatricial retraction of the retina (of this appearance the writer has seen notable illustrations). Its radiating fibres are dragged toward the spot, the rods and cones destroyed or this layer partially detached, and at the edge of the separated spot pigment accumulates which may penetrate even to the external granular layer. The cicatrization may go so far as to drag the retina into the choroid and its radiating fibres be incorporated with its tissue. Nothing but a depression may be recognizable.

"More common than atrophy is it to find thickening of the choroid in greater or less degree. Nevertheless, atrophy befalls the retina. Even at a late stage of the disease we may find exudation between the vitreous layer and the retina, and it may be as thick as the normal choroid. The pigment epithelium may be dis-

Digitized by the Internet Archive of Ophthalmology

placed both into the retina and into the choroid. The walls of the choroidal vessels are thickened by inflammation of all their coats. In the most advanced cases the retina is converted into a meshwork of connective tissue with pigment deposits scattered in it, especially around its vessels, whose walls likewise are much hypertrophied. The retina as a whole is attenuated and the radiating fibres adhere to the membrana hyaloidea. It must be emphasized that patches of morbid tissue and of healthy structure may alternate in various forms and arrangements." The occasional occurrence of large and extreme degrees of atrophy without corresponding impairment of sight is a remarkable fact which has come under the notice of most observers of experience. The exemption of the retina from injury over such large surfaces of choroidal lesion justifies the remark made by Michel, l. c., *vide supra.*

Exudative choroiditis, with small yellowish ill-defined dots, appear sometimes in the periphery or at any other situation. The dots may disappear leaving behind little change visible, or they may result in spots of atrophy. Fig. 219 shows such spots in a recent stage. Fig. 220 shows peripheral spots of atrophy.

The vitreous becomes hazy or liquefied by choroiditis, and the opacities may be localized or diffused—they have already been referred to. As the result of severe and prolonged inflammations, as in cases of phthisis bulbi, the choroid becomes greatly thickened by exudation and sometimes becomes the seat of osteoid and calcareous degenerations.

From the intimate physiological relations of the choroid with the optic nerve and retina, all these parts participate to greater or less degree in their several inflammatory processes, and we often draw distinctions which must be inexact and yet are justified by their conspicuous features. It is, moreover, possible for a morbid process beginning in the choroid to push forward and cause iritic adhesions with little or no outward hyperæmia to give warning of the malady—in other words, inflammation may march in either direction, either backward or forward.

Besides inflammatory changes the choroid is the seat of tubercles and of tumors of various types; angiomata have also been seen.

Symptoms and Subdivisions.—Various names are given to forms of choroidal lesion, such as ch. circumscripta; ch. areolaris; ch. disseminata; ch. centralis, all of which are based upon peculiarities of location and arrangement (see Figs. 221, 223, 224). We find the lesion in spots, one or many, small or large; isolated or confluent; at the equator, or at the posterior pole. There is also a form which, unlike the preceding, does not involve the

FIG. 219.

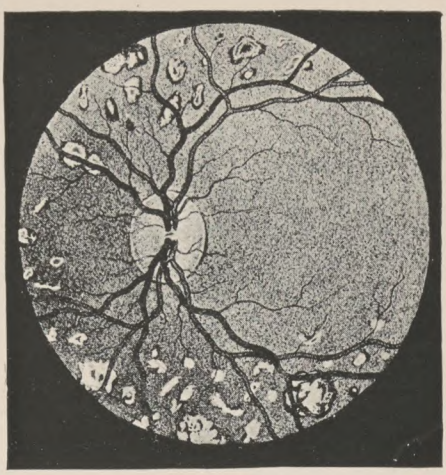

FIG. 220.

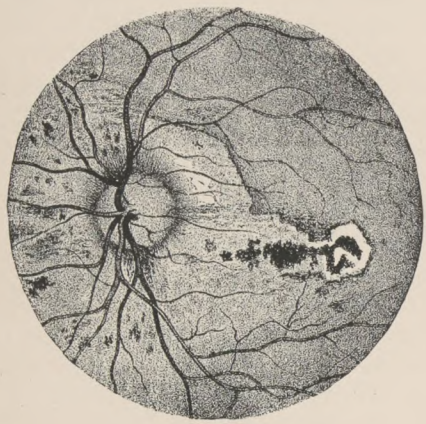

FIG. 221.

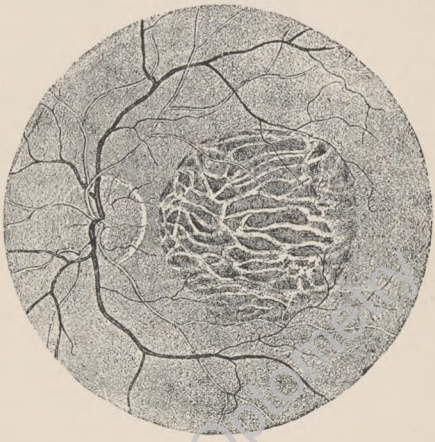

FIG. 222.

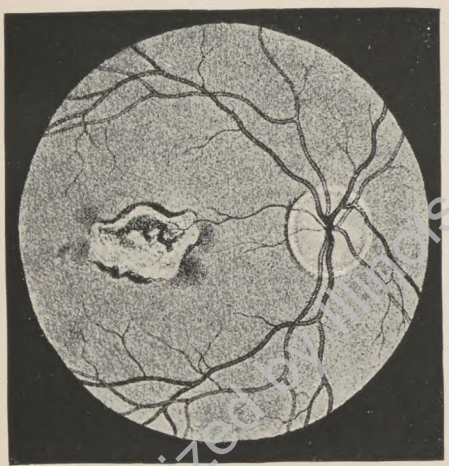

FIG. 223.

FIG. 224.

Digitized by Illinois College of Optometry

Digitized by Illinois College of Optometry

whole depth of the tissue, but affects its inner layers, *i. e.*, the capillary and the superjacent retinal pigment more particularly.[1]

Again, there is a disease of mixed character called choroido-retinitis pigmentosa which is kin to retinitis pigmentosa, extremely chronic and having rather the qualities of atrophic degeneration than of inflammation. Again, certain lesions appear to be distinctively atrophic in quality, because they are of long duration, and notwithstanding the extraordinary degree of alteration in the structure of the choroid both in extent and depth, as seen by the ophthalmoscope, impair vision much less than would be expected.

As already said, it is seldom that we see choroiditis at its beginning. Cases, however, are sometimes caught at the period when small, yellowish, ill-defined dots, not attended by pigment, are scattered over the fundus (see Fig. 219); the vitreous may be a little hazy and the optic disc red. After a few weeks or months we find the spots larger, whiter, flecked and bordered with pigment; perhaps some isolated choroidal vessels cross a larger one. At this time we have the common picture of choroiditis disseminata when atrophy has succeeded exudation (see Fig. 220).

Another form of choroidal disease consists in minute yellow dots whose position is determined by being seen below the plane of the retinal vessels, which have no accompanying pigment deposits, and no atrophy. They are scattered sometimes numerously about the fundus. There will be little or no redness of the nerve, and no haziness of the vitreous. Vision will be reduced. The trouble is commonly syphilitic. Mr. Nettleship[2] figures this condition, which, however, is not frequent. The spots may disappear and no damage to sight remain, while the contrary may be the result. It will not be easy to differentiate these dots from colloid deposits or from tubercles, simply by their appearance. The history of development, the dimming of sight, and their ultimate behavior reveal their quality. They are, however, softer and less conspicuous in outline than are such deposits, and suggest exudation rather than rotund growths.

The atrophic process may be confined to a particular situation, either at the periphery or near the macula, and the patch may be several times larger than the optic disc and of most irregular and pigmented outlines, and within it some traces of vascular stroma may remain. This would be called ch. circumscripta. Such lesions are seen in children, as well as in adults, and they may, if in the periphery, have developed without the knowledge of the patient or injury to sight. The same patch near the macula would cause a

[1] See Hutchinson on "Forms of Choroiditis," Ophthalmic Review, March, 1889, p. 86.

[2] Trans. Ophth. Soc. United Kingdom, v. V., 141, 1885.

Digitized by Harvard College Library

marked scotoma. Another name of what is pathologically the same process is ch. areolaris (Forster), and the name comes from having found the nodule of exudation which in ch. disseminata consists of nuclei and nucleated cells, transformed into fibrillæ, which is their natural development.

During the stage of activity we find little pigment accumulated at the border of the spot and much choroidal stroma may remain—the large vessels perfectly displayed, and sometimes they have a yellow tinge. There may be hemorrhage upon the patch. We may have also a spot of grayish or bluish exudation near by, with a fleecy brush running over the retinal vessels. Originating thus, connective-tissue shreds may reach into the vitreous. If in considerable quantity it may by gradual contraction give rise to radiating or parallel lines in the retina. We find, as might be expected, both retina and choroid participating in the morbid process, and sometimes it is hard to say in which it predominates. For instance, in a certain case, the vitreous was extremely hazy, both with molecules and larger bodies; near the equator were pinkish spots where retinal epithelium had been removed, around the macula were similar spots and also ill-defined patches of pigment, the optic nerve red and hazy, the retinal vessels full. The real condition was choroido-retinitis.

Such is the type of the disease in most syphilitic cases, and, besides pigment deposits about the choroidal lesions, we may find flecks of it in the retina without visible change in the choroid, and even sub-retinal effusion has been observed. Occasionally exudation and hemorrhage are intermingled, and so abundant that with the cloudy vitreous it is impossible to get any clear view of the surface.

It appears, therefore, that we have acute and generalized forms of choroiditis, and chronic forms with localized lesions. The subjective symptoms will vary. There will not be pain, and visual disturbance will depend on the seat of the lesion. It will suffer most with opacity of the vitreous and with central lesions. We cannot always predict how much loss of function will concur with a given lesion. Sometimes the disease consists chiefly in degenerations of the choroidal vessels, and loss of retinal epithelium with little implication of the remaining retinal layers. Such cases are very long in duration and the ophthalmoscopic picture is much more emphatic than the pathological effect on vision (see illustrations in Jaeger's Atlas).

There may even be a circumscribed patch at the macula causing very moderate injury to sight as is shown by a case of Mr. Nettleship:[1] and also central guttate choroiditis without defect of sight.

[1] Trans. Ophth. Soc. United Kingdom, v. V., 147, 1885. Ibidem, vol. iv., p. 164, 1884.

Digitized by Illinois College of Optometry

In the acute forms there may be much subjective luminosity or "glimmering," or the air may seem as it does when rising from a heated stove, later a diffused fog appears, and perhaps a marked scotoma, either central or peripheral.

Prognosis in chronic forms is not good. There is great danger of continuance of the disease, and only in few cases is it definitely arrested. Damaged tissue does not regain function. In acute forms much uncertainty exists, yet fair vision may be recovered, while relapses are to be expected. In case distinct membranes form in the vitreous springing from the retina and exhibiting vessels traceable to the retinal circulation, there will certainly be permanent damage to sight. Diffused vitreous opacity will often clear up. Atrophic choroidal spots entail retinal mischief which cannot be remedied.

Allied to the forms of choroiditis disseminata, is the disease of the tissue which appears in *myopia.* (See page 97 et seq. and Fig. 34.) The changes characterizing progressive or malignant myopia have already been referred to (see p. 99).

In addition to the lesions around the posterior pole we have both with and without myopia spots of disseminated choroiditis over the equator and all parts of the fundus. The vitreous may become fluid and floating bodies swim about in it. There may be visible perivasculitis of the choroidal vessels (Knapp[1]). The retina is liable to become detached, the lens may become opaque either as posterior polar or as soft cataract.

Visual acuity may be impaired when little lesion is to be seen at the macula and a peculiar condition of sight called *metamorphopsia* (*vide supra,* p. 99) occurs in these cases and in cases of central choroiditis without myopia. By this is meant that letters appear to be crooked, one may seem to stand higher than its neighbors. Fine parallel lines will show a curve at the place of fixation. A lady once said to me that the tip of her needle was crooked like the letter S. With increasing loss of sight this symptom passes into a fixed cloud or a scotoma. The explanation of it is that the elements of the retina become disarranged by intrusion of exudation masses and by the irregular stretching to which they are subjected.

Analogous to this anomaly are the conditions known as *megalopsia* and *micropsia.* In the former the bacilli being crowded together are in abnormally great number within the area covered by an image of a given size, and the object is therefore estimated to be larger than it is in reality. In micropsia the bacilli are spread apart, and fewer of them are covered by the image, and therefore the object is estimated to be smallar than it is in reality.

The processes above sketched are a mingling of inflammation

[1] Trans. Amer. Ophth. Society, 1869, p. 120.

Digitized by Illinois College of Optometry

and atrophy. Where the choroid may seem to be entirely wanting, a transparent structure like the thickened basal membrane remains, and the retina undergoes degeneration of its middle layers which may extend to the bacilli and the pigment epithelium. In the end a hyaline fibrous membrane may be substituted for all the retinal layers external to the inner granules.

To the above lesion must be added the occurrence of optic nerve atrophy in extreme myopia, caused in part by the stretching of its

FIG. 225.

fibres and in certain instances by pressure, as denoted by excavation of the disc. The nerve will be bluish-white or gray fading into white; its border fades into the surrounding choroidal atrophy and sometimes for at least part of its outline is hard to be recognized. There will seldom be arterial pulse even on pressure, nor increased tension. A marked reduction in vision exists for which the atrophy is to be held responsible, because no sufficient changes can be found at the region of the macula.

While it has been necessary to refer again to the choroidal lesions which sometimes attend myopia, still another condition is to be mentioned, viz., senile choroidal atrophy at the region of the macula lutea. It does not always appear in old age exclusively, and it presents various appearances.[1] In Jaeger's atlas[2] is a picture in which from this cause all the small capillary vessels, contorted like worms in a bait box, are exhibited over a circular space about three discs in diameter. This may terminate, as I have witnessed,

[1] See Michel, "Lehrbuch," 1890, p. 617.

[2] See Plate, p. 579, Fig. 222.

Digitized by Illinois College of Optometry

in more complete atrophy, just such as is seen in the usual cases of central choroiditis, save that the deposit of pigment is less abundant. The process is apparently merely a wasting of tissue from degeneration of vessels and lack of nutritive capacity. Mr. Nettleship gives a colored plate of this condition from an old person (Trans. Oph. Soc. United Kingdom, 1884, Plate VIII.).

A recapitulation of what has been said as to forms and appearances of choroiditis may be given by reciting the classification of Mr. J. Hutchinson (l. c., p. 88): (1) Choroiditis of myopia; (2) Choroiditis senilis centralis, sometimes simulated in syphilis—in England named after Mr. Warren Tay; (3) Hereditary choroiditis, appears either in early or in middle life, progressive, often attended by other degenerations and sometimes by insanity; (4) Syphilitic choroiditis in secondary stage, usually symmetrical and curable; (5) Syphilitic choroiditis in tertiary stage, improvable, not always curable; (6) Choroiditis of inherited syphilis, which may appear in either of above forms, and is often peripheral; (7) Choroido-retinitis-pigmentosa, due to blows, to inherited syphilis, etc., and usually progressive; (8) Choroiditis in young subjects of various forms and situations, without syphilitic history; (9) Hemorrhagic choroiditis, very rare; (10) Choroiditis with cyclitis and iritis, liable to recurrences; (11) Traumatic choroiditis with laceration and sometimes pigment spots, and occasionally progressive; (12) Tubercular choroiditis.

Something more will be said respecting choroidal lesions in the chapter on the retina.

Treatment.—When we deal with the more acute forms of choroido-retinitis we adopt moderately active measures. We have in most cases to do with syphilis and will select the means suited to the age, health, and surroundings of the patient and the peculiar phase of the disease whether secondary or tertiary. Inunction of blue ointment or of hydrarg. oleatis, 20%, mercurial vapor baths, corrosive sublimate, and iodide of potassium, will be our remedies. In robust persons with great vitreous haziness, muriate of pilocarpine injections, gr. $\frac{1}{6}$, may be used a few times. A continuance of treatment for months is to be expected. Local depletion may be cautiously used. Bright light should be excluded by dark smoked glasses. Confinement in a dark room is seldom advisable. The general health must be sustained, and for this tonics and proper hygiene must be selected.

In the distinctly chronic forms, especially among children where scrofula or hereditary syphilis appears, we rely on cod-liver oil, iron, good diet, a proper mode of living, and if mercurials be deemed appropriate we give very small tonic doses of corrosive sublimate, gr. $\frac{1}{50}$, or mild inunction, subordinating the specific to the generally invigorating methods.

Similar remarks apply to the forms of general choroidal atrophy. We can afford little aid and must simply caution the patients

Digitized by Illinois College of Optometry

against excessive eye work, and do everything to improve the health. Iron and cod-liver oil, extract of malt, good food, etc., are our reliance in the simple wasting forms, senile and otherwise. Sometimes a sort of marasmus coexists and several times I have known such patients to become insane, as if the wasting of the choroid was but the precursor of similar impoverishment of the brain.

The choroidal and other changes which attend upon some cases of high myopia, likewise require hygienic rather than therapeutic measures. To these, attention has already been directed.

Choroiditis Metastatica.

Under this title we have a disease affecting retina, choroid, iris, etc., consecutive to some other and generally distant malady, such as cerebro-spinal meningitis, puerperal fever, febris recurrens, typhoid fever, severe scarlatina, erysipelas, mumps, caries of cranial bones, surgical operations, septic or ulcerative endocarditis, etc. It usually involves the iris, and sometimes shows hyperæmia of the ciliary region. Frequently no outward sign is seen, and attention is attracted either by accidental discovery of blindness or by the white or yellow reflex perceived through the pupil. The general state of the patient is often so critical that this occurrence is overlooked. The eye is apt to be a little soft, not tender, and care must be taken not to confound the disease with glioma. Sometimes the whitish mass covers the fundus in a thick layer, sometimes it fills almost the whole vitreous. It may have blood-vessels upon its surface. A precisely similar condition may spring from injury of the floor of the orbit as I have once seen.

In all cases the disease is of embolic origin and in many instances the vessels have been found plugged with micro-organisms. A more severe type may arise in which putrid infarctions, that is germs, may excite violent inflammatory reaction, amounting to general suppuration of the globe, with attending inflammation in the orbit. Left to itself pus may find its way out of the eye, as in any case of suppuration, and shrinking of the globe ensue.

Pathological investigation of these cases has settled unquestionably their infectious nature by the presence of germs in the vessels, and been a strong argument in proving the doctrine now held on this subject. We need not go into details.

Suppurative choroiditis comes more frequently from local causes than from constitutional, viz., from wounds, from foreign bodies, after operations, etc. As a matter of fact we know that infection is in most cases added to traumatism and we need not dwell upon the clinical features in detail. We generally have panophthalmitis with less or more implication of the orbital tissues.

Digitized by the Internet Archive

Diagnosis.—Leaving out of view the severely acute cases which eventuate in general suppuration and finally in phthisis bulbi, it is proper to call attention to the milder and so-called benign cases, where there is no great reaction and in which the appearance of the eye is little changed. The discrimination between these cases and tumors, especially glioma, is very important. So far as the appearance of the intraocular mass goes, it is often absolutely impossible to rely upon any points of distinction. Color, tension, presence of vessels, situation, extent afford no certain criteria.

The main reliance is the previous history; whether there has been a fever, or cerebro-spinal meningitis, rheumatism, or any of the conditions which can produce metastatic effects. On this point the inquiry must be searching and minute. Some light is thrown on the diagnosis of metastatic choroiditis by the presence of iritic adhesions, which are more likely to exist in pseudo-glioma than in true glioma; there will be perhaps discoloration, or, perhaps, atrophy of the iris; the tension is likely to be minus: there may be tenderness on pressure. A careful estimate of all the symptoms and of the history is the best guide. (See p. 516.)

Treatment.—Considering now only the milder cases, it may be said that only palliative treatment is to be adopted, because as a rule, when examined the case has reached an incurable condition and the eye is innocuous. Under some circumstances we are compelled to decide upon the necessity for enucleation; first, because the history and the diagnosis may be so obscure that serious doubt remains as to the existence of glioma or other tumor—then, of course, one would not hesitate to remove a useless eye rather than run the risk of extension of the disease and death: secondly, the eye may be irritable, be tender on pressure, disposed to recurrent inflammations and to atrophy; in such conditions we would enucleate it.

Panophthalmitis Suppurativa.

It will be convenient at this point to consider this condition, notwithstanding it originates from many other causes than from primary choroiditis. We need give little heed to the multiform causes and may confine our attention to symptoms, diagnosis, and treatment.

Symptoms.—If the starting-point be from without, as after lesion of the cornea, this tissue will present suppuration and ulceration; there will be chemosis, swelling of the lids, and as the process advances, exophthalmus, and great tension of the globe and of the circumocular tissues. On the other hand, if the lesion starts from within, as because of a penetrating foreign body, the cornea may for some time remain clear and the pupil movable. The iris and

Digitized by Illinois College of Optometry

aqueous humor will be muddy, some chemosis will soon show itself, and presently a yellowish reflex will be caught deep in the eye. Sometimes the eyeball is soft instead of hard even during the early stages of the malady; a fact explained by the special implication of the ciliary body. Usually with its progress infiltration of the cornea ensues and the complete picture of suppurative panophthalmitis is seen. Sight is lost at a very early date, and pain from the beginning is distressing.

Diagnosis is almost self-evident. We have great reaction and swelling in gonorrheal conjunctivitis, in acute glaucoma, and in the very rare cases of thrombosis of the cavernous sinus. In the first disease the abundant purulent secretion and the mode of onset declare its character, which may in the end develop into panophthalmitis. In the second disease we have what may be called acute serous panophthalmitis, and the watery effusions with moderate or no secretion, except tears, are sufficient distinction. The last disease is rare and the eyeball is not primarily implicated, although there may be exophthalmus and great œdema, and it may be left out of view. The origin of the attack, whether from without or from within, whether spontaneous or traumatic, the formation of pus in the interior, or on the cornea, and the evident invasion of the deep structures in an acute process, adequately declare the true nature of the disease.

Treatment.—Efforts to save the sight never succeed; we may check the severity of the attack, yet to do this operative interference may be required. The severe pain calls for anodynes and constant application of cloths taken from a block of ice; a piece of ice resting on the eye is not well borne. Leeches to the temple are sometimes useful in robust subjects, but their value is limited to the early stage. The main reliance is on persistent use of cold applications night and day during the very early and progressive period and on anodynes, especially hypodermic injections of morphia in the temple. The degree of relief and the instincts of the patient will dictate the persistence of the application. But very often hot applications are more grateful from the outset and soon under any circumstances the preference for hot fomentations will be very decided. Use absorbent cotton soaked in hot solution of corrosive sublimate, 1–3,000. If tension is very great, we may make an incision across the front of the globe and let out the lens and infiltrated vitreous. Notwithstanding the great infiltration of the orbit and lids and the exophthalmus, enucleation may be the only effective resource. The operation is difficult, is attended with much bleeding and may be severe in its effects. Some cases are on record in which death has resulted. Prof. Graefe, of Halle, and Dr. Bunge have dwelt on the danger of a fatal issue, and have pro-

Digitized by Illinois College of Optometry

posed to substitute evisceration of the eye. In fact, they employ this proceeding in many instances which are not suppurative. The risk of death is not great, yet it is enough to give us pause when we have a feeble and especially also an old subject. We may then resort to the less radical method of emptying the sclera of its contents. This may be done after opening the globe by wiping out the cavity with absorbent cotton and forceps, and washing the interior with corrosive sublimate solution, 1 to 3,000. (See page 544, where the subject has been considered.)

Laceration of the Choroid.

Injuries, such as blows, which make no external mark and seem not to have caused serious mischief, sometimes cause laceration of the choroid. The place of its occurrence may be near the equator, but is much oftener about the posterior pole. It may surround the optic nerve in a crescentic form; it may be at the macula, and be a straight rent. There may be two or more, concentric with each other. Usually the retinal vessels are not torn, even if they traverse the fissure. There is hemorrhage about the spot, and vision is affected, of course most seriously when the rupture is near the macula. When the blood begins to be absorbed the sclera appears, and after a time an intense pigmentation occurs in and about the tear. I have a drawing of a case of long standing in which the deposit of pigment is extraordinary, and the rupture is not less than ten discs in length.

There may, of course, be other injury to the eye, viz., blood in the vitreous, luxation of the lens, etc. With laceration near the macula, metamorphopsia may be produced. Sometimes vision improves and healing of the rupture has been ophthalmoscopically observed. On the contrary, permanent impairment of sight is the usual event, and there may ensue detachment of the retina.

The mechanism of choroidal rupture has been elaborately discussed by Hughes[1] who also gives a full bibliography. There is no treatment for these cases except rest and protection of the eye, and abstinence from use until signs of irritation have disappeared.

Hemorrhage into the choroid is either spontaneous or traumatic and differs from bloody effusions into the retina, in the appearance of the spots. They are in irregular and broad patches, rather than in streaks and elongated forms. The blood may burst through the retina into the vitreous, or be diffused in the suprachoroidea and lift the retina. If the quantity be large the smoothness of the retina, the regular course of its vessels, and the deep color will

[1] Graefe's Arch. f. Ophth., Bd. xxxiii., Abth. iii., 21.

Digitized by Illinois College of Optometry

suggest the lesion. It may also happen that a real detachment of the retina from the choroid will co-exist. We see spontaneous hemorrhage in acute choroiditis and in chronic forms, especially complicating high myopia; we also find it with disease of the heart, sclerosis of the vessels, pertussis, in blood diseases, etc.

Detachment of the choroid, by *serous* effusion is very rare and is analogous to the condition so much more frequently affecting the retina. It has once or twice come under my notice in the living eye. It is common in museum specimens. Detachment arises from tumors, from hemorrhage, and from chronic retino-choroiditis.[1] The globe is apt to become soft.

Choroidal hemorrhage may be the precursor of tumors, it can occur with chronic disease of the choroidal vessels in which there are no large patches of atrophy, and it may give rise to acute glaucoma.

Treatment depends upon general indications, and consists largely in hygienic care both of the eyes and health. Absorption goes on slowly during weeks or months and the blood passes from dark to lighter shades of color, ultimately, as a rule, leaving a spot of exposed sclera, speckled and bordered with pigment.

Tubercles of the Choroid.

Such deposits are found chiefly in cases of acute miliary tuberculosis, and especially of tubercular meningitis. In the latter disease it is not, however, more frequent than in 35% to 40% of the cases (Michel). Children are naturally the most frequent subjects, and it is of course difficult many times, because of the serious nature of the general illness, to investigate the eyes. We find most commonly small specks in the choroid grouped chiefly about the central region, sometimes near the periphery; more rarely there will be a single one bigger than the optic papilla not far from the macula, and occasionally there is a copious deposit of tubercle in the choroid, with cheesy degeneration, invasion of the vitreous and the general aspect of metastatic inflammation. The small isolated specks are generally few, but may number thirty or forty and push their way through the hexagonal epithelium, are dimly white, with a pink areola, as the adjacent choroid loses its color. Sometimes at a very early period hemorrhages co-exist. They have no sharpness of outline, no pigment deposit and lack the brightness of spots of choroiditis. Sometimes the optic nerve is inflamed. They may appear with rapidity, *pari passu* with the general disease, but one case is on record where a local deposit preceded by six months the

[1] See Eisching, "Choroidal ablösung," Archiv f. Augenheil., B. xxiii., 1, 67.

Digitized by Illinois College of Optometry

symptoms of general tuberculosis (Fränkel). They do not impair sight, except when accompanied by neuritis or when, as rarely happens, they set up choroiditis, as will be known by pigment accumulations; generally both eyes are affected. Such cases naturally fall under the eye of the physician oftener than of the ophthalmologist. (See colored plate Fig. 15, taken from case of tubercular meningitis. There is optic neuritis.)

The diagnosis is not simple because the elevation may not be easy to recognize, yet when large enough this will form the principal feature, together with the variations in size, the indistinct border, absence of pigment, and lack of the lustre which characterizes colloid excrescences. To this will be added the youth and general symptoms of the subject. They affect by preference the larger choroidal vessels, and their adventitia. Much study has been given to this subject by pathologists, Cohnheim, Weiss,[1] Haab,[2] etc., and inoculation of Guinea-pigs has demonstrated this lesion as part of general tuberculosis. For a careful account see Michel, "Lehrbuch," 1890, pp. 403–406. There is no treatment. Prognosis is bad. We also find large masses of granulation tumors (tubercles) in the vitreous, the sclera, and the choroid.

Tumors of the Choroid.

Although of rare occurrence, viz., about once in 1,500 eye cases,[3] choroidal tumors challenge attention because of their serious effects both local and constitutional. The most frequent of them, 85%, are sarcomata, and of these the pigmented are largely in excess of the white. In a small number of cases the origin of the growth is associated with an injury—as a rule we know nothing of the cause—and the eye is the primary seat of the disease. Usually we do not meet a case until the tumor has attained an important size, but if its site, as sometimes happens, is at or near the macula lutea, the loss of vision will bring the patient for examination while the growth may be very small (cases by Becker and Knapp). In one instance under my observation a severe retinal hemorrhage across the middle of the fundus was the precursor of a tumor which developed in the periphery and of which the earliest indication was a mesh of vessels which could be very imperfectly examined because of their equatorial locality. The symptoms will vary with the site and development of the growth. Four stages are recog-

[1] Graefe's Archiv, v. xxiii. [2] Ziegler, "Path. Anat.," p. 768, 1884.

[3] Fuchs, "Das Sarcom des Uvealtractus," Wien, 1882. Berry, "Diseases of the Eye," p. 348, 1889, gives the frequency in Great Britain as 1 to 2,218.

Digitized by Internet Archive

nized (Knapp):[1] 1st, the period of early growth while no irritation is occasioned; 2d, the period when inflammation is excited, which is generally glaucomatous and exceptionally takes the form of irido-cyclitis with possible suppuration of the cornea and atrophy of the globe; 3d, where the tumor makes its way to the exterior of the eye; 4th, the period of metastasis to some remote part.

In the early stage the inception is the formation of a mesh of dark and convoluted vessels at some spot in the retina, and a bluish-gray opacity of the membrane (Michel). If within the field of observation we may see the elevation of the tumor, but it is very common for the retina to be lifted from it by serous effusion, and while discerning this we may fail to recognize the tumor underneath. If the retina be not too opaque, we may see the brown surface of the tumor to which the pigment epithelium always adheres, and perhaps irregular and broad vessels coursing over it. Attention will be attracted to the comparatively smooth surface of the retina, that it is not wrinkled, nor the vessels knicked, and that it flutters little or not at all. It is important to use very strong light and to have a dilated pupil. A large mirror of short focus is useful, and intense focal illumination may reveal the vascularity of the tumor. The tension may be normal, but if increased there will be strong suspicion of a tumor. The history may give some aid to the diagnosis. If it appear that a slowly increasing loss of sight has at any time been succeeded by a sudden and notable aggravation and without pain, we suspect tumor. The first effect will be due to the tumor, the second to the detachment of the retina. Under any circumstances the diagnosis is difficult and it may be rendered impossible by hemorrhage into the vitreous. There will be impairment of vision, either central or peripheral, but other subjective symptoms are variable and may be wanting. Sometimes the lens becomes hazy at this stage. In outward appearance the eye will be healthy. The duration of the first stage is from six months to four years (Fuchs), the average of 67 cases being 21 months. At the second stage, when inflammation is set up, there is already increased tension, by the interference of the tumor with the vortex veins and with excretion at the canal of Schlemm, as well as by the bulk which it adds to the ocular contents. If the vision has not already been annulled by total detachment of the retina, it quickly disappears with the symptoms of acute glaucoma. A grayish-green reflex may be possible from the fundus, but no details will be visible. The lens may perhaps be pushed out of place. The acute attack may pass and the eye go into the state of chronic glaucoma. It may yield to the pressure and develop

[1] "On Intra-ocular Tumors," 1869.

Digitized by the Boston Medical Library

scleral staphylomata. In a small proportion of cases considerable exudation occurs from irido-cyclitis and the globe afterward shrinks. Such an atrophied eye has been known to cause sympathetic ophthalmia (Fuchs, l. c., p. 253). After a longer period, which may be more than a year, the growth will show itself on the outside of the eye, either in front or behind, and the rate of progress will then be rapid. There will be cessation of pain, but the deformity will be likely to attract notice. A mass of some size may exist posteriorly without being recognizable. No limit can be assigned to the development of the growth at this stage. It may extend along the optic nerve or make its way out of the sclera by way of the vessels and nerves. There may be separate tumors in the orbit, it may encroach upon the bones and surrounding cavities. In former times very large tumors were sometimes met with, the so-called melanotic cancer of the eye. The disease may penetrate to the brain and provoke cerebral symptoms. During the fourth stage we have signs of cachexia and the local indications of disease of the liver or stomach, or lungs, as the case may be. The liver is the organ usually attacked.

Diagnosis.—If the retina adhere to the tumor there will be no difficulty in its recognition, and by the upright image its size can be approximated. It can happen that a subretinal effusion near the equator presents a smooth, uniform, rounded contour without flattening of its surface or twists in the vessels. Such a condition I have seen and have erred in diagnosis, believing the lesion to be a tumor. Enucleation proved the contrary. In case of subretinal effusion there will be obscurity, but hints have already been given which are important, and besides those which relate to the appearance of the retina the tension of the eye is to be noted. If clearly above normal, the inference in favor of tumor, complicated with sub-retinal effusion, is very strong. During the glaucomatous stage it may not be possible to escape error, in spite of careful inquiry into the history. If, however, iridectomy result in only temporary or negative relief, enucleation will be likely to be obligatory. It has been said that strong light and full magnifying power should be used in ophthalmoscopy, aided by dilated pupil. The employment of a convex lens 3″ to 4″ focus held near the eye and the mirror at about six or eight inches from it (Becker) increases both the illumination and the enlargement, and meets the special requirements of these cases.

Treatment.—Enucleation at the earliest period is imperative. The optic nerve should be severed as near the apex of the orbit as possible; it is not difficult to excise ten to fifteen millimetres if the globe be drawn well forward by putting the finger behind it, or slipping a strabismus hook over the nerve to make traction, and

Digitized by Harvard College Library

crowding the scissors well backward to make the cut of the nerve. Hemorrhage is with this proceeding copious, and is to be checked by pressure of the finger or thumb in the orbit. It is far better to take the time needful for the purpose, than to pack a sponge into the orbit and apply a compressive bandage. Getting out such a sponge will give sharp pain and perhaps reproduce hemorrhage. Perchloride of iron is objectionable. When active bleeding ceases a firm flannel bandage may be applied upon a sponge and absorbent cotton laid on the outside of the lids. The dressing may be removed in six hours.

If the growth has invaded the orbit we may be obliged to empty the cavity, and the operation may be formidable. We may have to split the outer canthus to get sufficient access to the growth. The best instrument is a large pair of scissors curved on the flat and with blunt points; with this and a strong pair of forceps the mass can be turned out of the orbit with the least bleeding. The shut scissors serve admirably for scraping or tearing away the periosteum and growth from the bony walls, and very little cutting will be required, except at the beginning and finish of the operation. If the bone has been attacked, we may remove with a sharp spoon as much as may be feasible, recognizing that we may penetrate adjacent cavities. Invasion of the cranial cavity is, of course, highly dangerous. Chloride of zinc paste is sometimes applied to the bony wall to cause exfoliation of diseased bone; doing this is not without risk. Great care will be taken to adopt antiseptic precautions, and if bleeding is not controlled by pressure or by torsion, a small thermo-cautery (Paquelin) may be used, but with extreme caution if the vessel be at the apex of the orbit. One instance in which I used a cautery proved fatal by meningitis. It appears from statistics by Fuchs (l. c.) that of forty-five cases of removal of the contents of the orbit only two resulted in death.

Prognosis.—Local return of the disease is rare and occurs chiefly when it has advanced outside of the globe. The possibility of an isolated tumor in the orbit is not to be forgotten. On the other hand, reproduction of the disease in a distant locality, especially in the liver, is highly probable. Many times the ultimate history remains unknown, and it is impossible to get accurate statistics on a large scale. Of twenty-two cases, Fuchs had knowledge of the result in seventeen; respecting them thirteen had died; of these, eleven by metastasis, and he was satisfied of immunity in one case only (l. c., p. 276). Metastasis occurs within periods varying from a few months to five years; the average is two years. The tumors most likely to show malignity are the pigmented round- and small-celled sarcomata: the spindle-cell, colorless, and slightly vascular tumors show less disposition to metastasis. The sarcoma

cells have been found floating in the blood-vessels of the choroid, showing that they actually enter the general circulation. While the liver is the most frequent place of deposit, the stomach, the lungs and other tissues may be involved. No form of tumor is so liable to be reproduced by metastasis as sarcoma. Griffith (*Ophth. Review*, Dec., 1891, "Prognosis of Choroidal Sarcoma") tabulates 23 cases whose ultimate history was known. Of these 14 were alive after periods varying from three to ten and a half years, and the 9 who died reached their end by local or remote effects of the disease after periods varying from one year and four months to six years and eight months. Prognosis is better for the younger subjects. See other references in Griffith's paper.

Of the other kinds of tumor which may be found in the choroid we have angiomata, fibromata, chondromata, tuberculosis, and inflammatory swellings. Choroidal tumor has been known in a very few instances to cause sympathetic ophthalmia.

Ossification of the Choroid.

In eyes which have long been shrunken by irido-choroiditis we not infrequently meet with ossific formation in the inflammatory tissue. There may be either plates and spiculæ or there may be a mass or a thick shell of bone. Very perfect specimens have sometimes been found. The stump is usually small, very flattened, and if grasped between thumb and finger, the bony mass will be recognized by its hardness and sometimes by its rough projections. Sympathetic irritation of the fellow-eye is sometimes caused by these stumps, and they should then be extirpated. A sharp hook should be used to seize the globe and give control over it, else the operation will prove troublesome.

Digitized by Illinois College of Optometry

CHAPTER XVII.

THE RETINA.

An account of the appearance of the retina when viewed by the ophthalmoscope is given on pages 34 et seq. We shall learn most about it by the direct method, which, to be exact, presupposes transparency of the media, and proper correction of optical errors both in the observer and the patient. If these conditions cannot be fulfilled, the indirect method will yield much information, and in the case of patients confined to bed is often the only one available. The blood-vessels are a principal object of study, and they help us to form a judgment as to the state of the retinal tissue. Allowance must be made for considerable variation in transparency of the retina, especially near the optic nerve, and in direct ratio to the depth of pigmentation of the fundus. On the nasal side of the nerve the retina is always thicker than on the temporal and is less clear. It is not necessary to repeat what has been said, p. 47, and an attempt to relate minutely the physiological variations in the look of the retina would be of little profit. Each observer must learn them for himself, and must govern his judgment of objective signs by examination of visual acuity, and of the visual field, and of the color sense, both central and general. In most cases of defective function, we can see tissue changes which, if not strongly pronounced, are evident enough; but when we bear in mind how intricate is the structure of the retina it will not be surprising that functional impairment may exist which will not betray its physical cause to the moderate magnifying power at our command.[1]

Minute Anatomy of the Retina.—It consists of ten layers which, beginning from the inner surface, are named as follows: 1, membrana limitans interna; 2, optic-nerve fibres; 3, ganglion cells; 4, internal reticular or molecular or granular layer; 5, internal granule layer; 6, external reticular layer; 7, external granule layer; 8, membrana limitans externa; 9, bacillary layer or rods and cones; 10, hexagonal pigment epithelium. Besides, the retina is traversed by numerous fibres of connective tissue which run perpendicularly through it and are known as the fibres of Müller. In Fig. 226, the relation of these parts is schematically represented. The optic nerve

[1] As to the appearances of the macula see G. Lindsay Johnson, Archives of Ophth., Jan., 1892, with colored plates.

Digitized by the Google Corporation

fibres, the ganglion cells, the outer and inner granule layers and the bacilli are the nerve structures; all other parts are considered as modifications of connective tissue. The membrana limitans interna serves to separate the retina from the vitreous. The succeeding five layers, from the optic nerve fibres to and including the external reticular, also called intergranular layers, are grouped together as the *cerebral* layers of the retina; the outer granules, the membrana limitans externa, and the rods and cones are called the *epithelial* layer of the retina. This distinction fixes upon the latter as the percipient elements, and regards the former as vehicles for conveying impressions. To the former must be added the hexagonal pigment cells, in which we find the visual purple, and which penetrates among the bacilli to a greater or less degree according to the stimulus of light. Very delicate processes run in from the pigment cells among the bacilli, and along these (not the cones) the molecules push themselves in greater quantity as the light is more intense.

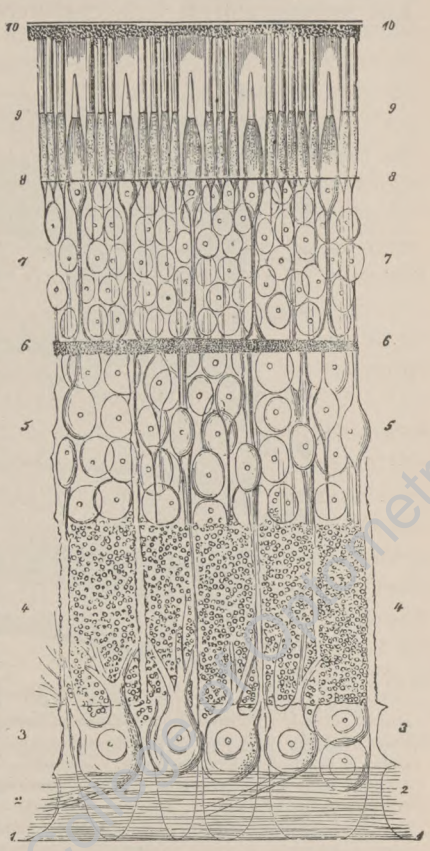

FIG. 226.

In various parts of the retina the layers are in different proportions, for example, near the papilla the optic fibres are in excess. At the region of the macula, important changes occur, while the fovea centralis has a character wholly unlike the rest of the retina. The fovea has a slightly oval shape, being horizontally 0.2 mm. and vertically, 0.15 mm. in diameter and measures in the visual field 1½° (Bunge). It does not exist in the embryo and is not yet visible at birth (Kölliker). The optic nerve layer disappears, the ganglion cells instead of being in a single layer as elsewhere, increase to seven or eight layers, the external granules are found, and the cones are enormously elongated and multiplied; while the rods do not exist. All other layers are wanting. The number of cones at the fovea is estimated at 7,000 (Kuhnt). We can thus understand the high sensibility of this spot where

Digitized by Illinois College of Optometry

nothing but the epithelial structures are found. At its margin (ora serrata) the retina becomes very thin, the optic nerve fibres and the ganglion cells almost cease, while the reticular layers disappear and the connective tissue becomes more abundant. The retina as it appears in section is well shown in Fig. 227, from Poncet. Its structure is nearly normal.

The optic fibres as they enter the retina, lose their neuroglia and become simple axis cylinders; they unite at acute angles in a

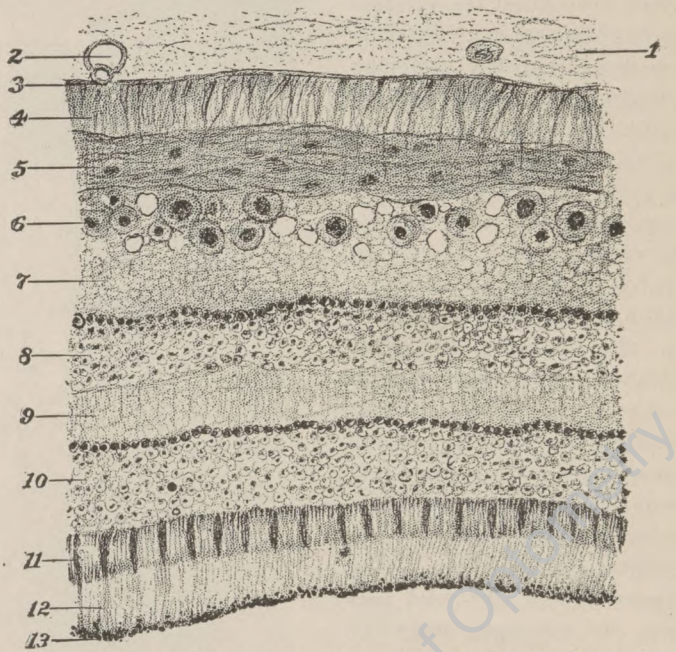

FIG. 227.—Section of Normal Retina. ×350.—Eye removed for Sarcoma, Retina detached but almost normal.—1. Vitreous; 2, hypertrophied cells of vitreous; 3, membrana limitans interna; 4, fibres of Muller (they are slightly hypertrophied)—they are part of the connective-tissue framework; 5, layer of optic nerve fibres, nuclei more numerous than usual; 6, layer of ganglion cells; some of them have undergone colloid degeneration; 7, internal molecular or reticular layer; 8, layer of inner granules; 9, external molecular or reticular layer—in this as in the internal molecular layer the fibres of Müller are abnormally distinct; 10, layer of outer granules; 11 and 12, layer of rods and cones, in which a distinction is made between the body of each element, 11, and the process, 12, which is its continuation. The line which separates 10 from 11 is called membrana limitans externa, it is not marked by a figure; 13, layer of epithelial pigment in polygonal cells. Fibres of Müller are also called radiating fibres.

plexiform manner, and as has been said can often be seen coursing upward and downward from the disc and sloping off along the principal vessels. Such of them as go transversely outward toward the macula are much finer than the above named, and we find that to the macula a large quota of fibres is directed, amounting, as Bunge found, to about one-fourth of all the fibres contained in the optic nerve. For the ophthalmoscopic appearance of the normal fundus see Plate III., Fig. 1, and colored plate Fig. 1.

Digitized by University of Toronto Library

Opaque nerve-fibres constitute a congenital peculiarity which is not very infrequent. By this is meant that certain fibres coming from the papilla retain their neurilemma for a distance after they enter the retina. They are grouped into a brush or cluster, which is usually either above or below, and exhibits considerable variety of form. It may be short and clumpy, or sweep in a long, wispy plume, and usually along the principal vessels. I have seen a case in which most of the centre of the fundus was whitened by such a condition. Such a case is figured in Liebreich's Atlas. To recognize the nature of this peculiarity, observe that the white or yellowish patch conceals the edge of the disc, has a glistening, striated surface, and the markings are in parallel lines; the edge is marked by a hair-like fringe. The surface is intensely white or yellowish, the vessels are partially concealed, and fine glistening markings appear. Surrounding parts of the fundus will be normal; sometimes the optic nerve looks very red, but it will not be swollen. In slight cases there will be no impairment of sight, in extreme cases there will be amblyopia. Sometimes spots of opaque nerve-fibres crop out, remote from the principal locality, but very rarely does the abnormality reach beyond the macula or its vicinity. (See Plate III., Fig. 2.)

Coloboma of the macula is an extremely rare congenital anomaly which resembles a patch of choroidal atrophy situated at the macula. It is a white or pinkish-white spot, usually without any pigment-deposit such as characterizes choroiditis, although in the colored plate given by Loring[1] some pigment granules are shown. Vision may or may not be reduced. This lesion has by many been disputed. I have not seen it. Testimony and argument in behalf of its nature and existence are found in several papers condensed by Manz, in Jahresbericht der Ophthalmologie, 1885, p. 279. See Plate I., Fig. 11, opposite page 114; illustrations taken from Fuchs.

Silex reports two cases under this title, but thinks them to be choroidal atrophy and not coloboma.[2]

Diseases of the Retina.

Hyperæmia, apart from actual inflammation, is not easy to make out. The blood-vessels are often tortuous, are in some cases very abundant, they vary in size in different persons, and there are so many varieties possible within physiological limits that it is difficult to be sure that a particular case is abnormal. We form a judgment chiefly upon the appearance of the optic nerve. It

[1] "Text-Book of Ophthalmoscopy," Plate III., Fig. 4; description p. 94, 1886.
[2] Archives of Ophth., March, 1889, p. 86.

Digitized by Google

may be very red, but this often arises from refractive error like hypermetropia or astigmatism, from prolonged use or excessive weeping, from irritation of a foreign body in the cornea, from sympathy with some other morbid process, like iritis, etc. In short hyperæmia is rarely idiopathic, whether in the nerve or retina, but symptomatic.

Nevertheless, there are cases of enlargement of the retinal vessels from orbital tumors, from obstruction to the cerebral vessels near the sphenoidal fissure, from emphysema of the lungs, from an open foramen ovale, from aneurism, etc. A condition of teleangiectasy is figured by Liebreich, and also a case where the veins were converted into a series of bead-like expansions.

The intraocular circulation is in great degree independent of fluctuations in the general system, and though an off-shoot from the blood-vessels of the brain, it participates little in its circulatory changes. A sharp distinction is to be made between idiopathic hyperæmia, and hyperæmia attendant on inflammation. With meningitis it is common, with brain disease its occurrence is variable.[1]

Pulsation of the retinal arteries, as a result of resistance to the influx of blood from increased intraocular tension, as in glaucoma, has been referred to; the same effect can arise from reduced impulse of the heart. We see this in insufficiency of the semi-lunar valves of the aorta, and less markedly with aneurisms of the arch and of the ascending aorta. The combination of aortic insufficiency with insufficiency of the mitral valves diminishes the tendency to pulsation of the retinal vessels (Michel). A different kind of pulsation, viz., one which is less abrupt and reaches over a longer stretch of the arteries occurs in exophthalmic goître.

Venous pulsation as a physiological condition has been referred to (page 51), it also occurs with aortic insufficiency, with hypertrophy of the heart, with increase of arterial tension. During syncope the arteries will be small and the veins full.

Anæmia of the retina, in the sense of diminished flow of blood independent of obstructive causes which will be referred to, scarcely presents itself. The retinal circulation may for a time be arrested, as in migraine and syncope, and in anæmic persons sometimes the color of the blood becomes pallid, and its impoverished state promotes hemorrhages, as in pernicious anæmia, chlorosis, etc., and inflammatory changes may be added both in the nerve and retina.

Spasm of the Retinal Arteries, Megrims, Epilepsy of the Retina.—In consequence of vaso-motor irritation the retinal arteries may be firmly contracted and completely arrest the circulation. Irritation of the sympathetic in the neck causes their con-

[1] See Gowers, "Diseases of the Brain," p. 173, 1887.

Digitized by Illinois College of Optometry

traction, while extirpation of the superior cervical ganglion induces enlargement of the vessels in much slighter proportion (Becker).

Suspension of the circulation causes partial or total blindness in one or both eyes. A so-called blind headache is a mild form of the disorder, and the vessels of the brain as well as of the eye may be affected.

The visual disturbance may be the most conspicuous phenomenon, and should not be regarded as of serious moment. An illustration is the following:

Mrs. W., widow, forty-three years of age, was brought to me by Dr. Burchard. She seems well nourished, but is said to have lately lost flesh. Has an anxious expression, been greatly worried by business cares, and been under much excitement. Three months ago she began to have partial obscurations of sight in the right eye. In a little time the sight would "go out," as she said, every twenty-four hours, and everything be dark for fifteen to thirty minutes. This condition affected the right eye only, until a few evenings since. Then, while at the opera, she became totally blind for about one-half hour, and, as she says, was in total darkness. Since then the same thing has happened every evening, and lasted from a few moments to half an hour. At my interview with her in my office she exclaimed that sight was leaving the left eye. Her vision had been previously examined and found to be $\frac{20}{20}$ in each eye. While the dimness existed I inspected the left eye with the ophthalmoscope. The arteries were reduced in size, the veins were normal, no other notable appearances. The attack passed in a few minutes, and then the arteries grew larger and were like those of the other eye. There were no signs of effusion or inflammation. My advice was to use bromide of ammonium, to take nourishing food, and try to secure exemption from anxiety and care.

In another instance in a man, the blindness was complete in both eyes for sixteen hours and then perception of light began to return. I saw the man twenty-four hours after the beginning of the attack and by the ophthalmoscope recognized great pallor of the optic nerve, tenuity of the arteries, the veins about normal. No effusion or swelling of the nerve or retina; tension normal; pupils active. Could count figures at six feet. By inhalation of nitrite of amyl, vision was restored in twenty minutes to the normal degree and the intra-ocular circulation was resumed.

The patients may be subject to migraine, and besides the headache and nausea have that kind of scotoma which is marked by a bright and angular outline constituting the so-called fortification line, because it resembles a fort with bastions. The attacks are usually of short duration, so far as vision is concerned. They sometimes take on the form of hemianopsia, which implies that the disturbance is cerebral and not ocular. This will be again referred to. In case of prolonged or severe attacks, inhalation of nitrite of amyl from three to five drops at a time will bring speedy relief. Prognosis is good. General treatment would consist of tonics and sedatives of the milder types, and attention to derangements of the stomach, the uterus, or any debilitating causes. One must be

Digitized by Illinois College of Optometry

careful not to confound these cases with the temporary obscurations which occur in glaucoma, and attention must be given to the state of ocular tension and to the possible existence of excavation of the nerve, etc. These conditions being absent, heart tonics are indicated, viz., digitalis, nitro-glycerine, etc.

Ischæmia of the Retina.—The condition to which this name is applied has been recorded a few times and it was first mentioned by Alfred Graefe.[1] The question will naturally arise as to how it may differ in essence from the spasmodic suspension of the circulation just now referred to. The subjects have always been persons who have been much reduced by illness. In a case which I saw in consultation with Dr. Knapp[2] the child, three years of age, had been much prostrated by whooping cough and when convalescing suddenly became totally blind, losing perception of light in both eyes. The optic nerves were white; in the left eye some arteries as fine as threads could be discerned, in the right none could be found. In both eyes the veins were of extreme tenuity. There were no other lesions. We have, therefore, seriously diminished heart's action and an impoverished state of the blood. That this situation alone may not be an adequate explanation, is probable from the observations of von Graefe upon cholera patients. He examined the retinal circulation, when they were in the last stages of prostration and never failed to find blood in the vessels, and they had correct vision so far as could be ascertained. He, therefore, thought that some obstructive cause was to be assumed in cases of ischæmia and that it was likely to be found in the optic sheath. It seems likely that we have a partial thrombosis behind the eyeball and that these cases are to be referred to this head. Both eyes have been affected.

Treatment is directed to promote the action of the heart and improve the health, and on the other hand to diminish resistance to intraocular circulation. Rest in bed, good food, digitalis and stimulants and tonics meet one indication, while paracentesis corneæ and iridectomy have been resorted to for the other. The former may be tried for twenty-four or forty-eight hours before employing the latter. Alfred Graefe did iridectomy on the tenth day of total blindness in one eye, and on the thirteenth day of total blindness in the other eye with restoration of perfect vision. Inhalation of nitrite of amyl will also suggest itself. As a rule the prognosis is good, but atrophy of nerve may result.

Embolism and Thrombosis of the Retinal Vessels.—Each of these conditions may occur separately, or in combination. There may also be complete or partial suspension of the circulation. The

[1] Graefe, Archiv f. Ophth., viii., i., 143.

[2] Archives Oph. and Otology, vol. iv., p. 448, 1875. See also Pooley, Trans. Med. Soc. State New York, 1878, p. 155.

Digitized by Illinois College of Optometry

obstruction may be in the central arterial or venous trunk, and may also take place in one of the retinal branches[1] (Saemisch). The first case of embolism of the arteria centralis retinæ was seen by von Graefe[2] in 1858, and he founded his diagnosis upon the intraocular appearances and upon the presence of endocarditis which was due probably to a severe blow upon the chest. The correctness of his judgment was verified by an autopsy eighteen months later. The remnant of a plug was actually found in the retinal artery just behind the eyeball.[3] The symptoms of this case were very striking and its pathology beautifully simple. Very few such observations have been made since. Some cases have seemed to point to partial arterial occlusion, because some blood was evidently circulating in the retinal arteries and vision was not wholly abolished. An emphatic feature of thrombosis is the presence of hemorrhages with signs of obstruction to the venous circulation, while vision is not so entirely destroyed as in cases of complete embolism. Still another lesion which may happen is hemorrhage into the sheath of the nerve (Magnus[4]), and a case in which this was assumed was reported by Sands[5] in 1866. A further complication giving rise to a different ophthalmoscopic picture is related by Angelucci.[6] He found at the autopsy the central vein completely occluded by a plug, also surrounded by a mass of exudation and clot which extended some distance up and down the nerve, and through the compression of this material the artery where it lay in contact with the venous plug, was completely shut up; behind this point it contained blood. In another case he found similar conditions without any hemorrhage in the nerve (l. c.)

An admirable discussion of this subject is given by the late Dr. E. G. Loring and illustrated by many plates in his "Text-book of Ophthalmoscopy," vol. 2, p. 59, 1891. See also "Embolie der Arteria Centralis Retinæ," Fischer, Leipzig, 1891, a treatise founded on 148 cases.

Symptoms.—Always there is sudden loss of sight without pain or external symptoms. In Graefe's case, which was the type of simple and complete embolism of the central artery the blindness was total. The optic nerve at the outset was extremely pale, the arteries reduced to a minimum, their finer twigs invisible, the veins smaller than usual, but fuller toward the equator than at the nerve;

---

[1] Monatsblätter f. Augenh., 4, 32, 1866, with plate.

[2] Graefe's Archiv für Ophth., Bd. v., Abth. i., 5, 136, 1859.

[3] Schweigger, "Vorlesungen über den Gebrauch des Augenspiegels," Taf. iii., Fig. 10, 1864. See also his "Handbuch der Augenheilkunde."

[4] "Die Sehnervenblutungen," Leipzig, 1874.

[5] Trans. Amer. Oph. Soc., 1866, p. 2.

[6] Monatsblätt. f. Augenheilk., xvi., 444, 1878.

Digitized by Columbia College of Physicians

there were no hemorrhages and no opacity of the retina. Neither phosphenes nor arterial pulsation could be excited by pressure; the tension was slightly minus. In ten days a slight to-and-fro movement appeared in the veins, and soon a little perception of light was gained in the inner and upper part of the field. Within a week a dense white opacity appeared over a considerable region around the macula and at its centre the fovea shone as an intense cherry-red spot. Its brightness was ascribed to the effect of contrast, and the color to depend on the shining of the choroid through the extremely thin membrane. Subsequently the appearances became those of complete atrophy of the nerve. Appearances such as are described, are depicted by Liebreich (Atlas, Pl. VIII., Figs. 4 and 5). In Fig. 228 from Magnus' Atlas the white exudation in the macula contrasting with the bright fovea is shown, while the optic nerve is also infiltrated and the arteries filiform.

FIG. 228.

We find variations from the above symptoms, in that sometimes the nerve becomes red again, and may be infiltrated. Autopsy has shown that there was a mixture of embolism and thrombosis. Again hemorrhages may occur. In Nettleship's[1] case of arterial embolism it appeared that the obstruction occurred at the branching of the artery in the papilla, that it happened twice and that one branch was left pervious. Hemorrhages indicate either that the arterial flow is not absolutely arrested, or they point to venous thrombosis as the chief lesion. Embolism of a single arterial branch on the retina was accompanied in Saemisch's[2] case with dif-

[1] Oph. Hosp. Reports, vol. viii., p. 1, 1874.
[2] Monatsblätter f. Augenheilk., iv., 32, 1866.

Digitized by the Illinois College of Optometry

fused opacity, but no hemorrhages, while in Knapp's [1] case there were abundant infarctions.

The central retinal opacity in some cases begins immediately, it may be delayed a week, after a time begin to disappear, and the borders of the arteries may show a white streak or be converted into white threads. The same kind of opacity occurs in the retina after contusions of the optic nerve in the orbit, or after its section. Experiments by Berlin on rabbits and frogs showed that when caused by section of the nerve, the change began in the nerve fibres and ganglion cells and extended to the remaining layers. Gowers found the retina infiltrated with small round cells. While embolism of the trunk cuts off the arterial supply to the inner layers of the retina, the outer layers possess their proper supply in the chorio-capillaris. Infiltration of the nerve may or may not take place.

Thrombosis of the vena centralis will present various symptoms depending on whether the calibre is entirely or partially closed. If closure is complete, the nerve is nearly obliterated by hemorrhage and effusion, abundant hemorrhages cover the retina and accompany the vessels, and mixed with the patches will be yellowish exudation. The veins will be tortuous and enlarged, interrupted by blood and exudative plaques, the arteries may be small and straight, contrasting with the sausage-like (Michel) look of the veins. The retina will be soaked and there may be a diffused opacity about the macula.

Imperfect closure of the venous trunk will exhibit fewer hemorrhages and these chiefly in streaks about the nerve, the retina will be less œdematous and opaque, but the contrast between the veins and arteries will be conspicuous. Pressure may or may not cause pulsation in the arteries and it may appear in the veins. Vision is greatly reduced, sometimes destroyed, is sometimes eccentric. Sometimes it will be partially restored. Tension is not affected. The progress of the case will be slow, and there may be recurrences of hemorrhage.[2]

As an exception to the features thus related, the case examined by Angelucci [3] should be mentioned, where thrombosis of the veins caused at the same time occlusion of the artery by pressure and there were no hemorrhages either in the nerve or retina. The arteries were in places empty and the papilla was infiltrated.

Primary retinal phlebitis, *i.e.*, confined to the veins of the fundus, is described by Mules [4] in three cases, and of one a colored plate is given. The affected veins are much swollen, dark for a part of

[1] Archives of Ophthal., vol. iii., No. 1, p. 38.
[2] Priestley Smith, Ophth. Review, iii., pp. 1, 33.
[3] Monatsblätter f. Augenheil., xvi., 450, 1878.
[4] Trans. Ophth. Soc. United King., ix., 130, 1889.

Digitized by Union College Library

their extent, and the rest pale and collapsed—in two cases hemorrhages; in one case the cherry-red macula with surrounding white œdema; in two cases total central scotoma. The onset of the thrombosis in two was slow, in one was sudden. Sight not restored; in two cases all ophthalmoscopic traces ultimately vanished. A case is also delineated by Loring, "Text-book of Ophthalmoscopy," 1891, Plate I. The cause is attributed to an overdose of quinine. See below, p. 700, remarks from De Schweinitz.

The isolation of the retinal circulation explains the peculiarities produced by embolism, because it communicates so sparingly with other vessels, viz., only with the choroid at the papilla. Sometimes a small twig (Schwalbe) runs up parallel to the central artery to the papilla and may account for some instances where the vascularity of the papilla was subsequently restored (Schmidt).[1]

Embolism of cerebral arteries happens in conjunction with retinal embolism. The ophthalmic artery may also be occluded and in one case irido-cyclitis ensued (Schmidt), while in another (Nettleship) acute glaucoma demanded enucleation.

In all cases, in order to establish the diagnosis of embolism, some source must be found whence the foreign body can be derived; from vegetations in the heart or aorta, aneurisms or atheroma of arteries, from thrombosis of the uterine veins or of those of the lower extremities after pregnancy or abortion, etc.

Thrombosis occurs mostly in elderly persons, whose arteries have degenerated and whose heart is likely to be fatty, or who may have marked emphysema and whose circulation is therefore feeble. It may come from a real phlebitis or periphlebitis.

Diagnosis.—A sudden loss of sight, attended by great reduction in the calibre of the retinal arteries and bleaching of the nerve; followed soon by haziness of the central region of the retina, bespeaks arterial embolism. When hemorrhages are abundant, the probabilities are in favor of thrombosis or of a mixed condition involving both arteries and veins (see Priestley Smith, *Oph. Review,* Vol. III., 1884, p. 47). What has already been said need not be repeated. It will not always be possible to decide what the precise lesion is, nor is it important apart from its scientific interest. Fig. 3, Plate III., presents some of the features described, but is spoken of as simply apoplexy of the nerve and retina. The cases are not frequent and

Prognosis in general is bad. A case seen by Mr. White (*Oph. Review,* Vol. I., 49, 1882) recovered sight under the eye of the surgeon who was making pressure on the globe, and he saw the circulation re-established. In a case seen by Mr. Eales (*Oph. Review,*

[1] Graefe's Archiv f. Ophth., xx., 2, 287, 1874; and see also Trans. Am. Ophth. Soc., 1890, p. 672.

Digitized by Illinois College of Optometry

Vol. I., 139, 1882) vision was restored in nine months, with the exception of a central scotoma. There is one case (Nettleship, *Oph. Hosp. Reports*, Vol. XI., 111, 260, 1887) in which both eyes became blind at successive periods, each retaining in the upper part of the field a sector where light could be perceived. Hirschberg reports a case where each eye was affected (*Centralblatt f. Augenheil.*, Jan., 1884) and at the autopsy the obstruction was not found. Recovery after embolism must mean displacement or disintegration of the plug. After thrombosis it would not seem so improbable, provided absorption occurred before destructive changes had ensued in the nerve and retina. Yet very rarely has any useful vision been restored.

Treatment can, in the nature of the case, accomplish little. Iridectomy and paracentesis have been tried in vain, with a view to lessen the opposition to the circulation within the eye. An embolus if loosened must soon be again caught fast, and the only hope would be in its becoming disintegrated. To this end as Mauthner proposed Mules (*Ophthalmic Review*, 1888, p. 245) and Gifford (*Jour. of Am. Med. Assoc.*, April 12th, 1890) have, in cases where a retinal branch was involved, resorted promptly to massage of the globe, and re-establishment of the circulation has been witnessed. For thrombosis there would only be general indications of tonic and recuperative treatment and the hope of absorption. Unhappily in nearly all the cases, atrophy of the nerve and retina is the outcome.[1]

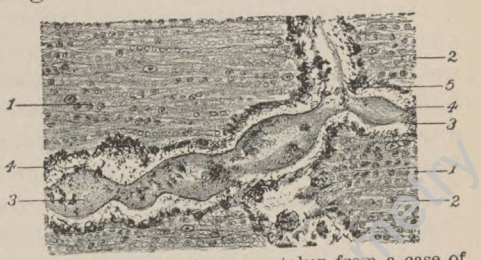

FIG. 229.—The specimen was taken from a case of hemorrhagic glaucoma. 1, Layer of optic fibres between which the internal granules are visible: 2, some ganglion cells; 3, varicose vessels, their walls have separated from the lymphatic sheath: 4, lymph sheath deeply pigmented and much larger than the vessel.

Hemorrhage into the retina presents itself under other conditions besides those just mentioned, viz., from injuries, as a complication of choroidal and retinal inflammations, in cases of choroidal atrophy in myopic eyes, and it also happens idiopathically. We find it in young persons of delicate health, in such as have a hemor-

[1] The literature of this subject is large. See a paper by Loring, Am. Journal Med. Sciences, lxvii., 313, 1874. See also Michel, Archiv f. Ophth. (Graefe), xxiv., 2, and Ophthalmic Review, vol. i., 52, 1882. A paper by Priestley Smith, Oph. Review, Jan. and Feb., 1884, is of much interest. For a very complete and minute discussion of the whole subject, see "Text-book of Ophthalmoscopy," Loring, part 2, pp. 59–97, 1891. Also "Embolie der Arteria-centralis-retinæ," Fisher, Leipsig, 1891, p. 246.

rhagic diathesis, as an effect of menstrual disorders, or of pulmonary emphysema, or of severe coughing or sneezing. It specially occurs in pernicious anæmia under the form of small streaks clustered about the nerve and scattered over the surface, while white patches may appear and sometimes neuritis. Severe retinal hemorrhage with atrophic changes in the choroid occurs in connection with great losses of blood at the menopause. The gouty or rheumatic, or syphilitic dyscrasæ, are frequent factors.

In new-born children retinal hemorrhages occur with considerable frequency (10% to 32%), especially when the labor is difficult. Permanent injury may not remain, but as the region of the macula is the favorite situation, a grave amblyopia may ensue for which no ophthalmoscopic lesion may afterward appear. This fact accounts for a certain number of cases of congenital amblyopia (see remarks on strabismus). Œdema of the retina and also of the optic nerve are met with, although less frequently, in these subjects.[2]

In all cases of spontaneous hemorrhage a weakened condition of the vessels is to be presupposed or a perverted quality of the blood, or both combined (splenic retinitis). The association of retinal hemorrhage with cerebral or other visceral apoplexy is not infrequent. The capillary aneurisms found in the brain may also exist in the retina and be the explanation of hemorrhage (see Fig. 203). While these are too small for the naked eye to discern, aneurisms have been noted which were readily visible and numerous (Hirschberg).

It is, therefore, important to study the remote as well as the immediate occasions for the occurrence, because not only will the possibility of recovery be often bound up with them, but the welfare, and even the life of the patient may be concerned. If the hemorrhage be not at or near the macula, the injury to sight will be moderate and be occasioned in part by slight turbidity of the vitreous, while a larger bleeding will do mischief to other regions of the retina by interfering with the conductivity of the nerve-fibres, and possibly by setting up inflammation. When it occurs in the fovea centralis, a dense central scotoma ensues, and sometimes the patient speaks of seeing things of a red hue. Abundant hemorrhage may deeply cloud the vitreous, and it is often impossible to trace the source of the effusion until the media have cleared up. The most common starting point in such severe cases is the ciliary body or choroid, while from the retina the bleeding is usually less

[1] See case with autopsy by Elizabeth Sargent, Archives of Ophthal., xxi., 1, 39, 1892.

[2] Naumhoff: Graefe's Archiv f. Ophth., xxxvi., iii., 180–246, 1890.

Digitized by the Internet Archive

copious, and, therefore, confined to its own tissue. Because the retinal vessels are situated in its anterior layers, it follows that recovery of sight is often possible, but if the blood should invade its posterior layers, more or less dimness of vision must be expected to remain. Allusion may be made to hemorrhagic glaucoma, and to the possibility of a choroidal sarcoma being imminent (see Fig. 229), and to the bleedings which sometimes follow operations for cataract or iridectomy.

The blood may be absorbed without leaving any visible alteration of tissue, while, on the other hand, a pigment-deposit may occur, or a whitish substance be left, which indicates inflammatory exudation, followed by secondary changes. Sometimes extensive cicatrizations and pigmentary deposits remain, especially if choroidal disease co-exists. When bleeding takes place into the macula, it is rare for sight ever to be perfect, and even if much be gained, metamorphopsia is liable to remain. A word may have some of its letters displaced or distorted, and the letters on either side of these be natural.

Retinitis apoplectica, or *hemorrhagica* as it is called, occurs chiefly among elderly persons and presents very marked features. Both the nerve and retina may be involved, there may be chronic renal and perhaps cardiac disease, and the blood-vessels be affected by atheroma or syphilitic degeneration. The affection is sometimes in both eyes. The attack comes suddenly, with great loss of sight, and without premonitory symptoms, except sometimes headache and dizziness. The lesions in a well-marked case are as follows:

The nerve is hyperæmic and swollen, its tissue œdematous, and edges indistinct—in some cases the outline is obliterated. The veins are full and tortuous, the arteries small, and some may be thread-like. The retina has a watery look, and the fundus is spattered with small hemorrhages, many of which are in short lines running parallel to the vessels (see Fig. 3, colored plate). There will also be larger and irregular patches of blood, and these usually by the side of a vessel. It will be noticed that one or more arteries are exceedingly reduced, or may be absolutely empty, and they will be close to or lost in one of the blood-patches. Near the hemorrhages, spots of yellowish exudation will be found, which may be extensive and numerous. If hemorrhage has been copious, the vitreous will be a little hazy, and further obscure the retina.

The features of various cases differ greatly. Sometimes the stress of the lesion is on the optic nerve, while only a limited space in the retina is affected (see Fig. 3, Plate III.). Sometimes the retinal lesion is at the macula and its vicinity. Sometimes the ecchymoses run along one vessel, partly covering it up, and spreading around it,

attended with blotches of yellow exudation, and not far from them will be found some empty and thread-like vessels. It was the early opinion that the starting-point of this affection was an inflammation of the retina, and that the hemorrhages were sequent to the inflammation; but these cases are really instances of obstruction and thrombosis of one or more arteries, and the inflammatory œdema, the hemorrhages, and the exudation, follow upon the obliteration of small or larger vessels. Such effects are possible in the retina, because its vessels anastomose sparingly with others, and if obstructed cannot obtain any aid. In fact, the branches which go to the macula and to the periphery, and also to other portions of the retina, constitute regions of so-called terminal vessels in the sense which Cohnheim has emphasized, and these localities, therefore, are liable to the peculiar changes he has described in treating of embolism. On this view the retinal process is an infarctus, with the same alterations which are found in the lungs, liver, and joints under similar conditions. Taking into account the modifying influence of the anatomical character of the retinal circulation, we have in these cases illustrations of the effect of chronic endarteritis or so-called arterio-capillary fibrosis as a purely local condition. The changes in the walls of the vessels have preceded the outbreak and their character has been of late carefully investigated. See article by Meigs: *The Medical Record*, Aug. 24th, 1889. Under the microscope rupture of the vessels is rarely found, and the hemorrhage is therefore chiefly by diapedesis. Phlebitis, with thrombosis, may be confounded with the above affection; but close attention will reveal the differences (see p. 551). See also Loring (l. c., p. 88, part 2).

In all that has been said about hemorrhages into the retina the distinction must be borne in mind between the cases dependent on changes in the composition of the blood such as pernicious anæmia, malaria, menstrual disturbances, etc., and those in which vascular changes, whether arterial or venous, are primarily at fault. In these two classes prognosis will be different, local features will vary, and treatment be dissimilar. I have refrained from portraying in detail these several classes, but call attention to the distinction to be made among them.

Another class of cases deserves mention, viz., those among new-born children. Naumhoff (Graefe's *Archiv*, XXXVI., 3, p. 180) examined the eyes of 47 new-born children who had died at or soon after birth, and found under the microscope choked disc, retinal œdema, and hemorrhages in the retina and choroid. All these lesions, and especially the last, are due to the compression produced by protracted labor and a narrow pelvis. The hemorrhages were the result both of rupture and diapedesis. They were

often absorbed without leaving any traces visible to the ophthalmoscope. Congenital amblyopia and congenital atrophy of the optic nerve may sometimes be explained by the lesions referred to.

Prognosis depends much on the general condition of the patient and on the extent of the bleeding as well as on its situation. A breach in the macula will seldom permit of perfect restoration. There will either be metamorphopsia or scotoma. With young and vigorous persons entire absorption may occur, while glistening or opaque white spots and black pigmentations often remain. In elderly subjects there may be partial recovery of sight, but the future as to cerebral hemorrhage is often ominous. Atrophy of the optic nerve may ensue, and the spots of hemorrhage or exudation be subsequently designated by whitish tissue; or, if the blood be fully absorbed, insterstitial changes in the retina may preclude useful function. The obliterated vessels are usually not restored, and those which at first were pervious may be slowly thickened and diminished, and bordered with white lines.

Treatment.—The local measures are simple, viz., rest, avoidance of light, abstention from use. Dry cupping and in very plethoric subjects leeches to the temple might be indicated. Exceptionally it may be proper to use atropia. The object is to promote absorption and to prevent recurrences. The course to be adopted will be determined by the general condition, the remote cause. With young subjects invigorating treatment, fresh air, generous diet, proper rest will be indicated. Attention must be given to menstrual disorders. In one of my patients removal of the ovaries was undertaken. In cases of pernicious anæmia the restoration of the function of the stomach and food assimilation, coupled with blood and nerve tonics, iron, strychnia, etc., will be regarded. To counteract the hemorrhagic diathesis, a visit to chalybeate springs, and the persistent use of iron and tonics will suggest themselves. Everything that will help digestion and assimilation, will be laid under contribution; the hypophosphites are often useful.

In elderly subjects, where the heart and arteries and perhaps the kidneys are at fault, the indications are different. There has often been great mental strain, and there is apt to be much nervous excitement. Suspension of business cares or literary labor, avoidance of worry, procurement of sleep, proper action of the bowels will naturally suggest themselves. Mild cathartics, moderate use of bromides, sometimes diuretics, will be proper for certain cases. For persons with a small and especially a hard pulse indicating high arterial tension, nitro-glycerin in doses of gr. $\frac{1}{100}$ has become an established remedy. Change of scene and quiet and cheerful surroundings are often important. Small doses of iodide of potassium may be useful. For gout and rheumatism, the special

remedies will be chosen. In short the treatment must be based upon a proper appreciation of the general condition of the patient and varied according to circumstances. Especial regard must be had to the dangers of cerebral hemorrhage, of which a retinal bleeding may be the signal. From one to twelve months and perhaps a longer time will be required for the completion of the recuperative process.

Miliary aneurisms have been seen in the retina similar to those of the cerebral arteries, and they may occasion hemorrhages

Retinitis.

Symptoms.—In describing inflammation of the retina, we are obliged to take account of the optic nerve, because in most cases both are concerned; yet it happens that each may be inflamed without apparent participation of the other. The subjective symptoms are dimness of sight in every possible degree, sometimes limitations of the field, and micropsia, megalopsia, or metamorphopsia, and frequently irritations of the retina in phosphenes, scintillations, or glimmerings:—there will be no pain. Objectively the eye shows no external alterations, either in its blood-vessels, in the action of the pupil, or in any way, unless retinitis be complicated by other diseases. By the ophthalmoscope we find a variety of appearances, consisting of exudations and alterations of tissue and of the blood-vessels. Before describing them it is well to call attention to the variations in the look of the retina, which are not morbid in the sense now intended. Such, for example, are the white and often abundant nerve-fibre striation running out of the disc, the turgid vessels, the red or leaden-hued nerve, with indistinct edges, to be found in some cases of marked hyperopia: to these add the flashing glitter seen mostly in the eyes of young persons, and sometimes called the shot-silk appearance, and the variable look of the macula in different persons and at different ages (see p. 50). Moreover, the blur which results from astigmatism or from haziness of the media must be carefully discriminated. Always must the observer be careful to determine the refractive conditions before he pronounces upon the status of the retina. To this end the direct ophthalmoscopic method is far to be preferred to the indirect. The following pictures present themselves as types of retinal inflammation apart from its etiology

a. Capillary congestion of the optic nerve without swelling, its edges partly or wholly blurred; the fibres which pass into the retina are uncommonly distinct above and below as fine parallel lines, they fade gradually and suggest a slight degree of infiltration. The

Digitized by Illinois College of Optometry

veins are turgid and wavy, the arteries of normal size. There may be a whitish line along the large vessels. No other textural change, except possibly one or two yellowish-white dots in the retina near the macula. This may be a low grade of inflammation, and is of doubtful significance.

b. Deep redness of the optic disc, the edge almost or wholly obliterated by the striation radiating into the retina about its entire circumference, the veins full and dark, the arteries large. Both are tortuous, and the light-streak is scarcely to be noticed—the tissue of the retina soaked with transparent fluid, and evidently swollen—the pigment-epithelium not to be recognized (*i.e.*, the normal granular look is wanting) and the reflex from the fundus is reduced. This is a case of moderate serous effusion.

c. Slight, perhaps no hyperæmia of the nerve; edges not well defined; vessels not noticeably altered; the retinal tissue pervaded by a gray, misty infiltration, seen best at the edge of the illuminated space, or by reduced light, and this cloud occupies the middle portion of the fundus; the fovea too dark, but impossible to be defined; the small vessels of the macular region conspicuous by their number and size; and along the large vessels a border of more positive gray; slight plastic exudations, such as are often found in syphilis. This is sometimes called retinitis centralis.

d. A rare condition is a patch of exudation in or near the centre of the fundus, partly concealing the vessels, of considerable extent, with soft edges, and no other changes, except bright hyperæmia of the nerve. A local plastic exudation.

e. At the macula a group of bright lustrous dots, few or many and apt to be arranged in radiating lines, while the nerve may be a little red; likely to be a mild albuminuric lesion. In the highly developed types of this condition, we have the nerve swollen and hyperæmic, its edges blurred, its tissue infiltrated, the adjacent retina swollen; a little distance from the nerve there will be white patches of irregular form; near or at the macula lutea are similar patches, which may be rounded or arranged in radii, like an imperfect star; extravasations along the vessels and in spaces where no vessels are visible. The white plaques or dots may be of a dull hue, like greased paper, or be intensely white and glistening. Sometimes the hemorrhages are more numerous than the white deposits; sometimes they are few, and large surfaces of white are seen. I have a picture of a case in which the fundus reminds one of a "mackerel sky" in full sunlight, so numerous and fleecy and bright are the clouds. In some cases pigment-deposits and choroidal lesions can be seen. The remarkable white infiltration of the retina found after embolism and thrombosis is not included in the present description.

Digitized by the College of Optometry

f. There are cases in which slight infiltration of the retina, haziness and redness of the nerve, and fulness of the vessels, are associated with turbidity and floating bodies in the vitreous, perhaps with hemorrhages or even with new vessels in the vitreous. This is the retinitis attendant on some cases of iritis and choroiditis, and is sometimes styled retinitis proliferans.

g. In panophthalmitis or suppurative choroiditis, the retina is infiltrated with pus, but the condition belongs to pathological anatomy rather than to clinical study.

h. Still another condition occurs after a blow upon the globe. It is a faint grayish-white patch, perhaps attended by hemorrhage, sometimes at the equator or at the central region, which comes almost immediately and will generally disappear in a day or two.

From the above it is seen that the features which command attention are changes in the color, texture, and outline and level of the nerve; opacities and infiltrations of the retina; the course and size of the vessels, the clearness of their light-streak, infiltration and thickening of their walls (perivasculitis); hemorrhages; we may also have sub-retinal effusion, pigment-deposits, and choroidal disease; complications on the part of the vitreous, lens, iris, and other structures may co-exist.

Etiology.—It is rare to find retinitis as a simple or idiopathic affection. It is rather the effect of constitutional dyscrasia, of blood disease, of disease of the brain, of lesions of other parts of the eye, or of injury. Exposure to extreme light will cause the milder types, as seen in Arctic explorers and among travellers in hot climates. But the chief causes are kidney disease, diabetes, syphilis; from menstrual disturbances, leucocythæmia, poisoning by lead and by phosphorus, etc. The most common is albuminuria, from whatever cause; next may be syphilis, while association with brain disease is a frequent occurrence.

Acute Traumatic Retinitis.—Mention should here be made of the appearance on the retina, after a blow upon the eye, of a circumscribed grayish-white patch, which lies below the vessels and may occupy either the middle or peripheral parts of the fundus. It was first described carefully by Berlin (*Klin. Monatsblätter*, 1872, p. 46), and a case is given by Jackson, with colored plates, in Trans. Am. Oph. Soc., 1888, p. 68. It comes soon after the injury and may entirely disappear, unless there have been hemorrhages, within twenty-four hours or three days. There may be temporary astigmatism from commotion of the lens. Marked amblyopia is caused, and this may not disappear until long after the visible changes have vanished. Sometimes there is from the beginning amblyopia without any exudation. The condition is liable to be

Digitized by the Internet Archive

overlooked, because the pupil is often rigidly contracted (see p. 478; see also Loring, "Text-book," Vol. II., p. 174).

RETINITIS SIMPLEX.—Such a name is justified by the fact that we sometimes are unable to assign any special cause for the lesion, while the appearances may be the same as in some cases of syphilitic retinitis, or even when some remote disease, like menstrual disorders, is considered to be the provoking affection. The purpose is to call attention to the lesion as shown in Fig. 17, colored plate. We have hyperæmia of the nerve, its edges not specially ill-defined, but concealed by a faint infiltration which resides in its substance and extends over a large area of the adjacent retina. The bluish haze is thin and delicate without specks or striations or plaques, but is evidently chiefly a serous effusion into retina and nerve. One artery going upward is a little enlarged and upon another directed to the macular region, is a minute hemorrhage. The real lesion of the case, as described by Jaeger, was probably in the nerve, and will be again referred to, but the retinal appearances are those of simple or serous retinitis. This infiltration passed entirely away as usually happens, and if there be no deeper lesion sight may be fully recovered.

RETINITIS ALBUMINURICA.—This condition occurs chiefly in the chronic forms of kidney disease, but also arises during the albuminuria of pregnancy and after scarlet fever, diphtheria, and rarely after measles. It may develop with any of the forms of kidney lesion, the fibrous, the fatty, the amyloid, etc. While hypertrophy of the heart often co-exists, it is not necessary to the retinal complication. The retinal affection appears when renal symptoms have already been fully declared, and it is also the first signal to attract attention in a notable number of instances. Uræmic symptoms, such as headache, morning nausea or vomiting and palpitations, with frequent micturition, especially at night, may have existed, and sometimes not even these signs have betokened the trouble. The severity of the local changes varies greatly, while in a very few cases there will be uræmic blindness or amblyopia without ophthalmoscopic appearances. The central portion of the retina is usually the part selected, and perhaps to the exclusion of the optic nerve, and, on the contrary, the nerve may be deeply infiltrated and swollen, with trifling implication of the retina. As a rule both nerve and retina are concerned. Diffused opacity, white patches large or small, and dots, hemorrhages, and with less frequency pigment-deposits and detachment of the retina, are what we find. It is highly exceptional to have but one eye involved (such cases are recorded; see *Ophth. Review*, Jan., 1885, p. 23; De Schweinitz, "Diseases of Eye," p. 431, 1892); frequently one is much worse than the other.

Digitized by Wilmer Library of Ophthalmology

It is declared that a faint and diffused opacity about the centre of the fundus and some redness of the nerve have been seen as the earliest evidence of the disease (retinitis simplex), but few have had opportunity to make this observation. Not infrequent is it, as said above, to be asked to explain loss of sight in a person supposed to be well, and find besides slight congestion of the nerve, that the fovea centralis has a darker hue than usual without distinct pigment granules, its border may be strongly accentuated, and make a rather conspicuous dark ring; near to it will be glistening white specks or streaks forming the rays of a star of unequal length, generally wanting on one side, and often broken up into dots (see Fig. 4, colored Plate). So brilliant are they and so noteworthy is their stellate arrangement, however incomplete, that on this appearance alone a diagnosis of kidney disease is often hazarded. Fatty degeneration of the fibrous tissue (radiating fibres of Müller) explains these cases. The tendency to stellate form may remain when the white deposits are very large and conspicuous; we may find hemorrhages and diffused opacity without plaques. Again the stress of the lesion may fall on the optic nerve, which will be swollen, red, permeated with newly-formed vessels and infiltration, the veins turgid, tortuous, and pulsating, and the arteries small, the border indistinct and encroaching on the retina, which also looks gray and swollen—the "Medusa head" nerve. (See Fig. 9, colored Plate.)

The more usual phenomena are a nerve somewhat or not at all swollen, red, or it may be of a dark and slaty hue, or even dead white, with small vessels; there will be white or greasy or grayish-white patches, covering sometimes a large area, perhaps so brilliant and extensive as to resemble a cloudy sky in sunlight. Sometimes they coalesce into a large and shining surface around the nerve, which can with difficulty be outlined in its midst, and the vessels will in places be obscured. There will be spots of hemorrhage, small or large, upon or away from the vessels, seldom numerous. Sometimes the white plaques develop so thickly about the nerve as to become continuous and then the vessels will by their irregular course and swelling show the hindrance to the circulation, while the border of the nerve may be indistinguishable.

There will naturally be great variety in the pictures presented.

Should the case continue long enough the stage of atrophy sets in. Hemorrhages and patches disappear, perhaps completely, although the stellate figure at the macula is the most persistent; the nerve grows pale, the vessels become small and bordered by white streaks; branching fibrous lines may appear in the retina, the hexagonal pigment may show irregular proliferation, especially about the macula and at the extreme periphery. It has even been

Digitized by the Internet Archive of Optometry

observed (Leber) that all characteristic lesions fade away and only the ordinary signs of optic-nerve atrophy with reduced retinal vessels remain (Fig. 2, colored Plate); yet very commonly some traces of exudation continue. The process requires months. Vision is sometimes not at all impaired, and it may be abolished. Every gradation is possible. With large hemorrhages there will be scotomata. The field is not limited, color sense not affected.

Diagnosis often is obvious, and yet in many cases very critical inspection is needed to see minute lesions. While in the large proportion of cases no hesitation need arise, we may not neglect a thorough examination of the urine chemically and microscopically. It may be that no traces of albumin may at the time be found, notwithstanding the presence of Bright's disease, and this will chiefly be in cases of the fibrous kidney, but it has also been found that disease of the brain has in a few instances been attended with all the ophthalmoscopic signs supposed to be peculiar to albuminuric retinitis, and that the kidneys were perfectly normal (Schmidt, Graefe's *Archiv*). Similar ophthalmoscopic appearances also occur in diabetes mellitus, in leucocythæmia, and with less degree of likeness in pernicious anæmia.

Cause and Development.—The cause and quality of the kidney lesion determine to a certain extent the behavior of the ocular disease. We have to separate the chronic types of renal disease from those connected with pregnancy and the exanthemata. Considerable study has been given to ascertaining at what stage in chronic Bright's disease the retinal complication occurs, and it is probable from statistics collected by Earles[1] that it exists more frequently than is generally supposed, because he found retinal changes in one-third the cases of Bright's disease, and of these ten out of thirty-one had no visual defect. Both he and other observers give the comparative frequency at from 20% to 33% of cases of albuminuria; and because defect of sight usually occasions ocular inspection, it seems probable that the renal disease or rather the general degeneration of capillaries and small vessels has advanced to a high degree at the time when the eye lesion appears. On the other hand, routine ophthalmoscopic examination of all cases of albuminuria, as was done by Earles, would probably show that the retinal complication is not postponed so late nor is it so infrequent as most writers have indicated. In pregnancy it has been seen at the third month and may be postponed until the seventh or eighth. It has been known to follow miscarriage. Detachment of retina in both eyes has been noted by Dickinson[2] in a scarlatinal case, and by Wadsworth[3] in a case of pregnancy. In-

[1] Birmingham Medical Review, Feb., 1880.

[2] "Diseases of Kidney," p. 230. [3] Trans. Am. Oph. Soc., 1887, p. 574.

Digitized by the Internet Archive

flammation of the retina alone, occurs in about three-fourths of the cases, of both retina and nerve in about one-fourth, and of the nerve alone (pure papillitis) in a very small percentage (Bull[1]). Hemorrhages appear in more than half the cases, and in certain exceptional instances they are the conspicuous and almost exclusive lesion. If at the macula, central scotoma and great damage to vision follow. "Hypertrophy of the left side of the heart without valvular lesion occurred in seventy-nine cases out of one hundred and three reported. There was hypertrophy of the left side of the heart with valvular disease in sixteen cases. In eight cases there was no cardiac disease at the time of the first examination, though hypertrophy of the left side subsequently developed in all but three cases" (Bull, l. c.)

Uræmic blindness may complicate the retinal lesion, or occur without it; it has been especially noted in scarlatina cases, and usually ends in recovery, but the blindness may be permanent. The nerve is generally much swollen. I once examined a case immediately after an attack which lasted only a few minutes; there was œdema of the nerve and retina, the arteries very thin, the veins tortuous. The patient had waxy disease of kidneys, liver, spleen, and intestines, and was extremely blanched.

Prognosis is better respecting vision than as respects life in the chronic cases. In pregnancy complete recovery is frequent, while atrophy in various degrees may occur. Even detachment of the retina has been known to disappear (Hirschberg, Wadsworth, l. c.). Hutchinson observed in one patient retinitis and recovery in a series of pregnancies, but finally she became blind by atrophy of the nerve. While improvement in vision is frequent, complete restoration is infrequent. The duration of life in chronic renal cases after eye symptoms arise, is given by Bull in 103 chronic cases, l. c.; viz., more than 50% died within the first year and the majority of these within six months; 17% died within the second year. Sudden death by apoplexy is not rare. On the other hand, a patient seventy-four years old whom I saw and who had had impaired sight for one year, survived ten years. Often the patient becomes indifferent to the eye trouble as the general malady increases. If, as happens, syphilis be the cause of the renal disease prognosis under correct treatment will be good.

After scarlet fever complete recovery is common. I have seen a case of papillitis in both eyes following a very mild type of scarlet fever in which perfect vision was retained, and each optic disc was the seat of nodular masses of colloid degeneration, piled to the height of 3 D and remaining substantially unaltered for seven years. (See Fig. 13, colored Plate.)

[1] Trans. Am. Oph. Soc., 1886, and Medical Record, July 31st, 1886.

Digitized by Illinois College of Optometry

Pathology.—By the kindness of Dr. John E. Weeks the following statement is presented. His views are also set forth in the *Archives of Ophthal.*, XVII., 3, 277, 1888:

"The diffuse white patches which occur in retinitis albuminurica are due to an escape of the plasma of the blood into the nerve-fibre layer, where it coagulates over larger or smaller areas. Blood-vessels passing through these patches are more or less hidden by the exudation. In addition to the exudation which gives the white appearance wherever it occurs, the tissues are œdematous from the presence of a serous fluid, very little opacity being apparent. The well-defined white patches which appear grouped in the region of the macula usually originate from the exudation of blood plasma

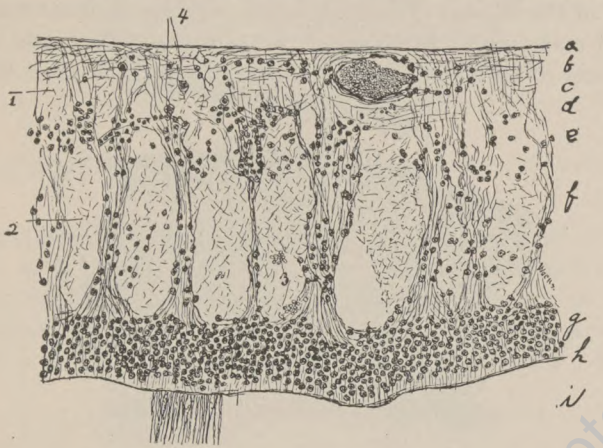

FIG. 230.—Changes in the Retina in Albuminuric Retinitis.—1, Fibrinous deposits in the nerve-fibre layer; 2, fibrinous deposits in spaces between Müller's fibres; 3, blood corpuscles; 4, ganglionic cells; *a*, membrana limitans interna; *b*, nerve-fibre layer; *c*, ganglion-cell layer; *d*, inner granular layer; *e*, inner nuclear layer; *f*, outer granular layer; *g*, outer nuclear layer; *h*, membrana limitans externa; *i*, rods and cones. Camera lucida, x300 diameters.

from the capillaries and venules that dip down into the deeper layers of the retina. This exudation occupies spaces in the middle layers of the retina, made by the separation or spreading apart of Müller's fibres, and breaks the continuity of the granular and nuclear layers. Müller's fibres are put on the stretch and the retina is much thickened where these deposits occur. These peculiar patches occur chiefly in the region of the macula and optic-nerve entrance. This fact is explainable on the ground of the richer network of capillaries that is present in these parts of the retina. The nature of the exudation in the deeper layers of the retina is the same as that in the superficial layer, but it occurs in larger masses in the deeper layers and from its position cannot be so readily absorbed. It is therefore subject to greater changes. After the deposit has existed for some months it is found to consist

of fibrin, coagulated masses resembling coagulated albumin, which subsequently degenerate into masses of a colloid nature, a few small globules of fat here and there in old deposits, and an occasional bunch of fat crystals. The latter are rare. Blood corpuscles are not infrequently met with in these masses of exudation. It is evident that exudation into the retina in retinitis accompanying albuminuria takes place under two conditions. First, from impairment of the walls of the vessels due to mal-nutrition (without thickening or the presence of any cause of obstruction to the blood current), which causes leakage of their fluid contents. This condition obtains in retinitis accompanying acute nephritis, pernicious anæmia and scorbutus, and is dependent on a depraved condition of the blood. The vessels having the thinnest walls, capillaries and veins suffer first, and it is from these that the escape of the elements of the blood first occurs. Very little true inflamma-

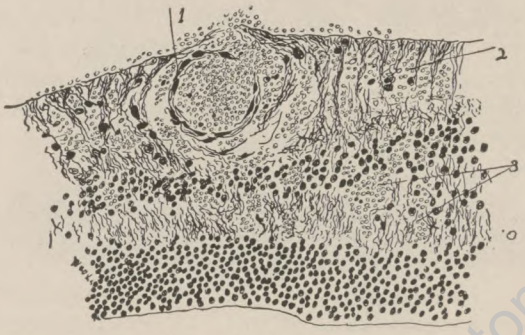

FIG. 231.—Albuminuric Retinitis. Rupture of Wall of Vein.—1, Wall of vein; 2 and 3, blood corpuscles in the superficial and deeper layers of the retina. Camera lucida, x250 diameters.

tion accompanied by increase of nuclei and the aggregation of leucocytes takes place ; however, in rare cases this does occur, and great impairment of vision due to connective-tissue changes in the optic nerve may result. Purulent conditions do not develop. Exudation may take place from the ciliary processes and iris.

"The second condition that causes exudation into the retina is obstruction to the blood current. This occurs in retinitis accompanying chronic interstitial nephritis and is due to an endoarteritis. The changes in the retinal arteries are indicative of a general arterial disease which may be most advanced in the retina, and not become manifest in the kidneys until a later date. The changes in the walls of the vessels are found in all the tissues of the globe, the walls of the arteries being most affected. A fibrohyaline degeneration of the tissue elements immediately beneath the endothelium develops, involving the elastic lamina and in some arteries the muscularis also, particularly the inner layers. This

Digitized by the Internet Archive of Optometry

degeneration leads to thickening of the walls at the expense of the lumen. It may occur irregularly or may affect a vessel throughout its entire course. The lumen may be partly or entirely obliterated; when entirely obliterated the endothelial cells are crowded together, forming the axis of the cylinder. Karl Theodor[1] speaks

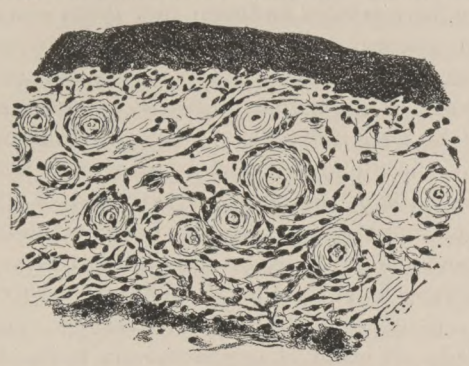

FIG. 232.—Section of Iris in a case of Albuminuric Retinitis. Marked Fibro-Hyaline Changes in the Walls of the Vessels. Camera lucida, × 250 diameters.

of having observed fatty degeneration of the endothelial cells. If it occurs it is not common. The capillaries, particularly in the chorio-capillaris of the choroid, are often completely occluded by fibro-hyaline degeneration of their walls. The veins are affected, but to a less degree than the arteries or capillaries. The nerve

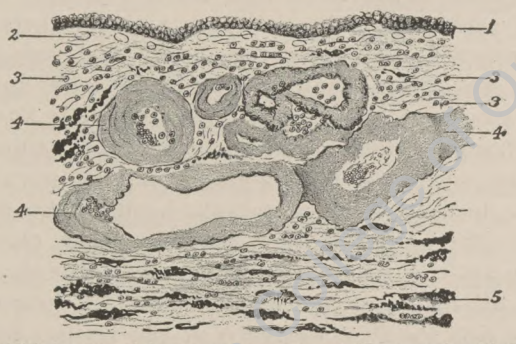

FIG 233.—Choroiditis in unusual degree, cross section.—1. Hexagonal epithelium almost intact; 2, minute capillaries; 3, cell infiltration most abundant about diseased vessels; 4, large vessels which have undergone colloid degeneration; 5, lamina fusca with moderate pigment proliferation.

fibres apparently become slightly thickened and in old cases undergo granular degenerative changes, disappearing entirely. It is extremely doubtful whether the fusiform enlargements of the nerve fibres pictured and described in nearly all the text-books on ophthalmology ever occur. In medullated nerve fibres this change

[1] "Ein Beitrag zur Pathologischen Anatomie des Auges," Dr. Herzog Karl in Bayern, 1887.

does take place, but the axis cylinders alone do not seem capable of assuming such form. The ganglion cells become much enlarged by imbibition, pass into granular degeneration, and disappear. Müller's fibres swell from imbibition and pass into a hyaline degeneration. Fatty changes may occur but are not usual. The granular and nuclear layers undergo but little change except in old cases, when general atrophy of the retinal tissue results. Granular degeneration of the bacillary layers occurs in advanced cases. Hyperplasia of the retinal pigment is sometimes observed. In certain cases the nutrition of that portion of the optic nerve immediately back of the globe is seriously interfered with by the degeneration of the walls of the vessels. Atrophy of the nerve fibres follows, the connective-tissue trabeculæ become thickened, and the function of the nerve is partially or completely destroyed."

Michel and Herzog Karl Theodor (l. c.) have shown that in certain types sclerosis and degeneration of the vessels, especially of the finer ones, precede all other changes and are found in the earliest phases of the disease. The granule layers suffer severely, because they lie between the retinal and choroidal systems, and with degeneration of both of them their nutrition is greatly damaged. The degeneration of the optic fibres is similarly explained, being in proportion to the vascular lesions. The vitiated state of the blood due to the damaged kidneys necessarily has a large share in the deteriorating processes, and because of the altered state of the vessels effete products are more difficult of removal. The lesions of the papilla seldom pass beyond the lamina cribrosa, but have been occasionally found as far as the chiasm, and even atrophy has been noticed. The distinction made by Dr. Weeks[1] into the general classes of cases is also set forth in his article (l. c.) and has practical value in both prognosis and treatment. Many times the prognosis in the cases with vascular degeneration is comparatively good. Sometimes we have a blood dyscrasia brought about by acute renal trouble: the kidney disease preceding the changes in the retina. These are the cases of pregnancy, scarlet fever, diphtheria, measles, and all forms of acute nephritis. In them œdema and white plaques are the first evidence in the retina; hemorrhages more or less numerous often follow. Another class depends upon general (systemic) diseased condition of the arteries, capillaries, and to a less extent of the veins. The eye symptoms may precede the kidney symptoms. A slight hemorrhage near the macula and a few bright dots will be the first tokens in the eye, while œdema and white patches develop later. The larger proportion of cases belong in this class.

---

[1] Archives of Ophthal., xvii., 3, 277, 1888.

Digitized by Illinois College of Optometry

Treatment.—The principal indication in the chronic cases is to protect the eyes from strain and irritation. Local blood-letting is inappropriate, and nothing is to be done which will reduce the health. Confinement in dark rooms is not to be thought of; colored glasses may be used if the light be offensive. The whole treatment is contained in what is most suitable for the renal affection. All the rules of hygiene, climate, clothing, food, and exercise, as well as the proper medication, iron, diuretics, sometimes mild mercurials, etc., are to be adopted which would be enforced if the eyes were not at fault. For the cases of vascular degeneration Meigs recommends carbonate of ammonia and digitalis.

Loss of sight during pregnancy, whether from purely uræmic symptoms or from visible retinitis, raises the question of the production of premature delivery. Loring[1] published a case in 1882, in which, at his suggestion, premature labor was resorted to, to save sight in a woman who at three successive pregnancies was the subject of atrophy of the optic nerves or rather of low neuritis optica. This was successfully done during the third month and achieved the desired purpose. No albumin was found in the urine, yet the lesion was attributed to the kidneys. Howe,[2] Pooley,[3] Moore[4] have recorded cases wherein the retinal disease was clearly pronounced and by removal of the fœtus sight was restored. Obstetric authorities agree that albuminuria raises this question because of the danger to life of both mother and fœtus. The grave significance of loss of sight as denoting advanced degeneration of the kidneys, lends added importance to the situation and must be considered as arguing in favor of interference. The uræmic state of the blood is dangerous to the life of the fœtus when it has already caused lesions in the optic nerve and retina of the mother, and with the prospect of convulsions and peril to the mother's life, resort to artificial labor may be abundantly justified. This point in the management of labor must in the future be regarded with more attention than it has received, and because there may be lesions of the nerve or retina without impaired sight, inspection with the ophthalmoscope is strongly recommended, for the same prudential reasons which call for examination of the urine even though there are no urgent symptoms. Vision may also be impaired with little or no visible lesion. The following conclusion by Howe seems judicious: "The induction of labor is

[1] Trans. Am. Oph. Soc., p. 423, 1882, also N. Y. Med. Journal, Jan. 20th, 1883.

[2] Am. Journal of Ophthalm., vol. ii., 5, 6, 1885.

[3] Medical Record, Jan. 28th, 1888.

[4] N. Y. Medical Journal, April 17th, 1886, also Thompson, Medical Record, March 3d, 1888.

Digitized by Illinois College of Optometry

warrantable when the retinitis appears in the early stage of pregnancy and persists in spite of proper treatment, but is not warrantable in the last few weeks, in spite of the greater ease with which it is accomplished, unless the inflammation is unusually severe."

Retinitis glycosurica is much less frequent than retinitis albuminurica. The features of both are to a great degree identical. There can be no doubt as to the competency of diabetes alone to cause retinitis, while it happens that in some cases sugar and albumin may coexist in the urine. It would seem that hemorrhages are more frequent and abundant than in albuminuric retinitis. They break into the vitreous, and therefore opacities in this structure are common. A case which I described in 1869, was one of diabetes without Bright's disease, and occurred in a lady sixty years of age. When first seen, in 1867, the retinal lesions were slight, but they soon increased, and hemorrhage was abundant. Improvement occurred to a marked degree, but a little more than two years afterward the lesions returned, and sight was worse than before; the general health had also materially fallen off. This patient had iritis before the retinal trouble. Galezowski reports a case in which iritis serosa and afterward acute glaucoma followed the retinitis; iridectomy proved of no value and enucleation was done. The essential lesion seemed to be copious hemorrhage and its transformations. The bright yellow patches are less liable to affect the macula; perhaps they lie more frequently between the disc and the macula. Their form is more nodular and irregular than is usual in the albuminuric type. Weeks reports hemorrhages and acute glaucoma in one of his cases of albuminuric retinitis, l. c. For the literature see Leber, in Graefe and Saemisch, Vol. V., p. 596. Hemorrhagic retinitis is said to have been found in diabetes insipidus (Loring). Amblyopia without visible lesion also occurs in glycosuria, and is characterized by central scotoma for red, like alcohol amblyopia. To this reference will again be made. Nothing need be said as to treatment, because it is included in that of the general disorder.

Retinitis leucocythæmica, also called splenic or leukæmic retinitis, is extremely rare, and its appearances are given in Liebreich's Atlas, Tab. X., Fig. 3. A peculiar orange hue pervades the fundus and there will be both exudations and hemorrhages. In persons of dark complexion the yellowish tinge may not appear, but the swollen veins will not be dark as with normal blood (Hirschberg[1]). The ocular conditions are described at some length by Gowers.[2] It may be characterized by hemorrhages, and Poncet

[1] Centralblatt für Augenheil., April, 1887, p. 97.

[2] "Medical Ophthalmoscopy," p. 190, 1879.

Digitized by Illinois College of Optometry

gives a figure which shows how in this, as in other retinal hemorrhages, degeneration of the vessels has prepared the way for the accident. Loring[1] lays stress upon the great tortuosity of the veins and their increase in diameter, while the arteries are less enlarged or even reduced. De Schweinitz[2] signalizes white spots with red borders, especially near the equator and the macula. They vary in size and are sometimes elevated. They consist of leucocytes, surrounded by red blood-corpuscles. Sometimes albumin is found in the urine. Examination of the blood will reveal the nature of the malady. Changes may occur in the choroid and its tisssue be infiltrated with leucocytes.

Retinitis Syphilitica.—While a very large proportion of cases of retinitis are caused by syphilis, it is not possible to establish the cause by the local appearances, any more certainly than with iritis. Certain types of inflammation are more common, viz., of the anterior layers, yet the deep layers are also the starting point of the disease, because it so frequently is associated with choroiditis. It occurs as a primary affection, and it also accompanies iritis and cyclitis, and then haziness of the vitreous may obscure its presence. It comes with the secondary lesions, more rarely with the tertiary, and it is also hereditary. As neuro-retinitis it occurs with syphilitic brain disease. The signs which we most often find are congestion of the optic nerve, without swelling, its edge blurred, the veins enlarged, the arteries normal, or even reduced; the retina at the nerve-border is faintly striated, sometimes is gray or dark, and about the centre of the fundus it has a faint haze, most easily discovered by weak illumination; along the larger vessels, the whitish exudation is more intense; bright white or yellow spots are not very uncommon (these are shown in several plates by Ole B. Bull: "The Ophthalmoscope and Lues," Christiania, 1884), and a considerable patch of yellow exudation can occur, but is more rare. If the vitreous be hazy, the veins will, by their distortion, best indicate the fact of retinitis; but the diagnosis of retinitis then requires great caution. One must see exudation to make it certain. Hemorrhages are infrequent. Fig. 17, colored Plate, might be an instance of syphilitic neuro-retinitis with slight opacity. There is a marked predilection for the central portion of the fundus, where little more than a delicate cloud will be seen, and there may be minute yellow points in an irregular group, perhaps erosion of epithelium and central scotoma (Graefe). Relapses are frequent and characteristic.

Still another type has been called *retinitis proliferans* (Manz: Graefe's *Archiv*, XXII., III., p. 229, 1876), in which membranes

[1] "Text-book of Ophthalmoscopy," vol. ii., p. 154, 1891.

[2] "Diseases of the Eye," p. 434.

Digitized by the Internet Archive of Ophthalmology

and bands of connective tissue spring out from the retina into the vitreous and are often traversed by newly formed vessels. They may originate from the nerve, and be so thick as to obscure the fundus, or present large openings through which one may look (see Fig. 16, colored plate). Hemorrhages may occur in the retina, the nerve will be red and spots of exudation will be seen, white lines course along the vessels, and vitreous opacities frequently follow them. In time pigment proliferation and choroidal erosions appear, and both these lesions may be very extensive. The condition is at length identical with choroiditis disseminata. The disease will be very chronic.

Again, we may find the retina covered with bluish-gray streaks and patches of connective tissue, which lie below the vessels and may be most abundant toward the equator. They have a fluffy or sometimes fibrous look, and intermingled with them are choroidal erosions. In all these conditions the nerve participates and from a state of congestion often passes into the pallor of atrophy.

The retina may become implicated in cases of iritis, as has already been stated, although haziness of the media makes its detection difficult or impossible. In the case of a boy seventeen years old ten days after the onset of gummy iritis, neuritis with plastic exudation, pallor and reduced vessels, made its appearance and was followed in a month by œdema of the disc and diffused faint infiltration of much of the retina. Meanwhile the iritis subsided and the media became clear. The other eye took on iritis, and through the moderately hazy media the optic disc was seen œdematous and slightly swollen, the veins turgid and capillaries congested. It may also happen that only the macular region is affected and the lesions be very faint, consisting only of a finely speckled or granular appearance. It also happens in pronounced cases that the vitreous becomes filled with large flocculi, and the choroid as well as the retina shows extensive lesions.

Visual disturbance may be very serious or moderate. It will often be in no proportion to the visible alterations. With little tissue-change the vision may be very bad, and *vice versa*. Metamorphopsia takes place from exudation into the macula, by which the cones are thrown into disorderly arrangement—either spread out, or packed together more closely. In some cases objects appear too small, because fewer cones receive the image (micropsia), and the contrary may happen, at least theoretically, if too many cones be clustered into a given area (megalopsia). This last condition is seldom, if ever observed, because if the cones become condensed they usually undergo atrophy. No kind of glasses, either spherical or cylindric, can relieve the condition. The patient complains that words or letters do not stand in regular line but

Digitized by Google

are thrown above or below adjacent ones. Lines drawn parallel will show a curve at some point either in or out. Other disturbances are scotomata, which may be central or eccentric, and sometimes are ring-shaped, with central vision unimpaired, and the ring of dull or absent vision may be complete or incomplete. Förster has noted a distinction in these cases of positive and negative scotomata. The former appears to the patient as a dark spot in the visual field, and is most emphatic in feeble illumination. Consequently, a patient so affected seeks a strong light, and then reads fairly well. The lesion may be due to retinitis circumscripta (at the macula), to choroidal hemorrhage, or other choroidal disease. A negative scotoma is not recognized by the patient under any degree of illumination, whether strong or feeble; it is a color-scotoma, and chiefly for red. The negative scotoma occurs in disease of the optic nerve, and in the amblyopia from tobacco and alcohol. Color-perception in syphilitic retinitis is good, except in the event of atrophy. Scintillations and phosphenes are frequently complained of—one eye alone, or both eyes, or each in succession, may be affected.

Treatment is constitutional, and consists of mercurials and iodide of potassium. Regard must be had to the patient's general condition, and to the stage of the disease. If tertiary, the proportion of iodide will be larger; but mercurials, to the degree of toleration without ptyalism, are essential. As we must often anticipate a long period of treatment, care must be taken to keep up the general health, and frequently the form of the remedy is to be changed. The activity of the process will suggest the kind of mercurial. Iron and tonics are often to be invoked. Should the disease be hereditary, the same remedies are to be used, while cod-liver oil and means of promoting nutrition are to be especially regarded. In many cases serious complications occur in other tissues of the eye, or there may be tokens of the disease in the brain.

Prognosis depends on the extent to which the system has been tainted, and its responsiveness to treatment. Affection of the deep layers of the retina is more unfavorable than of the anterior layers; therefore, cases attended by pigment-changes, or by choroidal exudation and atrophy, are unfavorable. Atrophy of the optic nerve, and of the retina, sometimes ensues. See Fig. 2, colored Plate, in which the white lines along the vessels and the dirty blue color of the nerve are the typical features. Of the uncomplicated cases, very many recover, with no injury to sight. While the duration of many cases is from six to eight weeks, others are more obstinate and may continue for years. When the macula alone is concerned, there is great reason for anxiety, because serious impairment of sight is prone to remain, and we find choroidal changes, or permanent exudative deposits, or development of nerve-atrophy.

Digitized by the Internet Archive

There is said to be a form of retinitis dependent on *oxaluria*, and Michel says it occurs also in *phosphorus*-poisoning. In both cases we have fibrous degeneration of the small vessels, and the consecutive changes already referred to. In view of the frequent occurrence of similar pathological lesions from diverse etiological causes, it is proper to utter the caution that the ophthalmoscopic picture cannot ever alone be safely relied on to inform us of the constitutional nature of the disease. This conviction becomes more and more strong as one's experience widens.

Retinitis punctata albescens (Mooren) is an excessively rare condition and indicates a peculiar degeneration, in which minute, isolated, white specks appear in the retina, behind the vascular layers, and scattered over the fundus. There is very slight change in the nerve, perhaps a little gray discoloration. Vision is moderately impaired and we have little knowledge of either the pathology or treatment. I have seen two or three instances.

Pigment Degeneration or Sclerosis of the Retina.

Retinitis pigmentosa.—The affection thus designated is a chronic disease usually congenital, consisting of proliferation of connective tissue in all the layers of the retina, atrophy of the nervous elements, intrusion of pigment into its tissue, with a tendency to follow the blood-vessels. The same features belong to choroido-retinal affections already considered, but with the difference that, unlike them, the alterations are not confined to the outer and middle retinal layers, but concern them all. Such is the anatomical distinction which Leber points out. The chief feature in the disease is the pigmentary deposit, which comes from the hexagonal epithelium, and so far from showing any of the usual signs of inflammation in enlarged vessels, exudation, and hazy vitreous, we have simply the tokens of atrophy. The walls of the blood-vessels are thickened, and their calibre reduced; the pigment-epithelium is in some places atrophied, and in other regions its cells are multiplied and penetrate the whole thickness of the retina. These lesions appear without the occurrence of any other disease, and without any outward sign. On the other hand, they also arise in a secondary way after other maladies, such as corneal staphyloma, irido-choroiditis with closed pupil, exudative choroiditis, etc.

In regard to the *pathology* of this disease, much has been written, and the process is interesting, but we must pass by most of the details. The periphery of the retina is the usual seat and beginning of the disease, and it advances centripetally toward the macula lutea. The rods and cones are destroyed at an early stage, and sometimes the retina is in spots converted wholly into connec-

Digitized by the Boston Medical Library

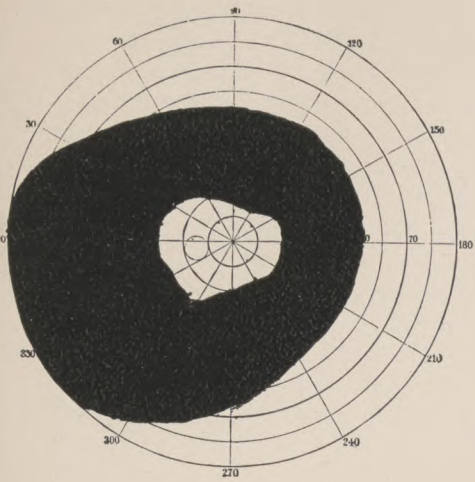

Right Eye.

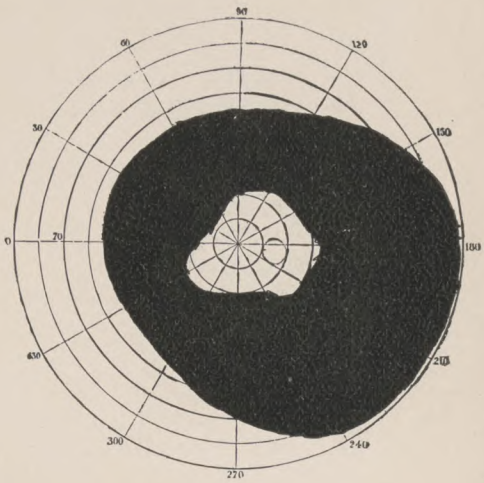

Left Eye.

Retinitis pigmentosa. Extreme reduction of fields concentrically. J.D., æt.26. An uncle has similar affection. Failure of sight noted twelve years ago. O.D.V.=$\frac{20}{100}$; O.S.V.=$\frac{20}{70}$. Fundus like that of albino in absence of hexagonal pigment and distinctness of chorio-capillaris. Retinal vessels at periphery bordered by pigment. Middle of fundus dotted with pigment as if sprinkled from a pepper box. Optic nerve dull, opaque, have a greasy look; vessels small.

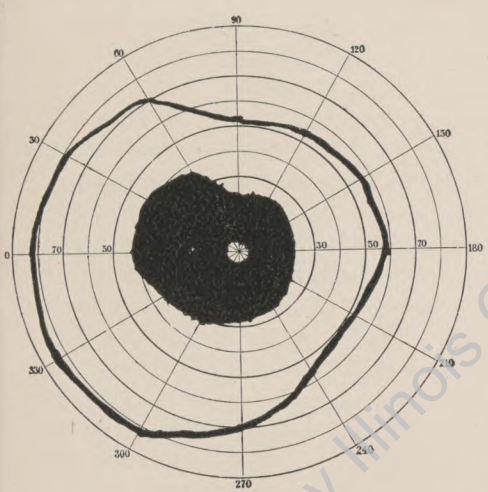

Left Eye.

Right Eye.

Retinitis pigmentosa with slight peripheral limitation of fields and broad ring scotoma which encroaches closely upon the region of the macula. Dr. B. E. H., æt. 46.

O.S. + 4.50 V = $\frac{20}{40}$? O.D. + 4 D. V = $\frac{20}{40}$?

Digitized by Illinois College of Optometry

Digitized by Illinois College of Optometry

tive tissue. Where the pigment is thickest, the retina and choroid adhere together. The vitreous layer of the choroid is studded with masses of colloid deposit, and the optic nerve is atrophic, even up to and beyond the chiasm. Sclerosis of the choroidal vessels occurs to some degree. Atrophy of the nerve accompanies the later stages and may be complete.

The subjective symptoms are peculiar: there is a loss of peripheral sight, which gradually advances toward the centre, and for a long time the central vision may, in good light, remain correct. But the peripheral blindness impairs the patient's freedom of movement, because it compels him to constantly turn his head to acquaint himself with surrounding objects. In addition, these patients when in dull light experience a grievous reduction of central vision. At night they become almost helpless, and their malady has hence been called hemeralopia. When walking at night, they keep their eyes on the sky to help guide their steps, and grope in much uncertainty. After a time central vision, even with good light, becomes affected, and in the end total blindness ensues. The symptoms in most cases begin in early life, while in a few no trouble was noted until fifteen or twenty years of age. The consummation of the disease usually comes after twenty to thirty years of age. It is found in families, and inter-marriage of kindred has been considered greatly instrumental in its production. Leber finds about twenty-five per cent of the cases within this category. It is sometimes congenital; see chapter on blindness. Some cases after attaining a certain stage remain stationary at any rate for years.

Special peculiarities sometimes appear in the symptoms. I have notes of three cases in which the central vision was good, while exterior to the visual axis was a zone of blindness, outside was another zone of good vision, and at the periphery again was blindness (ring-scotoma). Such cases prove that for a certain zone in the periphery the rods and cones remain intact, while across the interior blind zone, where the bacilli are destroyed, the optic fibres continue uninjured. Again, Leber, who has studied this subject with care, puts under the same general head certain cases of congenital night-blindness, or amblyopia, without concentric field-limitation, and which exhibit no pigmentary changes. They may remain *in statu quo* for a lifetime, and certain remarkable examples of heredity are given, extending as far as through six generations (see G. and S., Bd. v., p. 650). In the congenital cases nystagmus is frequent. The pupils act slowly, but respond to light.

To the ophthalmoscope the appearance is striking. Dots and network of pigment are scattered over the periphery of the fundus (see Fig. 234). Often the choroidal vessels are strongly brought to view by atrophy of the retinal epithelium. They may also show

yellowish or buff outlines, which indicate their sclerosis. The retinal vessels, both arteries and veins, are small; their walls thickened, possibly bordered with a whitish line, and upon them pigment will lie in greater or less quantity. The optic nerve I have, in certain instances, seen to be red, although not swollen; in most cases it will be gray, and ultimately a dirty white. In all cases it is opaque, by interpolation of connective tissue. In the last stage the nerve loses its capillary vessels, and the emergent arteries are reduced to threads. Opacity at the posterior pole of the lens is frequent; it finally may become complete cataract. The rate of progress is extremely slow. Vitreous opacities are not common, but I have



FIG. 234.

noted them and seen the vitreous so fluid that accompanying cataract was easily extracted in its capsule. I have also seen iridochoroiditis ensue. Some cases which strongly resemble retinitis pigmentosa are syphilitic, either acquired or hereditary.

In them the disease may be confined to one eye, but in the typical cases both eyes are involved. A certain proportion of deaf-mutes have this lesion, and among idiots, as Liebreich showed, it is not rare.

Diagnosis.—Very little difficulty can arise in ordinary cases. Choroiditis disseminata is either in isolated spots, or most extensive, and presents exudations and atrophy, with white blotches and pigment-deposit in greater quantities. Sometimes choroidal lesions will strongly simulate the retinal lesions, but neither is the difficulty frequent, nor would an error be important. Neuro-retinitis of acute type and syphilitic, is sometimes although rarely attended

Digitized by Illinois College of Optometry

Digitized by Illinois College of Optometry

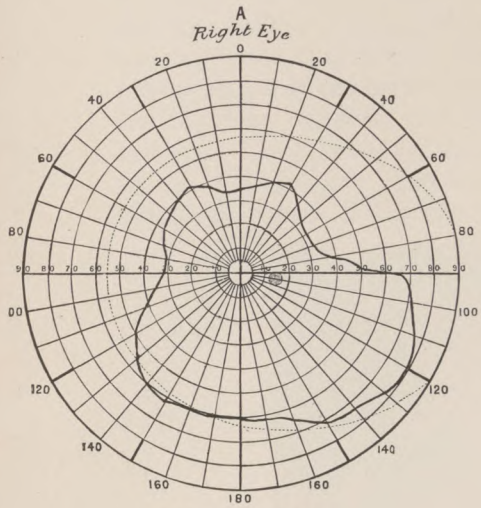

Oct. 18th, 1887.

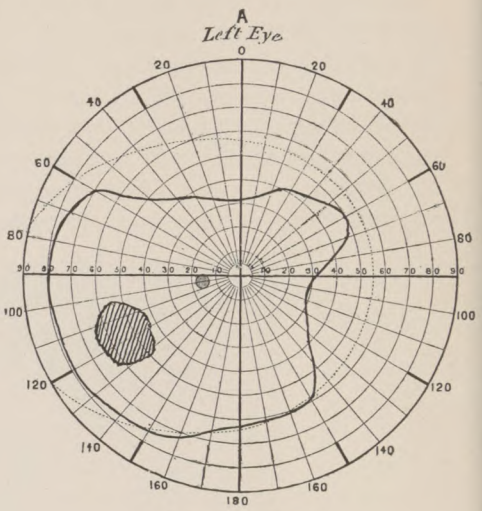

Oct. 18th, 1887.

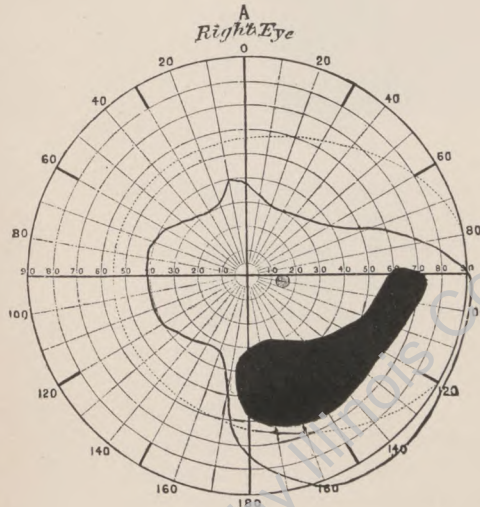

Nov. 4th, 1889.

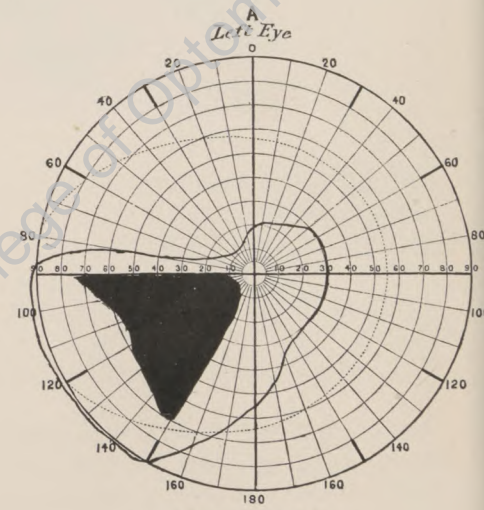

Nov. 4th, 1889.

Neuro-retinitis pigmentosa. Miss A. T. B., p. 629.

Digitized by Illinois College of Optometry

by pigment-deposit at the periphery, in this respect simulating the disease in question, but the activity of the process sufficiently differentiates it.

Donders has shown that the essence of the disease is not the pigment-deposit, but the atrophy of the retina. The insensitive region of the retina he found to be in advance of the pigment-district, by throwing upon it, with the mirror, a very small flame, which was not perceived, although not resting upon the pigmentary region.

Hemeralopia, without pigmentation, is less prone to increased loss of sight, and more frequently comes to a stand.

Prognosis is unfavorable, although the rate of advance is slow.

Treatment is of little value. Alteratives, derivatives, strychnia, etc., have no permanent yet sometimes an apparent temporary effect. Attention should be given to proper care of what sight remains, and its economical employment.

Some have thought (H. Derby [1]) that galvanism mildly applied has influence in retarding progress; others who have tested it have found no benefit and in some cases apparent harm. There are sometimes long pauses in the progress of the disease and sometimes, when the field has been excessively contracted, central vision may remain fairly good and so continue for years.

Neuro-retinitis Pigmentosa.—At this point may be introduced a form of disease which bears in many respects the closest analogy to the pigment degeneration of the retina above referred to. Under that description the occasional occurrence of inflammatory lesions in a mild form was referred to, but that affection is an atrophy, while the type now considered is chiefly and notably inflammatory. The analogies between the types are the peculiar and prolific deposition of linear and irregular formations of pigment, resembling bird tracks, or oriental letters, bone corpuscles, etc., and especially disposed to run along the vessels. There is in the present type peripheral limitation of vision. The differences are that the former is chronic, requiring many years, is not amenable to treatment, and the latter is comparatively acute, has opacity of vitreous, infiltration and hyperæmia of the nerve, and does yield to treatment. In the latter a scotoma may develop, and be the conspicuous feature. This is very unlike the ring scotoma sometimes found in retinal pigment degeneration.

The features of the disease can be best portrayed by giving the following case, now under treatment:

Miss A. T. B., æt. 13, came to me in October, 1887. She is the second of

[1] Trans. Am. Oph. Soc., 1887, p. 217.

Digitized by Illinois College of Optometry

six living children. Her mother's first pregnancy resulted in miscarriage at 6½ months. The patient was born three weeks before full time and weighed nine pounds. She has always been "nervous," never had any serious illness. About three years ago it was noticed that she did not see well in going from a light to a dark room. She would stumble over the baby, did not notice a man who was laying a carpet. The trouble has increased very much within six months and she cannot use her eyes. O.D., V = 0.5; O.S., V = 0.5; glasses do not improve. There is no hereditary lesion except that cataract has existed in the father's family. By ophthalmoscope : O.S., nerve seen with + 3 D., and so is the macula and the region between them. The macula appears as a small red spot closely resembling a small bleb, and the retinal tissue between it and the nerve is stippled, has a whitish reflex and is elevated above surrounding fundus as if by effusion. Surrounding parts of fundus best seen with + 1 D. At the periphery are on all sides numerous pigment deposits in the retinæ. In O.D. are similar appearances save that the region of infiltration in macula, nerve, and included space is less elevated, being seen with + 2 D. Visual fields shown in chart. Ordered "mixed treatment."

Within two weeks vision improved to 0.7 O.U. Four months later a whitish reflex noticed around the region of the macula in each eye. Some fine vessels concealed; nerve diffusely swollen and surrounding retina striated; opacities in anterior part of vitreous. Three months later the exudation about the macula had disappeared. Infiltration and redness of nerves the same. Besides mixed treatment has been taking iron: "Blaud's pills."

In November, 1889, V. O. U. = 0.7. Vitreous in each eye less hazy; swelling of nerves abated; redness less intense; surrounding radiation more defined but less abundant, now resembles opaque nerve fibres. Pigment deposits have approached nearer the central part of fundus.

Visual fields show a scotoma as indicated in charts, and the several charts show the changes which have occurred. The case is still in progress.

Detachment of the Retina. Sublatio Retinæ: Amotio Retinæ.

Displacement of the retina by fluid effusion between it and the choroid, when very pronounced and the retina opaque, can be seen by the naked eye, but ordinarily is to be recognized only by the ophthalmoscope. It presents various appearances, according to the nature and quantity of the fluid. It may be partial or total, and may occur at any part of the fundus. Its more frequent seat is near the equator. It often develops within a few hours, but may require a period of one or two weeks. The subject is sometimes unconscious when it occurs, and usually there is no pain. In some cases there are premonitory flashes of light or of color. The visual field is mutilated, although a degree of light-perception is often present over the damaged part. When the central part of the retina is not visibly disturbed, it may have good sight, but frequently this is not the case. Objects may appear crooked (metamorphopsia) when the macular region is only slightly disturbed. It is very common, both before and after the occurrence, to hear complaint of muscæ, and examination reveals floating vitreous

Digitized by Illinois College of Optometry

opacities, sometimes very numerous. It is almost the rule to have diminished tension. Examination by the inverted image gives an idea of the extent and relations of the fluid, while the upright image tells the depth of the effusion and the details. What arrests attention is, that the retina bulges over a greater or less extent toward the middle of the eye. If the membrane itself is not clearly noticed, its disturbance is seen by the position of the retinal vessels. They suddenly bend toward the centre of the eye, become tortuous, tremulous, and dark in color, with no light-streak. They may take an abrupt change of course, follow long curves, or wriggle in short bends (see Fig. 5, Plate III.). They will generally undulate. The retina may be clearly visible, because of a drab, gray, speckled, or glistening appearance; on the other hand, it may be transparent and difficult to recognize. If the amount of fluid is great, little trouble will be had in diagnosis, but if small and transparent it may take close inspection to discover the disease. Nothing but a rippled surface may be seen, and this will sometimes be the condition upon a region where effusion has taken place and afterward disappeared. If the illumination is thrown upon the edge of the detached retina, the choroidal vessels will come out with great distinctness, in case the layer of fluid is thin and transparent. The light is refracted through it so as to make them appear to start forward. In some cases the sac may look like mahogany, and then the effusion is bloody. I have seen zones of different color, in different parts, passing from mahogany to yellow and then to transparency. It is very common to find whitish spots on the retina, or bright streaks, and sometimes cholesterin. It does not generally happen that the region of the yellow spot is involved, but when this does occur, and the amount of fluid is moderate, the fovea appears bright red, and contrasts vividly with the adjacent retina. This hue is in consequence of the thinness of the membrane at this point, which permits the choroid to shine through it. This is essentially the same explanation of a similar contrast in embolism. In a traumatic case—a cork popping from a bottle (Trans. Am. Oph. Soc., 1871, p. 128)—I was convinced that the fovea had remained upon the choroid and been torn from the surrounding retina. Precisely the same look I have once since met with, although I have seen clear instances of a detached fovea, and I therefore regard a central laceration as possible. It is very common to find a rent in the retina at its peripheral part (see Fig. 6, Plate III.); there may be as many as three, near together and parallel. Sometimes a loose tongue is torn up, and through the opening the choroidal vessels are visible. Liebreich's Atlas pictures such a condition most truthfully.

The fluid beneath the retina is albuminous; even when it is not

Digitized by the Internet Archive of Canada

bloody it contains blood- and lymph-corpuscles, fat-cells and crystals, pigment, and epithelium, etc. In a large number of cases the vitreous is liquefied, as is proved by the tremulousness of the sac. After a considerable time, the rods and cones become macerated and destroyed, or by interstitial inflammation fibrous tissue may be developed, and atrophy of nerve-elements ensue. Sometimes the separated retina remains practically normal. This happened in a case of choroidal sarcoma (Poncet), see Fig. 201.

The above description belongs to the cases which may be called simple or idiopathic in character. But we find separation of the retina as an outcome of a large number of morbid conditions of various origin, in which cyclitis or choroiditis bears a part. Almost every case of chronic irido-cyclo-choroiditis has detached retina. It is a pathological condition very common in museum preparations. It appears often as a total detachment, and in its last result presents simply a cord running from the optic nerve to the ora serrata, within which no recognizable traces of the vitreous remains (see Figs. 161, 162, p. 431). In condemned eyes with closed pupil the total want of perception of light often warrants the diagnosis of the above condition. As a part of the suppurative process in purulent choroiditis or retinitis, separation of the retina occurs. I have seen in such a case flecks of blood scattered thickly over the whole retina, with yellow serum between choroid and retina. Cystic degeneration of the retina is described by Iwanoff and Leber, both in the late and earlier stages of the retinal disease; it is only seen by the microscope.

In very many cases the lens in time becomes opaque and presents the characteristics of soft cataract.

Etiology.—Statistics collected in Horner's clinic[1] of 300 cases, show that about one-half the cases (48%) occur in myopic eyes, while 16% were due to injury. One-half the cases were in persons above fifty years of age. In twenty-seven cases both eyes were affected and the interval between the successive attacks varied from three weeks to nineteen years. Besides myopia, which in the great majority was of high degree, inflammatory processes of the iris, ciliary body, and choroid and retina accounted for many of the remainder. The immediate and active cause could often be set down to some congestion due to overwork, strain, cough, hard drinking, emphysema, etc. There is often more or less night-blindness, and there may be much complaint of the dimness of light impression for the preserved portion of the field. Leber speaks of a tendency to confuse blue and green (Berry, p. 289).

Many theories have been advanced to explain the *pathogenesis*

[1] "Klinische Studien über Netzhautablösungen," Walter, Zurich, 1884.

Digitized by Illinois College of Optometry

of the affection, and that which seems to be most satisfactory is given by Nordenson.[1] The condition precedent is the change of the vitreous from a fine to a coarse fibrillar structure and its consequent shrinking. As this goes on fluid is effused between it and the retina, and the progress is usually from behind forward. If the vitreous acquires adhesion to the retina, which it may do over a large or small area, it will as it shrinks pull it from the choroid, and in so doing it often happens that the retina is torn. As the membranes are most intimately coherent in front of the equator, this will usually be the place of rupture. When this opening is made, the fluid vitreous rushes through and lifts up the retina, and the effusion is simply a change of place and not an addition of fluid. As a fact Nordenson found among 119 cases, a laceration of the retina in 49 (38.6%); certainly it might exist in many others and because very peripheral, not be open to discovery. This theory accounts for many sudden cases, while in cases which progress slowly and respecting whose duration or beginning no accurate history can be elicited, it is fair to assume that the vitreous had adhered to the retina over a large surface and with its slow shrinkage the retina is pulled off and fluid is effused beneath it *ex vacuo*. The cause of the lesion in the vitreous is to be looked for in chronic disease of the choroid and ciliary body; in this we have the explanation of the frequent implication of myopic eyes. It is not necessary to find visible opacities in the vitreous to warrant the above theory, although they are extremely common. We need not attempt to account for some special peculiarities which are met with; the elaborate treatise of Nordensen, who wrought out the explanation first announced by Leber, will answer many questions.

Diagnosis.—Besides impaired sight we have the notable defect in the field, and the ophthalmoscopic appearances will in the great number of cases be easily interpreted. The inverted image will give a correct idea of the relation of parts, while with the mirror alone an unexpectedly distinct view of the separated retina appears at a distance from the eye, denoting a high degree of hyperopia. If the retina flutters much, this indicates fluid on both sides of it. If it be tense and smooth it will lie in contact with the vitreous. Difficulty in diagnosis arises only with small and transparent effusions, but they will be revealed on careful study with the upright image. An important matter is to recognize intraocular tumor concealed beneath a separated retina. The most valuable distinction is that as a rule in simple retinal detachment ocular tension is *minus*, while with tumor it is *plus*. Some rare exceptions have been noted, but the rule is in general a good one. There will be a

[1] "Die Netzhautablösung." Wiesbaden, 1887, pp. 255, with 27 plates.

Digitized by Google

history of slow encroachment on the field; there may also be hemorrhage into the vitreous with tumor. (See also p. 590.) If the retina be thickened, and have whitish deposits mingled with a mesh of vessels upon its surface, and be at the same time tense and rounded, there will be great liability to suppose it to be a tumor: especially when located at the periphery. I have been compelled to wait the course of events which alone could settle the diagnosis; and I have fallen into a mistake in recommending enucleation when it was needless, because I was deceived as to the existence of tumor.

Prognosis is, as a rule, unfavorable. An advantage attaches to the descent of the fluid to the lower part of the eye, which commonly occurs at an early date, because blindness above the horizon is less injurious than blindness below the horizon. The replaced retina generally recovers part of its function; it happens, too, that some absorption is common, and it is of the greatest consequence to have the macula escape. But, even when it does not seem to be involved, we may find metamorphopsia. I have already mentioned the dulness of sight due to torpor of the retina, and degenerative changes are quite probable; moreover, a detachment is prone in time to become greater or even total. It is a frequent thing to have cataract occur; I found it twelve times among fifty-eight eyes. Spontaneous recovery takes place in a few cases; I have observed it four times—all were myopic persons—two were not treated at all; one was treated antiphlogistically, and he had irrecoverably lost one eye already by the same lesion; the fourth was operated on by scleral puncture, and with no good result for three months, but after that time a great portion of the fluid disappeared. Leber reports a case which recovered spontaneously from five successive attacks.

Treatment.—This will be either medical or surgical or both. A widely prevalent practice has been confinement to bed for four or five weeks, a pressure bandage on both eyes, and use of infusion of jaborandi, or hypodermic injection of the muriate of pilocarpine gr. $\frac{1}{6}$ to $\frac{1}{4}$, to active diaphoresis and salivation. The last-mentioned remedies are often not well borne, and many have lost faith in them. Improvement has been witnessed in many cases, as the result of confinement, but it is extremely irksome and to many subjects intolerable.

Therefore, an entirely opposite plan sometimes commends itself, viz., to use such means as will best and most rapidly promote the general nutrition, withholding the eyes from all use. This means abundant food, exercise, and recreation, and avoiding everything likely to cause congestion of the head, and is not inconsistent with light purgatives and such medication as circumstances may indicate.

Digitized by Illinois College of Optometry

A choice between these opposing methods may be determined by the patient's general condition. If the health should be such as to contra-indicate the treatment by bandage and close confinement, it would certainly be unwise to enforce it. If not injurious to health, it is most suitable to resort to it at the outset. To compel absorption Dr. Carl Koller (personal communication), has had one success by injections of pilocarpine reinforced by insisting upon total abstinence from all fluids for several days and confinement to bed. Cases of recovery are reported by those measures, and by other means, viz., iodid potas., salicylate of sodium, tonics, etc.

To bring about the replacement of the retina there must either be absorption of the underlying fluid or its transfer to the front of the retina. A most natural suggestion is to let out the fluid. Von Graefe and Bowman punctured the sac to let its contents diffuse into the vitreous. Some gratifying results ensued, but rarely were they permanent. Some cases were rendered worse; I have had two such unpleasant experiences. At present this treatment has been abandoned. Wecker at one time introduced a gold-wire suture or seton into the sclera. This has not found general approval, and some cases of destructive irido-choroiditis have been caused. Puncture of the sac through the sclera was done to evacuate the fluid externally in 1859 by A. Sichel, and has been repeated since by Arlt, Alfred Graefe, Hirschberg, and others. A paper by Hirschberg, reporting ten cases of scleral puncture, authorizes the conclusion that no harm is done, that in most cases improvement is gained, but that relapses are to be expected. Higgins reported double optic neuritis with subretinal effusion in both eyes, and in one tapping was done once, and in the other eye was done three times, and in neither case with any benefit. Detachment in both eyes during pregnancy has been reported by Adamück, and others, resulting from albuminuria and sometimes precipitated by eclampsia. Premature delivery in Adamück's case restored both eyes. The vitreous is always assumed to be in a degenerate state to admit of the detachment of the retina.

Wolfe, of Glasgow,[1] makes an incision upon the line of a meridian six to eight millimetres long, first laying off the conjunctiva and keeping it retracted by hooks, and by the large wound insures free drainage of fluid. He has reported several cases of good result. When the retina floats freely, this is all that is required. If, however, the retinal sac is smooth and tense, denoting a vitreous of normal consistence, it would seem proper to puncture the retina at the same time that the sclera is incised. Brailey gives three cases of decided improvement after incision. In his cases, as in most

[1] Annales d'Oculistique, 91, 92, p. 149, 1884.

Digitized by Google

others, the patients are put to bed with bandaged eyes for a week or so, and may also receive diaphoretic treatment. An iridectomy lance or a Graefe's knife may be used, and cocaine will suffice usually as an anæsthetic. The reaction is generally moderate.

On the whole the results of treatment are not encouraging, and puncture has proved uncertain; either of no benefit, or if helpful often for only a short period—in a few cases permanent, but in the great number, as reported by many observers, relapsing in four or five weeks. It may be said to be permissible but not obligatory. So long as perception of light remains it may be employed. Sutphen reports a cure maintained for three years to last observation (Trans. Am. Ophth. Soc., 1888).

Some French surgeons, notably Galezowski and Dransart,[1] to cure the separation have practised a broad iridectomy. The former is less enthusiastic about it than he was at first, but still resorts to it, especially when both eyes are affected. The latter reports forty operations and eighteen recoveries. The duration of the cases was from two weeks to about a year. The amount of vision regained was in all the alleged recoveries, save one, very imperfect. Further evidence is required to form an opinion on the real value of this suggestion. Coppin[2] reports upon eighteen cases treated by iridectomy, and by the subsequent confinement to bed, bandage, and derivatives, with the result of two successes, two temporary improvements, eleven without benefit, and three losses. Some cases are complicated with irido-cyclitis and synechiæ, and to them iridectomy would be applicable. After Wolfe's operation with a large incision of eight to twelve millimetres and followed by such treatment as above outlined for a month, in fifteen eyes he had eight cases of improved vision lasting from five months to a year; in one of these vision was $\frac{1}{2}$, while the remainder had $\frac{1}{6}$ to $\frac{1}{50}$; in five no benefit was gained and two eyes were lost.

Evidently iridectomy does not offer much encouragement, and the large sclerotic incision, even when reinforced by the derivative treatment, gives a valuable success in very few cases. Injection of tincture of iodine, two or four drops, into the vitreous has been brought to notice by Schoeler, who reports five cases; three of these continued to have detachment, but vision was much improved. Abadie commends the treatment; Grosz and others find no benefit from it; Schiess, 1890, in two cases obtained some absorption in one case, and the patient had to be discharged prematurely because of homesickness. In the other case the retina became replaced but cataract ensued. This complication is reported by others. In his

[1] Bulletins et Memoires de la Société Française d'Ophthalmologie, p. 178, 1886.

[2] Ibid., p. 100, 1887.

Digitized by Internet Archive

original paper Schoeler ("Zur operatiren Behandlung und Heilung der Netzhaut ablösung," Berlin, 1889) gives five chromolithographs and other diagrams of the five cases on which he based his report. He observed, in all cases but one, considerable reaction and vitreous opacities. Treatment lasted for from four to eight weeks. He employed hypodermic injections of biniodide of mercury (hyd. biniod. 0.25, kalium iodat 2.5, aq. distil. 25.0, of this one gram) once daily into the muscles of the back while the reaction continued; also atropine, etc. The cases on recovery presented reattachment of the retina and spots of choroido-retinitis with pigment, evidently indicating adhesions. Bull reports five cases with unsatisfactory results, and in some great reaction (Trans. Am. Ophth. Soc., 1891, p. 30).

Sometimes we are called upon to remove cataract, consecutive to detached retina. By needling very little absorption is to be procured. Only extraction is to be relied upon. The object is simply in most cases to remove a blemish. It might be expected that a partial detachment would afterward become more extensive or total. This does follow, but does not necessarily occur. The hope of improving sight by removing the cataract is in most cases delusive.

The great frequency of this disease as a cause of blindness is referred to in the chapter on Blindness.

Glioma Retinæ.

Fungus Hæmatodes of the Eye.—The subjects of the above disease are often infants, and none have yet been recorded whose age was above sixteen years—the great majority are below ten. Very rarely it is congenital. The cases are usually discovered by a bright reflex from the interior of the eye, which arrests attention. Usually only one eye is involved, but both eyes may be implicated simultaneously, or in succession. There will have been no preliminary symptoms, and the anterior part of the eye may be normal.

The appearance varies with the extent of the growth. When observed early, the ophthalmoscope or oblique illumination will detect a white or yellow, or reddish-yellow surface, with blood-vessels whose arrangement is more or less plexiform and unlike the retinal circulation, and they will be minute, or possibly very scanty; exceptionally no vessels may be visible. The surface may be smooth or nodulated. Inspection is easy, because the mass approaches the nodal point. The retina may be in position or, more usually, it is detached by effusion. The vitreous and lens are clear. As the tumor grows, the lens is pushed forward; the pupil becomes sluggish and dilated—may become adherent; the anterior chamber is

Digitized by Illinois College of Optometry

shallow; the anterior ciliary vessels are distended. If long duration and sufficient growth be permitted, the coats of the eye give way and bulgings appear. After a time the mass crops out, becomes ulcerated, bleeds, gives forth sanious and fetid discharge, and a projecting, hideous tumor may be formed. Pain begins with distention and external development, and cachectic symptoms soon arise. Surrounding parts, such as the bones of the head or the brain, become involved, and metastasis may take place to other parts of the body. Death, either by exhaustion or by brain-disease, is the final event.

Prognosis.—While fatal if left to itself, or if not cut short at an early period, experience has shown that a very early removal of the eye may save life, because in the beginning the disease is local. We have authentic cases to verify this statement. Vetsch[1] gives thirteen cases, Hirschberg out of seventy-seven cases reports five recoveries, *i.e.*, 6.5%. He reports a congenital case (*Centralblatt für Augenheilkunde*, April, May, 1884). I have had two permanent recoveries or rescues in my own experience. When relapse occurs, it is within a few weeks, perhaps within less than a month, or within three months. Several children in the same family have been known to be affected. Wilson reports eight children attacked, of whom three died by this affection; the others survived ("Oph. Hosp. Rep."). The most usual mode of death is by extension of the disease through the optic nerve to the brain. Should a relapse occur, a fatal issue is almost certain. A single case is given in which the patient survived after removal of a secondary tumor.

The Pathology of the growth has been carefully studied by Knapp, Hirschberg, Delafield, and others. It consists of small round cells, similar to, but not, as once supposed, identical with the granular layers of the retina, besides a scanty amount of fibrous tissue and numerous blood-vessels. The starting-point is most frequently from the external granular layer, but it can begin from any other layers. Delafield remarks that the disease is anatomically identical with small round-cell sarcoma, and might be so called. Hirschberg and Bull concur in this view. It may grow outwardly or inwardly, more frequently the latter. Its prevalent mode of extension is along the optic nerve.

Diagnosis.—There are several possibilities of error. 1. Glioma should not be mistaken for choroiditis metastatica. In the latter case there will be a history of a preceding sickness, either of the brain or of the spinal cord, or of both as cerebro-spinal meningitis, and redness of the eye may have been noticed. There will usually be a shallow anterior chamber, the pupil adherent and irregular,

[1] Arch. of Ophthalmology., Am. Ed., xii., 43, 1883.

Digitized by the Boston Medical Library

the periphery of the iris retracted, the lens pressing against it, the globe a little reduced, tension minus; the yellow mass may be vascular, and the retina may or may not be detached. The symptoms and history of an inflammation are the clue. It is conceivable that an eye having glioma may be seen during the period of glaucomatous outbreak and the existence of deep disease never have been recognized, and at the time be masked by turbidity of the media. Wadsworth reports one such case, and the cornea was suppurating. An incision to relieve the suppuration discovered the tumor.

2. Raab (*Arch. f. Oph.*, XXIV., iii., 163) gives the anatomical description of three eyes enucleated as gliomatous, which had a peculiar deposit of fibrous tissue behind the lens, resulting from cyclitis or from choroiditis. In one case the lens and iris were pushed forward, the pupil dilated to an extreme degree; there was a greenish-white reflex, upon which red streaks could be seen; tension a little plus; slight punctate opacity of the cornea; the peri-corneal and ciliary vessels were injected. In the other two cases the facts were somewhat different, but need not be repeated. In all, there was increased tension, absence of inflammatory tokens in the anterior part of the globe, and the presence of a light-colored mass in the depth of the eye. As a rule in plastic cyclitis or choroiditis, there will be diminished tension, tenderness on pressure, discoloration of iris or ciliary hyperæmia. Yet inflammatory growths have been mistaken for true glioma by the best observers.[1] It must be admitted that a mistake in diagnosis would, under such circumstances, be pardonable.[2]

3. I have seen two cases, in young subjects, in which there were intraocular deposits, resembling glioma in all microscopic appearances, which ultimately terminated in the disappearance of the mass. There were no signs of inflammation, and, for want of better knowledge, they were called cases of "strumous" deposit.

4. Schiess (Basel, 1891, p. 48) reports a case in a child of three years, of total detachment of the retina, presenting two nodular white masses which, on examination, proved to be merely thickened retina; yet the diagnosis was glioma. There was no history of injury.

5. White sarcoma of the choroid is not found usually at the early age when glioma occurs, yet I have one such case recorded in a child eight years of age.

Treatment.—Medication is useless, and the only safety lies in the earliest possible removal of the globe, with as much of the

[1] "Untersuchungen über intraoculäre Tumoren. Netzhaut Gliome," Dr. J. R. Da Gama Pinto, 1886.

[2] "Pseudo-glioma from Traumatism," Trans. Am. Oph. Soc., 1887, p. 485, H. D. Noyes; also, Trans. Am. Oph. Soc., 1869.

Digitized by Illinois College of Optometry

optic nerve as can be excised. There is encouragement that life can be saved if the disease be extirpated at an early date—the operation would be proper at a later period to relieve pain, but at the stage of fungus growth the undertaking may be too formidable. The surgeon will act according to his discretion, in view of all the circumstances. Should the painful condition present itself of glioma in each eye, I should not hesitate to enucleate both, if, by so doing, a fair prospect of life could be secured. Carmalt [1] reports removal of both eyes of a child two and a half years old, for a glio-sarcoma in each, and that after three years the child was living and healthy.

To remove an eye which is the seat of some disease that resembles, but is not glioma, is a needless mutilation; but it may be justly argued that it is better to err on this side than to fail to remove an eye which is truly attacked by this formidable malady. Moreover, the cases of pseudo-glioma may demand extirpation because of danger of sympathetic trouble to the fellow-eye.

There is one case on record of preservation of life when the disease reappeared in the orbit and was again removed. All its contents must be taken away, and the walls of the orbit treated with chloride of zinc. But the probability is against recovery.

[1] Trans. Am. Surg. Assoc., June, 1892.

Digitized by Illinois College of Optometry

CHAPTER XVIII.

THE OPTIC NERVE.

Anatomy and Physiology.—Within recent years our knowledge of this topic has gained so much in precision and richness that it will be proper to give an account of it which shall clearly yet succinctly, set forth the recognized facts. Their bearing upon pathology and upon clinical experience justifies or perhaps compels such a rehearsal.

The optic nerve may be considered in three separate regions: its cranial, its orbital, and its intra-ocular portions.

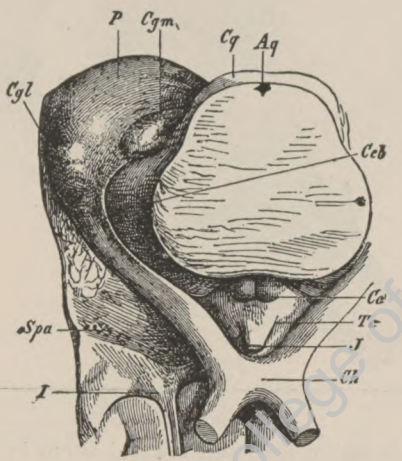

FIG. 235.—Base of the Brain to show the Emergence of the Optic Nerves. The cerebral hemispheres have been removed to show the posterior portion of the optic thalamus. The peduncles have been divided behind the corpora quadrigemina. *Cgm*, Corpus geniculatum mediale; *Cgl*, corpus geniculatum laterale; *P*, pulvinar of the thalamus; *Ch*, chiasma nervorum opticorum; *Cq*, corpora quadrigemina; *Aq*, aqueductus Sylvii; *Ceb*, pedunculus cerebri; *Cc*, corpora caudicantia (mammillari); *Tc*, tuber cinereum; *J*, infundibulum; *I*, tractus olfactorius separating into its middle and lateral roots; *Spa*, substantia perforata anterior.

Within the skull the nerves are short and flattened, and they diverge from the optic chiasm to reach the canalis opticus on either side of the median line under the tip of the lesser wing of the sphenoid bone. The chiasm is a flattened mass elongated transversely and resting on the olivary process or body of the sphenoid. The anatomy of the parts in this region is familiar; and it is only needful to refer to the order of the organs arranged on the median

Digitized by the Internet Archive College of Optometry

line beginning with the anterior perforated space and lamina terminalis cinerea; behind, is the optic commissure or chiasm, from whose posterior angles diverge the tractus optici, to wind around the crura cerebri (peduncles). Abutting upon the posterior border of the chiasm is the tuber cinereum, which narrows to the tube-like infundibulum and terminates in the posterior lobe of the pituitary body; and this is lodged in the sella turcica. Behind the tuber lie the corpora mammillaria (albicantia, candida); on either side of

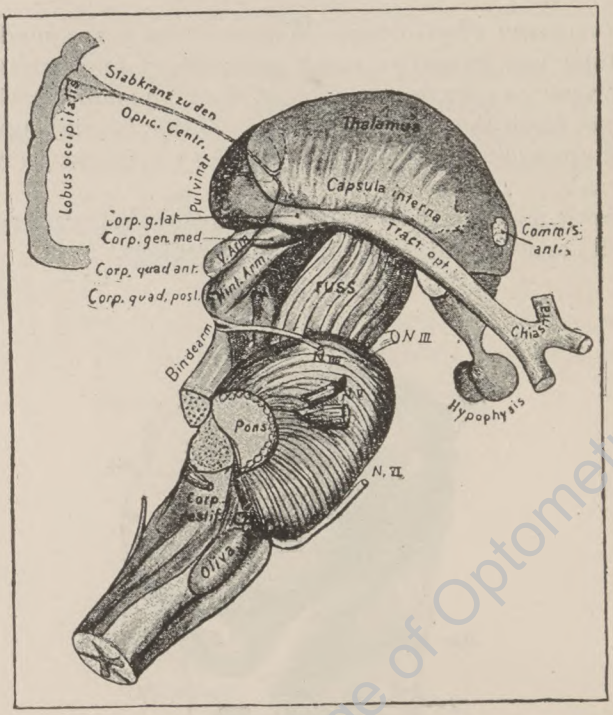

FIG. 236.

and close to the median line and behind them is the posterior perforated space.

In Fig. 236 in which the parts are schematically portrayed, the tractus opticus is seen passing around the crus cerebri (German, *fuss*) to the corpus geniculatum laterale or externum, in close relation with the corpus geniculatum mediale or internum and reaches the posterior extremity of the thalamus opticus which is called the pulvinar. Deeper connections are omitted. In Fig. 237 which is also schematic, the same relations are displayed upon a nearly horizontal section. By this figure the following facts are exhibited: Each optic nerve contains fibres coming from the tractus of its own side (direct fibres, fasciculus non-cruciatus)

Digitized by Illinois College of Optometry

and also fibres coming from the opposite tractus (crossing fibres, fasciculus cruciatus). There is also seen a loop passing across between the tractus which is the posterior commissural band of Gudden: sometimes called inferior or arcuate commissure. Beneath this, but not exhibited, lies still another and much smaller commissural band, which is Meynert's. See article on Chiasm, by Stefan Bernheimer (*Archives f. Ophthal.*, Vol. XX., No. 2, p. 163, with illustrations, 1892), which fully confirms the above statements.

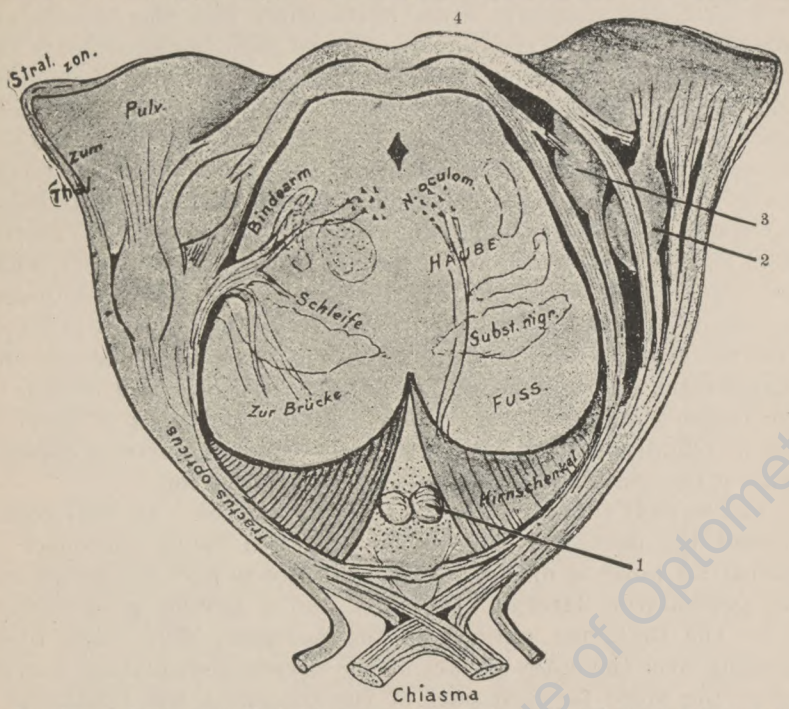

FIG. 237.—1, Corpora mamillaria lying upon the posterior perforated space; 2, Corpus geniculatum externum or laterale; 3, corpus geniculatum internum or mediale; 4, corpora quadrigemina to which proceed the brachia antica and postica.

Bindearm = Brachium.
Zur Brücke = To the pons.
Fuss = Pes.
Zum Thal. = To the thalamus.
Schleife = Fillet or Lemniscus.
Haube = Tegmentum.
Hirnschenkel = Pedunculus.
Strat. Zon. = Stratum zonulare.

The fibres of the chiasm intricately interlace, and the crossing set are upon the ventral and inner (medial) region; the direct fibres are upon the dorsal and lateral surfaces. The crossing fibres are the more numerous as three to two. The question of the arrangement of the fibres in the chiasm, as between partial and total decussation, has been hotly contested. The proof that it is partial is now conclusive. In fishes the opposite arrangement obtains. The result is that the tractus opticus of the right side supplies the right half of each retina; the tractus of the left side the

Digitized by the Illinois College of Optometry

left half of each retina, because each optic nerve is made up of fibres from both tractus. The separation between the temporal and nasal halves of the retinæ is by a line nearly vertical, as shown by cases of homonymous hemianopsia, yet not always passing exactly upon the vertical meridian—a circumstance to be dwelt upon hereafter. The division is, however, sufficiently vertical and mesial in each eye to enable us to locate the position of a lesion, either in front of or behind the chiasm.

It is found that still other fibres enter into the chiasm, viz., some from the tuber cinereum, and some from the substantia perforata anterior and from the lamina cinerea terminalis which lies just behind it in the recessus opticus. The fibres last mentioned come down to the chiasm in part from the gray matter of the wall of the third ventricle. The vicinity of the optic commissure to this cavity makes its morbid conditions of great importance to sight; for example, in hydrocephalus internus, etc. Among fibres derived from the tuber cinereum are large ganglion cells (Wagner), which are called by Meynert the basal ganglion. The fibres composing the commissure of Meynert soon quit the tractus, penetrate in curved lines the crura cerebri, and appear to terminate in the corpus subthalamicum or ganglion of Luys which lies above and outside of the corpora mammillaria. These commissural fibres of Meynert and of Gudden serve to connect corresponding parts on opposite sides of the brain and have no direct visual function.

Let us next trace the tractus to their sources. As they course around the peduncles they divide into two roots, an outer or lateral, an inner or medial. The outer root in part enters the corpus geniculatum laterale (Fig. 237), and a portion goes beneath it to the thalamus opticus at the pulvinar; still other fibres crossing over the outer surface of the corpus geniculatum laterale reach the more forward part of the thalamus, and constitute a part of its radiating superficial striation (tectum thalami), stratum zonulare in Fig. 237. Another set of the fibres of this group go to the anterior corpora quadrigemina by the brachium anticum. See Fig. 237 and Fig. 70, p. 150. This root of the tractus therefore goes to the corpus geniculatum laterale, to the thalamus opticus, and to the anterior corpus quadrigeminum (natis). From these ganglia go forth the radiating visual fibres of Gratiolet, which in the posterior third of the internal capsule finally attain the gray matter of the occipital lobe, indicated in Fig. 236, p. 642, as Stabkranz zu den optic. Centr. In their course they pass outside the posterior horn of the lateral ventricle. It follows from this arrangement that the same kind of hemianopsia will ensue from lesion of the posterior part of the internal capsule and the designated occipital region, as will be caused by lesion of the corresponding tractus.

Digitized by the College of Optometry

The inner or medial root of the tractus goes to the corpus geniculatum mediale, Fig. 237, and by the brachium posticum reaches the posterior corpus quadrigeminum (testis); a few fibres also go there directly and another small portion go to the anterior corpus quadrigeminum. Yet another bundle of fibres leaves the inner root of the tractus before reaching the corpora geniculata to pass through the outer part of the pedunculus (crus) cerebri and part of it goes direct to the cortex of the occipital lobe. See left side of Fig. 237. In this same bundle it is thought that fibres exist which gain the cortex without traversing the primary ganglia; but it is doubtful. If they do exist, they lend no support to the theory of crossed amblyopia, which Charcot advocated and which Gowers also is inclined to sustain. Stilling and Edinger emphatically assert that yet another bundle of this group makes its way through the crus to the pons Varolii, goes down alongside one of the roots of the trigeminus to the posterior (sensitive) columns of the cord. He calls this the *radix descendens*. By this bundle are we enabled to comprehend the implication of vision which occurs in locomotor ataxy. These fibres are indicated in Fig. 236 and in addition other fibres reach the nuclei of the third nerve to establish the recognized pupillary reactions. Out of the same internal root of the tractus are developed fibres which terminate in the corpus dentatum of the cerebellum. The inner root of the tractus is thus perceived to be the principal medium of relation with the corpus geniculatum internum and with remote parts; while the outer root is destined chiefly to the thalamus, the anterior corpus quadrigeminum and the corpus geniculatum externum. These last-named three bodies are the important endings of the optic nerve and are known as the "primary visual centres." In the mass of ganglion cells and fibres (neuro-spongium) of which they consist, the optic impressions are transformed in some unknown way and conveyed by a new set of fibres, "the visual radiations," in the posterior part of the corpus callosum, to the cortex of the occipital lobe.

The internal or medial geniculate bodies and the posterior corpus quadrigeminum (testes) take no part in vision. They are believed to be concerned in hearing. See M. Foster, "Text-book of Physiology," Part III., p. 1089. London, 1890.

If both optic nerves are destroyed, atrophy ensues in a large part of both tractus, the corpora geniculata lateralia, the anterior corpora quadrigemina, and in the posterior part of the optic thalami; but a part of the tractus is preserved, viz., the commissures of Gudden and Meynert, which is ground for believing that they have no direct function in vision. The corpora geniculata interna and the posterior corpora quadrigemina are likewise not visibly injured.

Digitized by Union College Library

Striking testimony confirming the experiments of Gudden is afforded by cases of congenital anophthalmus. See Haab ("Beiträge zur Ophthalmologisches Festgabe, Friedrich Horner," 1881, p. 131), who examined the brain of an idiot girl, 27 years old, in whom this condition existed. The body was small and the head in relative proportion. The eyeballs were simply rudimentary, their muscles well developed; the optic nerves and the chiasm were wanting; the tractus simply small cords and composed of the commissural fibres of Gudden and Meynert as proved by their destination. The corpus geniculatum externum (laterale) was entirely absent; the pulvinar much reduced in size. The anterior corpus quadrigeminum not much reduced visibly in bulk, but under the microscope it showed manifest impairment. The internal corpus geniculatum and the posterior corpora quadrigemina entirely normal in size and structure.

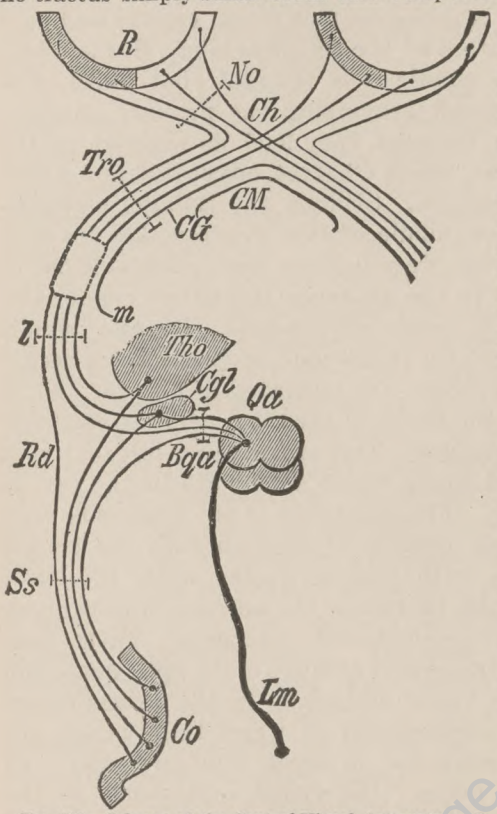

FIG. 238.—Scheme of the Central Visual Apparatus.—*R*, Retina, shaded where it is innervated by the left, clear where innervated by the right hemisphere; *No*, nervus opticus; *Ch*, chiasma; *Tro*, tractus opticus; *CM*, Meynert's commissure; *CG*, Gudden's commissure; *l*, lateral tract root; *m*, median tract root; *Tho*, thalamus opticus; *Cgl*, corpus geniculatum laterale; *Qa*, nates; *Bqa*, brachia anteriora; *Rd*, direct cortical tract root; *Ss*, sagittal medullary layer of occipital lobe; *Co*, cortex (chiefly of the cuneus); *Lm*, median tract (Schleife).

A few words on the functions of the anterior corpora quadrigemina (bigemina). They are in connection (1) with the tractus opticus directly by the brachia anteriora; (2) with the corpora geniculata lateralia and so indirectly with the tractus opticus; (3) with the cortex of the occipital lobe by the brachia anteriora and by the radiation of the internal capsule (Gratiolet); (4) with the spinal cord by the middle fillet (radix descendens); (5) with the nuclei of all the ocular muscles, and their relations to the pupils by the so-called bundle of Meynert is especially important.

The connections of the posterior corpora quadrigemina are much more obscurely known: (1) with the inner root of the tractus by the corpus geniculatum mediale (perhaps also directly); (2) with the cortex of the cerebrum and in both cases by way of the brachia posteriora; (3) with parts belonging to the spinal cord (especially the region of the acusticus) by the lateral fillet. That they have

Digitized by University of Illinois at Chicago Library

important relations to the auditory centres, and that the commissure of Gudden subserves this function, is becoming a prevalent opinion.

Fig. 238 condenses many of the above statements in pictorial form, and its study will explain variations in visual disturbances according to the different localities involved. For instance, disease at *No* impairs only the left eye and all of its field; at *Ch* affects the inner half of each retina and causes bitemporal hemianopsia; at *Tro* causes right homonymous hemianopsia, and the same effect ensues from lesions more caudad as far as the cortex.

After leaving the primary ganglia the visual fibres pass caudad, as has been said, under the name of the optic radiation. The general opinion has been that the whole region of the occipital lobe and especially the cuneus is to be regarded as the visual centre. Investigations by Henschen,[1] whose elaborate and rigid analysis of a large number of cases in great detail cannot fail to carry conviction to the mind of the reader, establish a more exact and limited region as the vital seat of vision. He shows that at a distance of six or seven centimetres from the occipital apex the fibres are gathered into a compact bundle which is about four mm. in diameter. It lies at the level of the second temporal convolution. In it the upper fibres correspond to the upper part of the retina and the lower fibres to the lower part of the retina. The fibres to the macula are probably more medial. The crossing and non-crossing fibres lie in immediate proximity to each other and are intermingled.

An extremely important and interesting discovery from Henschen's analysis is that the really essential part of the visual area is the calcarine fissure marked in his plates *oc*. Unless this is touched hemianopsia does not occur; when it is implicated, hemianopsia is complete. This is a new fact, and for proof one must study the cases and diagrams which Henschen presents. The subjoined figures represent the most conclusive cases yet on record. In Fig. 239, case A (Henschen, Th. II., p. 324, Karte G.), by Reinhardt, shows the lesion described, and there was no other to account for the hemianopsia, although in the second and third occipital convolutions were areas of softening, but which could not, as will later be shown, cause this result. Case B (l. c., II., pp. 386–394) was a hard drinker, who had no other nervous symptoms than hemianopsia, and at the autopsy nothing was found except what is shown in *B* and *B'*; the latter being a section of the occipital lobe about five cm. from the apex. Some 500 microscopic preparations of the brain were examined. The visual fields were

[1] Klinische und Anatomische Beiträge zur Pathologie des Gehirns, Upsala, 1892, Erster und Zweiter Theilen.

Digitized by Illinois College of Optometry

unequally divided, the line of demarcation running irregularly and encroaching much on the blind halves. In case C, by Dr. Hun, of Albany, N. Y., which is well known, the loss of sight was at the upper quadrant only of each eye, on the left side, and the lesion being at the lower part of the cuneus, the inference was that the upper part of the cuneus answers to the lower quadrant of the

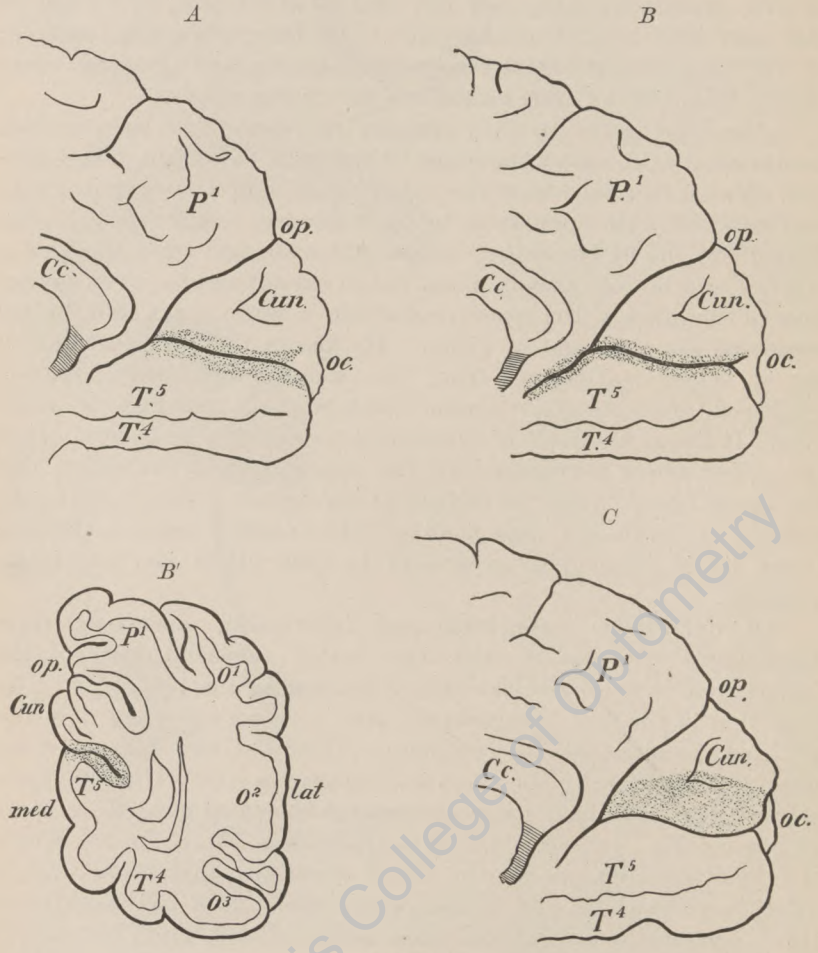

FIG. 239.

retina. But the explanation must be that the upper lip of the calcarine fissure answers to the upper side of the retina and the lower lip to the lower side of the retina. It must be added in further proof of the above conclusions that Henschen depicts and quotes many cases where the occipital lobes on the ventral, the posterior, and the external surfaces were affected, and some in which spots

Digitized by Illinois College of Optometry

of the cuneus displayed lesions not touching the calcarine fissure, and in none of them did hemianopsia appear. This point will be again referred to.

It is, however, admitted that we find in the outer surface of the occipital lobes, in regions not yet precisely defined, but lying near the angular and supra-marginal gyri, areas connected with visual acts in the sense of visual memories, and lesions in them give rise to the singular symptom pointed out by Munk and called by him psychic blindness, now spoken of as a form of *apraxia*. It has been shown by many examinations, of which Henschen quotes several (see Taf. VIII.), and one of the most carefully studied of which is by Professor Donaldson,[1] of Clark University, Mass., that in cases of early or long-continued blindness the occipital lobes undergo atrophy. Professor Donaldson says the atrophic area includes the cuneus and angular gyrus, but does not pass over to the ventral surface. The thinning which the cortex suffers is not the same throughout the visual area, but is small in the cuneus and occipital pole, large in the areas immediately surrounding it and finally small again in the most outlying portions. Professor Donaldson thinks the reason for these differences lies in the fact that the parts most essential to vision are earlier and more highly developed and more resistant to disturbing influences.

We may now turn back to a more detailed study of the optic nerve.

As to the *orbital* part of the nerve: each optic nerve reaches the orbit by the foramen opticum, or canalis opticus, and adheres very closely to the wall of the canal by its external sheath. The canal is five to six millimetres long. Important vessels here enter the nerve—one is called the arteria centralis posterior. (It may be well to call attention to the close proximity of the canalis opticus and of the cavernous sinus which receives the ophthalmic vein, and of the carotid artery, which sends off the ophthalmic branch to accompany the nerve in its passage through the foramen. The ophthalmic vein passes through the sphenoidal fissure.) From the chiasm to the foramen, the nerve is usually about 10 mm. long, while its orbital portion is 28 to 29 mm. long. It is round, and about 4 mm. in diameter. It touches the globe abqut 4 m. to the nasal side of the optic axis and a little below it. It passes in the midst of the ocular muscles, and is surrounded by fat and connective tissue. It is somewhat sinuous in its course, and long enough to permit free movement of the globe. As it proceeds forward it is slightly twisted, so that the lower surface turns to the temporal side. Within the skull the nerve has only a pial sheath; in the

[1] "The Extent of the Visual Cortex in Man, as deduced from the study of the Brain of Laura Bridgman," Am. Journal of Psychol., August, 1892.

canalis opticus we find an external or dural sheath, which also serves as periosteum, and within it is the internal sheath, more delicate and closely attached to the trunk and also called the pial sheath. Between the sheaths is a space occupied by delicate trabeculæ of connective tissue and by lymph. This is continuous with the arachnoid cavity of the brain, and may be injected from it, and the cavities are lined by endothelium. Still another lymph space, normally microscopic, lies beneath the pial sheath, but pathologically it is sometimes conspicuous. At a point varying from fifteen to twenty millimetres distant from the globe, the nerve is pierced by the arteria and vena centralis retinæ, which enter it obliquely and pass into the eye.

As the nerve gains the eye, its external sheath mingles with the outer part of the sclera, the internal sheath passes inward a greater distance, and mingles with the inner layers of the sclera. It also sends into the nerve septa of connective tissue, by which it is subdivided into numerous fasciculi, about 800 (Schwalbe), but exhibits a more compact mass when seen in cross-section than do most nerves. On passing within the globe, not only are the enveloping sheaths left behind, but the septa which isolate the fasciculi also turn aside and become attached to the adjacent sclera. The nerve fibres now lose their neuroglia, and are reduced to naked axis-cylinders. Thus liberated from all its accompanying connective tissue, the nerve becomes transparent and of less diameter, viz., one and a half millimetres, and terminates as the optic papilla. There is a mesh-work of fibrous tissue interwoven among the nerve-fibres at the level of the sclerotic opening, which is called the lamina cribrosa. It is made up of the connective-tissue sheaths and septa above mentioned. This structure is the limit beyond which inspection by the ophthalmoscope is impossible, and it is more or less visible according to circumstances. The inter-vaginal space passes into the sclera for a slight distance, viz., as far as the lamina cribrosa. The optic-nerve fibres before they gain the retina must not only pierce the sclera, but the choroid likewise; this they do through a circular opening. The edge of the opening is sometimes in close contact with the nerve, and sometimes a small space is left, through which the sclera can be seen from within as a ring.

Some facts as to the appearance of the optic disc, and the distribution of its vessels, have been stated on page 47 *et seq.* A circlet of vessels (*circulus Halleri*) surrounds the nerve-head, which bring it into communication with both the choroid, the sclera, and the optic sheath, as well as with the retina. A much greater vascularity is furnished at this spot than at any other outside point of the globe. Stilling states that by the lymph-vessels of the papilla some of the fluid of the vitreous humor escapes.

Digitized by the Internet Archive of Canada

Digitized by Illinois College of Optometry

1

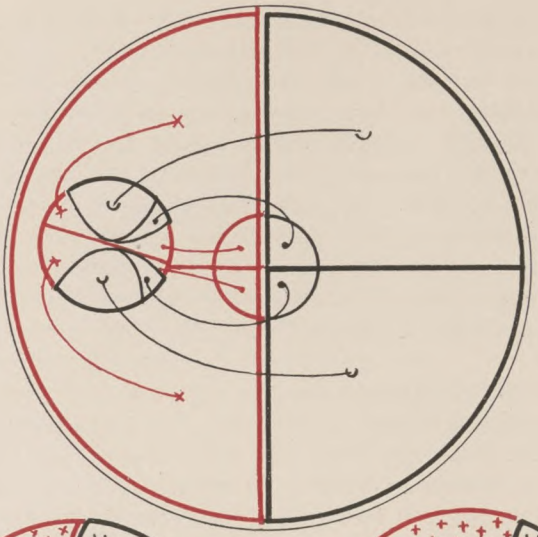

2

3

4

5

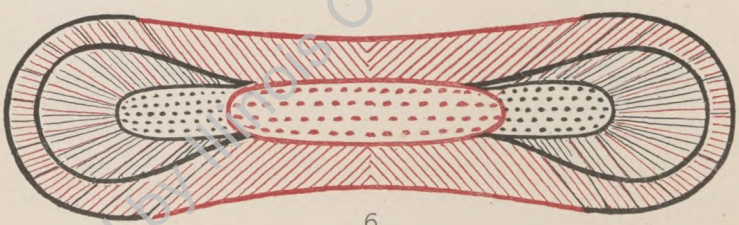

6

Digitized by Illinois College of Optometry

The number of fibres in the nerve has been estimated to be 438,000 (Salzer), and by Krause 1,000,000; one-fourth of them (Bunge [1]), or one-third of them (Uhthoff [2]), are considered as belonging to the macular region. Considerable interest attaches to the determination of how the various groups of fibres making up the optic nerve are arranged. We have three sets for visual purposes, viz., the macular, the direct (uncrossing), and the crossing fibres; besides, there are fibres for the pupillary reactions, and of these last we know nothing. But of the visual fibres our knowledge as to their arrangement is remarkably precise. Samuelsohn (1882), Vossius (1882), Nettleship, Bunge (1884), and Uhthoff (1886), had singular opportunities for defining the position of the macular group, and the relations of the crossing and direct fibres have been ascertained by several investigators through the study of cases of monocular optic atrophy. Schmidt Rimpler's [3] case is one of the most valuable. But the subject has been handled by Henschen [4] in his splendid monograph in the most masterly way. Collating the work of other persons and adding cases of his own, he has constructed a diagram which is the representation of our present knowledge. It is, however, understood that scope must be allowed for individual variations. He traces the several groups through the orbit to the chiasm and up the tractus. In Plate A we have his conclusions.

Fig. 1 represents the retina of the right eye with the macular area in the centre, denoted by the circle, and the papilla to the left. The retina is divided by a vertical line into halves, of which the lateral (temporal) side is supplied by the direct fibres and the medial (nasal) side is supplied by the crossing fibres. The parts of the optic disc from which these fibres respectively arise are denoted by the peculiar areas laid out upon its surface. Those parts included within black lines go to the temporal side of the retina and represent the direct fibres. The remaining portion composing an irregular figure in red, contains crossing fibres, and they are destined to the nasal side of the retina. But close inspection shows certain lines from parts of each of these areas which lead to the macular region, and in a significant manner. Their purpose will be understood by looking at Fig. 2, which is an enlarged representation of the papilla. In it again the spaces marked out by black lines indicate the direct fibres, and we find them in two bundles, one above, another below, and the chief portions lie on the temporal side. From each of these a small sector is marked off from which spring the fibres to the temporal side of the macular region. These special subdivisions are seen also in the papilla of Fig. 3, and from them go lines to the upper and lower quadrants of the temporal region of the macula. Again in Fig. 4 the intervening area of the disc is marked on the nasal side with crosses, and on the narrower

[1] "Ueber Gesichtsfeld und Faserverlauf im Optischen-leitungs Apparat," 1884.

[2] Bericht Ophth. Congress zu Heidelberg, 1884.

[3] Archiv f. Augenheilkunde, xix., 1888.

[4] Klinische und Anatomische Beiträge zur Pathologie der Gehirns, Upsala, 1890, 1892.

temporal side with dots, and the latter space denotes the region from which spring the crossing fibres to the macula. It is seen that the latter region thrusts itself between the two bundles of the direct macular fibres like a wedge. The whole macular area is represented by a sector of the papilla, embracing about 90° on its infero-temporal side; a fact established by numerous and conclusive examinations. This important point must always be borne in mind, and the area is often marked by a physiological excavation. It is also seen that the crossing fibres, which are usually heaped into an elevation on the nasal side, cover the conspicuous part of the disc. This fact explains certain appearances which occur in old cases of hemianopsia.

As we leave the eyeball, a section of the nerve just behind the entrance of the blood-vessels shows a change in the relations of the two bundles of direct fibres: they become narrower, more ribbon-shaped, and their temporal borders approach each other, and this change continues until on a section near the apex of the orbit we find an arrangement represented in Fig. 3. Now the direct fibres form a crescent on the ventro-lateral side of the nerve, and the crossing fibres fit into the figure in a gibbous area. The macular bundle marked by dots is now ovoid and nearly central. At the optic canal, Fig. 4, the nerve is flattened and the general relations of its constituent bundles are not otherwise greatly changed. Just in front of the chiasm, Fig. 5, while slight modifications are seen in the shape and position of the bundles, another feature is more noteworthy, indicated by a few lines at the bottom of the diagram running nearly horizontally across the bundle of direct fibres. They are meant to mark the fact which Henschen is the first to clearly state, that some strands of crossing fibres run across among the strands of direct fibres and loop back again to their own side of the nerve. This interlacement was seen by Michel and is thought by Henschen to explain in part his assertions of the complete decussation of the tractus in the chiasm.

Fig. 6 displays a section of the front of the chiasm. In its middle are the macular fibres for each eye, arranged in form of a baton, the direct fibres at each end, the crossing at the middle. While the direct fibres to the periphery of the retina are at each lateral edge of the chiasm, Henschen indicates that at the extreme edges a few crossing fibres intermingle with the non-crossing fibres.

Other diagrams are given to show the tractus at more caudal levels, and they represent the crossing fibres as retiring to the ventral and mesial side while the direct fibres appear upon the dorsal and lateral parts. The commissures of Gudden and Meynert form a considerable part of the tractus section. *Gudden's commissure* unites the two corpora geniculata interna and the posterior corpora quadrigemina, and it also sends a direct strand into the optic radiation of each occipital lobe. The posterior corpora quadrigemina are closely united by crossing fibres with one another, and a bundle also passes into the lemniscus (fillet); Gudden's commissure seems by its terminations to stand in intimate relations with hearing and perhaps even to be an auditory chiasm. It remains intact when both eyes are destroyed, and further confirmation of this view is found in the preservation of the internal corpora geniculata when the cortical auditory centres in the temporal lobes are extirpated (Knies, l. c.).

We have little knowledge of the function of *Meynert's commissure;* it is lost in the crus and seems also to pass into the ganglion of Luys, beneath the thalamus.

Digitized by the College of Optometry

Diseases of the Optic Nerve.

We are compelled to take account, not only of the head of the nerve, as we see it in the eye, but of its intra-orbital and intra-cranial portions and of its relations with the brain and the spinal cord. It has come to be recognized that a proper investigation of cerebral disease includes examination of the optic disc, and experience has shown that there may be in the latter moderate or very marked or no alterations, and that visual disturbances are sometimes in a notable degree independent of the existence of demonstrable lesions. That is to say, with notable physical alterations there may be great or no disturbances of sight, while with a nerve of normal appearance vision may be good or otherwise.

We, therefore, are obliged to test all the visual functions and also inspect the optic disc in cases of cerebral or spinal-cord lesion. As to visual functions, we have to examine direct vision, if possible by test types, and aided, if need be, by suitable glasses: also the visual field (a small perimeter which can be carried in the hand has just been introduced by Schweigger, which may be very useful in bedside investigations either in hospital or private practice (see *Arch. of Ophth.*, June 1889, p. 187), the color sense, and look for scotomata. With the ophthalmoscope we are to view the optic disc both by the direct and indirect methods, if possible.



Fig. 240.—Schweigger's Hand Perimeter.

The normal look of the optic nerve and retina as seen by the ophthalmoscope is shown in Fig. 1, Pl. III. and in Fig. 1 colored Plate. The great variety of the physiological appearances of the optic nerve has been referred to on pages 46 and 114; much more might be said, but completeness would prove both exhausting and unpractical.

Before entering upon the consideration of diseases of the optic nerve, it seems necessary to refer briefly to selected portions of the anatomy and physiology of the brain, in view of the fact that questions of cerebral lesion and localization are often thrust upon us What was deemed necessary in the case of the motor nerves and their cerebral origins and relations seems equally proper when we enter the brain by way of the optic nerve. The task will be made more easy by relying largely upon illustrations.

In Fig. 241 we have the cavity of the skull and the arrangement of the

Digitized by the Illinois College of Optometry

dura mater, and also the base of the brain with the arterial distribution. See also the base with the cranial nerves, p. 146.

Fig. 236, p. 642, gives the chiasm and tractus and primary ganglia. The cerebral convolutions are shown in Figs. 242 and 243.

The "localizing areas" are shown in Fig. 244, for which I am indebted to the kindness of Dr. M. A. Starr. The great motor region occupies the middle portion of the hemisphere and runs over at the upper edge upon its medial surface. The regions concerned with speech and hearing are below, for taste and smell also below and on the mesial surface and for vision posteriorly. The motor region responds likewise to nerves of sensation, and the two functions are more or less intermingled. The frontal region seems set apart for the higher mental functions. While individual areas can be mapped out with a degree of accuracy, they shade somewhat into neigh-

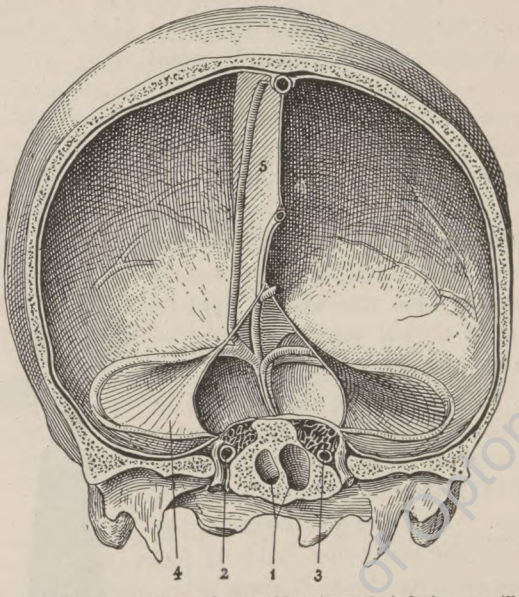

FIG. 241.—1, Sphenoid sinuses; 2, internal carotid artery; 3, inferior maxillary nerve; 4, tentorium cerebelli; 5, falx cerebri.

boring parts, and the intercommunication among separated and even distant regions is maintained in a most intimate manner by transcortical and subcortical fibres whose arrangements we know very little about. Between the frontal and parietal region at the upper part of the hemisphere is a space allotted to conjugate deviation of the eyes. This accords with both clinical and physiological experiences. Some have set apart another region about the angular gyrus for the same function, and when stimulated this area will cause such movements. But this effect is simply in accord with the fact enunciated by Knies that motor impulses to the eyes necessarily emanate from the region to which visual impressions are conveyed, and these impressions are always binocular. The visual region becomes thereby a centre for oculo-motor impulses and so-called visual memories, and hence impairment of this locality gives rise to so-called psychic blindness. That motility of the eyes is not impaired by a one-sided lesion may be explained by the continuous energy of the opposite hemisphere. It

Digitized by the College of Optometry

is, however, to be admitted that psychic blindness is a symptom which belongs peculiarly to lesions of the left angular and supra-marginal gyri and not to the right. It varies as the subject may be right or left handed, as does the motor centre for speech. Hence this region ought not to have a special designation to this effect. It is known, moreover, that conjugate

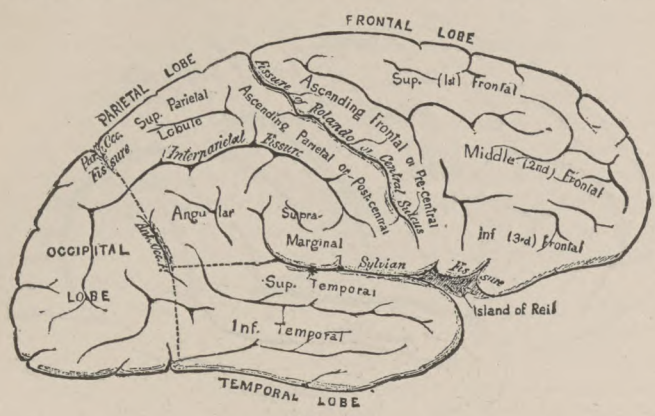

FIG. 242.

deviation from cortical lesion is not a localizing symptom (see p. 165) because it ensues after lesions in most varied situations. So far as it has localizing value it is to be traced to the anterior and upper part of the second frontal convolution, to the corresponding point in the internal capsule, or midway between them along the radiation, or to the pons, as set forth on p. 165. It is also said that stimulation of the above-named anterior cortical region causes opening of the lids, and here we find a special area for the levator

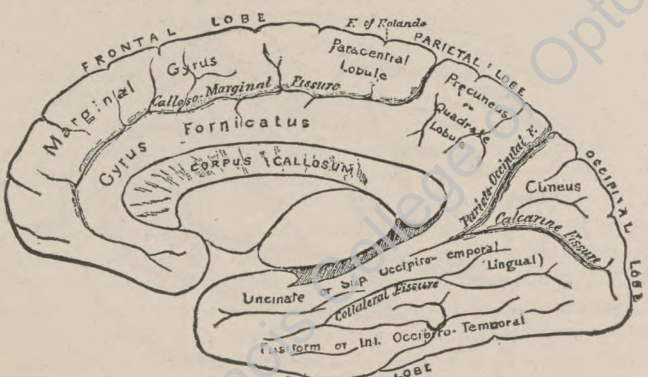

FIG. 243.

palpebræ controlling the opposite side. The reflexes which act upon the movements of the eyes come, as common experience tells us, from almost all parts of the cortex, communicate with the visual centres, and stand in most immediate relation to the nuclei of the ocular muscles. The crossing of the rootlets of the trochlearis and of the obliquus inferior gives rise to paralysis of these muscles on the side opposed to the hemispheric lesion, while all

Digitized by University of Illinois College of Optometry

other ocular muscles are affected on the same side. Another point to be noted is that at the lower part of the motor area is a separation between the regions for the lower face and for the upper face. The latter includes the orbicularis and frontal muscles, and we know clinically that one set of muscles may be paralyzed or be affected by spasm separately from the

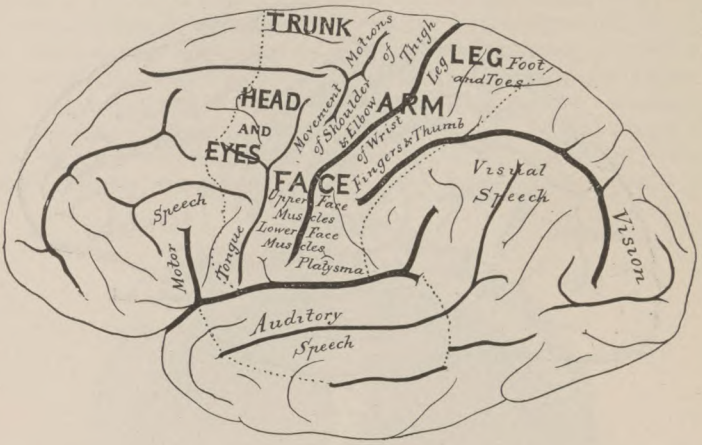

FIG. 244.

other. Again we have had to refer on a previous page (see p. 155) to the association between the facial, the abducens nucleus, and the hypoglossus in the pons. We see again how closely the lower facial and the tongue areas lie together in the cortex.

The motor speech area (Brocas) has long been recognized, but we now

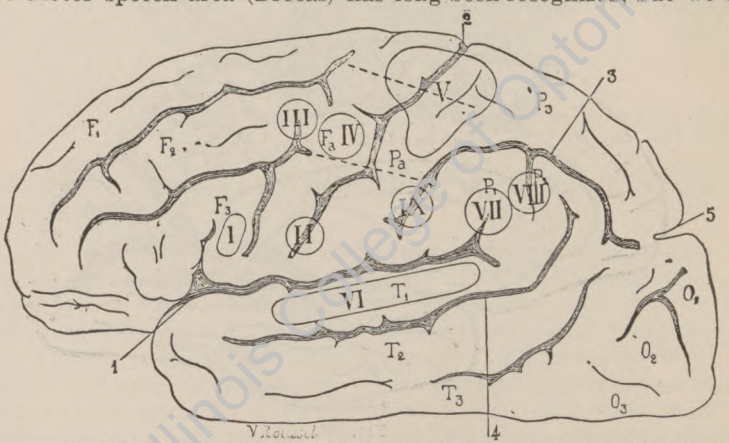

FIG. 245.—I, Motor aphasia (type of Bouillaud-Broca); II, centre for the face; III, agraphia (?); IV, arm centre; V, leg centre; VI, verbal deafness; VII, verbal (psychic) blindness; VIII, movement of the eyes; IX, Ferrier's and Walton's optic centre.

discriminate two principal kinds of aphasia, viz., motor and sensory. The former includes inability to speak, *aphemia;* inability to write, *agraphia;* loss of gesture language, *amimia.* The varieties of sensory aphasia are mind blindness, viz., *alexia* and *apraxia;* mind deafness, viz., *word deafness, music deafness,* and *paraphasia.* The affections thus designated can-

Digitized by Illinois College of Optometry

not be sharply localized because the disorders arise from disturbances both of commissural fibres and of originating centres, and the intercommunications are too complex to be fully unravelled. The lesion in aphemia (motor aphasia, as generally understood) is in the posterior part of the third left frontal convolution, or Broca's convolution; for agraphia, sometimes in the base of the second frontal convolution, Exner; sometimes in the angular gyrus, Déjérine Soc. de Biologie, Feb. 27, 1892. For gesture language there is no known centre. The lesion in word blindness (psychic blindness) is in the angular gyrus, extending forward into the supra-marginal, and backward into the occipital. The lesion in word deafness is in the posterior part of the first temporal and upper part of the second temporal convolutions. In right-handed people the lesions are always on the left side, in left-handed people on the right side. See Starr, l. c., pp. 65–73: "The various speech areas are all supplied by the middle cerebral artery, and the frequency with which an embolus lodges in this artery, instead of plugging a small branch of it, explains the frequency of mixed aphasia and the rarity of pure forms, which are due to small areas of softening."

The Corpus Striatum.—This ganglion is in close relation with the cerebellum and with nuclei in the pons. It is also in connection with fibres that come up from the muscle-sense tract in the spinal cord. Its functions are therefore probably connected with securing co-ordinate and purposeful movements. Destruction of this ganglion in the human brain, however, produces no definite symptoms and lesions in it cannot be diagnosticated. It is therefore called clinically a *latent region.*

The Thalamus Opticus.—The thalamus is in relation by its projection fibres with the frontal, parietal, occipital, and temporal cortex (see Fig. 71, p. 151). The fibres that go to the occipital cortex come from the pulvinar and have to do with vision. We are for the most part ignorant of its functions, although it has numerous masses of gray matter. A summary of various theories may be found in Berger,[1] pp. 17–19. Lesions of the posterior part of the thalamus (the pulvinar) will produce partial blindness (hemianopsia). Other than this, lesions of the optic thalamus produce no definite symptoms which enable us to make a local diagnosis.

The *internal capsule* has already been referred to (see p. 157, Fig. 76), and will again be mentioned under hemianopsia.

The Tubercula Quadrigemina.—Of these only the anterior are concerned with vision, and the injury of one causes hemianopsia. They are so close to the nuclei of the third nerve that when diseased some form of ocular paralysis is probable, while general ataxy is likely to co-exist. If to these signs hemianæsthesia or hemiplegia be added the peduncles are probably involved. The posterior quadrigemina are probably concerned with hearing and are connected by the commissure of Meynert (the optic chiasm).

The Corpora Geniculata Externa and Interna.—Only the former have relations to vision, and it is naturally very rare to find them exclusively diseased. Henschen reports two cases (l. c., p. 65). In one the external ganglion was entirely destroyed—there was homonymous hemianopsia. Secondary degeneration had reached up to the occipital lobe, and gone downward by the optic tract to both optic nerves. In both the cases the tubercula quadrigemina and the lemniscus were involved (see p. 150, Fig. 70).

The corpora geniculata interna are probably concerned with hearing, being affiliated with the posterior corpora quadrigemina. Lesions in the

[1] "Les Maladies du Yeux, dans leurs rapports avec la pathologie generale," 1892.

vicinity of the parts now referred to, bordering on the fourth and third ventricles, give rise to other symptoms such as somnolence, forced movements, loss of equilibrium, sometimes to polyuria or to glycosuria. It is common clinically to have a complexity of symptoms whose analysis may be far from easy.

"The *red nuclei* are connected with the anterior cerebellar peduncles on the one hand, and with the lenticular nucleus and optic thalamus on the other, and are concerned in securing equilibrium and the adjustment of the body in space." See Fig. 70, which shows the relations of the primary visual ganglia in the anterior part of the pons, as has already been described on p. 150, to the red nucleus and the nuclei of the third nerve, etc.

The Cerebellum.—"The cerebellum is connected with the pons, the cerebrum, and spinal cord. The vermis, or median lobe, is the part which in man is most important. Lesions of the lateral lobes or hemispheres produce few direct symptoms, and they are called latent regions. Injuries of the median lobe, however, produce disturbances in equilibrium, forced movements, and a peculiar form of inco-ordination in gait, which is known as cerebellar ataxia. Lesions of the middle peduncles produce forced movements also, the forced movements being either toward or away from the side of the lesion, according as it is an irritating one or a destructive one."[1] Tumors in the cerebellum are almost certain to be attended by optic neuritis, and the general symptoms are usually conspicuous, as will be mentioned hereafter.

Coloboma of the Sheath.—This at first sight would be thought to be only a variety of that retraction of the choroid seen most frequently in myopia, occasionally in hyperopia, and differing from it in that it occurs on the lower edge of the disc. The apparent elongation is always of moderate extent; it is not marked by pigment; the border of the nerve runs into the exposed sclera or sheath imperceptibly and has often a bluish color and seems concave. While the direction is commonly downward it may also have a trend inward. The hollow look and want of distinction between the nerve edge and the crescent, and the unusual position will indicate the diagnosis (see Figs. on Plate I., opposite p. 114).

Congenital defects of structure are sometimes observed, and without referring to all the abnormal appearances, attention may be called to signs of apparent atrophy or degeneration in loss of brightness and translucency, in a bluish look and lack of clearness of outline, possibly with or without any changes in the vessels. Sometimes with these conditions function is normal, but true atrophy is sometimes congenital and due to intra-uterine inflammation. Small cysts have been seen. Eversbursch and others have described singular malformations.

Opaque nerve fibres (see Plate III., Fig. 2, and p. 545).

Sometimes a *pigment* spot is seen on the face of the disc, and may be congenital. It is, however, very rare. It is extremely

[1] Dana, "Diseases of the Nervous System," 1893.

Digitized by the Internet Archive

common to have pigment deposit on the edge of the choroid, next the papilla, and this is not ordinarily counted pathological.

Occasionally the disc is anatomically not circular, but oblong, although this appearance is commonly the optical effect of astigmatism (see page 114).

The presence of a mesh of connective tissue on the papilla or sometimes running along the vessels, is not rare (see Fig. 246). It is white or gray, semi-transparent, envelopes the vessels at their emergence, and presents a great variety of appearances. It may

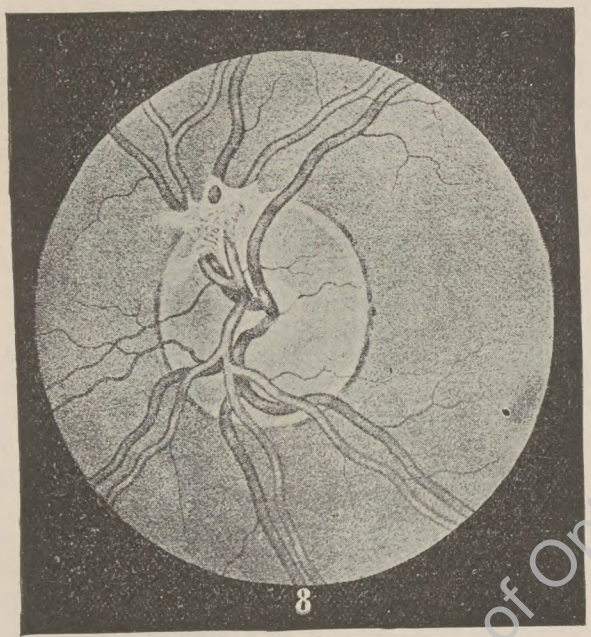

FIG. 246.

cover a large part or even the whole of the disc and may be very dense. It is distinguished from opaque nerve-fibres by the irregularity of the structure. The nerve with this exception looks normal, and no importance attaches to this peculiarity (see also Purtscher, *Graefe's Arch.*, Bd. XL.).

Sometimes the vessels emerging from the disc turn to the nasal instead of to the temporal side, and curve back to their destinations.

Hyperæmia.—Apart from inflammations, turgescence of the capillaries and of the larger vessels of the nerve is found under a great variety of conditions, and the greatest care is required to distinguish from each other the symptomatic and the idiopathic. By far the larger number of cases are symptomatic. Of these,

Digitized by Illinois College of Optometry

the majority are the effect of fatigue of the accommodation, as found in refractive errors, spasm of the ciliary muscle, or other causes of asthenopia. Another cause is cerebral hyperæmia, more particularly of the meninges. It is not to be inferred that every case of cerebral hyperæmia will reveal itself in congestion of the optic nerve, but the concomitance occurs. In apoplexy, the nerve may be deeply red, and it may be pallid; no uniform sequence can be asserted, as was once supposed. In cases of fracture of the skull (or other injuries) hyperæmia is often seen, and, in general, morbid processes at the base of the skull are apt to cause optic congestion, if not inflammation. It is not safe to argue from this symptom alone, but in a given case it will take its place among other phenomena, and often have decided value in diagnosis. With patency of the foramen ovale of the heart and general cyanosis, venous stasis in the optic nerve is also seen. In those who use alcohol to excess the nerves are red. In plethoric persons there is always fulness of the optic circulation, and the greatest scope must be allowed for anatomical and physiological varieties. Hyperæmia of the optic nerve is, therefore, of very uncertain value as a pathological symptom.

In high degrees of hypermetropia it is always present, and the nerve texture is generally streaked and marked with connective tissue. We must always distinguish between hyperæmia with and without opacity of structure. The latter may be recent or chronic, and we must also look carefully for swelling as indicative of infiltration.

Anæmia of the optic nerve may show itself as a part of general feebleness of circulation. A temporary arrest of circulation occurs in some cases at the beginning of an epileptic attack, but the contrary has also been seen. Upon an attack of syncope the nerves become pallid, as I have witnessed. In cholera, Graefe found the current of blood still in motion through the vessels, during the last stages of the disease, and remarks that the flow in the veins was intermittent or jerky. Both arteries and veins were all extremely small. Enough has been said on this point in the chapter on the retina.

Hemorrhage may take place in the head of the nerve or within its sheath. The first is easily seen and will be of variable amount. It occurs after contusions, sometimes in new-born infants after difficult or instrumental delivery, and in adults is the token of vascular degeneration in various diseases, such as albuminuria, glycosuria, pernicious anæmia, etc. It may attend papillitis in its various types, and thrombosis of the vena centralis, and embolism of the arteria centralis. If it implicate the fibres destined to the

Digitized by Illinois College of Optometry

macula, serious damage to sight occurs; otherwise vision may suffer little.

Hemorrhage into the orbital part of the optic nerve or into its sheath has been referred to on page 549.. It comes after injuries, fracture of the base of the skull, of the orbit, from diseased vessels, from pachymeningitis hemorrhagica. The ophthalmoscopic signs have been already dwelt upon *l. c.* More may be learned about it by referring to Magnus, "Die Sehnerven Blutungen," Leipzig, 1874, in which are related three cases with

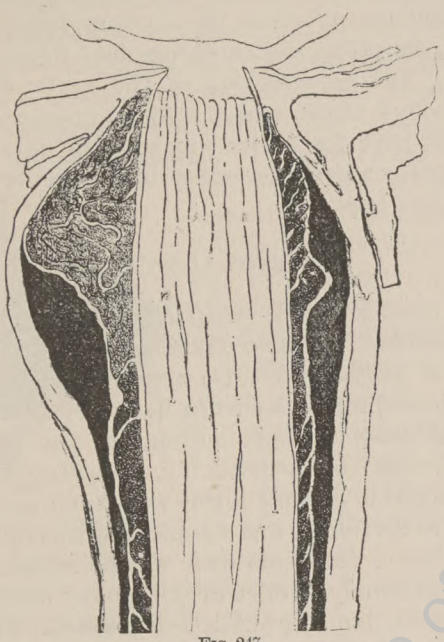

FIG. 247.

two colored ophthalmoscopic plates. The symptoms have the characters both of embolism and of perineuritis. The result in these cases depends on the extent of the bleeding and on the complications. Recovery may take place, or atrophy destroy the sight. In Magnus's case, see p. 550, Fig. 202, the signs include gray exudation at the macula reaching to the optic disc and surrounding its whole margin, though more pronounced on the macular side—the red spot at the fovea centralis, circulation in the arteries reduced but not abolished, the nerve swollen and red, not exsanguinated, the veins small. At first peripheral vision was retained, but in five days perception of light was destroyed and the nerve finally passed into atrophy. The picture was taken six hours after the occurrence.

Digitized by Illinois College of Optometry

Priestley Smith[1] gives a diagram of the optic nerve Fig. 247 with its sheath distended by a copious hemorrhage in the subdural space. The bleeding took place into the sheath of each nerve. The man had a fall, followed ten days after by a fit, and he died on the 13th day in another fit. There was *no optic neuritis,* and at the autopsy it was found that hemorrhage had occurred in the left frontal lobe and blood had escaped from its inferior convolution and extended on the left side back to the cerebellum, both on the convexity and the base. There was ampullar enlargement of each sheath behind the eyeballs. In the diagram the blood lies external to the arachnoid sheath, while nevertheless the sub-arachnoid space is filled with clear fluid, doubtless the cerebro-spinal fluid which had been forced into it. "The examination of the nerve discs was made eighteen hours before death, and it is by no means certain that the blood had at this time forced its way into the optic nerves." The case affords a perfect demonstration of the several sheaths and the two inter-vaginal spaces.

Neuritis Optica.

Clinically we distinguish (1) *papillitis* affecting the head of the nerve, (2) *neuro-retinitis* or *neuritis descendens,* (3) *retinitis circum papillaris* or *perineuritis,* (4) *neuritis retro-bulbaris.* The first two forms, including perineuritis, have well-marked and visible features; the last often exhibits nothing to the ophthalmoscope. It is sometimes a partial neuritis, *i.e.,* affecting the axial fibres alone, and is identical in chronic forms with toxic amblyopia.

1. *Papillitis,* in its purest and simplest form, is a serous infiltration with distention of the veins over all the retina, and while the nerve is red and extremely swollen even to many dioptries, its tissue is transparent and its diameter but little increased. There is nothing more than venous and capillary stasis with their effects. But upon such a condition other inflammatory lesions may be grafted, showing gray exudations, infiltration of surrounding retina, with hemorrhages perhaps, etc. In pictures 7, 8 and 9, colored plates, are seen gradations and varieties of the inflammation, from serous œdema to deep infiltration and exudation belonging to neuro-retinitis. See also Fig. 4, Pl. III. Accepting the possibility in a certain degree of distinguishing papillitis from neuro-retinitis we cannot always make sharp distinctions and shall therefore describe the various pictures which may be observed. When both nerves are affected one usually follows the other, and the process is more intense in one than in the other.

The most simple form presents a slight swelling of the disc with

[1] Trans. Oph. Soc. United Kingdom, vol. iv., p. 273, 1884.

Digitized by the Internet Archive

no change of color, no alteration of vessels, and the only recognizable features are the low swelling and the want of transparency in the tissue. It looks pasty and the appearance may be confined to one half only. Such is the fact in a case now under notice in whom only one nerve is affected, and the cause is albuminuria from syphilis of remote origin. Here is œdema and true tissue change in a very limited region. Yet this case may possibly be a true neuritis reaching farther back.

In papillitis with dominant serous infiltration (choked disc), we have swelling measured by two, three, or even six dioptries; the mass is almost globular, and shows an extreme degree of parallax when the observer shifts his point of view from side to side, Fig. 248. The substance is bright red, the outlines are almost or quite obliterated, and fine lines radiate into the retina; the arteries seem small, and the veins are strangulated. Pulsation may exist in the veins, and possibly in the arteries. In some cases the surrounding retina is much infiltrated, and again it is not. If it be not, the border of the swollen nerve will be well marked, and its increase in size greatly emphasized.

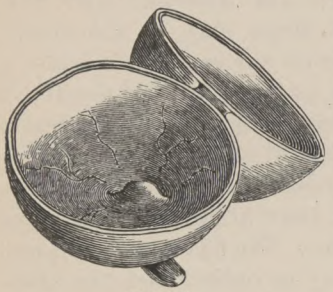

FIG. 248.

In severe cases small vessels are extremely abundant, while the circulation is evidently impeded, because they wriggle in and out in a manner which suggests the head of Medusa (see Fig. 9, Colored Plate, and Fig. 3, Pl. III.). Sometimes minute, or even considerable hemorrhages appear. Such cases have pronounced plastic infiltration often mingled with hemorrhages of the linear type. The apparent diameter of the disc is much enlarged and it is opaque, while translucency characterizes the simple choked disc. Both varieties present great prominence of the papilla, and as a rough measure of the degree it may be assumed that 1 D = 0.3 mm.

There may be acute papillitis with great exudation, and a patch of yellow exudation at the macular region, resembling what is seen in embolism, even to the bright red fovea and hemorrhages. There may also be opacities in the vitreous. I have seen such a case which was monocular. This type approximates neuritis descendens. While the intraocular end of the nerve is the focus of lesion, a moderate amount is found in the orbital portion, and if the condition be critically studied the deep-lying parts of the nerve will not be found to have escaped as much as was formerly thought. This will be referred to under pathogenesis. In the great majority of instances both optic nerves are inflamed, and this is almost the rule where intracranial affections are the cause.

Digitized by Illinois College of Optometry

But cases of one-sided neuritis occur in which the symptoms clearly indicate intracranial lesions. Such cases are noted by Magnus, Pagenstecher, Fieuzal, etc. I have had such cases under observation. We also have cases of cerebral tumor recorded, in which only one optic nerve was affected, viz., one by Reich[1] (details not given), two by Hughlings Jackson,[2] one by Pooley,[3] one by Parinaud,[4] and one by Bouchut,[5] also by Gowers and by a few others. The tumor is usually on the side opposite to the papillitis. But for monocular neuritis optica we are usually to seek the cause in the orbit, or at least below the optic chiasm. It is common in such instances to have other nerves involved. I have seen the third and fourth combined with the optic, and the lesion was doubtless at the sphenoidal fissure. I have also seen neuritis optica associated with paresis of the rectus internus muscle, and the attendant exophthalmus and pain indicated the situation of the disease to be in the orbit. On monocular papillitis, see Burnett and Oliver, *Am. Journal Med. Sci.*, Jan., 1884, p. 138. In acute otitis media there may be monocular papillitis and on the same side. In severe ear cases this lesion is not very rare, especially with meningitis, as is set forth in the above paper. Both abducentes may be involved, which implies a lesion near the pons, and there may also be cerebral hemianopsia.

2. *Neuro-retinitis*, or *neuritis descendens*. The ophthalmoscopic appearance is usually less striking than in pure papillitis, yet it resembles or merges into it in many cases. We have, however, less swelling of the nerve, its borders are hazy or obliterated, the veins tortuous and large, the arteries perhaps small. Some cases show little swelling (Fig. 7, Colored Plate), the nerve will be deeply red, while its texture will no longer be transparent, its edges will have a corona of fine lines, and the arteries and veins be turgid. There may in this and other cases be infiltration along the retinal vessels. If the nerves have a physiological excavation, this may be recognized; but it is not likely that the lamina cribrosa can be seen, because of the infiltration. (For the opaque lines along the vessels, see Colored Plate, Figs. 9 and 2.)

Again, more extensive changes can arise in which both optic nerves and retinæ participate, and are swollen, infiltrated, and hyperæmic, while white or buff-colored specks or patches appear in the retina, both in the neighborhood of the optic nerve and of the yellow spot. They may be clustered in radiating streaks, in the latter locality, precisely as are found in albuminuric retinitis.

[1] Klin. Monatsblätter (Zehender), vol. xii.
[2] Ophth. Hosp. Reports, vii.
[3] Arch. für Oph. und Otol., Bd. vi., p. 27.
[4] Annales d'Oculistique, lxxxii., 19, 1879.
[5] Bouchut: "Ophthalmoscopie Médicale," p. 144.

Digitized by Illinois College of Optometry

Digitized by Illinois College of Optometry

EXPLANATION OF PLATE III.

FIG. 1.—Normal fundus.

FIG. 2.—Opaque optic nerve fibres.

FIG. 3.—Neuritis optica with apoplexies of the nerve and retina.

FIG. 4.—Choked disc. Neuro-retinitis.

FIG. 5.—Sub-retinal effusion.

FIG. 6.—Sub-retinal effusion with partial absorption of fluid and laceration of the retina, *vide* p. 630.

Digitized by Illinois College of Optometry

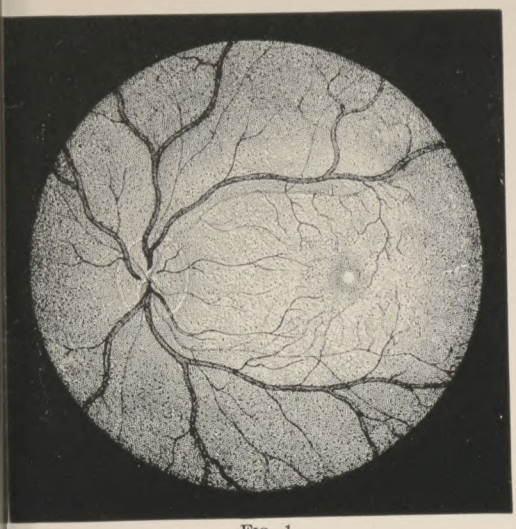

FIG. 1.

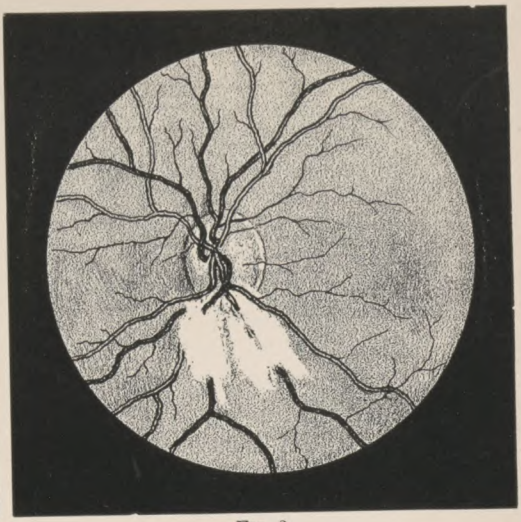

FIG. 2.

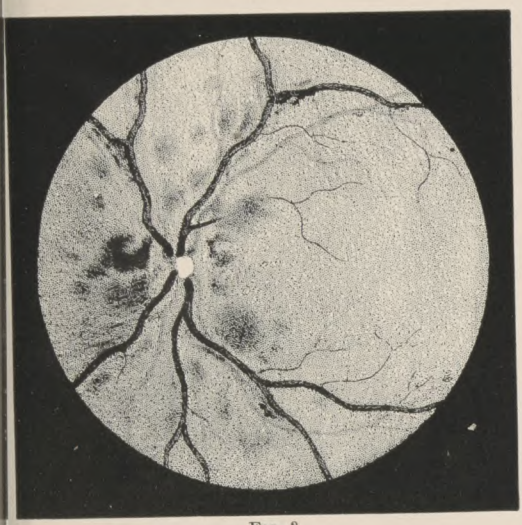

FIG. 3.

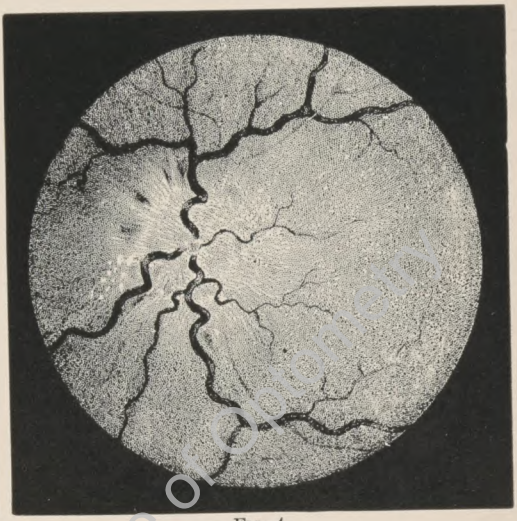

FIG. 4.

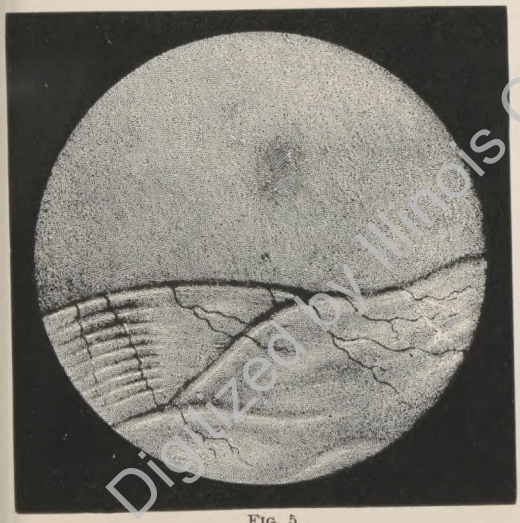

FIG. 5.

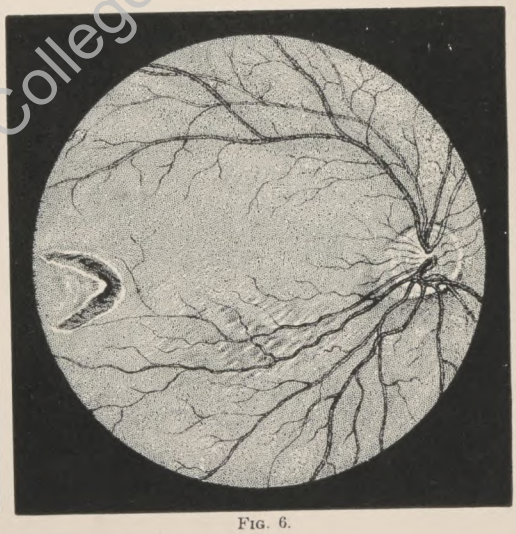

FIG. 6.

Digitized by Illinois College of Optometry

Digitized by Illinois College of Optometry

This is not a frequent occurrence, but one notable case of such neuro-retinitis with brain tumor, simulating in the closest way the retinitis of albuminuria is on record by Schmidt, but it is very rare (*Archiv für Ophth.*, XV., iii., 253). Some cases have fallen under my notice.

Neuritis hemorrhagica or *apoplectica* exhibits features identical with those found in the similar affection of the retina. Such a case which is monocular is now under observation. The loss of sight, which was rather sudden in its beginning, has existed three weeks; V in right $\frac{20}{30}$ in left $\frac{20}{70}$. In the latter, one is struck by the extreme redness and swelling of the nerve. The papilla measures between 3 and 4 D, is bloody red with hemorrhage and hyperæmia and œdema; the arteries are reduced, the veins very large and turgid and tortuous. The diameter of the disc is enlarged and its border rather sharply marked. In the retina very near the nerve on the nasal side are white exudation patches and hemorrhages. The region of the macula and the rest of the fundus are normal. Manifestly a phlebitis with thrombosis has happened in the nerve near the globe and the papilla shows the natural effects in the obstructed circulation and œdema. The lesion is extending to the retina and presents features resembling Fig. 3, Colored Plate.

3. *Peri-neuritis* was first named by Galezowski and has since been depicted by Iwanoff and Wernicke (retinitis circumpapillaris). It presents a moderate swelling of the periphery of the disc with a depressed centre, the redness may be either marginal or general, and the surrounding retina exhibit striation and perhaps grayish infiltration. It is only a variety of the affection already described and has been shown to be propagated by meningitis. Vossius has seen it after traumatic orbital phlegmon. Alt observed it after meningitis, and the cavity of the nerve sheath was obliterated by exudation of fibrin and round cells. It is only needful to state its clinical features and cause. It has occasionally come under my notice. We shall refer to *retro-bulbar neuritis* in a subsequent section.

When the acute process abates, other features come out. Some portion of the nerve may have a gray opacity, from formation of connective tissue, and another part be red. The cases of most acute infiltration may by slow gradations pass into gray or buff, into a bluish or white color, and the result be connective-tissue development and atrophy of nerve structure. On the other hand, the nerve disc may regain transparency and its normal hue.

The length of time required for the culmination of acute neuritis and for its entire retrogression, is impossible to be determined. It has been seen to come on within a few days, and even in a single night (Gruening), while its disappearance is always slow. Months

Digitized by Illinois College of Optometry

may usually be counted on, and Matthewson (Trans. Fifth Internat. Oph. Congress, p. 63, 1876) reports a case of choked discs in which the optic nerves remained *in statu quo* for three years. As above stated, the termination may occasionally be in complete recovery, or in partial or total atrophy of the nerve-fibres. A state of swelling, with a white and apparently flocculent texture, sometimes remains a long time, and this has suggested the term "woolly" (Hulke) (Fig. 8, Colored Plate). Gradually the swelling subsides, and may eventuate in concavity. The borders for some time remain fuzzy and obscure, but at length the choroidal margin comes out black and distinct. White lines bordering the vessels continue for a period, and at length may disappear. If a case be noted for a sufficient time, the atrophic appearances ultimately succeeding severe optic neuritis will in no wise differ from those which are seen in cases of primary atrophy of the nerve. It has been thought that a distinction could be made in this regard, but if sufficient time be allowed, both processes will bring about the same ophthalmoscopic picture. During a considerable period of time we may with some confidence say that the atrophy in progress has been preceded by inflammatory exudation.

A singular and rare accompaniment of optic neuritis has been noted by Nettleship, Leber, Priestley Smith,[1] and others, viz., a persistent dropping of fluid from the nostrils. The subject is discussed by Berger and Tyrman,[2] and in some of the cases quoted there were polypi in the nostrils, in some there was anosmia, and in some evident brain complications. The origin of the fluid has been ascribed to hydrocephalus internus, and also to escape from lymph vessels coming out through the lamina cribrosa. One case of this type was verbally reported by Dr. C. S. Bull at the New York Ophthalmological Society.

Subjective Symptoms of Neuritis.—There are no external signs, usually not even in the pupil. There is no pain, except in case of orbital affections—when there may be tenderness on pressure and possibly swelling of the lids or proptosis. The central vision, as has been said, may be normal in œdematous papillitis and so remain for months, but it at length fails, while in other and acute cases it is reduced from the outset and continues to fail. Should it be lost, the pupil will be enlarged and fixed. The more chronic the course, the less will be the degree of visual change and slower its decline. The visual field may undergo manifold modifications. Sometimes it will be normal, again there will be moder-

[1] Ophthalmic Review, 1884, Jan.

[2] "Die Krankheiten der Keilbein-Höhle und des Siebbein-Labarynthes," Wiesbaden, 1886, p. 41.

Digitized by the College of Physicians

ate peripheral contraction: there may be sector-like defects in great variety or even hemianopsia either vertical or horizontal. Color perception may be intact, but will suffer in the ratio of central amblyopia, and is often a valuable index of the progress of the lesion and of the prognosis. There may be a central scotoma for color, and peripheral perception be good. Color sense may be wholly wanting or the failure may occur in the usual order of first green then red and then blue. If the visual field steadily contract and the color sense correspondingly fade, we may look for atrophy and loss of sight; on the other hand, normal peripheral color sense in the return of the red, then green, and finally disappearance of central color scotoma, may be the course of the recovery, and meanwhile the visual field enlarges.

Ulrich asserts that papillitis does not greatly threaten vision in itself, but that the danger arises from consecutive atrophy, or from concomitant pathological processes in deeper parts of the nerve, because the lesion sometimes mounts upward. If an atrophic state ensues, vision of course suffers. Syphilitic processes not infrequently end in atrophy of the nerve because of degenerative changes in the blood-vessels which damage its nutrition, and the same remark applies to syphilitic cerebral lesions.

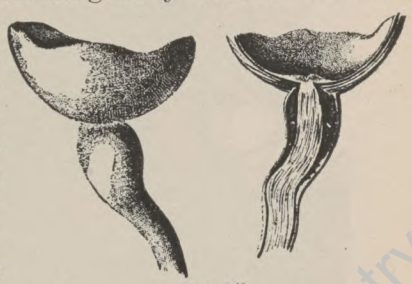

FIG. 249.

The anatomical characteristics of neuritis optica are serous and plastic infiltration, new vessels, hemorrhages, multiplication of nuclei, thickening of the vessels, and especially swelling and varicosity of the nerve fibres, sometimes deposits of granular masses in the granule layers of the retina. At a later time we have connective-tissue formation in the nerve and along the vessels with disappearance of optic nerve-fibre structure. A notable circumstance which has excited great attention is distention of the optic sheath in an ampulla close up to the globe. This has been much dwelt upon in attempting to account for the occurrence of papillitis. See Fig. 249, taken from Pagenstecher and Genth, "Atlas der pathologischen Anatomie des Augapfels," Plate XXXI., Fig. 1, and Fig. 133, De Schweinitz, "Diseases of the Eye," 1892.

But there is little doubt that this does not result from fluid flowing down the dural space, but is rather the consequence of the papillitis *in loco*. Gowers says, l. c., p. 172, "The cause of the strangulation is the compression of the veins by the inflammatory products within the swollen papilla, and not, as once thought, their compression within or behind it by distention of the sheath." This

distention is by no means always present, at least in noteworthy degree, yet in certain cases, as in Priestley Smith's case of hemorrhage, see page 661, the fluid does travel down the dural or arachnoid space, but there is not such uniformity in the event as to give certainty to the "transport theory."

Besides the above-mentioned pathological changes, the head of the nerve may contain colloid bodies, see Fig. 250 (Pagenstecher and Genth, Plate XXXII, Fig. 8), and these are displayed in a great

FIG. 250.

mass in the Colored Plate, Fig. 13, as seen by the ophthalmoscope.

Interstitial neuritis, which is by far the most frequent, and may be primary, or succeed the œdematous condition just described, exhibits enormous cell-infiltration and increase of connective tissue, affecting both the neuroglia of the nerve-fibres and their intervening trabeculæ. Round cells surround the fibres and the blood-vessels, and the latter are often greatly increased in numbers and cause extreme swelling of the papilla. As the round cells subsequently develop into connective tissue, which undergoes shrinking, the blood-vessels and nerve fibres in turn diminish or disappear,

Digitized by Illinois College of Optometry

and atrophy ensues. According to Alt, two kinds of atrophy occur. In one of them the nerve fibres become simply thinner, and we find lying between them fatty cells, probably neuroglia-cells undergoing regressive metamorphosis. In the other form, the nervous element is represented by a grumous substance, formed of molecular fat-drops, that is detritus. This change may involve much or little of the nerve structure, and it may at any stage become stationary, or be continuously progressive.

The optic layer in the retina also becomes thin, while perivasculitis and interstitial retinitis are observed. The sheaths of the nerve may be inflamed and hypertrophied.

The changes which occur in serous infiltration of the nerve are well shown in Fig. 250, in which, besides the œdema, the retina

Fig. 251.

is seen to be crowded away from the papilla, and as a rather rare condition colloid bodies are scattered through the papilla. Probably this condition is not so rare as has been thought (see Colored Plate, Fig. 13).

Again in Fig. 251 the swelling of the nerve by infiltration and the proliferation of nuclei is well displayed. In Fig. 252 the separation of the sheaths from each other is well shown and the nuclei are seen most thickly clustered together at the periphery and about the central vessels. The inter-fascicular septa are strongly accentuated.

Digitized by the University of Illinois College of Medicine Department of Ophthalmology

Etiology of Papillitis and of Neuritis Optica.—The attempt to sever these affections from each other in their etiological relations has little more success than the attempt to divide them in their essential pathological significance.

It is probably true that papillitis more frequently signifies intracranial or cerebral disease than does neuro-retinitis—yet each may result from similar causes. If the theory of increased cranial pressure be given up, as for the most part it is as the explanation

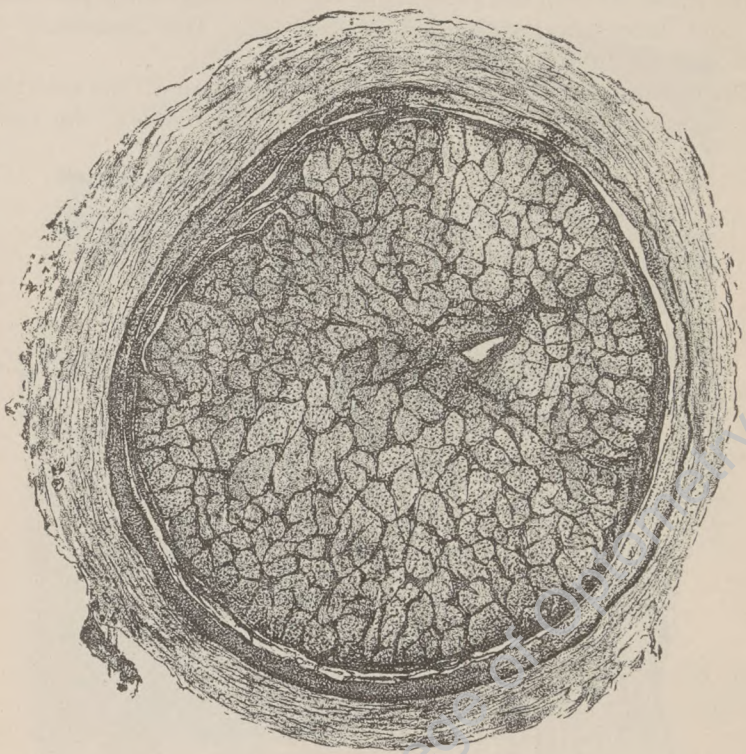

FIG. 252.

of papillitis, we only have remaining the difference of intensity in the inflammatory action, to mark the distinction between the two affections. Each comes from local and constitutional causes. If monolateral, papillitis has usually a local etiology in the orbit or erysipelas, etc. If bilateral, in the great majority of cases we have disease of the brain as the cause, and most *frequently tumors*, perhaps next in frequency will be injuries of the skull, then inflammation of the meninges, either simple or tubercular. Among tumors are included neoplasms and cysts and tubercular deposits, etc. Sometimes clots have this effect, but papillitis is seldom seen with apoplexy unless a hemorrhage breaks through to the base of the

Digitized by Illinois College of Optometry

skull. It is also infrequent with hydrocephalus, either external or internal (atrophy is more common). It occurs with acute otitis media, as has been said, and is then apt to be monocular and to imply meningeal complication. As respects tumors, neither their character nor location nor size seem to be important. Yet their location in the cerebellum is of all places most likely to produce the lesion, and the tumor need not be bigger than a cherry. Annuske,[1] Reich,[2] and Edmunds and Lawford[3] in long tables give abundant proof of this statement.[4] Papillitis is not a localizing symptom in brain disease.

Papillitis often comes late in the progress of cerebral tumors. Jackson gives an autopsy where symptoms of tumor existed nine years, while papillitis appeared only six weeks before death. It may arise very suddenly. It may appear and complete its course before death occurs. On the other hand, it has been known to last three years (Mathewson).

Reich, in forty-five cases of tumor with autopsy, found only three where no papillitis occurred. The statistics of Bernhardt[5] are misleading in taking 22% as the known frequency of choked discs in cerebral tumors; because, as he says, in 47% of the cases he discusses nothing was said in the histories about the matter. He does, however, show by his tables that in 45% of cases of choked disc vision remained intact. The real proportion of choked disc in brain tumors is undoubtedly approximated in the tables of Edmunds and Lawford, l. c., who, out of 107 autopsies, give a record of choked disc in 77 cases, or 66%. Jackson has seen it in atrophy of the brain. In a case of general hardening of the brain with large distention of the ventricles by fluid, which I saw from the beginning, there were only signs of atrophy of the nerve. Abscess of the brain may cause papillitis, while abscess of the cerebellum seldom does. Tubercular meningitis causes optic nerve lesion in 80% of the cases, including hyperæmia and effusion, but positive swelling occurs much less frequently—in twenty-four autopsies it was found fourteen times (Garlick[6]). See "Papillitis," by C. S. Bull, *N. Y. Med. Jour.*, Feb. 21, 1891; and Morrow, Trans. Oph. Section Am. Med. Assoc., 1893.

The attempt to set apart the etiology of neuro-retinitis or retinitis descendens, from that of papillitis can have only partial success. The former may occur with tumors, but with less frequency than the latter. It comes from causes local in the orbit, as erysipelas, injuries, periostitis; sometimes from orbital tumors, etc. Also from empyema of the frontal sinus and from caries of

[1] Graefe's Archiv, v. xix., iii., 165–300. [2] Klin. Monatsblätter, v. xii.

[3] Trans. Oph. Soc. Unit. Kingdom, v. iv., p. 172, 1884.

[4] See case of tumor of thalamus without neuritis, by Edes, with literature, N. Y. Med. Record, May 24, 1890.

[5] "Hirngeschwülste," 1881, p. 23. [6] Med. Chirurg. Trans., lxii., 447, 1879.

Digitized by the Internet Archive in 2007

the teeth (Vossius). Very often it comes from meningitis, simple and tubercular; from congenital malformations of the skull; from tumors in the substance or at the base of the brain.

We likewise have it not seldom as a purely local and limited affection, an idiopathic neuritis which has no remote connections, just as any other nerve may be thus impaired. In theoretical statements too little stress has been laid upon this kind of idiopathic affection. See Hirschberg: *Centralblatt für Prak. Augenheil.*, Nov., 1887, *Ophth. Review*, Jan., 1888.

As to constitutional causes, we have syphilis of the brain (gummata) or of the meninges or of the nerve, and cerebro-spinal meningitis. It comes from toxic agents, such as lead, albuminuria, glycosuria. It follows typhus and typhoid and intermittent fevers, pneumonia, measles, scarlatina, acute otitis media. About 6% of cases of multiple sclerosis exhibit it (Herter). It is not rare, especially among youths of both sexes, from anæmia; in females from chlorosis, menstrual disorders and uterine disease (Mooren). It is a common consequence of severe hemorrhages. It happens at all ages; it may be congenital, and hereditary. Sunstroke has been followed by neuro-retinitis (Holtz), and its occurrence in sympathetic ophthalmia has been dwelt upon (see p. 491).

Acute myelitis has, within a few years, been found to be accompanied by optic neuritis. The first case was published by Steffan and Erb, another by Dr. Seguin, of this city, and I have joined Dr. Seguin in contributing another.[1] Dr. Chisholm has another. The symptoms are those of acute, but moderate, neuritis optica, with remarkable impairment of the visual field and of central vision. There may be entire loss of direct sight; there may be any kind of irregularity in the fields, including total abolition on both sides or affection of one only; there may be repeated recoveries of sight and relapses. The singular peculiarity of the cases has been that vision, both direct and indirect, should undergo such great and unexpected variations. The lesion of the cord was in its lower and middle portions, as was fully manifested by symptoms of the bladder and the lower limbs. No explanation of the optic neuritis has been offered, although we may bear in mind that a root of the tractus has been traced by Stilling through the crus cerebri along the fillet to the posterior columns of the cord (see p. 591). The agency of the sympathetic nerve has been invoked to explain the optic neuritis, but this is nothing better than surmise. All the cases have gotten well, both in respect to sight and to the functions of the cord. In my own case, large doses of iodide of potassium were employed, gradually reaching three hundred grains daily,

[1] Am. Journ. Med. Sci., July, 1879, 105.

Digitized by the Internet Archive

and were well borne. The case occupied about four months in its evolution.

NOTE.—A case of double optic neuritis following myelitis is reported in *Annales d'Oculistique*, tome cii., Jul., Août, Sept., 1889, p. 123, Proceedings of Soc. Fran. d'Ophth. A man aged 30 is seized with headache and double amblyopia. He has double optic neuritis. Very soon general neuralgia, various paralyses, all the symptoms of myelitis ensue, and death occurs in three months. At the autopsy are found plaques of sclerosis in the cord; the optic chiasm reduced in size. Microscopically an interstitial inflammation was found in the left tractus opticus, reaching the chiasm and propagated along both optic nerves. Very remarkably, only the axial fibres of each nerve were affected, leaving intact the peripheral fibres and the sheath, and the whole process came to a stop at the middle of the orbital portion of the nerves. Then another focus of inflammation appeared immediately behind the lamina cribrosa, and produced the ophthalmoscopic appearances. There were signs of perivasculitis abundantly. The disease was considered to be syphilitic. The limitation to the axial fibres and the interrupted course is very noteworthy, and the association with myelitis was demonstrated.

Pathogenesis.—When produced by orbital disease it is easy to understand how inflammation of the trunk of the nerve causes swelling of the disc, because at this point the vascularity is greatest, expansion can occur only inward, because the lamina cribrosa behind and the sclera on each side may be said to imprison it; moreover, the absence of neurilemma predisposes the fibres to expansion by imbibition. The peculiar bulging of the sheath just behind the globe was noticed by Stellwag in 1856. When Schwalbe (1869) showed that the cavity of the sheath was a prolongation of the arachnoid cavity of the brain, Schmidt-Rimpler, Manz and others, assumed that the fluid came down from the brain and caused the papillitis. Leber, Trans. London Ophthalmolog. Congress, held this view in a modified form in 1881. To the naked eye the optic nerve shows no sign of inflammation behind the lamina cribrosa. Kuhnt[1] seemed to give evidence that the effusion in the sheath caused degeneration of the fibres of the papilla. The question arose whether the papillitis causes the effusion in the sheath, or the effusion causes the papillitis. Alt gives a case of peri-neuritis following meningitis, with obliteration of the cavity of the sheath. Oeller[2] also gives a case of papillitis and other lesions following cerebro-spinal meningitis without any changes in the sheath.

But other theories have been advocated and much discussion arisen on this subject; the vaso-motor nerves (Benedict, Hughlings-Jackson), and the trigeminal nerve (Loring); œdema of the brain extending through the nerve (Parinaud); meningitis at the base of the brain (Edmunds), etc., have been invoked. Careful study of the trunk of the nerve by the microscope has shown that notwith-

[1] Graefe's Archiv, xxv., iii., 256. [2] Jahresbericht für 1879, p. 443.

Digitized by Google

standing its frequently apparent normal look it is the seat of a low grade of inflammation, which penetrates it by the pial sheath and the entering trabeculæ, and thus reaches the interstitial connective tissue, and also follows down the nutrient blood-vessels. The interspaces are expanded by serum (Edmunds, Poncet), and nuclei are abundant. Edmunds found at the periphery of the nerve the most abundant infiltration (see Fig. 223). The name choked disc comes from the theory of mechanical engorgement first propounded by Graefe, which attributed the cause to interference with return circulation at the cavernous sinus; still another theory of a similar kind regards increase of pressure within the skull as the causative agent. This doubtless has a degree of value, but not great, as proved by the cases of hydrocephalus internus. It seems probable that more than one factor enters into the result, but the most potent cause is now held to be a low grade of neuritis proceeding down the nerve, or following along the sheath. Mechanical hindrance at the ocular end of nerve, by compression of the retinal vessels, aggravates the swelling of the papilla. To quote Gowers, "distention of the sheath of the nerve alone is probably insufficient to cause papillitis, but may, perhaps, intensify the process otherwise set up, leading to retention or augmentation of fluid in the lymphatic spaces in the nerve-fluid which may in some cases possess an irritative quality."

It was Leber who in 1881 originated the idea that fluid coming down the sheath by its chemically irritating properties provokes papillitis. Deutschmann, pursuing the suggestion (1887), experimented with fluids charged with microbes (bacillus tuberculosis) which he injected into the cranial cavity of rabbits, and produced papillitis and vaginal distention. By simple distention of the sheath with unirritating fluid no result followed. He therefore believes irritating properties to be essential to the material which is conveyed to the papilla. He expressly disclaims any difference between papillitis and neuritis descendens, except in degree, and declares that intracranial pressure is inoperative, except as it favors the penetration of pathogenic material into the sheath. Dropsy of the sheath is not necessary to papillitis, but may be wholly absent.

Parinaud, *Annales d'Oculistique*, p. 26, 1879, assumed that there is œdema of the brain and hence of the nerve and its lymphatics. He recognized the low grade of optic neuritis present with papillitis which other observers failed to see. His view may be too sweeping as to œdema of the brain, and we perhaps cannot fully account for the process by the method of Leber, nor does the suggestion of Parinaud tell us how the inflammation of the nerve arises, but the facts which he was the first to detect in the nerve are confirmed by

Digitized by the Internet Archive

Picquè,[1] and with these we may at present rest, having at least gotten rid of some untenable and disproven theories. He finds that in the great majority of cases the inflammation is propagated by continuity of tissue along the meninges to the papilla; it enters the nerve, and may be very slight or more pronounced, whatever may be the originating cause of the process. He thinks the papillary œdema or stasis results from the concomitant meningitis and neuritis. Accepting in some degree the views of Deutschmann and Leber, he finds the intervention of germs unnecessary.

Diagnosis.—What has been said is enough to establish the existence of papillitis, but we are also called upon to make the diagnosis of the cause and relations of the morbid condition of the nerve. We may in some instances assume a purely local lesion with no remote causation, but we often have to wrestle with the problem of the originating lesion of the brain, its nature, and its seat. We have first general symptoms of brain disease, and we also have focal symptoms. The former are called distant, the latter localizing symptoms. The distant or general symptoms are due either to brain irritation or to brain compression, or to both combined. They cannot always be separated, but those of irritation are usually associated with hyperæmia and consist of headache, vertigo, vomiting, photophobia, mental irritability, insomnia, peculiar feelings of fulness and pressure about the head, noises in the ears or in the head, tenderness about the scalp, and, in severe cases, convulsive symptoms and delirium.

The symptoms of brain compression are headache, vomiting, mental hebetude, or dulness, perhaps some form of paralysis, contracted pupils, and eventually coma. With these there is often constipation and retracted abdomen. Pressure symptoms may be associated with anæmia or œdema, and often in states of malnutrition where the brain is impoverished the symptoms much resemble those of compression (Dana). For local diagnosis we are guided by the focal symptoms, viz., those characteristic disturbances, either paralysis, convulsions, or perversions of sensation belonging to the portion of the brain affected. It is in this inquiry that adequate knowledge of cerebral anatomy and function is essential. At the same time our knowledge is incomplete, and we cannot always reach a correct conclusion. For example, it is held that headache, vertigo, vomiting, staggering gait, and optic neuritis are positive symptoms of tumor of the cerebellum, the staggering being especially significant of disease of its middle lobe. In Henschen (l. c., Taf. XIX.) is a plate of a tumor of the tuber cinereum beneath the optic chiasm, and another from the mid-cerebellum

[1] Archiv d'Ophthalmol., Sept., 1888.

Digitized by Boston Medical Library

resting upon the fourth ventricle which were not diagnosticated during life other than as a tumor cerebri. Symptoms were not sufficiently marked to make localization certain, although the patient was in hospital twelve days before death and capable of answers for ten days. There was optic neuritis.

Another item in diagnosis is as to the nature of the pathological process, whether hemorrhage, tumor, abscess, meningitis, softentening, embolism, etc. On all these points reference must be made to treatises on diseases of the brain, such as Starr, Dana, Gowers, etc.

Prognosis will be extremely various. It will depend mainly on the cause and the severity of the lesion. The first consideration is to determine if possible whether some grave disorder, general or cerebral, is to be dealt with. If no malady of an incurable nature has found lodgment, the eye trouble may disappear.

With a duration of amblyopia for months a partial or complete restoration is possible, and this may sometimes be true with total amaurosis. The underlying cause is the great factor. Better than by objective appearances we must be guided by the visual and color sense as to the true progress of the neuritis.

Reference to the special causes of the disease may more satisfactorily set forth the probabilities of a case in hand. Meningitis may cause neuritis of one or both sides. In acute tubercular meningitis, visual damage will depend on the acuteness of the process (see Fig. 15, Colored Plate), and, as depicted, it may be attended with choroidal tubercles. There may be great obtundity of intellect and attendant visual depreciation. Cerebro-spinal meningitis may cause optic neuritis and useful vision may, as I have seen, remain in one eye despite obvious atrophy. With chronic meningitis it is more usual for blindness to ensue, yet restoration of sight is possible both in children and in adults. Even if notable atrophy occur in the nerves, vision may remain good enough for ordinary purposes and endure, as I have seen, for fifteen years.

Neuritis after orbital affections, including the cellulitis from erysipelas, may have a rapid onset, with great or total loss of sight, and end in either recovery or blindness, the latter by atrophy, and be either partial or total.

Syphilitic neuritis may proceed from the nerve trunk, the meninges, or the brain, and in the last case by formation of gummata. One or both eyes may suffer and either together or in succession. Thickening of the walls of the vessels is often seen. Very rarely the signs presented are the same as in albuminuric retinitis, even to perfect representation of the stellate bright deposits at the macula and hemorrhages. Hemorrhages about the veins are not rare. Brain syphilis often gives rise to the "woolly disc," with

Digitized by Illinois College of Optometry

swelling and plastic infiltration without much redness, although the contrary and usual features are seen.

Neuritis from anæmia, chlorosis, loss of blood, or menstrual disorders is usually of a low grade with little exudation, but I have seen choroidal lesions also about the macula. The course of the malady is prolonged. Recovery may not come for a year. Prognosis is relatively good.

As to albuminuric and glycosuric neuritis enough has been said in a previous chapter.

Treatment.—We are guided by the nature of the malady and by the cause. If there be a tumor or acute tubercular meningitis we can do little. Local measures are most effective when the cause is basal or orbital, then dry or wet cups to the neck or temple, sometimes the seton, the milder irritants, as mustard and turpentine stupes, hot foot baths, occasional use of leeches if strength permit, and moderate purgatives will suggest themselves. These measures will be especially chosen if there be local pain, or tenderness on pressure or on percussion. For rheumatic or gouty cases, salicylates, alkalies, lithia waters and the recognized medicaments will have their use. Pilocarpine by injection will not be left out of view as a possible resource. In anæmic neuritis, or that which follows hemorrhage, iron will take the chief place. A long course is to be expected and with encouraging results. Blaud's pills,[1] or in scrofulous subjects Blancard's iodide of iron pills, while in anæmic subjects Flint's tablets[2] are now carrying off therapeutic honors. Among such subjects a change of formula, while adhering to the iron, is often required. Quinine, strychnine, and various tonic mixtures, not omitting oleum morrhuæ and extract of malt, with generous and especially meat and milk diet, form an essential feature of the programme.

In no cases are the results of sagacious treatment more brilliant than among the syphilitic, especially in the tertiary or gummy varieties. Here iodide of potassium, in full doses, with moderate

---

[1] Ferri sulph., potass. carb., āā gr. iiss. Dose 1 to 3 pills.

[2] ℞ Sodii chloridi, ... ʒ iij.
Potass. chloridi, ... gr. ix.
Potass. sulph., ... gr. vi.
Potass. carb., ... gr. iij.
Magnes. carb., ... gr. iij.
Sodii carb., ... gr. xxxvi.
Calc. phos. præcip., ... ʒ ss.
Calc. carb., ... gr. iij.
Ferri redacti, ... gr. xxvii.
Ferri carb., ... gr. iij.

M. In capsules No. 60.

Sig. Two capsules three times daily after eating.

Digitized by Illinois College of Optometry

amount of mercurials, is the trusty weapon. The dose of iodide will vary from gr. xxx. to ʒ i. daily. The amount must be ascertained by the exigencies of the case and the toleration of the patient. Iron will go with it in women and weakly subjects, *i.e.*, the iodide of iron often, or possibly other forms. Mercurials may be given by inunction, by the vapor bath, as the biniodide, gr. $\frac{1}{8}$ to $\frac{1}{32}$, or bichloride, gr. $\frac{1}{8}$ to $\frac{1}{32}$. A good formula for feeble subjects is Mass. hydrarg., gr. iij.; Ferri sulph. exsiccat., gr. i. Fiat pil. unam, ter in die.

In many doubtful cases we give "mixed treatment" and oftentimes hit; in fact, as in whist a player in doubt leads trumps, so in neuritis the remedies we keep in readiness for a dubious case are potassium iodide and corrosive sublimate.

As the stage of atrophy ensues we employ strychnine, phosphorus, arsenic, etc., in all cases whatever the etiology, and perhaps without letting go the remedy previously employed.

Confinement in close rooms or in bed, or the exclusion of light are not called for in most cases; on the contrary, if the situation permit, fresh air, exercise, good food, and good hygiene are powerful aids to recovery.

In cases of tumor, should there be aggravation of symptoms, increased doses of iodide may be required, and perhaps leeches to meet the presumable vascular afflux. We have to combat in these patients most severe and obstinate headache. A prescription much commended is tr. gelseminum and tr. veratrum viride, equal parts, in doses of ten drops as required. See Taylor, *Trans. Am. Ophth. Soc.*, 1891, p. 189. We may have to go through the whole list of anodynes, but naturally avoid morphia as long as possible.

4. *Retrobulbar Neuritis.*—Cases of loss of sight occur which exhibit very moderate lesions of the disc, but have features which lead to the diagnosis of inflammation of the nerve between the globe and the chiasm. It may be that only certain groups of fibres are implicated and these may be either the central (axial) or the peripheral. It follows that we have either partial or total defect of sight. In other words we can have a central scotoma either for color or absolute, or a peripheral scotoma or a limitation of field which may be either for colored or for white light.

In considering the lesions of the various portions of the nerve we have two groups of cases, one inflammatory and one toxic. The former may be chronic, subacute, or acute. The lattter is always chronic and is due in the great majority to alcohol or tobacco or both. The correlation of alcoholic or tobacco amblyopia, with the inflammatory retro-bulbar neuritis, has been justified within a few years by the investigations of Samelsohn, Vossius,

Digitized by Google

and Uhthoff, who found that in all these cases the axial fibres especially are the seat of the lesion. Graefe first suggested the explanation of the simple inflammatory type, and Leber describes it in Graefe and Saemisch, "Handbuch," vol. V., 829, grouping all the kinds together.

In the *chronic inflammatory* cases there are scarcely any other symptoms than the central, or possibly and more rarely a peripheral scotoma according to the part of the nerve attacked, with or without reduction of visual acuity according to the severity of the lesion. The disc may be red and a little hazy and the veins enlarged, or it may be normal. There will be little or no pain and it will be difficult to date the beginning of the affection. Only one eye may be affected; to find the ailment double is rare.

In *acute* cases other symptoms appear, and the loss of sight is quickly developed and may be very marked. There is pain which may be severe, usually circumorbital, perhaps reaching to the occiput; movement of the eye is uncomfortable; pressure upon the closed lid pushing the globe backward causes pain, and one eye must be compared with the other. The papilla may look quite healthy for weeks even in cases which terminate in blindness. On the other hand, it may in mild cases show slight changes and sometimes the region of the macula will be hazy. When only the central fibres of the nerve are concerned the visual defect will be at the middle of the field, and will be, as already said, either a color scotoma, viz., green appears gray, or red fails to yield its proper shade as compared with an eccentric part of the field, or an absolute scotoma.

In testing these cases the bit of colored paper must be not more than three millimetres in diameter, and while one is held in the line of direct sight, another is simultaneously held alongside of it, making an angle of 5° or 10° with the visual line. The colored paper should be on a black ground, and in good light, while a quick answer should be demanded. Visual acuity may be normal in good light, but by reduced light, or with the color types of Ole Bull, or Stilling, or by the light-sense types of Seggel, marked reduction may appear. Moreover, with common type, black on white, vision may be bad.

There will be great varieties in respect to the visual field and there may even be no perception of light. Hock[1] draws attention to cases in which he thinks the periphery of the nerve, and probably the sheath, was affected and bases his opinion upon the correspondence which he found between the position of invasion of the field, and the direction in which movement of the globe caused the greatest pain.

[1] Centralblatt für Augenheilkunde, April, Mai, 1884, p. 107.

Digitized by Illinois College of Optometry

For example, with great pain in looking upward, the upper part of the field would show defect or reduction of color sense. He explains this by the stretching of the sheath of the nerve under the movement. In his cases the upper part of the field was first attacked, central vision was gradually diminished, the lower part of the field was for long exempt and recovery took place in the reverse order.

Nettleship[1] describes a series of cases of mixed kind.

The following, from my own note-book, has typical features:

Mrs. M., thirty-four years of age, wife of a Methodist clergyman in New Jersey, came to me on December 12th, 1878. Has been married thirteen years, has one child, is in good health, except slight indigestion and occasional rheumatic pains. The last menstruation was four days too soon. In right eye V = $\frac{20}{30}$; in the left merely sees movement of the hands on the outer side of the field. Six days ago, on awaking in the morning, she found that the left eye had only ability to discern the situation of the window. By noon this had been lost for the central region, and remained only in the extreme temporal part of the field, as found on my first examination. The pupil normal, no headache and no head symptoms, but had "a feeling of deadness about the brow and the opening of the orbit." Menstruates about every three weeks, and flows copiously. By ophthalmoscope find the optic nerve injected, and a little swollen and indistinct on all sides, except on the outer part, the veins a little enlarged, the arteries rather small. All the retina rather hazy. Ophthalmoscopic lesions greatly out of proportion to the loss of visual function; patient put upon iodide potass. After a week she began to gain a little better perception—slowly, the improvement continued. She took the iodide for about four weeks, but no notes were taken until six months passed, when in right eye V = $\frac{20}{20}$, left eye V = $\frac{20}{100}$. The nerve was decidedly pale, veins large, arteries unchanged, and near the macula were many whitish dots. color-perception very deficient; leaves on the trees appear black, and the only color which she readily recognizes is yellow. In November, 1879, viz., eleven months from the beginning, find O. D. with + 48c. 90°, V = $\frac{20}{20}$; O. S. +60 c. 90°, V = $\frac{20}{30}$; visual field, O. S., normal, color-perception bad, nerve pale, the outer half most decidedly.

In the case above cited, mention is made of pallor of the disc at its outer side; this feature is sometimes but not always conspicuous in axial neuritis, whether inflammatory or toxic. It must be carefully discriminated from a physiological excavation inclining to the temporal edge. This will be easy if a normal-looking border remains at the very edge of the disc, but even this feature may be wanting without indicating pathological lesions.

It has been remarked that the field of vision shows a variety of encroachments in different classes of cases. A case is presented in which there seemed reason for the diagnosis of orbital neuritis and which presented the unusual phenomenon of ring scotoma.

Miss Mary B. B., æt. 17, living in New Jersey, came to me in April, 1886.

[1] Trans. Oph. Soc. United Kingdom, v. iv., p. 186, 1884.

Digitized by Illinois College of Optometry

She had previously had asthenopic trouble, for which had been prescribed both prismatic and spherical glasses, and tonic treatment. Her health was delicate, had had pneumonia, was thought to be disposed to tuberculosis, was very impressionable and apt to think herself seriously sick. Had been in Florida for her health and for some time prior to the above date had been quite well; had had otitis media and was slightly deaf: in both ears there is perforation of the membrana tympani, and from the right there is discharge. During the summer of 1885 both eyes and health had been good; during the winter she began to run down, and often had dizziness. Her brother, who is a physician, said that she had rheumatism of the abdominal muscles during the winter, for which she took salicylic acid. In February, 1886, sight both for distance and near began to fail. At my examination, April 13th, the ocular condition was O.D. $+\frac{1}{8}+\frac{1}{48}$ c. 90° V$=\frac{18}{60}$. O.S. $+\frac{1}{24}$ s. $+\frac{1}{48}$ c. 90° V$=\frac{18}{40}$. Ophthalmometer shows astigmatism in each eye: 1 D axis 90°—180°. In each eye has central scotoma for red, which is more decided in the right. The perimeter shows no impairment of field in the left, but in the right there is ring scotoma as shown in the chart (see Chart No. 1, p. 550), while there is no peripheral limitation. In reading the test types at six metres with her glasses, she finds with the right that alternate letters stand higher than the others, with the left, each is divided from the next by a faint line. For three weeks has had constant and severe headache—frontal, temporal and occipital—much pain in the globes. Says she sometimes gets perfect vision for a few seconds and then a cloud appears. She often sees a white line running diagonally across the page and is compelled to move the book to see the whole of a line. The line is sometimes zigzag. Sees colored spots, blue, green, and red. Sight is more dim at night. When riding on the railway or in a carriage often sees a green stripe about two feet wide by the side of the road, and it blots out of view everything which it covers.

These symptoms suggest hysterical amblyopia, but the ring scotoma was unmistakably demonstrated on several occasions. Outside of it, the test object did not wholly disappear but was very faintly seen. By the ophthalmoscope O.D., deep central excavation of the nerve, which slopes to the temporal side, its tissue clear, edge well defined, no lesion of fundus. In O. S. similar excavation and fundus normal to the periphery. Ordered potass. iodid. in small doses, but it could not be borne, and she was given Blancard's pills of ferri iodid. She went away from home on a visit. She also took cod-liver oil afterward. She was seen at intervals of about a month and her health improved. On June 8th, 1886, in O.D. V$=\frac{18}{15}$; — in O.S. V$=\frac{18}{20}$. Ring scotoma in O.D. disappeared, but central scotoma for red remains. Had an attack of dimness lasting fifteen minutes, during which could not recognize faces across the street. Both eyes, fundus normal. Vision equally good both with and without glasses. On Sept. 15th, 1886, eyes entirely normal, color scotoma disappeared. She continued well for two years, but in Jan., 1889, had slight return of asthenopic symptoms.

The case was undoubtedly in great measure hysterical, but there can be little doubt of the presence of actual lesions, and the scotoma for red points to the axial fibres of the nerves, while the ring scotoma in the right eye may denote peri-axial neuritis.

Causes of the disease in the inflammatory types are exposure to cold, rheumatism, syphilis, and the canalis opticus is doubtless in very many cases the site of the reaction. Should the sphenoidal

fissure be involved other nerves would suffer, but we do not now take them into consideration. There would be diplopia of such sort as would be proper to the affected nerves. The epidemic of 1891–92 known as *la grippe* has been held to be a cause by various writers, and with great probability. See paper by Weeks, *N. Y. Med. Journal*, Aug. 8, 1891.

Prognosis is uncertain, yet many recoveries occur—some may be complete, others partial.

Treatment will be mildly antiphlogistic and be determined by the view taken of causation. Iod. potass. will be most apt to be useful, yet other indications may call for saline diuretics, or salicylate of sodium; the Turkish bath may be useful. In anæmic cases iron, arsenic, quinine, cod-liver oil, etc., will find place. The eyes must be out of use and the general health attended to. Sometimes the artificial leech, or dry cupping, or a blister may be employed.

Toxic Retro-bulbar Neuritis, Amblyopia from Alcohol or Tobacco, Amblyopia ex abusu.—The dimness of sight caused by alcohol or tobacco has long been clinically recognized, although not until recently accurately understood. The literature is very copious and much of it is polemic. The main facts can now be stated with much assurance, since the publication of an article by Uhthoff[1] which leaves little more to be said. He examined 1,000 patients who were detained in hospital because of alcoholic excess (alcoholismus) and out of these found 6% affected with amblyopia; in 6.5% more, he found the peculiar nerve lesion without amblyopia, and in 5.3%, pathological conditions of the nerve and the adjacent retina. Added to these were some other lesions affecting the pupil, the muscles and the retina, making a total of eye diseases among 1,000 alcoholic patients of about 30%. In another category he studied 100 cases of alcoholic amblyopia, and in almost all of them the lesion had continued more than six weeks. For how long time the indulgence had continued is not stated. The ophthalmoscope found in 63% of the amblyopic cases atrophic pallor of the temporal side of the nerve, often extending below, and this lesion occurred in all the protracted ones; in 8% there was slight but distinct haziness of the nerve and the adjacent retina; in 28% there was no abnormal appearance. That the outer half of the nerve is often brighter or paler than the nasal side is perfectly true of normal eyes, but in the cases designated an opaque and emphatic whiteness reaching to the margin is to be noted, and the importance of carefully distinguishing normal from abnormal appearances is signalized by the result of autopsies. Absolute blindness very rarely takes place from alcohol alone.

[1] Graefe's Archiv, Bd. xxxii., Abth. iv., 95–188, 1886; Bd. xxxiii., Abth. i., 257–318. 1887.

Digitized by Illinois College of Optometry

The pathological lesion is atrophy succeeding to inflammation of the *axial* fibres of the nerve, and the beginning may be at any part below the chiasm, although by preference it affects the distal, that is, ocular, portion of the nerve. With deep lesions some time is required for their manifestation at the disc—hence, in many cases, no visible sign is afforded.

Other poisons cause similar lesions, and out of 204 cases of retrobulbar neuritis the following table is instructive; 138 were from toxic causes, and 66 from miscellaneous causes, some of them inflammatory:—

From abuse of alcohol	64
" alcohol and tobacco	45
" abuse of tobacco	23
" diabetes	3
" lead	1
" sulphuret of carbon	2
	138

From syphilis, acquired	7
" " hereditary	7
" multiple sclerosis	5
" cold	5
" menstrual disturbances	3
" pregnancy	4
" loss of blood at abortion	2
" anomaly of heart	1
" periostitis orbitæ	1
" unknown	32
	66

It appears that in Germany amblyopia from abuse of tobacco is considerably less frequent than from alcoholic poisoning. In England, judging from Mr. Hutchinson's papers, the proportion is probably greater. Mr. H. speaks of the great strength of the tobacco used by his patients. The apparent infrequency of the affection among Orientals is explained by the mildness of their tobacco. It is very notable that all the first group of cases are males, and of the second 38 were men and 28 women. Smoking seems more hurtful than chewing, but I have seen the effect from the latter habit. Indulgence for many years is usually necessary to produce the result.

The symptoms are color scotoma, or absolute scotoma, varying in size and either central or paracentral. The shape of the scotoma has no relation to the kind of poison, as Förster has claimed. There may be no reduction of acuity by test types, or vision may be extremely bad. The periphery is not affected. Patients are sometimes conscious of their color defect, as was the fact with an artist who never drank wine or liquor, but smoked constantly and complained that he no longer found himself able to get the brilliant effect with reds which he had been accustomed to. There is sometimes a glimmering sensation; there is no pain either spontaneous or on pressure. Commonly both eyes are affected and the progress of the disease is slow, both in culmination

and in recovery. The blindness relates to both red and green, and in very rare cases to blue, just at the centre. Mr. Nettleship reports a case of ring scotoma added to the central scotoma. Total blindness is not common. Other symptoms appear in enfeeblement of the ocular muscles, and to some extent of accommodation. The muscular asthenopia is sometimes very conspicuous and presents debility in all the binocular movements, whether of abduction or adduction. A "weak heart" may or may not be discovered; and so is it with the frequent pulse. A neurotic condition is sometimes very pronounced. Pathological anatomy need not be enlarged upon, but inspection of Figs. 253 and 254 from Uhthoff shows the localized character of the lesion and the different sites it may occupy in different parts of the nerve. While all parts present multiplication of nuclei, the heavily shaded parts (stained by carmine) give the regions most concerned.

Treatment demands entire abstinence, which will be freely promised and not so often practised. Iodide of potassium seems to be of use, and Minor has found cases of recovery in tobacco amblyopia under its use when abstinence was not practised. The enforcement of abstinence with alcohol amblyopia is imperative. Dry cupping, hot foot baths, and the Turkish bath may be of value. Concomitant symptoms of dyspepsia, insomnia, must be suitably dealt with. Hypodermic injections of strychnia, gr. $\frac{1}{12}$ or $\frac{1}{30}$ daily, will often yield excellent results, and the remedy may be given in granules in increasing doses, beginning with $\frac{1}{10}$ daily and going to $\frac{1}{2}$ or more in some cases. In mild cases no drug may be needed. In some quinine as a tonic acts well; Filehne[1] found in himself that during four weeks after quitting smoking, sight grew worse and then progressed to recovery. Resuming the habit was not at first attended by harm, but later, sight again failed. Other toxic agents cause axial neuritis: Fuchs reports *stramonium*, the leaves smoked for asthma; the man used them freely, and did not use tobacco or alcohol ("Lehrbuch," p. 477); and sulphur used in caoutchouc factories, as bisulphide of carbon. Lead causes the same effects and is much more rebellious to treatment. We may have peripheral neuritis as well as axial, and we shall be guided in deciding the localization by the quality of the field. The scotoma of diabetes and of some other cases might be called toxic. See Knapp, "Orbital Optic Neuritis," *Archives für Ophth.*, Jan., 1891.

(NOTE.—The pathological demonstration of axial optic neuritis is one of the most interesting discoveries of recent ophthalmology. The first clear case with autopsy was published by Samelsohn in 1882, who confirmed what has already been conjectured with some correctness, by Leber, Michel, Lieb-

[1] Graefe, Archiv f. Ophth., xxxi., 11, 25, 1885; also Groenow, Graefe, Archiv, xxxviii., 1, 1.

reich and others, and then other cases were reported by Vossius (1882), by Nettleship, Bunge (1884), and Uhthoff (1886), making it perfectly clear that

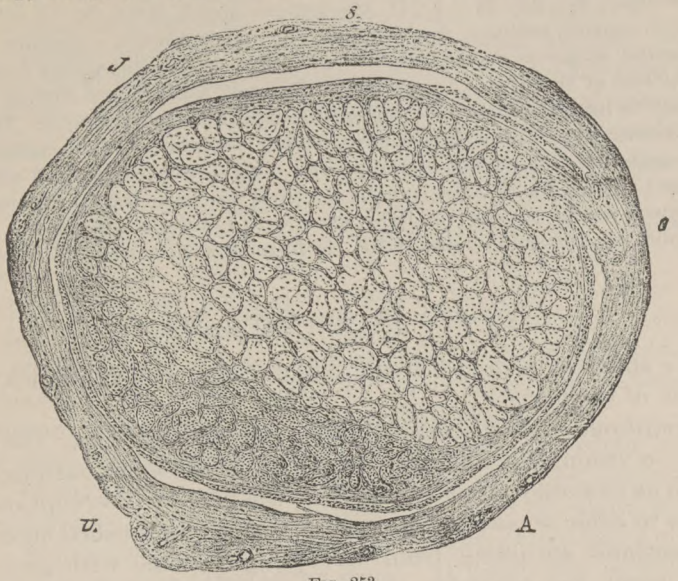

FIG. 253.

the fibres which supply the central region of the retina enter the eye as a wedge-shaped cluster on the temporal side of the disc, occupying nearly

FIG. 254.

its inner and lower quadrant. A similar and still more interesting fact is the autopsy of Uhthoff's case, where this lesion arose in a patient with

Digitized by Illinois College of Optometry

typical locomotor ataxy. At the present time a case of strabismus comes under my notice in a boy of ten years, whose right optic nerve has diffused hyperæmia, V = 0.7, H = 1.5 D; the left eye has V = 0.1, H = 2. D, with a defined central scotoma for red, and the nerve shows a distinct sector of triangular shape on the outer and lower side of opaque white tissue, while all the rest of the disc is hyperæmic. The boy was noticed during his early infancy to have peculiar eyes and squinted when two years old. This seems to indicate congenital axial neuritis. Leber, G. and S., v. 832, assigns simple color scotoma with normal vision to the optic nerve lesion, and while color scotoma with reduced sight he calls a retinal scotoma, that the latter is to be demonstrated by testing the light sense with Forster's apparatus. Patients feel more comfortable by dim light, yet in reality their vision is worse.

Atrophy of the Optic Nerve.

We speak of primary atrophy not of that which follows inflammation of the nerve.

Symptoms.—They are both subjective and objective. The former relate to vision, which may be impaired in the most various degree —both as to acuity, the boundaries of the field or interruptions in it, and as to color sense and light sense. With diminished sight there is sometimes shrinking from strong light, while with greatly reduced sight the contrary obtains. Rarely, patients complain of glimmerings; the onset of the trouble is slow. With total loss of sight there will usually be dilated pupils, but on this point important differences occur, because inactive, unequal, and reduced pupils are characteristic of the large class of cases which depend on spinal lesions. It is related of one case as a great exception that the pupils reacted when exposed to light, yet there was absolute blindness. The eye commonly looks normal, and there is no pain.

The ophthalmoscope alone reveals the true situation. (See Colored Plate, Figs. 10 and 11.) The appearances of the condition are somewhat various. The nerve-disc is always opaque, and in the greater number of cases is white; but we also find it gray, leaden, bluish, or "dirty." Very often the lamina cribrosa is conspicuous, appearing as a mixture of white and dark dots, or intersecting fibres. The nerve is flat, or more often concave, and is especially apt to be saucer-like; the degree and kind of concavity will be modified by the original form of its surface, whether or not it may have had a physiological excavation. The outline is always in advanced cases sharply defined, and is often deeply pigmented. There may be a time, if atrophy follows inflammation, when the border is ragged, or striated, or ill-defined. According to the nature of its surface, both as to color and form, the nerve may be uncommonly bright and luminous, or of a dull hue. There are cases of partial atrophy where the temporal half is white and pallid, while the nasal side is red. Care must be taken not to hastily pronounce on

Digitized by the Internet Archive

such a condition, because such an arrangement is often normal. The vital point in diagnosis is want of transparency in atrophic nerve-tissue, while healthy substance always is transparent. (The upright image and the edge of the illuminated surface as it is moved by slight rotation of the mirror will best reveal the condition.) A want of capillary vessels, and the development of connective nerve-tissue, while healthy substance always is transparent. A want of capillary vessels, and the development of connective tissue, is necessarily implied in the above description. As to the larger vessels, the arteries will be small, sometimes thready, and the veins, although larger, will also be of reduced size. Sometimes the vessels are not much changed in calibre, and in other cases they are almost entirely wanting. It is not rare to find the vessels bordered with gray or whitish lines, so-called peri-vasculitis. (See Colored Plate, Figs. 2 and 6.) Often there will be traces in the retina of a concomitant or pre-existing lesion.

The subdivisions of nerve atrophy are made according to color into white and gray (Leber), the latter being regarded as significant of spinal lesions, but there are mixed forms and the distinction has only an approximate value. For example, many old cases of glaucoma have a gray or bluish-gray color. It must also be remarked that in old age the nerve often loses its clearness and may become gray or leaden with no evidence of impaired function. For recognition of slight changes in color the light must always be weak. Cases of a simply pallid nerve occasionally occur which so closely resemble atrophy as to be very puzzling. This may happen both in young and older persons and naturally will appear in the anæmic. The point to be especially noted is the texture of the nerve. A pallid and pellucid nerve is not atrophic. If pale and opaque, or dead looking and into whose texture one cannot penetrate, this denotes atrophy.

Another division of atrophy is into primary and secondary, or into medullary and interstitial; the former is a lesion of the nerve fibres, the latter concerns the connective tissue and may be preceded by inflammation. Atrophy affects the papilla primarily or secondarily, and may come from disease in the retina and choroid or with glaucoma; it may ensue after lesion of the trunk of the nerve; it may be cerebral or spinal or from numerous general causes. Men are affected in much greater proportion than women. It occurs at all ages and may be congenital. There is a hereditary tendency which has been noted by Leber, Nettleship and others. Many members of the same family have been known to be victims.

Causes.—A carefully studied collection of cases by Uhthoff,[1] amounting to 183, gives the following results:

[1] Graefe's Archiv f. Ophth., xxvi., Abth. 1, 1880, and "Beiträge zur Pathologie des Sehnerven," etc., Berlin, 1884, p. 50.

Digitized by the College of Physicians Library

		Men.	Women.
Spinal cord	59	55	4
Brain	41	23	18
Simple progressive	22	16	6
After neuritis optica	17	13	4
Sudden embolism of arteries	8	3	5
Disease and accident in orbit	8	3	5
Dementia paralytica	7	6	1
Loss of blood	4	0	4
Alcoholism	4	4	0
Lead poisoning	2	2	0
Hereditary	3	2	1
Injury	3	2	1
Epilepsy	2	2	0
Nephritis	1	0	1
Railway spine	1	1	0
Congenital with hydrophthalmia	1	0	1
	183	132=72%	51=28%

It is seen that in the above table only causes outside of the eye are mentioned and we naturally take only these cases into consideration. Just 100 of the above cases depend on lesions of the brain and spinal cord, or more than 54%, which is higher than the figures given by Galezowski[2] from 166 cases. Still other causes are alleged, viz., fevers, menstrual disturbances, etc. The numerical frequency of *spinal cord* lesions as a cause of atrophy has been noted by many observers and the longer the cases are kept under observation the more decided becomes this preponderance. The three symptoms to be looked for in spinal cases are nerve atrophy; abnormities in the action of the pupils, viz., small size, inequality, torpor, lack of response to light while responding to convergence and accommodation (Argyll-Robertson), indisposition to dilate upon sharp irritation of the skin as by a pin prick or the faradic brush; and the want of knee reflex. The last symptom may at a given period be wanting, yet in course of time appear; so with pupil abnormities. Both eyes will be affected and blindness occur in from one to three years; a shorter period is rare. In the great majority of cases, about four-fifths, the whole field is impaired, and its reduction takes place concentrically from the periphery, while visual acuity steadily declines. Sometimes well-defined sectors are cut out and very irregular outlines are formed, and the remaining portion may continue relatively good for a long period. Singular maps are sometimes thus produced —and as special peculiarities the following may be noted; blindness of the upper or lower halves of the field—and cases where the field becomes excessively narrow and regular, and with very fair vision

[1] Journal d'Ophthal., 1, pp. 45–50, 180–212, 1872.

Digitized by the Internet Archive

both for white and colors. The occurrence of central scotoma in spinal lesion has been noted. Defect of color sense is the rule, the ability to recognize green is usually first lost, then red, then yellow and blue. The proper limits of recognition of the respective colors will be reduced and finally their perception gradually fades entirely. Sometimes the first color lost is red—while green may remain. In what direction impairment of the field first appears in spinal optic nerve atrophy cannot be declared; different authors give different results.

In these cases further symptoms due to the spinal lesion will eventually appear, viz., trouble of the bladder, staggering gait, constriction of the body, burning of the feet, mental impairment, vertigo, etc.; while the lightning pains will have existed both long before, during, and after the nerve atrophy.

Atrophy from *cerebral* causes includes those which have been preceded by papillitis, and of which the causes have been previously mentioned, viz., tumors, etc. (see p. 602). Perhaps one-fourth of the cases are of this type, but this is necessarily mere conjecture. Among other causes are meningitis, hydrocephalus, mechanical pressure of tumors on the nerve or on its deeper connections, distention of the third ventricle pressing on the chiasm. Narrowing of the optic canal by periostitis is not an infrequent cause. Injuries which cause fissure of the orbit, or of the canalis opticus (Holden), or of the base of the skull, may eventually show their effect by atrophy, while amaurosis may have preceded it. Disseminated sclerosis and general paralysis of the insane (paresis) cause atrophy. The latter is preceded by distinct but moderate chronic inflammatory signs. Embolism of the retinal artery and sometimes cerebral hemorrhage, or embolism, are followed by atrophy. Severe hemorrhage from any source is followed sometimes by optic neuritis and also atrophy, either primary or secondary. I have seen atrophy follow softening of the brain, but the sequence is rare. There are also cases of hereditary and infantile atrophy of various causation. Sclerosis of cerebral vessels has, Michel thinks, important influence.

Atrophy occurs in some cases as a primary lesion of the nerve, both in the papilla at the onset, or retro-bulbar and subsequently exhibited in the papilla. The condition is analogous to primary optic neuritis. General diseases, viz., facial erysipelas, diphtheria, typhus and typhoid fevers, diabetes, scarlet fever, menstrual irregularities, pregnancy (Loring, "Text-book," Part II., p. 206), etc., are correctly catalogued as causes. Many times we are quite unable to assign a cause with any assurance.

Morbid Anatomy.—In the *medullary* or parenchymatous atrophy which we have with ataxy and other conditions, the medullary part of the nerve fibres disappears, at first becoming pale and

Digitized by Boston Medical Library

varicose and interspersed with cells of granular fat, which will be especially abundant in the chiasm and tractus. Amyloid corpuscles appear and more numerously in the cerebral parts of the tractus. After a time the nerve fibres are reduced to an indifferent structure and the whole nerve becomes smaller. The connective tissue becomes somewhat increased, though not to a marked degree; the walls of the blood-vessels become thickened and their calibre reduced. Few fibres or many may be involved and in sectors or portions or for the whole length of the nerve, and likewise in its cerebral continuation.

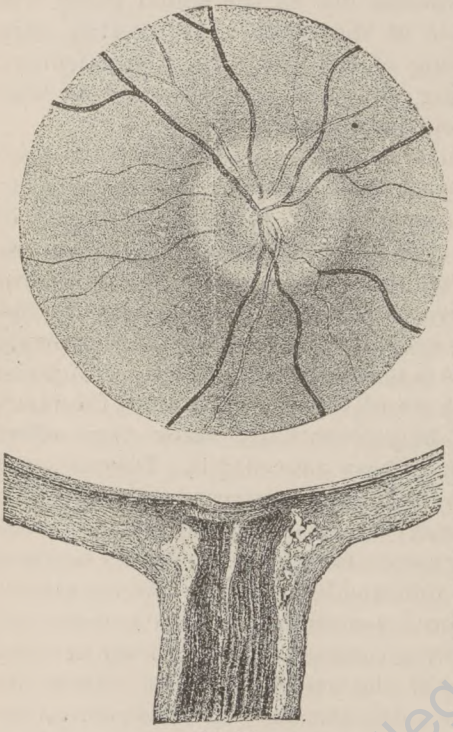

FIG. 255.

As a result of the shrinking of the constituents of the nerve its size becomes reduced and it opens up the sheath cavity as displayed in Fig. 255 from Jaeger, especially around the papilla. From this condition the formation of the shallow excavation of the disc in extreme atrophic states is understood.

The textural changes are understood by the figures from Poncet. Fig. 256 shows a portion of a normal nerve; Fig. 257 shows the nerve which has passed through the period of inflammation and arrived at atrophy. The case was one of locomotor ataxy and the patient had been blind for thirty years.

The atrophic process will be set up by destructive disease of the retina, by loss or extirpation of the eye, and will ascend to and beyond the chiasm. Gudden's experiments in removing the eyes of young animals have plainly demonstrated this effect. On the other hand, lesions of the cortical sight centre, of the tractus, or of the chiasm, will very slowly give rise to nerve atrophy. The pressure of tumors, foreign bodies, and exudation, exhibits the same effect. The descending process is much slower than is the ascending.

Interstitial atrophy found after inflammation or after sclerosis, exhibits a much larger development of connective tissue and nuclei, with choking of the nerve fibres. They lose their myelin and are

Digitized by Illinois College of Optometry

changed into connective tissue. A greater or less portion may be involved. In the retina the layers which suffer are the optic fibres and ganglion cells, while the remaining layers, as a rule, are intact.

Under this head comes a very interesting class of cases which present the white color of atrophy with but little loss or possibly serious loss, and ultimate recovery, of sight. In them interstitial neuritis causes proliferation of connective tissue, with consecutive choking and damage of the medullary sheaths, without destruction of the axis cylinders. Such cases are found with disseminated sclerosis or in primary lateral sclerosis. See Zimmerman, *Arch. f. Ophth.*, XX., 3, 329, 1891.

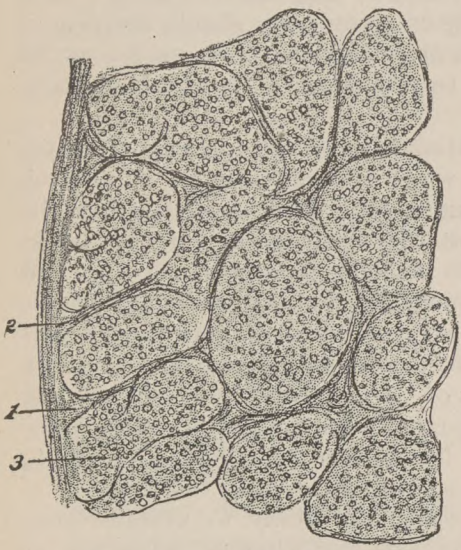

FIG. 256.—1, Internal sheath; 2, sheaths of connective tissue, separating the bundles; 3, optic nerve fibres.

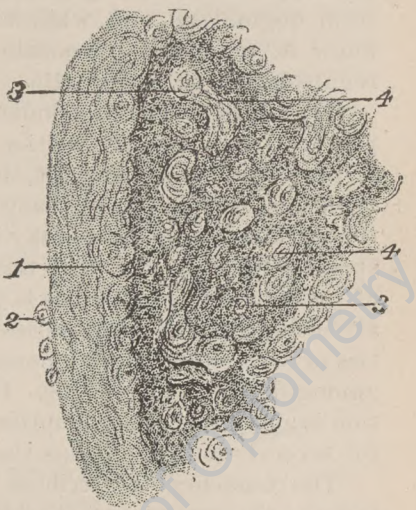

FIG. 257.—1, Internal sheath, hypertrophied and sclerosed; 2, epidermic globules common in old persons; 3, nerve substances wholly disorganized; 4, connective tissue—very abundant about the numerous fine vessels.

Prognosis.—Seldom is it otherwise than bad. Proper weight must be given to surrounding and causative circumstances, because the nerve-lesion is often concomitant, and its character largely dependent on the chief affection. Certain cases retain remarkable sight, and they are more likely to be the interstitial where the primary affection is in the connective tissue. See Zimmerman, l. c. If the originating disease has ceased its activity, as, for example, meningitis, and some sight remain, this may even improve. I have seen several such instances, and more especially in young subjects. Nettleship[1] has published several "cases of recovery from amaurosis in young children," doubtless interstitial atrophy.

Digitized by Illinois College of Optometry

It is right to emphasize the statement already made, that pallor of nerve must not be mistaken for atrophy. Neither must a true atrophy be always pronounced progressive. The state of the field and the quality of the color-sense are to be duly considered. One consolation is often possible, viz., that the rate of progress to the bad will be slow.

It is affirmed that regular concentric limitation is more unfavorable than fields of irregular outline caused by deep entering angles of darkness. It has, however, been shown that good vision within a very narrow field is sometimes long preserved. Cases which show a similarity in the irregularities of the two fields are to be traced to brain-lesion, and they may or may not be curable. Our ignorance of the true pathology of many cases should restrain us from dogmatism, and, while we utter only the truth so far as we know it, we ought to hesitate to pronounce a doom, which many regard as worse than death.

Treatment.—The first indication is to correct any and every departure from normal function which we can discover or control, in nutrition, sexual organs, lungs, etc.; also to counteract the syphilitic, rheumatic, or gouty diathesis, and scrofulous tendencies; to discriminate, so far as may be possible, diseases of the brain and spinal cord, and, even when there may be no token of syphilis, iodide of potassium in high doses is justly esteemed. Under these heads are included many possibilities of treatment suited to the peculiarities of each case. Minute doses of "gray powder" are much in use among English physicians. Corrosive sublimate in watery solution is also a useful prescription for children, giving gr. $\frac{1}{60}$ or gr. $\frac{1}{100}$ for several months. It has the advantage of being tasteless.

The tendency to attribute locomotor ataxy to syphilis lends force to the prescription of mercurials and iodide of potassium, or iodide of sodium. Many times the nerve lesion simply follows the general malady and too often we are wholly at a loss to know what to suggest. As the optic lesion goes with the spinal disease, reference may be made to an important article by L. C. Gray, *N. Y. Medical Journal,* Nov. 16th, 1889. In former times setons and blisters and moxas were much employed; now the actual cautery is applied to the scalp and to the skin over the vertebræ, when the brain or the spinal cord are thought to be congested. The faradic brush, rest in bed, etc., are employed. When, however, these proceedings have been tried or do not seem to have any claims for trial, we are reduced to the use of a few remedies. The most important is strychnia. Nagel has the credit of having taken it up systematically and with energy, and claims special benefit from its hypodermic administration, giving of the sulphate of strychnia $\frac{1}{30}$

[1] Trans. Oph. Soc. United Kingdom, v. iv., 1884.

Digitized by Illinois College of Optometry

to $\frac{1}{10}$ grain once daily in the temple. His method has been largely adopted, but it is to many patients inapplicable, because of the constant attendance on the physician which it necessitates. One may therefore substitute its internal administration in granules, which may be $\frac{1}{60}$ or $\frac{1}{30}$ grain each, and give a quantity sufficient to bring about manifest constitutional symptoms. There will be a tendency to cramps in the legs and in the lower jaw, sometimes colic, and sometimes exalted nervous excitability. The amount requisite to obtain this result will be different according to the subject, but $\frac{1}{3}$ grain daily is not a large amount for an adult male, and I have given $\frac{3}{4}$ grain with impunity. This amount is to be gradually reached by adding to the number of granules every third day, until the proper symptoms appear. When the full effect of the drug has been reached, the dose is to be kept up for three or four weeks, or so long as continuous gain is observed, and this may go on during three months. If, after three weeks of strychnia-symptoms, no improvement in sight is discoverable, the remedy may be considered unavailing.

Another remedy, which is less positively effective, but is to some extent useful, is phosphorus. It is sometimes given with strychnia. It is not advisable to push it to the production of constitutional symptoms, and it is not usually carried higher than $\frac{1}{12}$ grain daily. A combination of the following kind is a tonic of high value, both for these cases and in many debilitated subjects. It has the virtues of both remedies.

℞ Acid. phosphorici dil., ... ℥ iij.
Strychniæ, ... gr. i.

Take thirty drops in water three times daily.

The proportions may be varied as desired.

As to zinc and nitrate of silver, I can say nothing from experience. Cod-liver oil is often helpful, but not as a specific like strychnia. Quinia and iron are many times indicated. Electricity has failed to vindicate its pretensions to any real value, although, by its capacity for exciting phosphenes, it fosters the hopes of a credulous incurable.

Stretching the optic nerve by a strabismus hook passed behind the globe has been practised (Wecker), but it has not been found of value.

Digitized by Illinois College of Optometry

CHAPTER XIX.

AMBLYOPIA AND AMAUROSIS.

THESE terms designate certain cases of partial or total loss of sight which do not present any visible intraocular lesions. Among them retro-bulbar neuritis in any of its forms, inflammatory or toxic, is not included. Hence, we omit the so-called alcohol and tobacco amblyopia. Neither do we put hemianopsia in this category. We use the words to designate conditions whose pathology is not known or which may be functional in character, to use an expressive, though vague, term. There may be limitation of the field, or scotomata, and loss of color sense. Some cases are permanent, some are transient. With the advance of our knowledge, we shall make less frequent use of these terms. For example, we speak of uræmic or diabetic amaurosis and amblyopia, or of that which occurs in pregnancy, of reflex amblyopia, etc., and as colloquialisms they are justified. But cerebral cases, for example those with lesion of the occipital cortex, are excluded.

What we may include in our catalogue of amaurosis and amblyopia will be such conditions as the following: 1. Traumatic. 2. By lightning. 3. Hemorrhage, local or general. 4. Toxic, from which we have excluded alcohol and tobacco. 5. Uræmic. 6. Diabetic. 7. Hysterical. 8. Migraine. 9. Reflex.

Some cases will for a time be reckoned as amblyopia until a later stage shall show the true nature of the disease. The pathological lesion may lie in some special cases, 1st, in the retina over limited or more extensive portions and for months escape ophthalmoscopic detection. It may also exist, 2d, in the deeper parts of the orbital portion of the optic nerve, or in the chiasm. 3d. In the tractus and its continuation in the brain—but these cases will sooner or later exhibit recognizable tokens of atrophy of the papilla nervi optici. 4th. Again, we have cerebral blindness coming under some of the heads above designated and some denoted as mental blindness because all recollection of visual impressions as well as ability to perceive them has been obliterated.

Traumatic amblyopia or amaurosis is either a provisional term awaiting the development of the true morbid status, or it may simply mean that we are unable to discover the lesion. The trau-

matism may be direct or indirect. A direct blow on the eye may sometimes cause amblyopia without visible tissue lesion except as follows: First, immediate rigid contraction of the pupil. This has been noted by Berlin, and probably by others. I have seen it a number of times. The contraction is to the smallest size, and resists for hours the most vigorous use of atropia. So small have I found the pupil that ophthalmoscopic examination has been impossible. Berlin (*Klin. Monatsbl.*, XI., p. 42, 1873), writing upon concussion of the retina, divides these cases into two groups: First, those in which central vision is moderately impaired (say to $\frac{15}{100}$ or to $\frac{15}{200}$), while peripheral sight is intact. In a few days sight is fully restored and he thinks irregular astigmatism of the lens is the proper explanation. See p. 613.

Second, Berlin, l. c., describes cases of direct injury to the globe, in which he has seen a spot of whitish opacity of the retina at a point opposite the place of injury, and sometimes also on the site of the blow, which begins to appear within a few hours, and vanishes after two days, with restoration of vision. I have noted this lesion, and it must generally be sought at the extreme limit of the ophthalmoscopic field. Knapp has reported cases. In experiments upon rabbits he always found a subchoroidal hemorrhage at the situation of the retinal opacity. Aub (*Archives of Oph. and Otol.*, vol. II., 173) reports a case of metamorphopsia after a blow, which implies disturbance of the retinal elements. There may be innumerable complications of such injuries in other lesions of the globe, such as hemorrhages, irido-dialysis, distortion of the pupil, etc., but they are not now under consideration. Continual pressure on the eyeball will cause blindness. Testelin reports it in a man who, when drunk, lay for many hours with his eye pressing upon his hand. Graefe cured a case of severe blepharospasm, which had lasted eleven months, by section of the supraorbital nerves, and the child had become almost blind. In the course of a month sight returned, simply, as Graefe believed, because the pressure was removed.

Another class of cases are due to indirect injuries by which the optic nerve, either in the orbit or in the brain, has suffered lesion. The explanation is to be given of not a few cases, which was brought forward by Berlin in the Heidelberg Ophthalmic Congress, 1878, to the effect that fissure of the roof of the orbit is far more frequent than is generally supposed, and it extends often through the optic foramen or through the sphenoidal fissure. To discover it, the dura mater must be stripped from the bone, which is rarely done at an autopsy, and it was found by Dr. von Hölder to occur in ninety per cent of the cases of fracture of the base of the skull. Naturally by hemorrhage into the optic sheath, or by laceration of the fibres

Digitized by the Columbia University Library

of the nerve, sight would be injured, and atrophy might ensue, while for a long time no signs could be seen within the eye.

Apart from these cases, to which reference will be again made when speaking of lesions of the orbit, the nerve can suffer serious injury by contusion within the canalis opticus, and hemorrhages are quite likely to take place here where numerous vessels come in to supply the nerve. Within the category now discussed will come the cases which sometimes have been called reflex amaurosis by injury of the supra-orbital nerve as it passes through the supra-orbital foramen. Not now deciding the point of possible reflex influence, it is certain that some of these cases are fully explained by fissure of the orbital roof and consequent injury, direct or indirect, to the optic nerve. Analogous to this lesion is the following case in my own experience:

A very large man fell into a hole in the street, and struck the outer edge of one orbit on the pavement. He lost sight in the eye of the injured side immediately, and after a few days the opposite eye became very amblyopic. In neither was any lesion to be seen by the ophthalmoscope. A fissure of the orbit probably extended to both sides. It is important to inquire for bleeding of the nose, and to search for subconjunctival ecchymosis, which may come to view several days after the injury. Both these signs would be strongly indicative of fissure, but would not be indispensable as symptoms.

Penetrating wounds of the optic nerve are rare, but two unquestionable instances have fallen under my notice, in one of which proof was found in the immediate and total loss of sight and in the ophthalmoscopic appearances of the optic nerve (see page 687.) Of course such cases are not samples of amaurosis, which we now are discussing, but they may explain some other cases wherein total loss of sight followed a trifling injury (Haas,[1] by penetrating wound with a table fork) in which no lesion could be seen.

Traumatic amblyopia, or amaurosis, may occur through a great variety of injuries of the skull or brain, to which no clue can be found should the patient survive, but in which some disorganization of tissue undoubtedly has occurred to structures concerned in vision.

Concussions of the spinal cord may cause loss of sight. More than twenty years ago I saw a man who, by a railway collision, received a sudden and severe blow upon the lower end of the spine, whose force was transmitted in the line of the vertebræ directly upward. He suffered extreme pain at the base of the skull, and along the spine, while his sight was, as I remember, about $\frac{20}{100}$, and the

[1] Klinische Monatsblätter, 1884, p. 280.

Digitized by Illinois Eye and Ear Infirmary

visual fields were contracted to a space whose angle was less than thirty degrees. In both eyes there was extreme hyperæmia of the optic discs and of the large and small vessels. For a number of weeks the condition remained unchanged, and I do not know how it finally turned out. In this case a paralysis of the fibres of the sympathetic might well be assumed as the cause of the vascular dilation. What caused the extreme limitation of the fields is purely conjectural.

Loss of sight by concussion of the spinal cord is dwelt upon by Erichsen in his treatise 1875, and 1883, and in his chapter, p. 233, on visual affections is much that is irrelevant and unproven. Later writers have contributed to this subject under the head of traumatic neuroses. Charcot, Oppenheim, Strumpel, Dana have written upon the subject, and a paper by P. C. Knapp, in Boston *Medical and Surgical Journal*, Nov. 1st, 1888, covers the subject intelligently. A case reported by Boland[1] gives the visual symptoms happening in such cases: viz., as an immediate effect—colored vision (not always present, and is transient), contraction of the fields, and monocular diplopia. In Boland's case the limitation of the field was in only one eye. The monocular diplopia passed away, but the retinal affection remained. Concussion of the lens would appear to be the only explanation of the diplopia, while the contracted field may be accounted for, perhaps, by hemorrhage pressing on the nerve. In some autopsies minute hemorrhages have been found scattered in the brain. Cases of this kind have great importance in their medico-legal relations because they arise often after railway accidents. Unhappily because the symptoms are almost wholly subjective and the temptation to simulation and exaggeration great, the physician is compelled to a rigid scientific and somewhat sceptical examination, to justify him in hazarding an opinion about their genuineness. His opinion will be eagerly solicited in aid of a claim for compensation for alleged visual and other injuries. While visual lesions may be produced, he must not forget the possibilities of malingering.

Prognosis in traumatic amblyopia and amaurosis is good for the mild cases, while for severe injuries of the orbit, of the skull, of the brain, or the spinal cord, it must be guarded.

Treatment at first will be such as the special conditions of injury call for, and when the primary symptoms have passed, resort may be had to strychnia, either by injection or by the stomach. The mild cases of traumatic amblyopia will get well spontaneously within a few days (see case in Hirschberg, *Centralblatt*, April, 1881, p. 100; by Reich, neuro-retinitis partialis after injury of skull —recovery; also see case in Gowers, p. 318, fracture of orbit, etc.).

[1] Boston Med. Surg. Journal, Nov. 10th, 1887.

Loss of sight by stroke of lightning has been recorded in many instances and the lesions are diversified, viz., burn of the skin and hair, and of the cornea, ptosis, especially production of cataract, whose maturation may be rapid and is apt to begin at the posterior pole; sometimes iritis and other inflammatory conditions, and absolute amaurosis not accounted for by other lesions and occurring very early. In other cases neuro-retinitis and partial atrophy of the nerve have been discovered, as well as mydriasis and paresis of accommodation, and we therefore refer to such injuries simply to call attention to the liability to implication of the nerve and retina with or without conjunction of other lesions. For careful report, see case by Laker (*Archives of Ophthal.*, Am. ed., vol. XIV., p. 181, 1885, and Buller, *Archives of Ophthal.*, XVII., 2, 131, 1888, and Leber Graefe's *Archiv*, XXIII., 3, 255.)

Amblyopia or Amaurosis from General Hemorrhage.—This subject has been elaborately presented by Fries in an inaugural dissertation (Beilageheft zu *Klinische Monatsblät.*, Zehender, 1876), based upon 106 cases recorded from 1641 to 1876. A number of instances have been published by other observers since Fries. Mandelstammer, two cases from nose-bleed, *Centralblatt*, 1879, p. 175. The sum of the matter is that, after severe hemorrhage, loss of sight sometimes takes place, and may be immediate, may be within a few days, or be deferred as late as the eighteenth day. In a number of cases signs of neuritis, or retinal hemorrhage, or of retinitis, or of atrophy of the nerve, were found, while in other cases no visible lesions appeared. The pathological connection between cause and effect is not understood. The source of the bleeding may be most various: most often it is from the stomach and intestines; next in frequency, it comes from the uterus either in childbirth, from abortion, or during menstruation; it may be from the lungs, the bladder, the urethra, or by venesection, or by injury. The last is the least common cause. It is sometimes attended with peculiarities in the visual field, such as irregular defects or scotomata. In 90 per cent (Fries) both eyes are affected; in 47 per cent the loss of sight is permanent, the pupils being dilated and perception of light wanting; in 31 per cent there was improvement, and in some of these cases this occurred in only one eye; in 21 per cent entire recovery was obtained. The time when recovery set in was variable, that is, from a few hours to three or four months, and in one case to nine months. The pathological appearances would naturally have great influence on prognosis, and in the bad cases inflammatory signs are most pronounced.

A lady, 52 years of age, under my own observation, in whom uterine hemorrhages were of the greatest severity and for which ovariotomy was undertaken, had choroido-retinitis and retinal hem-

Digitized by the Internet Archive

orrhages, but the great factor in the loss of vision was proved to be the general depreciation by the loss of blood, because during a period of months when the hemorrhages ceased, vision notably improved, and again receded when the bleeding recurred—meantime no intraocular changes could be detected to account for the variation in sight. Subsequent to writing the preceding lines additional loss of sight ensued, as the effect of atrophy of the choroid and retina at the region of the macula. This was evidently the consequence of impoverished nutrition and signified coarse lesions succeeding the finer ones which had for so long a time impaired vision.

In a case reported by Ziegler,[1] at the autopsy there was found fatty degeneration of the optic nerves. See also Hirschberg in *Centralblatt f. Augenh.*, Sept., 1892, p. 257, showing neuritis and atrophy.

Treatment will be modified by the general condition of the patient and by the source of the bleeding. The most efficient means of aiding recovery are: first, the vigorous use of strychnia by injection or by the stomach; second, by galvanism; third, by dry-cupping about the temple; and fourth, by general invigoration, to improve the action of the heart and the quality of the blood. This includes iron, digitalis, cod-liver oil, quinine, etc. That the sight does not more frequently suffer by large loss of blood is in part due to the comparative independence of the intraocular circulation as compared with the systemic; but this, of course, is only true within certain limits. Gowers ("Medical Ophthalmoscopy") has condensed many of the observations on this subject (see pp. 184–188), 1879.

So called *amblyopia ex anopsia* in strabismus has advocates (Leber and Theobald), and within very narrow limits may be conceded, but it will be left out of our category. See p. 181. On the other hand *congenital amblyopia*, central or general, is not rare. The cause will lie in retro-bulbar neuritis, axial or general, in transient meningitis, etc.

Toxic Amblyopia and Amaurosis includes many pernicious causes. Alcohol and tobacco, which excite a peculiar partial neuritis, have been discussed. We have, moreover, lead, to which reference has been made, and osmic acid,[2] which besides severe irritation of the conjunctiva causes great and sudden amblyopia. Nitrobenzol containing aniline is another toxic agent (see case by Litter, in Hirschberg's *Centralblatt*, p. 118, April, 1881); the patient was in coma, and the surface of the body, as well as the eye-grounds, were intensely blue. Silver and mercury are said to cause amblyopia; likewise sulphide of carbon, used in the manufacture of india-

[1] Fortschritt de Medizin, 1887, Nov. 15th, p. 735.

[2] Noyes, Trans. Am. Ophth. Soc., 1866, p. 34.

Digitized by the College of Physicians Philadelphia

rubber—in which lead is used (see "Report of Case on Bisulphide of Carbon," Trans. Oph. Soc. United Kingdom, 1885–1886).

Quinine, in large doses, has had the same result, as reported by Graefe, 1857, Voorhies, Trans. Amer. Med. Assoc., p. 411, 1879, Roosa and Grüning, and others. Grüning concludes his article on *quinine amaurosis* (see *Arch. of Oph.*, p. 81, March, 1881) by this statement: "The patient, after the ingestion of a single dose or of repeated doses of quinine in various quantities, suddenly becomes totally blind and deaf. While the deafness disappears within twenty-four hours, the blindness remains permanent as regards peripheric vision, central vision gradually returning to the normal after some days, weeks, or months. The ophthalmoscope reveals ischæmia of the retinal arteries and veins, without any inflammatory changes." By others it is stated that permanent diminution of the vessels and even their obliteration occurs: the nerve being pallid, that is atrophic. Color blindness, sometimes complete, has been noted by Grüning, Knapp, and Roosa. In one case central scotoma for white was noticed (Iodko, Brunner, l. c.). There may be permanent limitation of the field, while central vision is good. In most cases complete restoration takes place. (See "Ueber Chinin Amaurose"—Inaugural dissertation by Brunner—under the auspices of Horner, Zurich, 1882.) An exceedingly complete summary of cases is given by Atkinson, *Journal of Amer. Med. Assoc.*, September 28th, 1889. He finds the first reported case in 1841.[1]

Salicylic acid is, by Riess, reported to have had the same effect. Full doses of santonine do not impair sight, but make all objects look yellow. I have no knowledge of the appearance of the fundus in these cases. In regard to lead, we find inflammation of the nerve and retina, atrophy, and also amblyopia without visible lesion. There are also cases of brain-lesion. For lead amblyopia, treatment by iodide of potassium gives good results; for inflammation and atrophy, the prospect is unpromising.

Uræmic amaurosis and amblyopia due to kidney disease has been referred to: it accompanies and subsides with other symptoms of blood poisoning, viz., pain in the head, epileptoid fits, etc.

Glycosuria sometimes presents a chronic form of amblyopia, viz., central scotoma for red, central scotoma for white light more or less intense, even to totality; there may also be irregular peri-

[1] De Schweinitz, experimenting on dogs, explains the process as follows: "The original effect of quinine is upon the vaso-motor centres, producing constriction of the vessels; that finally changes in the vessels themselves are set up, owing, perhaps, to endo-vasculitis; that thrombosis may occur, and that the result of all these is an extensive atrophy of the visual tract."—Trans. Am. Oph. Soc., 1891, p. 23, with micro-photographs. The study of the pathological process is very complete.

Digitized by the Internet Archive

pherical limitations of the field; there may be hemianopsia and this can subsequently invade the whole field. Both eyes are concerned, yet often very unequally. The affection may disappear under suitable constitutional treatment, yet prognosis will hang upon the duration and severity of the amblyopia, upon the control which may be gained over the general malady, and upon whether signs of optic nerve atrophy appear. Even with evident nerve atrophy valuable vision may long be preserved. See Leber, Graefe and Saemisch, vol. V., p. 894, and a *résumé* of diabetic affections of the eye, by Dr. Moore, *N. Y. Med. Journal*, March 31, 1888.

Amaurosis of pregnancy has been referred to, and that it may be quite independent of uræmia so far as can be discovered. In the cases described only slight lesions could be found in the eye-grounds, but the optic nerves showed a tendency to atrophy. This occurrence has been known to happen twice to the same person. It is very grave, and has required the production of premature delivery as the only means of preserving sight; and this it has accomplished (Loring). See page 567. Sudden amaurosis from suppression of menstruation is reported by Samelsohn. After typhus and typhoid fever, sight is sometimes impaired or lost, and there will usually be atrophy of the nerve.

Hysterical amblyopia, or, as it is sometimes called retinal anæsthesia, is a recognized condition, and has been studied by Charcot, Landolt, and others. It is temporary, irregular, and attended by other hysterical symptoms. Hemi-anæsthesia is sometimes a characteristic of the cases. There may be only one eye affected, and but one-half of the field. There may be only central scotoma.

In epileptics temporary loss of vision sometimes occurs, which may be of various types, *e.g.*, hemianopsia, perhaps preceded by an aura of colored light (blue or red), or of smokiness, and without vertigo or unconsciousness or spasm; or there may be loss of sight in all the field, and the accompanying symptoms be various. A central scotoma and irregular limitations of the field may occur. But aside from these temporary perversions of vision is another and more persistent affection of which a mild form has been already referred to (see p. 197), to which Wilbrand called attention. The fields undergo concentric limitation, and may be reduced to a very narrow area, suggesting some organic lesion, yet nothing is visible to the ophthalmoscope. The following case illustrates the subject, and is especially pertinent because it was also studied carefully by another and very capable observer, Dr. Starr:

Herbert B——, 26, single. Father nervous, subject to neuralgia; mother subject to sick headaches. Has had sick headaches occasionally as long as he can

Digitized by the Boston Medical Library

remember; no syphilis; no venereal; occasional muscular rheumatism. Always has been nervous. Present attacks date back five years; formerly preceded sick headache, now do not. He suddenly sees yellow sparks or flashes in one half of the visual field of both eyes, either to right or to left, never in front, and then in a "few seconds" the entire half of the visual field in which he has seen the flashes becomes dark for a "few minutes." He feels dizzy and bewildered at the time and as if about to faint, but he has never fainted or fallen, or had a spasm or twitching of any kind and is quite sure that he has never lost consciousness. The attacks are usually accompanied by palpitation of the heart, and at times are followed by severe unilateral headache, nausea, and vomiting. During the attack his face flushes, and his head feels full. He can arrest the attack and diminish the after-effects by putting his feet in very hot water at once. He knows of no cause for the attack. The attacks occur about once a week, though the intervals vary in length. Digestion good—no flatulence—bowels regular. Urine free from albumin and sugar, and passed in normal amount, no excess of uric acid, no oxalates, no cardiac or pulmonary disease. No disturbance of sensation, co-ordination or motion. Reflexes normal and equal. No ataxia. Pupils equal, are widely dilated, react promptly to light and in accommodation; V $\frac{20}{20}$ in each eye. Adduc. 9°, abduc. 6°, $\frac{1}{2}$° esophoria, no hyperphoria. Is a very tall, thin young man, poorly nourished, "overgrown." Weighs 147 lbs. Visual fields normal for light and white, colors not tested. Says he can always see well excepting during attack. He fears insanity, has worried much, is a clerk at desk, writing 10 to 11 hours daily. Says he is becoming irritable and forgetful. Presents no mental symptoms during examination and memory of illness is good. Examination, May 15th, 1888.

Diagnosis.—In a boy of neuropathic constitution hereditary migraine attacks have developed of paralytic variety. The present attacks are of a migraine nature—vaso-motor in character and not true epilepsy.

A case of hysterical blindness, or perhaps rather simulation, lasting ten years, is given by Harlan, Trans. Am. Oph. Soc., 1889, p. 327. See others by Moore, Trans. Am. Oph. Soc., 1888, p. 80. Other eye diseases have been simulated in these cases, viz., glaucoma, and for this iridectomy was once done by Cuignet. Prognosis is good, and treatment must not be too serious. The main question is diagnosis.

Under the name of *amaurosis fugax* cases of total loss of sight without ophthalmoscopic findings and without hysteria have been recorded and we can give very little account of their etiology. See Snell, *Ophthalmic Review*, vol. i., p. 400, 1882.

Spasm of the retinal vessels or *migraine*, scotoma scintillans, has been described elsewhere, page 546. In these cases the lesion is in the retina, not in the brain as in the above case of Dr. Starr, and it can be observed by the ophthalmoscope.

One caution should be observed in these cases: not to confound attacks of megrim with the temporary obscurations which occur in glaucoma. For this reason, the tension of the globe, the state of the optic nerve as to excavation, and the limits of the field, must be exactly determined.

Dyslexia, paralexia, alexia, are terms denoting certain hindrances to vision which do not consist in impairment of visual acuity, but in incapacity to read at all or to read understandingly. A person having dyslexia has normal acuity, and can read a few acuity, but in want of capacity to read at all or to read correctly. A person having dyslexia has normal acuity, and can read a few words correctly, then suddenly puts down the book and cannot be induced to go on. There is no pain, no indistinctness, no fatigue, but the power of attention and reading is exhausted. It makes no difference whether he read aloud or to himself, he cannot proceed. A careful examination excludes all refractive or other functional error, or these may be perfectly corrected—hence the case differs entirely from asthenopia with which it may be confounded. Berlin[1] reports six cases and refers to others. In almost all there were symptoms of cerebral disease, and in six autopsies lesions were found in the left hemisphere not far from the third frontal convolution (Broca's region). In paralexia, the patient substitutes wrong words for those he means to use. In alexia he sees but cannot read the words. The last-named condition is part of the disease called by Munk mental blindness, which consists in the loss of memory of words or symbols describing objects, and depends on injury in the cortex of the occipital lobe near the gyrus angularis. It may be associated with agraphia, inability to write, and other lesions. See treatises on cerebral disease under forms of aphasia, etc. (*e.g.*, Wernicke, "Gehirnkrankheiten," Bd. 1, p. 338; also Starr, "Familiar Forms of Nervous Disease," and Herter, "Symptomatology of Nervous Diseases," 1892, p. 200 *et seq.*

Mental or psychic blindness has chiefly been studied by experiments on animals and it is not yet clear whether it can be ascribed to lesion of a particular part of the occipital region. According to Michel it sometimes ensues after violence to other parts of the brain and also after simple loss of the cerebro-spinal fluid. Discrimination between true cortical blindness and psychic blindness is not always easy, as is illustrated by a case reported by Schmierling from *Archiv f. Psychiatrie* in Zehender, October, 1889.

The cognate subjects of illusions and hallucinations, loss of memory of faces, etc., concern the mental concepts and processes which are associated with vision, and we shall briefly refer to them under another head.

Hemeralopia, night-blindness, denotes unduly reduced vision on the approach of night. The word nyctalopia which has been used in the same sense is now discarded. This condition must not be confounded with varieties of retinitis pigmentosa, in which the same symptom occurs, and each may be hereditary. Prolonged exposure to bright light will occasion this torpor of the retina, as

[1] "Eine besondere Art des Wortblindheit (Dyslexie)," 1887.

Digitized by the Internet Archive in 2007 with funding from Microsoft Corporation

well as the opposite state of exalted sensibility, hyperæsthesia. Hemeralopia unconnected with recognizable lesion, such as choroiditis, detached retina, etc., is sometimes epidemic, it happens to soldiers on the march under a hot sun, to travellers in the tropics and in the arctic zone, to glass blowers and others who work before furnaces. Color sense and peripheral sight will be reduced in certain cases, but often not at all. It is noticed that insufficient or poor food is a factor in the disease. The persons see well by day, but when the light is reduced below a certain degree, whether by night-fall or artificially, their vision is far worse than it ought to be. Sailors designate this condition as "moon-blindness," and attribute it to lying on deck in the moonlight. It often attends scurvy. See Leber in Graefe-Saemisch, vol. V., p. 994; *Arch. of Ophthal.*, vol. XII., p. 190, 1883.

Snow-blindness, as it is called, is a mixed condition, consisting of intense photophobia, spasm of the eyelids, conjunctival and corneal irritation, and sometimes chemosis. See case of Keratitis on p. 358 The bright glare and the severe cold combine to cause the condition and the treatment consists in soothing applications to the lids, warm water, with a little cocaine, 2%, protection by shades, goggles, veils, etc., or, if possible, shelter indoors. Some of the cases exhibit anæsthesia (torpor) of the retina, and some undue sensibility. For the cases of ordinary idiopathic hemeralopia, prolonged exclusion from light, with good diet, and in many cases antiscorbutics or cod-liver oil, will almost surely afford relief.

The occurrence of asthenopic or reflex amblyopia, especially as displayed in peripheral or "spiral" restrictions of the field, has been referred to on page 197 (Wilbrand).

Amblyopia from irritations of the teeth, *i.e.*, of branches of the fifth pair of nerves, has long found a place in text-books, but all such cases demand rigid investigation to establish their verity. A recent treatise[1] brings together many alleged instances, and credence may well be given to some of them. The teeth giving rise to trouble are those in the upper jaw; sometimes only the roots remain; they may or may not be painful. Frequently there is periostitis, and the causal connection may be by communicating inflammation to the orbit and the optic nerve. Again the relationship seems to be purely reflex judging by the quickness of relief after removal of the teeth. Galezowski reports iritis and infra-orbital neuralgia relieved by extracting bad teeth (l. c., p. 97). Widmark (l. c., p. 111) gives a case in *The Lancet*, July 10th, 1886, of blindness cured in four days by removing carious molars. Neuralgia of the eye may, as I have seen, be caused by irritation from a "wis-

[1] "Maladies des Yeux et Maladies des Dents," par Courtaix, Paris, 1892.

Digitized by Illinois College of Optometry

dom" tooth, and various cases by Hutchinson and others are reported by Courtaix, l. c. Abscess of the antrum has led to abscess of the orbit and even death; while affections of the pupil, of accommodation, and of motor muscles are reported by trustworthy observers (Ely, *Med. Record,* 1882, p. 258). Blepharospasm and photophobia are thus caused, and Galezowski gives a case where a denture provoked these symptoms. The brochure of Courtaix is worth study. Dunn gives a case where six months after an injury sight began to fail in both eyes, and after trying other remedies, section of the supra-orbital nerve gave relief to pain and sight gradually returned. There may have been a neuritis with reflex in optic nerve. See *N. Y. Med. Journal,* Aug. 9th, 1890; also, Despagnet, *Annales d'Oculistique,* Aout, 1893.

The literature is collected by Leber, G. and S., V., p. 978.

Treatment of the above cases, when not already touched upon, will vary with the nature of the cause so far as this can be discovered. Some recover spontaneously and may be aided by mild medication of the nervine or antispasmodic or tonic character—encouraging prognostications are potent curatives. For toxic causes, suitable antidotes and abstinence suggest themselves. The principal element in all these cases is to fix the diagnosis by absence of lesions of the fundus, of errors of refraction, or disorders of accommodation, or disturbances in muscular functions, and the treatment will follow the rational estimate of the case according to general therapeutic laws. For emotional cases, a hypnotic to secure a good night's sleep, a cup of hot, strong tea, a mustard plaster to the back of the neck, dry cups, bromo-caffeine, an injection of strychnia and various devices suggested by salient symptoms are to be brought into requisition. Under this head comes metallo-therapy, which is soberly dwelt upon by some French writers—a scientific form of "faith cure," and the galvanic battery is not to be forgotten: especially the faradic current or the constant current with production of phosphenes by frequent reversals of the current.

Hyperæsthesia of the Retina.

This condition sometimes appears apart from any visible disorders of other tissues of the eye, *i.e.,* such as cause photophobia and with which we are familiar in the preceding pages and apart from sympathetic ophthalmia. It is sometimes the effect of exposure to extreme light, and it follows prolonged seclusion in darkness, which will naturally be attended by impaired health.

Nyctalopia, in the sense of seeing better by dim than by a strong light, may here be mentioned. As a mere symptom it belongs to

Digitized by Illinois College of Optometry

cases of mydriasis or albinism, to coloboma iridis, and to some affections of the retina and optic nerve; it may appear with central scotoma, and with small polar cataract; such persons get on by night relatively better than by day.

We have, however, a more pronounced class of cases in whom excessive sensibility to light is the conspicuous and distressing symptom, it may be called *hysterical hyperæsthesia retinæ.*

It is found both in men and women. It is often associated with some error of refraction, and is brought on generally during an attack of illness. Light becomes unpleasant, and the patient desires its partial exclusion, until at length nothing but absolute darkness will be tolerated. One such instance is as follows: A man of active mind and good health was submitted to an operation for varicocele. During confinement to bed he amused himself by studies in mathematics. His eyes after a time gave trouble, and he caused the windows to be shaded. Anxiety about the condition of his genital organs made him morbidly sensitive, and this aggravated the growing irritability of his eyes. After he was cured of the varicocele he remained in a perfectly dark room for several weeks, and was unable to bear the least light without great distress. When he came to me he was encased in wrappings about his eyes, which he was very loth to remove. By urgency and insistance, and assurances that his fears of blindness were needless, I finally succeeded in examining and testing his eyes, and found a high degree of hypermetropia. Suitable glasses were given, and he soon gathered courage to face the light and use his glasses, and was perfectly restored. I relate this case from memory, and cannot adequately convey the extremely distressing state to which a highly educated and capable man had been brought.

An instance in a young woman, about twenty-three years of age, was so intense in its character as to be absurd. To shut out all light when going out-doors, she had constructed a visor of pasteboard, cotton wadding, and green cloth, which covered her head and face to the end of the nose, like a huge mask, and was tightly tied behind. Over this she wore a thick veil. These things were removed in a dark room, and then no persuasion could induce her to unclose her eyes. She finally consented to be chloroformed in a dark room, and while she was unconscious the blinds were thrown open, and, on waking, it was some time before she observed the increased light, and thenceforward improvement took place. She had muscular asthenopia, and there was a relapse afterward, but the hyperæsthesia ultimately disappeared.

In another case, of which I have full notes, the lady had been for eight months in darkness. When she had laid aside the wraps about her face, I succeeded, by the help of the atomizer playing on

the lids and by hopeful talk, in getting her to open her eyes, and in two hours she was able to bear the ordinary light of a room. Afterward atropia was used. There was marked conjunctival irritation and spasm of accommodation. Encouraging assurances to the patient greatly aided her recovery, and by abductive prisms, to correct muscular insufficiency, she was able to get moderate use of her eyes.

These cases, as may be seen, belong strictly to the category of asthenopia, but their predominant feature leads me to mention them in the present connection and additional suggestions as to their management are needless.

Hemianopsia—Hemianopia.

We have referred repeatedly in describing intra-ocular diseases to limitation or invasion of the visual field as a frequent and important system. It occurs in glaucoma, in optic atrophy, in embolism of a retinal vessel, in retinitis pigmentosa, etc. But it is also a symptom of ocular affections which have an intra-cranial origin, and to the discussion of these conditions we now attend. What is to be said will be made intelligible in the light of the explanations which have been given respecting the anatomy of the visual path within the brain (see p. 644). The title of the present section describes the loss of one-half of the visual field of each eye, because it is characteristic of intra-cranial affections now referred to that the lesion is a double one and that it is symmetrical. The usual condition is the loss of the right or left half of each field, the boundary line being on the vertical meridian: *hemianopsia homonymous and lateral.* (The old word hemiopia is discarded, because that signifies half-sight and our interest attaches to the half-blindness.) We also have cause of *bitemporal* and of *binasal hemianopsia,* the dividing line being central in each eye and vertical. Cases are recorded in which the dividing line is horizontal—as, for instance, in one eye the upper half, in the other the lower half was wanting,[1] or both of the upper or both of the lower halves may fail, or the defect may be confined to one eye. While cases of these types may arise from intra-cranial lesions, they are more frequently functional than organic, *i.e.*, hysterical, or they depend on causes within the eye such as partial embolism, detached retina, etc.

Excluding the purely ocular cases, we divide hemianopia into two broad classes, the peripheral and the central. Under the periph-

[1] British Medical Journal, Nov. 22, 1890. Williams, Trans. Ophth. Soc. United Kingdom, vol. xi., 190, 1891.

Digitized by Illinois College of Optometry

eral we place those arising from lesions of the chiasm and optic nerves, and the central are such as depend on injury of the tractus, the so-called primary ganglia, and the parts leading from them to the cortex.

It is conceivable that a lesion at the canalis opticus may cause hemianopia of one eye. Mauthner[1] gives cases of monocular hemianopia not due, as he thinks, to ocular but to nerve lesion—but the diagnosis is not certain. Schmidt-Rimpler[2] saw a case due to aneurism of the internal carotid near the cavernous sinus. In Mauthner's cases retro-bulbar neuritis is certainly not excluded, because negative ophthalmoscopic appearances are frequent. It is characteristic of peripheral cases that they show a structural alteration of the optic disc, either inflammation or atrophy. In rare instances no such change appears, but if not an early, it is likely to be an ultimate symptom. In central cases the contrary is most frequent, *i.e.*, the optic disc looks normal. To this rule exceptions are more frequent than is the contrary in peripheral cases, because we sometimes have to deal with cerebral tumors, and also if the tractus be damaged inflammation or atrophy may reach the optic disc. It has been noted by Mauthner[3] and Wilbrand that in case central hemianopia has existed for many years the eye whose temporal field is wanting and which is supplied by the crossing fibres will exhibit an atrophic disc and perhaps much reduced vision, while the other eye will be normal in appearance and function. Peters[4] relates such a case: A child nine months old received a blow on the head which caused right hemianopsia—when seen at the age of twenty-nine the right optic disc showed atrophy, V.=$\frac{20}{100}$—the left optic disc was normal, V.=$\frac{20}{20}$. The explanation of this fact will be seen by referring to the diagram from Henschen of the arrangement of the crossing and the direct optic fibres in the disc (see p. 651), by which the former overlie and partly conceal the latter.

Within a few years attention has been called by Wernicke[5] to a pupillary symptom which may furnish a diagnostic sign between peripheral and central hemianopsia. It is called the hemiopic pupillary inaction. The symptom has value when present, but to utilize it the patient must be in a dark room and the illumination carefully concentrated upon the extreme lateral half of the eye. Furthermore we are told by very recent observers that it is not always to be met with even in central disease. If the light be pre-

[1] "Gehirn und Auge," 1881, p. 408.

[2] "Augenheilkunde und Ophthalmoskopie," p. 137, 1885.

[3] L. c., p. 402.

[4] Deutsche medizin. Wochenschrift, p. 1097, 1891.

[5] Fortschritt der Medizin, i. No. 2, 1883. The same thing is discussed by Wilbrand, "Ueber Hemianopsie," 1881, p. 89.

Digitized by Google

cisely thrown upon the blind half of the eye, and the pupil do not contract or contract sluggishly, while if thrown upon the seeing half it responds actively, the inference is that the lesion is at or in front of the primary ganglia. If the pupil respond with nearly equal readiness in case the light fall upon either the blind or seeing half of the eye, the lesion will be located behind the primary ganglia. The explanation is that when the reflex arc for the pupil is interrupted by disease of the primary ganglia (corpora geniculata externa, pulvinar, corpora quadrigemina anteriora) or of the parts peripheral to them, the same lesion which produces the hemianopia extinguishes the pupillary reflex action and the hemianopic pupil ensues. But a more central lesion which destroys the visual function leaves intact the special fibres which convey pupillary impulses. Seguin[1] lays much stress on the value of this symptom. A case is given by Oliver[2] in which the immobility of one pupil and the sluggish reaction of the other aided in fixing the lesion as essentially peripheral, although the inaction was not hemiopic. There was a tumor of the frontal lobe which sent down a prolongation beneath the chiasm. Henschen reports some typical cases.

Bitemporal and binasal hemianopsia are explained by lesions at the chiasm. The former implies a cause operating at the front of the commissure or upon its ventral surface doing injury to the crossing fibres of each optic nerve. It may be a tumor or an exudation or deposit; it may spring from the sella turcica as a bony growth. It may be caused by fracture at the base. Tumors may form in this locality without disturbing the function of the chiasm; see case by Bull[3] in which concentric limitation of both fields and late atrophy of the optic nerves took place, but not hemianopsia; see also case figured by Henschen[4] of one tumor beneath the chiasm and another in the middle lobe of the cerebellum and whose position could not be determined during the twelve days of observation before the patient's death. A case of Weir-Mitchell's[5] was diagnosticated correctly (a cyst as large as a lemon, caused by an aneurism and attended by hydrocephalus externus—situation in the sella turcica), and see Berry in *Ophthalmic Review*, 1884, for two cases and numerous references. See also Wiethe.[6] Wilbrand,[7]

[1] Journal of Nervous and Mental Diseases, xiv., Nov., Dec., 1887. Heddæus claims priority in its discovery; see his treatise on the Pupil, 1880.

[2] Trans. Amer. Opth. Soc., 1890, p. 479.

[3] Trans. Am. Opth. Soc., 1892, p. 270.

[4] "Klinische und Anatom. Beiträge zur Pathologie des Gehirns," Upsala, 1890, Theil 1., S. 98.

[5] Journal of Nervous and Mental Diseases, 1889, xiv., p. 44, quoted by Wilbrand.

[6] Graefe's Archiv f. Opth., xiii., 3, 301, 1884.

[7] "Ueber Hemianopsie und ihrer Verhältness zur Topischen Diagnose der Gehirnkrankheiten," 1881.

Digitized by the Internet Archive in 2007 with funding from Microsoft Corporation

1881, collected sixty-four cases of lesions of the chiasm with autopsy. Very rarely is a true bitemporal hemianopsia present, because the tumor or other lesion is seldom small enough or so exactly placed as to produce the supposed effect. On the contrary we are apt to meet in one eye with total loss of sight or marked amblyopia, and temporal hemianopia in the other. There will also often be lesion of the third and fourth or other nerves, and various "distant" symptoms. In rare cases there may be hemiplegia. At some period, it may be late, there will be signs of optic neuritis or atrophy seen by the ophthalmoscope. Convulsions are apt to occur and headache is usual and severe. In basal tumors numerous symptoms arise as already said (see p. 158), and among them loss of hearing, of smell, of taste, great neuralgia, and even exophthalmus can occur.—See case by Norris, Trans. Am. Ophth. Soc., 1890.

Binasal hemianopsia has been a few times recorded, but a single case of Knapp's is as yet the only one with autopsy, and this revealed an aberrant and sclerosed artery pressing on each side of the chiasm. Similar conditions must be exceedingly uncommon. Wilbrand [1] reproduces the visual fields of three cases of bitemporal hemianopsia (Taf. VI.), one very precise and symmetrical due to fracture at the base (no autopsy), and the other two with the remaining half-fields much encroached upon above, and there were various cerebral symptoms (no autopsies). On the other hand he quotes two cases of incomplete bitemporal hemianopsia, in one of which the autopsy showed the cause to be a very large and widely diffused tumor in the sella turcica whose precise origin could not be traced and which had only partially injured the crossing fibres of the chiasm. It is proper to add that Jatzow [2] gives the visual fields of ten patients in each of whom were found small insular bitemporal defects touching the vertical meridians and less than ten degrees in area, which he explains by attributing them to neuritis at the optic foramina—in both cases signs of optic neuritis were present—and not to deeper lesions.

When we pass caudad of the chiasm to the tractus and deeper visual paths we find hemianopsia to be always lateral and homonymous—that is, it is right-sided or left-sided. It may be complete or incomplete, it may occupy one-half of each field, or one-quarter, or a small sector, or an insular area. In some cases peripheral parts of the half-fields are impaired, but the defects are always symmetrical in location and very nearly in outline. Sometimes a very small test object must be used to discover them.

We have records of cases in which both halves of each field have been invaded by successive attacks; for example, the half

[1] "Die hemianopischen Gesichtsfeld formen," etc., Wiesbaden, 1890.
[2] Graefe's Archiv f. Ophthal., xxxi., 2, 264, 1885.

Digitized by Illinois College of Optometry

Digitized by Illinois College of Optometry

O.S.



O.D.

Irregular homonymous hemianopia. Mrs. H., æt. 27, Aug., 1879. While bathing and in the water found sight suddenly impaired. Had some twitching of face and numbness of left hand. No other symptoms. In October, 1888, heard that vision is the same; health good. Cause probably a small hemorrhage—location doubtful.

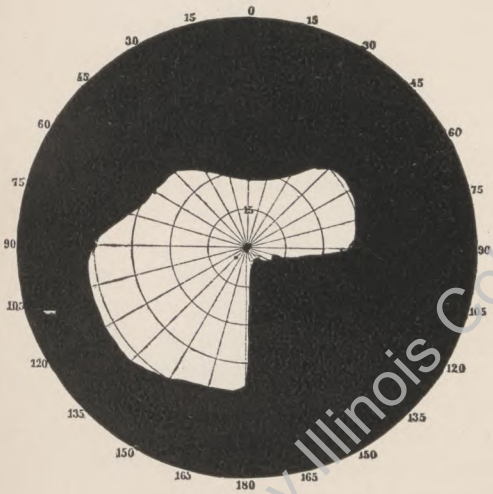

O.S. V = $\frac{20}{200}$.



O.D. V = $\frac{4}{100}$.

Mr. F., æt. 33; February, 1872. White atrophy of optic nerves. Syphilitic. Had brain symptoms, but localization not practicable.

Digitized by Illinois College of Optometry

of each field, and at a subsequent time a part of the remaining half, leaving perhaps a quarter of the totality of each field intact. Several such cases are quoted by Wilbrand, and he instances a number where total blindness was thus produced. But the most interesting occurrences of this nature are described by Förster[1] and Schweigger.[2] In Förster's case a man who became hemianopic on the right side from apoplexy again became hemianopic, but on the other (the left) side, by a second apoplexy five years later. At first inspection the patient seemed completely blind, but there was a little activity of the pupils to light and he could very slowly read S. 1½ with each eye—while V = $\frac{1}{10}$. It was also found that he had a central field of 2½° to 3° in each eye below the horizontal meridian. There was no perception of color. In Schweigger's case there was a similar central field about 2° to 3° in diameter, V $\frac{9}{12}$ and $\frac{5}{36}$ in the respective eyes and color perception good. Two other well-observed cases have been reported, one by Groenow,[3] another by Berger.[4] In the former the fields were larger, oblique, and like the figure 8 in each eye—color sense good. There was loss of visual memories and of localities, which implies a lesion in the lateral part of the occipital lobe.

The variations in position and direction and character of the boundary between the blind and seeing portions of the fields call for some notice. Sometimes the field is cut into two exact halves upon the vertical meridian; again there is a semicircular notch at the macula reaching over into the blind side; again the boundary line is oblique or sinuous or it may be in part on the meridian and in part not. In all cases of inequality of the two sides of the field the blind portion is the smaller. The fact is very important to the patient that a slight portion of the blinded side remains unhurt, because it enables him in case the right half is gone, to read with much greater ease than would otherwise be possible—because he can anticipate the coming letters as we habitually do.

The explanation of this circumstance includes the explanation of the preservation of the very small central fields noted in cases of hemianopsia attacking each side of each eye in succession (Förster, Schweigger). Förster assumed the existence of a special blood supply from the pia mater at the cuneus for the region corresponding to each macula, but both Wilbrand and Henschen with more probability attribute the fact to the existence in each cuneus of cortical structures representing each macula, or those parts in each retina adjacent to the vertical meridian which give what

[1] Graefe's Archiv f. Ophthal., xxxvi., 1, 1890.
[2] Archiv f. Augenheilkunde, 2 and 3, S. 336, 1890.
[3] Archiv f. Psychiatrie, xxiii., 339.
[4] Breslau Arztlich. Zeitschrift, 1885.

Digitized by the Internet Archive

Wilbrand calls the overlapping area. This means in other words that in all such cases each macula receives fibres and cortical impulses from each cerebral centre.

A careful study of cases shows that the presence or absence of an overlapping area has no relation to the portion of the visual tract whose impairment causes the hemianopsia, *i.e.*, as Gowers says, no localizing inferences can be drawn from the varieties of the boundary. Wilbrand (l. c., p. 47) remarks that the papillo-macular bundle is of dissimilar size in different cases, and this evidently has relation to the extent of an overlapping or common area in the central region of the retina.

Before proceeding further it remains to be stated that we find in addition to the hemiopic loss of light sense two other conditions, viz.: first, cases in which there is half-blindness for color with preservation of light sense, *i.e.*, hemi-achromatopsia; and second, cases of visual hallucinations affecting only one-half of each field. The former, viz., the hemiopic loss of color sense, has been found to be confined in a few cases to one eye, which proves that it is not always due to a cortical or subcortical lesion. Siemerling (see Wilbrand, l. c., p. 144) reports loss of light sense in one-half of one field and only loss of color sense in the corresponding half of the other field. Usually both eyes are affected, and the same is true of the hemiopic hallucinations. Both these conditions may exist together, as shown by Wilbrand [1] in a case of a small clot in the subcortical visual region near the posterior horn of the lateral ventricle. See also case by Putzel. [2] Swanzy [3] enumerates eight cases, and in one autopsy showed an old clot in the visual tract of the occipital lobe below the posterior horn of the lateral ventricle.

We may now take up the consideration of hemianopsia caused by lesions of the tractus and deeper parts. The optic tract for about one-third of its course lies exposed at the base of the brain, but then passes under the edge of the temporo-sphenoidal lobe and winds up obliquely around the crus. It is also crossed by the third nerve. Being thin and flat and narrow it is of course most likely to be totally rather than partially damaged by a lesion. Yet an instance of partial injury is given by Marchand [4] due to a glioma in the right temporal lobe near the gyrus hippocampi, which pressed upon its edge only, and caused loss of homonymous quadrants of the fields; there was slight double optic neuritis. See also case by Norris, l. c. It is naturally unlikely to be the seat of hemorrhage because of its small size, yet such cases are recorded

[1] "Die hemianopischen Gesichtsfeld formen," etc., 1890, p. 56.
[2] New York Medical Journal, Aug., 1890, Jan., 1891.
[3] Trans. Ophth. Soc. United Kingdom, ix., p. 23, 1889.
[4] Graefe's Archiv f. Oph., xxviii., 2, 64, 1882.

Digitized by the Internet Archive

(Wilbrand), and its vascular supply from the pia mater is common to it and the chiasm and not associated with that of the crus. It may be damaged by tumors proceeding from the base of the skull, or from the adjacent crus or temporo-sphenoidal lobe. Norris[1] gives a case of blindness of one-fourth of each field explained by a glioma in the temporo-sphenoidal lobe, pressing on the tractus. For other cases of tumor in this region, see Wilbrand, "Ueber Hemianopsie," p. 93. It may also suffer from localized meningitis. Lesions at the base may involve other nerves, especially the third, the fourth, branches of the fifth and the sixth, while facial and auditory and deeper nerves have also been noted to be affected. The functions of the crus may be impaired, causing hemiplegia as the result of a tumor in the temporo-sphenoidal lobe. There may be hemianopsia with hemiplegia, hemianæsthesia, and impairment of the lower facial and the hypoglossus, and the cause may be either in the crus or in the internal capsule, more frequently in the latter region. If the above symptoms be combined with oculo-motor paralysis of the opposite side the lesion will be in the crus.

Lesions of the tractus may ultimately be attended with signs of optic nerve atrophy, or with neuritis when caused by tumors. Some stress is laid upon the quality of the half-blindness. It is not a gray or dark appearance, but is said to be an absolute absence of all sense of light, which is not the fact in cortical half-blindness. The hemiopic pupillary inaction will exist. What has been said of the symptoms of tractus lesions applies in great measure to all the primary ganglia, and we can almost never succeed in declaring which of them are involved. Henschen[2] and Wilbrand give histories and autopsies of cases where the several ganglia were diseased, but no clearly significant symptoms can be elicited. What most conspicuously presents itself for solution is the nature of the lesion, and the general localization near the primary ganglia is usually all that is possible. In Oliver's case a careful analysis of all the symptoms of such a lesion is made, and the diagnosis proved correct (Trans. Am. Oph. Soc., 1890, p. 479). The near vicinity of the internal capsule excites various motor symptoms, spasmodic or paralytic, as well as disturbances of the several varieties of sensation. Lesions of the optic radiation and of the cortex are now more readily recognized than formerly. Hemianopsia may occur from direct interference with the visual path and cortex or as a remote symptom. It is sometimes temporary at the outset of an apoplexy in the cerebrum (Gowers). When the course of the optic radiation and its precise form and size as deduced by Henschen, and the nearness of its approach to the pos-

[1] Trans. Am. Ophth. Soc., 1890, p. 470.

[2] L. c., Zweiter theil, s. 267.

Digitized by Illinois College of Optometry

terior horn of the lateral ventricle, are considered, we can understand how readily it may be encroached upon from all sides. We also bear in mind that while the calcarine fissure is signalized as the focus, so to speak, of the visual fibres, the whole of the cuneus and the angular gyrus and adjacent occipital gyri are the seat of visual memories, and that when they are damaged hemianopsia may occur because the influence of the lesion may reach farther than is apparent. In cortical hemianopsia we often have aphasia and mind-blindness, especially if the lesion be on the left side. The symptoms suggest lesions along the middle cerebral artery running through the fissure of Sylvius (see Fig. 242). The aphasia is due to the mind-blindness being amnesic, because words recall no memories, and therefore correct speech is impossible. There may of course be alexia and also agraphia. There may be monoplegias of various types, convulsions, athetosis, hemichorea, and various distant symptoms, and they happen also in the lesions near the primary ganglion. The diagnosis of cortical or subcortical hemianopsia is not always easy, but is founded upon the pupillary symptom of Wernicke and upon the absence of hemiplegia and other signs referred to above which appear usually in connection with lesions of the pons, the crus, and the internal capsule.

It often happens that besides the hemianopia there is peripheral limitation of the remaining half-fields. A marked illustration is the case reported by Oliver (l. c., Trans. Am. Oph. Soc., 1890), where the remaining half-fields are extremely reduced. This is explained by the general disturbance of the brain oppressing the visual tracts. Analogous to this condition is the peripheral limitation without hemianopsia, observed with tumors located in various positions not near the visual paths. There may be no optic neuritis to account for it. Such a case is figured by Henschen, Taf. XXXI., and others, and he remarks that these peripheral limitations have no special significance. They are found with tumors, and also with softening. Henschen gives the restricted fields in several cases where there was softening in the occipital lobes. Wilbrand [1] gives the fields of a case of lesion of the internal capsule in which the original conditions showed extreme limitation besides hemianopsia, and after twelve months, recovery so far took place as to leave only a quadrant of each field defective. He also gives the fields of the same case taken by less acute and patient observers before he made examination, and shows how the extreme difficulties belonging to such patients make errors very likely. He justly suggests that imperfect examination, probably explains the erroneous inferences of Charcot as to the occurrence of crossed

[1] "Ueber Sehstörungen bei functionellen Nervenleiden," 1892, pp. 47–54.

Digitized by the Internet Archive

amblyopia in lesions of this region. His assumption of a double crossing of the visual paths has no anatomical foundation.

Diagnosis.—We have to consider the position of the lesion and also its character. What has already been said gives hints in regard to locating the lesion, but it is evident that hemianopsia in

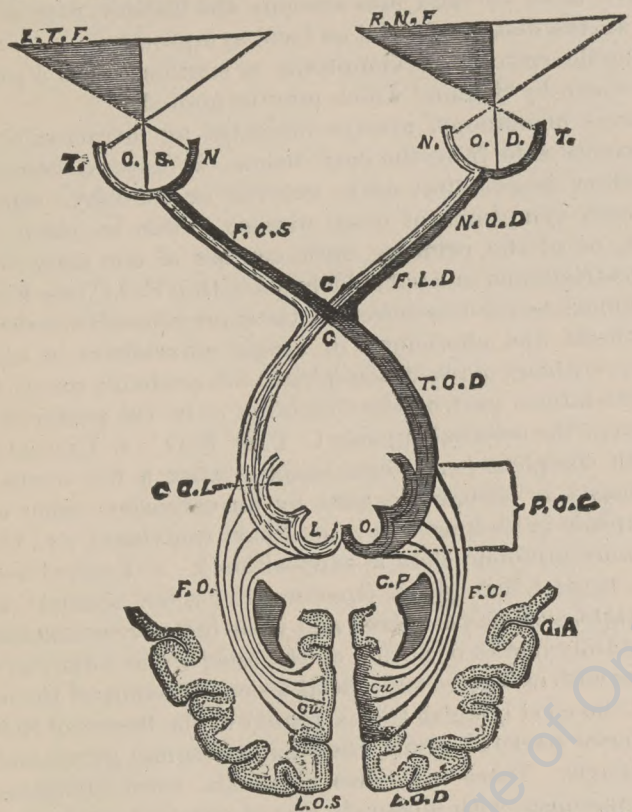

FIG. 258.—Diagram (from Seguin) to illustrate Left Lateral Hemianopsia. *LTF*, left temporal half-field; *RNF*, right nasal half-field; *OS*, oculus sinister; *OD*, oculus dexter; *N. T.*, nasal and temporal halves of the retinæ; *NOS*, nervus opticus sinister; *NOD*, nervus opticus dexter; *FCS*, fasciculus cruciatus sinister; *FLD*, fasciculus lateralis dexter (fasciculus non-cruciatus dexter); *C*, chiasma or decussation of fasciculi cruciati—(commissures of Gudden and Meynert are omitted); *TOD*, tractus opticus dexter; *CGL*, corpus geniculatum laterale (corpus geniculatum mediale and the brachia are omitted); *LO*, lobi optici (corpora quadrigemina); *POC*, primary optic centres (including corpora quadrigemina, corpora geniculata and pulvinar of thalamus opticus); *FO*, fasciculus opticus, radiating visual fibres of Gratiolet in the internal capsule; *CP*, cornu posterius of lateral ventricle; *GA*, region of gyrus angularis; *LOS*, lobus occipitalis sinister; *LOD*, lobus occipitalis dexter; *Cu*, cuneus and subjacent gyri constituting the cortical visual centre in man. The heavy and shaded lines represent the parts connected with the right halves of the retinæ.

itself alone does not point to a definite locality. It must be interpreted in the light of concomitant symptoms. The nature of the lesion must at the same time be considered. Apoplexy, embolism, softening, tumor, gummy exudation, sclerosis, meningitis, tubercle,

Digitized by the College of Optometry

aneurism, etc., these are to be passed in review. Moreover, we may have multiple lesions, viz., several tumors or hemorrhages or spots of softening, etc. We likewise have to look for remote disease, albuminuria, diabetes, heart disease. Sometimes a retinal lesion will give us light on this point, viz., spots of exudation or of hemorrhage. We have to take into account the history, rate of progress, and all the distant as well as focal symptoms.

A valuable epitome of symptoms is summed up in a series of rules laid down by Seguin,[1] which may be quoted.

1. Lateral hemianopia always indicates an intracranial lesion on the opposite side from the dark fields. 2. Lateral hemianopia with pupillary immobility, optic neuritis or atrophy, especially if joined with symptoms of basal disease, is due to lesion of one optic tract, or of the primary optic centres of one side, *i.e.*, the corpora quadrigemina and parts included within P.O.C.(see Fig. 258). 3. Homonymous sector-like defects of the same geometric order, with hemianæsthesia and choreiform or ataxic movements of one-half of the body, without marked hemiplegia, are probably due to lesion of the caudo-lateral part of the thalamus, or of the posterior (caudal) portion of the internal capsule C. P. or F. O. 4. Lateral hemianopia with complete hemiplegia (spastic after a few weeks) and hemianæsthesia, is probably caused by an extensive lesion of the internal capsule in its knee and caudal part (pulvinar), *i.e.*, farther back and more profound than in supposition 3. 5. Lateral hemianopsia with typical hemiplegia (spastic after a few weeks): aphasia, if the right side be paralyzed and with little or no anæsthesia, is quite certainly due to occlusion of the middle and adjacent cerebral arteries with extensive superficial lesion, softening of the motor zone and of the gyri lying at the extremity of the fissure of Sylvius, viz., the inferior parietal lobule, the supra-marginal gyrus and the gyrus angularis. There may also be alexia, word blindness. 6. Lateral hemianopsia with moderate loss of power in one-half of the body, especially if associated with impairment of the muscular sense, would probably be due to a lesion of the inferior parietal lobule and gyrus angularis with their subjacent white substance, penetrating deeply enough to sever or compress the optic fasciculus on its way posteriorly to the visual centre. If mental blindness exists, the lesion would lie in the more anterior central parts of the occipital lobe. 7. Lateral hemianopia without motor or common sensory or any accompanying symptom is due to lesion of the cuneus only, or of it and the gray matter immediately surrounding it, on the mesial surface of the occipital lobe in the hemisphere opposite the dark half-fields. The lesion may be partial or total.

[1] Journal of Nervous and Mental Diseases, xiii., Jan., 1886.

Digitized by Google

Digitized by Illinois College of Optometry



O.S.

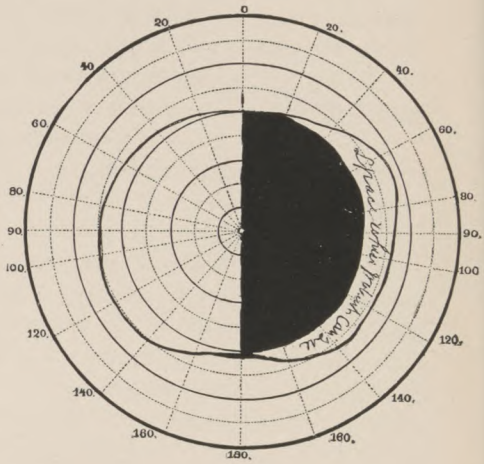

O.D.

Miss S., April, 1879, p. 644.

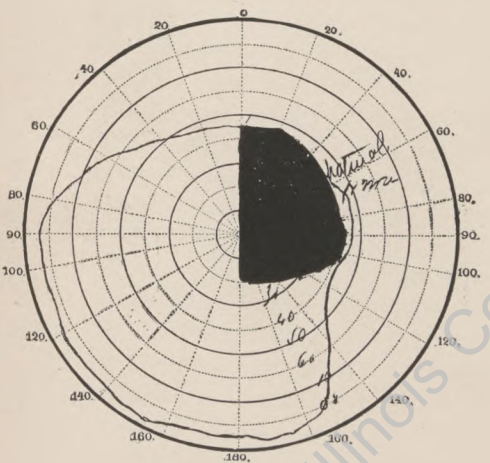

O.S.

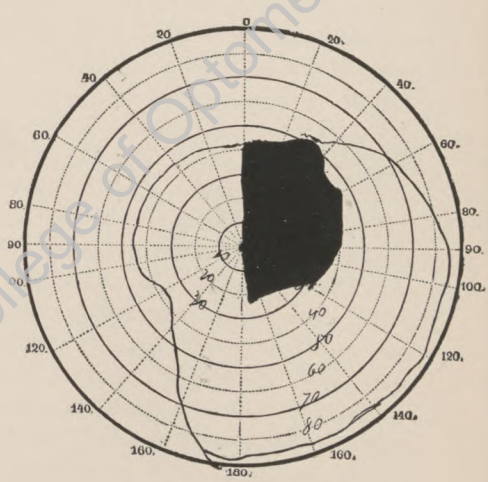

O.S.

Hemianopia. Miss S., August, 1879, p. 717.

Digitized by Illinois College of Optometry

Most surgical cases come at once after convalescence within this rule or within rule No. 6.

In all cases coming under rules 3 to 7, inclusive, the pupils react normally; and rarely does the ophthalmoscope show any lesion of the optic nerve, except of course in some tumor cases, where neuro-retinitis may be expected.

Prognosis.—Cases of short duration with perfect recovery are recorded. The defect at first complete, may after a time become less extensive. This is chiefly true in apoplectic cases. The larger number of cases remain unchanged. Prognosis depends chiefly upon the nature of the lesion if this can be made out.

Chart V. gives the fields in a case seen by myself where partial recovery occurred. The history is as follows:

Miss S——, aged thirty, came to me in April, 1879. She was forewoman in a large establishment, and, being extremely busy, had not slept well for many months. Four weeks ago she had an attack of severe pain, running from the left clavicle and shoulder to the head, which drew it to one side, and prevented sleep for two nights. Two weeks afterward she found herself totally blind on the right side. There were no other symptoms. Examination found no disease of the kidneys, nor of the heart; she had not had rheumatism. Vision in each eye $\frac{20}{20}$. By the ophthalmoscope: right disc not swollen, vessels full; near it the retina a little œdematous, and has some dots, while a bluish zone surrounds almost all the disc. Left eye about the same. Visual fields have this peculiarity: that while there is symmetrical hemianopia, perception remains on the extreme periphery of the blind sides. Treatment was iod. potas., gr. x., ter in die. After a month her condition, which had been one of great excitement, because of her impaired sight, was more calm, and she slept well, yet felt very tired. Had some numbness of the left leg and hand. Visual fields then showed a clearing up of the lower half of the previously blind portion. See charts. In August following, the fields were about the same, and in the retinæ there were fewer specks than at first. The right optic nerve was more hyperæmic than the left. Patient seen in 1882 and condition of fields the same: vision normal.

There is of course a serious question often as to life. For some recoveries of sight see Lang[1] and Wilbrand.[2] Michel[3] says that in 154 cases of hemiplegia, hemianopia occurred 59 times.

It may be said that patients are sometimes unaware that they are hemianopic, because other paralytic symptoms absorb their attention. In one instance I performed extraction of cataract for an old lady and was not made aware of her hemianopia until the time came for fitting glasses.

Treatment.—This must be in accordance with the indications of the situation and cause of the mischief. For inflammatory cases

[1] British Medical Journal, Nov. 23, 1889.
[2] "Die Hemianopsie," 1881, p. 205.
[3] "Die Lehre der Augenheilkunde," p. 607.

the iodides, for many cases bromides will be serviceable. We may have to administer to severe pain by antipyrine or opium; we may require derivatives, ice to the head, mustard to the lower limbs, dry cups to the nape or temples. We must endeavor to decide upon the nature and cause of the lesion to properly choose a line of treatment. The eye symptoms are merged in the other features of the case in most instances. In late periods strychnia injections sometimes do good.

Literature on this subject is very extensive. Among papers not referred to in the text are Starr, *Amer. Journal of Medical Sciences*, Jan., 1884; Seguin, *Journal of Nervous and Mental Disease*, 1886 and 1887; Hun, *Amer. Jour. of Medical Sciences*, Jan., 1887 (includes his famous case of partial cuneus lesion); Swanzy, *Archives of Ophthalmology*, 1891; Schweigger, *Graefe's Archiv f. Ophthal.*, XXII., 3, 297, 1876. The several treatises of Wilbrand, 1881, 1884, 1887, 1890, 1892, compose a library of information. The contribution of Henschen, of which two parts are out (Upsala 1890, 1892), is a magnificent example of exhaustive work both in original research and compilation, with spendid illustrations. See also Magnus, "Anleitung zur Diagnostik der central Störungen des optischen Apparates;" Tafel und Text, Breslau, 1892.

Amaurosis in Young Children.

It is not pretended under this head to give a nosological description of a particular disease. Many lesions of the optic nerve and brain cause loss of sight in the early period of life. The conditions may be congenital. What makes brief reference desirable is the fact that while sometimes lesions of the optic nerve or retina may be found, in certain cases none will be discovered. Moreover, there will be sometimes unmistakable head symptoms, such as fits and vomiting, headache, great excitability, or contrariwise stupor, or unconsciousness; there may be motor disturbances in wasting of the muscles of the face or limbs, paresis or paralysis, hydrocephalus, etc. Hereditary tendencies must be investigated, and especial care given to search for syphilitic or tubercular, or meningineal symptoms. Many cases are and remain blind, but on the other hand partial and even complete recoveries are by no means rare, and for useful observations on this subject see Vol. IV. of Trans. Ophthalmological Society of United Kingdom, 1884, papers by Mr. Nettleship. See also reference under head of retro-bulbar-neuritis.

Undiscovered Monocular Blindness.

It is not very rare to have a patient tell of sudden loss of sight in one eye, discovered by accidentally closing the other. He nat-

Digitized by the Internet Archive

urally supposes the condition to have been suddenly produced; examination may find complete optic nerve atrophy or choroidal lesion, or extreme hyperopia, myopia or astigmatism, cataract, etc., none of which can be recent. Such states of vision often exist with strabismus.

On the other hand, total blindness may take place in one eye without immediately attracting the patient's notice, especially if there be some high optical error. An incident[1] of this kind took place in a young girl who was myopic 13 D, and in one eye suddenly found, on closing the other, that she had no perception of light. Treatment by artificial leech and tonics was followed in two months by restoration to her previous condition. She was not hysterical, had no cause for deception, and no explanation was found by the ophthalmoscope. She had had severe headache for six months; catamenia were irregular.

Simulated Blindness.

In countries where military service is compulsory, persons sometimes seek to escape it by pretending to partial or total loss of sight in one or both eyes. Such malingering is also practised to secure pensions or to obtain compensation after the receipt of injuries, and it sometimes presents itself as the expression of a perverted imagination, among children and hysterical persons. Pretence to total blindness is uncommon; to blindness more or less complete in one eye (the right) is the usual claim. It is common to find great exaggeration of an existing visual defect due perhaps to opacity of the cornea, to myopia, to irregular astigmatism or hyperopia or to congenital amblyopia, etc. The unexpected discovery of the need of strong convex glasses is sometimes coincident with an injury and will give plausibility to the claim that the condition is entirely traumatic.

A striking instance came under my care in a man 45 years old with hyperopia 3 D, who had never used or needed glasses, and was wounded in the left eye by a piece of glass in a railway collision. The wound was through the ciliary region and severe. It was necessary to perform iridectomy, and the patient suffered much. His real suffering was in my judgment far less than he wished me to believe it to be. During a treatment extending through several months, his pain and intolerance of light and grimaces of agony were so disproportioned to the pathological conditions that I felt sure he was practising deceit. A suit for damages against the railroad company and an effective exhibition of his hypocritical symptoms before the jury, brought him the handsome sum of $7,000. A month later he came to me with much candor to show how remarkably well was his eye and free from trouble, while with

[1] Dr. H. Derby, Boston Medical and Surg. Journ., Feb. 7th, 1884, p. 126.

proper correction by a spherico-cylindric glass vision was $\frac{20}{30}$ and it had been the same before the trial of his suit in court. His vision continued equally good for three years.

It is difficult to unmask the pretence of total blindness. One must have opportunity to watch the person without his knowledge. By the ophthalmoscope nothing abnormal will be seen. The action of the pupils will be noted, and one will be ready to suspect fraudulent use of a mydriatic if dilated pupils fail to expand a little more when the eyes are in shadow, it being assumed that no lesion of the fundus exists. The disposition of the pupils to contract upon convergence of the visual lines will be remembered.

A person totally blind has a manner and carriage of the head which are characteristic. If blind for a long time he has usually acquired confidence in the guidance of another person and will walk briskly when led by the arm. He will carry the head erect, often thrown a little back or to one side. If told to look at his own hand he will attempt to do it, and by strenuous insistence of voice and placing his hand in front of the face he will look not far from its true position by the help of general sensation. A malingerer will not be likely to act thus. He will profess entire inability to look toward his own hand, and will assert his entire helplessness. This stamps his hypocrisy. One may flash the direct light of the sun for an instant into the eye and mark the effect. It is not usual for skilful malingerers to pretend to total inability to see light. They know that this is unnecessary for their purpose. Hence the detection of their fraud, if both eyes are claimed to be imperfect, must be made by setting a watch upon their behavior and endeavoring to surprise them when off their guard.

For detection of simulation of blindness in one eye we resort to various devices. Let a prism be put before one eye with its base vertical and oblige the person to walk some distance. He will be obliged to shut one eye to escape the confusion of double vision if stones and steps are in his way. Going downstairs will be a sharp test when wearing spectacles of this sort. Viewing a candle flame at twenty feet through prisms each say 7° with bases outward will lead to convergence of the visual lines to unite the images, and the action may be discovered by the observer.

A prism of 5° may be placed with its apex across the middle of one pupil and thus cause monocular diplopia, using for the purpose the good eye and screening the other. When the person is acquainted with this phenomenon and admits its existence, a trifling movement of the prism to cover the whole pupil and the simultaneous removal of the screen is likely to be followed by the admission that double images are still present, and the fraud is disclosed, because two eyes are now being used (Alfred Graefe).

Digitized by Google

Snellen arranged a series of letters to be hung in the window and alternate letters are made red or green by shifting behind them a piece of red or green glass. The person examined views the letters through spectacles of which one side is green and the other red. As the letters are altered in color, the green will be invisible to the eye wearing the red glass, and the red invisible to the eye wearing the green glass. Stilling's colored letters may be used for the same purpose. If the pretended blind eye can see green letters through a red glass, the person lies. The red glass will be over the good eye and plane glass over the assumed bad one.

One may use strong convex and concave glasses to view distant print; putting a plane glass before one eye and by a reversible frame make the person use unconsciously his bad eye.

The stereoscope can be utilized in various ways. The person's eyes must be exposed constantly to view and he must not see beforehand the cards put into the slide. On one side may be the letter L and on the other F. Combined they make E, and if this be admitted the case is proven. Other figures and marks may be used which differ on the two sides and by several trials success may be achieved.

Harlan puts before the pretended blind eye a plane or weak concave glass, — 25 D, and before the good eye a strong + glass, say + 16 D. If the patient read the distant test type he convicts himself.

With hysterical persons and children pretended blindness may be the effect of self-deception. Occlusion of both eyes by plasters or a bandage as a means of cure, is likely after a sufficient lapse of time to have this result. One may make a hypodermic injection into the temple of a minute dose of strychnia, using say three drops at a time, twice daily, of a solution gr. i. ad ℥ i. The acupuncture will be more effective than the strychnia. Some hysterical persons have a deliberate purpose to deceive, and the claim of poor sight must be judged in the light of other symptoms. I once cured a young girl of excessive photophobia by subjecting her to chloroform and on recovery she was fully able to face the open windows.

Digitized by Illinois College of Optometry

CHAPTER XX.

THE ORBIT.

Anatomy.—The cavity which contains the eyeball is a quadrangular pyramid, in which we distinguish the base or opening, the four walls, and the apex. The angles of the base are rounded, and the infero-temporal angle is at a lower level than the infero-nasal angle. In other words, the upper and lower sides have a slope downward toward the temple. The edge is somewhat sharp on three sides, because it overhangs the interior surface. On the fourth, viz., the internal side, the edge rounds off and slopes toward the median line. The orbital margin is capable of great resistance, because the bone is dense, and is buttressed by the zygomatic arch, which expands into the malar bone, and by the arch of the frontal bone. On the medial side, where strength is not needed, the bones are very thin, but their celluloid arrangement gives great capacity for dispersing the force of shocks. On the wall of the inner margin we have the groove in which is lodged the lachrymal sac, in front of which is the insertion of the orbicularis, and behind which is the insertion of the tensor tarsi. This edge is formed by the ascending process of the superior maxillary, which joins the nasal process of the os frontis. The groove for the lachrymal sac is mostly channelled out of the lachrymal bone. At the supero-nasal angle the supra-trochlear arteries and veins are found, and a little behind the edge is the loop through which passes the tendon of the superior oblique (trochlearis) muscle. At the distance of from six to ten millimetres from the supero-nasal angle we have a foramen, or, it may be, a notch which gives passage to the supra-orbital nerve, and to a small arterial twig. Beyond this the edge overhangs the cavity more decidedly, until at the supero-temporal angle we find behind it a decided fossa, in which is lodged the lachrymal gland. Passing around the outer to the lower border, we find, a little inside the middle of the latter, the region where the infraorbital nerve emerges. It comes out of the bone about eight millimetres below the edge. The orbital margin is composed of the superior maxillary, the frontal, and the malar bones. The prominence of the frontal sinuses makes this the most elevated part of the region of the base, while at the temporal side the bone is thickest and most

Digitized by Google

dense. The inner wall of the orbit is smooth and polished, presenting the surface of the os planum of the ethmoid, and here we have two foramina in the suture between the os frontis and the orbital lamina of the ethmoid; the anterior foramen gives passage to the nasal branch of the ophthalmic nerve into the skull, and the latter to an artery into the nose. The superior wall, or roof, of the orbit is slightly concave and smooth. Immediately next to it is the levator palpebræ superioris; it is very thin, and at its anterior and inner part it separates into two layers, between which is the frontal sinus. The surface of the outer wall is nearly flat, inclines outward from the median plane, and is composed of the greater wing of the sphenoid, and of the malar bone. The inferior wall is thin, and furrowed by the groove for transmission of the infraorbital nerve; below it lies the antrum. Between the outer and the inferior walls, at their place of junction, is the spheno-maxillary fissure, which sweeps from without and below, inward and upward in an imperfect right-angled bend, bounding the posterior part of the body of the superior maxillary bone, and opening into the muscular mass and the vessels which lie about the pterygoid process. It is through this fissure that a cut is made in excision of the upper jaw. The fissure is sometimes called the inferior orbital. At the angle of junction between the superior and outer wall is another fissure, shorter than the preceding, which separates the lesser and greater wings of the sphenoid, and is called the superior orbital, or sphenoidal fissure. It gives passage to all the motor nerves of the eye, to the ophthalmic nerve, and to the ophthalmic vein, while it has upon its cranial side the cavernous sinus, and is occupied by dense connective tissue, which shuts up the aperture firmly. At the apex of the orbit, above the inner end of the sphenoid fissure, is the optic canal or foramen, which perforates the sphenoid at the junction of its wings with its body. The canal is cylindrical, is rather larger in front than behind, *i.e.*, funnel-shaped, is from eight to nine millimetres long, and about six millimetres in diameter on the average. Its course is from below and outward, upward and to the median line, and the canals of opposite sides converge to each other. Posteriorly they open into the middle cranial fossa. The canal contains the optic nerve and the ophthalmic artery. The sphenoidal fissure running outward, and the spheno-maxillary fissure running downward and outward, meet and become continuous with each other just below the optic canal. These fissures are of variable length and breadth; they may differ on the opposite sides of the same person, and usually grow larger in later life. The spheno-maxillary fissure contains fat and connective tissue, and some vessels which communicate with the internal maxillary.

Digitized by the Internet Archive

The dura mater adheres to the sphenoidal fissure and to the optic canal very firmly. It clothes the surface of the optic canal, and, curving forward, is continuous with the outer sheath of the optic nerve and with the periosteum of the orbit. There is also an inner sheath of the optic nerve which is continuous with the arachnoid, and which at the optic canal is firmly attached to the outer sheath by meshes of connective tissue. In many cases this meshwork is sufficiently open to permit fluid to be injected from the cavity of the skull into the space between the two sheaths of the nerve, as was proven by Schwalbe. But this is not invariably possible, and in all cases the optic nerve is so closely attached to the wall of the bony canal that it cannot be pulled away from it. Schwalbe says this adhesion is most intimate at the upper part of the canal. The ophthalmic artery coming from the internal carotid and about two millimetres in diameter, lies in the canal below and to the outer side of the nerve. The recti muscles and the superior oblique originate around the opening of the optic canal, the rectus externus having two roots, between which passes the third nerve. The course of the muscles and the arrangement of the oculo-orbital fascia have been described. It may be proper to refer to the so-called orbital muscle of Müller, which does not admit of demonstration, but consists of numerous fibres of non-striped muscle controlled by the sympathetic nerve in the neck. They influence to a certain extent the degree of exophthalmus or its opposite state of enophthalmus. They are found in the fissura orbitalis, the inferior or spheno-maxillary. The ciliary ganglion is referred to on p. 400.

The orbits stand to each other in such relation, that their axes form an angle opening forward of about forty degrees, whose apex would be at the middle of the anterior clinoid process of the sphenoid. The floor of the orbit slopes downward, forward, and outward; the shape of the cavity thus inclines the eyeballs to assume a position looking outward and downward. The globe is placed so as to lie nearer to the outer wall than to the inner, while the optic canal is above the level of the middle of the eye.

The remark must not be omitted, that owing to congenital asymmetry of the skull it is quite frequent to find the floors of the orbits not on the same plane. One will be higher than the other. This appears in the position of the auricles as well as of the eyes. Sometimes the action of the ocular muscles is for this cause rendered painful—hyperphoria occurring—and if not painful their unusual behavior under prism tests will be accounted for.

Digitized by Boston Medical Library

Diseases of the Orbit.

We consider: 1st. Inflammatory conditions which may take place in the periosteum, in the connective tissue, in the capsule of Tenon or oculo-orbital fascia. Inflammation may arise spontaneously or extend into the orbit from the face or adjacent cavities. The bony walls may be diseased, giving rise to hypertrophy or more frequently to caries. They may also be perforated or pushed inward by diseases in adjacent cavities. 2d. We have spontaneous hemorrhage into the orbit. 3d. It is a favorite site for the growth of tumors. 4th. We also have to consider traumatic lesions. Because situated within the orbit we might refer to inflammations and diseases of the lachrymal gland, but they have already been discussed.

There are two important symptoms peculiar to orbital diseases; one is displacement of the globe (exophthalmus), and the other is its immobility, the latter, however, may occur through paralysis of all its muscles and will then be differentiated by the co-existing ptosis.

Periostitis Orbitæ.

This appears as an acute and a chronic condition. The causes are traumatic, rheumatic, syphilitic, and so-called scrofulous. The most common are syphilitic or scrofulous, and the disease is most frequent in children. The favorite locality is the margin of the orbit, while if the walls are affected the symptoms are somewhat different and more serious. If the disease is marginal and acute there will be pain; œdema of the lids; some chemosis, beginning equatorially; and the distinctive symptom is that the edge of the orbit is very tender when pressed by the finger and there may be a tense swollen spot, highly sensitive and at a later time there may be fluctuation. I have seen this symptom in exquisite degree in cases of syphilitic acute periostitis, in which the diagnosis was perfectly palpable (*sit venia verbo!*). The chronic form is diagnosticated with more difficulty, except when nodular bony swellings appear within reach of the finger, and they may interfere with the function of the nerves or muscles, or even with the position and movements of the eye.

The disease when chronic is very tedious, lasting for months and even for years. The course of the acute affection is various. If an abscess form near the surface and is promptly opened, the case may terminate soon and without retraction of skin or deformity. But if the case be neglected or the constitution unfavora-

ble, general phlegmonous inflammation may ensue, and this result is the more likely the deeper the site of the trouble. In chronic cases we often have caries of the bone, fistulæ, retraction and adhesion of the skin, deformity of the lids, either upper or lower, and especially ectropium. Necessarily the eyeball suffers both in the conjunctiva and possibly in the cornea. See chapter on the lids.

If the disease is parietal, its recognition becomes more difficult the deeper its situation, and also more serious according to the importance of adjacent regions, *e.g.*, the roof. Besides pain, swelling of lids, chemosis, stiffness and pain in moving the eye, there will be pain on pushing the globe backward, it may or may not be laterally displaced or perhaps pushed a little forward. There will be nocturnal exacerbations of pain and perhaps rise of temperature. A deep digital exploration is of great importance to detect some spot of marked tenderness. The smaller the surgeon's finger the greater his advantage. In some cases it is allowed to make a deep exploratory incision under antiseptic precautions with a narrow blade or exploring needle. Such a condition befell a friend of mine, a lady about fifty years of age. No cause except a rheumatoid diathesis could be given.

She had constant and troublesome pain over the forehead, aggravated at night, and lasting for some weeks. It became localized over the supra-orbital notch, and was attended by swelling of the lid in that region. I ventured, after some delay, to pass in a narrow knife, and on probing reached a spot of rough bone. Pus in small quantity escaped, a fistula was established, and after many months, and persevering treatment by injections, it was closed up. It may happen, that when not evacuated in front, such an abscess, breaking down the bony tissue, shall find its way into surrounding parts, viz., into the ethmoid, the antrum, the frontal sinus, or into the cavity of the skull and brain. The consequences of these several events are readily understood. Again, caries or necrosis may take place, and when the dead tissue reaches the surface, and comes out through the formation of an abscess, a fistula ensues, and, when it heals, deformity of the skin and lids will follow, viz., ectropion, or exophthalmus, etc., of various degrees. A very notable case of this kind came to me some years ago, and was published in the Trans. Am. Oph. Soc., p. 129, 1870. The disease began at one year of age, and when I saw the young lady she was sixteen. Pieces of bone had been discharged. When I saw her, there was protrusion of the globe from the orbit, the cornea was opaque and turned downward; the upper lid adherent to the upper margin of the orbit, and fully everted; the conjunctival surface covered by thick and coarse granulations; the globe constantly exposed, and requiring to be covered by a pad or the hand. In the orbital edge

Digitized by the College of Optometry

was a deep sulcus, from which bone had been exfoliated. The other eye intolerant of light, and in a state of chronic irritation. The treatment adopted, and which was the only resource, was enucleation of the globe, removal of all of the conjunctiva, bringing down the lids to proper position, and closing the orbit by flaps of skin so as to cover it completely. The deep part of the orbit was filled by growth of connective tissue, its cavity was narrowed by hyperostosis of the walls, and there was no possibility of wearing an artificial eye.

Still another possibility is that periostitis near the apex of the orbit not causing purulent effusion may cause inflammation of the sheath and substance of the optic nerve. As we have seen on page 614, we may have from this cause sudden and total blindness, amblyopia, scotomata, etc., while ophthalmoscopic signs may be slight or wanting.

Treatment.—During the acute period, usual antiphlogistic measures, especially hot fomentations and poultices, will be employed locally, and in adults iodide of potassium will be used; in syphilitic cases, gr. xx., ter in die, or perhaps in larger amount, while in rheumatic cases, gr. v., ter in die, may suffice, but salicylate of sodium may be preferable, and proper anodynes must be given, such as antipyrine, gr. x., or bromide and chloral. Should an abscess threaten, my judgment is in favor of an early incision, always using a long, narrow knife, or bistoury, for a sufficiently deep puncture. If a fistula has formed, one must be very prudent in its exploration by a probe. Often the deep parts are readily excited to inflammation. The proper way is to secure a full external opening by dilating it, at first with laminaria probes, and later by small sponge-tents, until access is gained to the deeper parts of the sinus. Syringing with a fine tube should be practised daily, so long as any secretion is pent up, and should the parts become callous, or indisposed to heal, stimulating fluids may be introduced, but always under strict limitations of prudence as to possible overeffect. One must also know when to stop interference, lest healing be prevented rather than promoted. An attack of acute cellulitis is not hard to awaken, and is liable to be disastrous.

If rough or dead bone is felt by the probe, its situation deep and extent limited, we may simply keep the outlet patent, and use warm antiseptic injections of carbolic acid, 1 to 100, or of aqua chlorinat., 1 to 20, or acid. boracici, 1 to 25. In very old cases injections of iodine tincture properly diluted or of sulphate of zinc, gr. x., vel xx., ad ℥i., etc., are permissible. But if the diseased bone be easily accessible and of considerable extent it is to be gouged or scraped or pulled away. We may often be let into neighboring cavities—the frontal or ethmoid cells, etc. The gen-

eral condition of the patient, especially in young subjects, is to be properly cared for in administration of good food, ol. morrhuæ, iron, especially syr. ferri iodidi; giving mild mercurials, viz., biniod. hydrarg., gr. $\frac{1}{40}$ to $\frac{1}{20}$ ter in die, or corrosive sublimate, gr. $\frac{1}{20}$ to $\frac{1}{60}$, with small doses of iod. pot., the object being to bring the nutrition up to the state in which healthy tissue shall replace the dead bone. Hereditary syphilis will not be forgotten.

The possibilities of serious complications involving life are not to be overlooked in case the roof is involved, because of the near vicinity of the brain. An instructive paper on caries and necrosis of the walls of the orbit is by Knapp, Trans. Am. Oph. Soc., 1889, p. 325.

Inflammation of the Oculo-Orbital Fascia. Tenonitis.

It is not intended to refine needlessly upon the varieties of inflammation in the orbit, but we meet cases sometimes, whose distinctive features justify us in designating the above tissue as the seat of the lesion. For example, a girl, fourteen years of age, presented herself, in whose left eye was to be seen a yellowish bleb over the insertion of the rectus externus. The conjunctiva at the equator was moderately injected; the globe was slightly prominent, its movements were a little uncomfortable; pressure upon it caused pain. Such an attack had occurred twice within six weeks, and disappeared each time in less than two weeks. The girl seemed in good health, and no syphilitic or strumous taint was apparent. Such a case would seem like episcleritis, but the prominence of the eye, and its tenderness on being pressed into the orbit, located the disease farther back, and pointed out its seat to be in the ocular part of the capsule of Tenon.

It happens that the symptoms of the above case may become a little more pronounced, so that instead of a local and well-defined bleb, chemosis may begin at and surround the whole equator, and reach the cornea attended by no distinct symptoms of scleral, conjunctival, or other disease of the front of the eye, but attended by swelling of the upper lid, slight proptosis, and slight restraint of motion. Such is the picture of well-marked tenonitis. Its recognition is practicable only when the effusion is serous; its origin is usually rheumatic. Treatment should be mild, in soothing lotions and choice of suitable rheumatic remedies, according to the indications; alkalies, iodide of potassium, salicylate of sodium, etc. Mild cases will get well in a few days. Dr. Bull has recorded cases of the disease following operations for strabismus, and I have mentioned one of the same kind. Other operators have seen the same.

Digitized by the College of Physicians

Cellulitis Orbitæ.—Phlegmon of the Orbit.

This appears under the form of subacute inflammatory œdema and of phlegmon. It may be occasioned by a variety of lesions, both traumatic and idiopathic. The mildest form of œdematous cellulitis is as follows: a delicate boy, of pale skin, about nine years old, complained of dull pain about the right eye; there were no signs of ocular inflammation. After two or three days the globe began to advance from the orbit, and then I saw him. There was a little swelling, but no redness of the lid, no chemosis nor conjunctival redness; the eye stood forward several millimetres, and turned outward. There was difficulty in movement, and occasional diplopia. Pressure on the globe, when firm, was unpleasant; no hardness or tumor could be felt on pushing the finger between the globe and the orbital margin. Vision was perfect, pupil and fundus natural. The symptoms continued the same for several days and the eye finally returned to its place. Such a mild attack of cellulitis is most likely to occur, as I have found, in young and not robust children. It is not dangerous, and needs only mild external applications, such as warm infusions of opium or of chamomile flowers, or the liquor ammonii acetatis, 1 part to 5 of water.

With increased severity there may be considerable displacement of the globe, perhaps diverging strabismus, and there may be episcleritis with possible chemosis and the termination of the process be in resolution.

Phlegmonous inflammation of the orbit is either idiopathic or symptomatic. It may be ushered in with a chill and rise of temperature. There will be pain, swelling, and duskiness of the lids, especially of the upper, and the eye will advance. Chemosis of a yellowish-red color, with conjunctival vascularity, will appear; the eye will move with difficulty, and in the height of a severe attack it will be absolutely rigid; pressure on the globe may or may not make it recede, and will cause deep pain; exploration by the finger in the circumocular sulcus will find the tissues firm, tense, solid, and painful, some parts being more tumid and tender than others. This last symptom of resistant and painful infiltration of the orbital tissue is the important feature. In bad cases the eyeball becomes involved by infiltration and opacity of the cornea, and perhaps even to general suppuration. The optic nerve, the sclera, and the interior textures may in turn participate, and the end be panophthalmitis. The cases vary in severity and general features, but the above facts are the chief symptoms. Such a lesion may be metastatic from puerperal fever, remote phlebitis, septicæmia, carbuncles, or typhus fever; it is more frequently coincident with facial erysipelas, and

Digitized by Illinois College of Optometry

then is usually double, with disease of the neighboring bony walls, or with acute inflammation of the lachrymal gland. It has been observed as a complication of purulent meningitis; but in such cases there is strong reason for regarding thrombosis of the cavernous sinus or neighboring veins as the middle factor of the process.

It has been caused by thrombo-phlebitis after extraction of a carious back tooth (Vossius, Pagenstecher); it has attended fœtid nasal catarrh. It may result from caries of the parietes. In all cases of suppuration of the eyeball there is more or less orbital cellulitis.

Without external signs of eye disease, there may be danger to sight from optic neuritis, and this is to be especially watched for after facial erysipelas. In these cases there is thrombosis of the orbital vessels.

The extension of erysipelatous inflammation into the orbit is a frequent and grave occurrence. Not only may it destroy sight by optic neuritis, as I have seen and has been reported by Knapp, Spaulding, and others, but I have seen the cornea ulcerate and suppurate from its exposure during exophthalmus. If the cornea is not so severely damaged, it is liable to be hazy and render ophthalmoscopic inspection difficult. The nerve is apt to be swollen, pale, infiltrated, and its vessels extremely attenuated, in the worst cases; while in milder types congestion may exist with swelling, and the more usual phenomena of neuritis. There is naturally great risk of meningitis.

Prognosis is serious, and turns on the age, health, and habits of the patient, and on the cause of the trouble, and on the efficiency of treatment. The great majority recover.

Fatal cases through meningitis and abscess of the brain are on record. Griffith[1] reports a case fatal on the seventh day because of thrombosis of the ophthalmic vein extending to the sinuses of the dura mater and causing death by thrombus of the pulmonary artery by way of the jugular veins.

Treatment will vary according to the period when the case is seen, and with its cause and complications. For a case seen early, cold or warm applications, as the feelings of the patient dictate, and free use of leeches on the brow and temple—six or eight of them—will be judicious. When the swelling rises high, and if exploration beneath the rim of the orbit detects deep infiltration and resistance, and if the swelling of the lid be of a hard and brawny type and there be much pain, an incision should be made at the point of greatest tension and tenderness with a straight, narrow bistoury, close and parallel to the wall of the orbit and generally

[1] Ophthalmic Review, vol. iii., 1884, p. 147.

Digitized by the Illinois College of Optometry

above the eye. The knife should enter for one-half inch or perhaps much deeper, and while the point may not cut widely, the opening through the skin and fascia must be one-fourth to three-fourths of an inch in length. By this incision the tension of the oculo-orbital fascia is relieved, the vessels are unloaded, serum finds vent, and the tissues are relaxed. It is not necessary to find pus, but in case such a focus has formed, the knife must aim for it and go to any depth to reach it. My convictions are strong in favor of an early incision with sufficient external opening, as a means of arresting the phlegmonous inflammation and the formation of pus. I quite disagree with a tendency to long tarrying until pus begins to show at the surface, because meanwhile grave mischief can befall the optic nerve and likewise the cornea, as the result of tension, pressure, and contiguous inflammatory action. The wound is to be kept open by a tent of borated lint, and washed freely with warm borated or carbolated water or solution of corrosive sublimate to promote bleeding and subsequent discharge, and lotions of warm water or acetate of ammonia must be continued; or hot poultices of ground slippery-elm bark or of spongio-piline wrung out of hot water, should be kept up. The patient's general condition will modify the local treatment, because if laboring under a grave general disease, fever, pyæmia, or meningitis, there will be some hesitation about inflicting pain or incurring much loss of blood. The principles of general surgery must be our guide. When, however, orbital cellulitis and blepharitis complicate erysipelas of the face or head, incisions are to be made early, when the skin assumes the tense and dusky hue and hard feel of phlegmonous infiltration. The circulation being strangulated by the effusions, deep incisions offer the best chance of preventing the sloughing of tissue and injury to the eye. In these cases there is less danger from undue bleeding, because the vessels are choked by the infiltration.

It need not be said that in many of the complicated cases, the general disease demands the chief attention, by stimulants, supporting food at short intervals, quinine, mineral acids, etc.

It may happen that the eyeball passes into general suppuration or suppurative keratitis. For the latter, and for early stages of the former, warm fomentations are to be sedulously used. Paracentesis of the cornea, or its free division, may be required. For suppuration of the globe, where it has become tense, and is giving great pain, an incision may be made into its anterior half to evacuate the vitreous, at least in part. In these cases enucleation may be done, as I do not hesitate to do when its suppuration is primary and the affection of the orbit secondary. There are, in literature, a number of cases of fatal results following abscess of the orbit, but, discrimination must be made as to those which are associated

Digitized by Illinois College of Optometry

with other and grave disorders. For remarks on these conditions see page 545 *et seq.* An extensive abscess of the orbit, when purely local, threatens risk by extension backward to the brain, and it may also, in some cases which terminate in recovery, cause so much contraction of the connective tissue as to interfere with the motility of the eye; this has been seen to take place, especially between the levator palpebræ and rectus superior. Such mishaps are, however, uncommon, and recovery usually occurs with entire restoration of function. Impairment of sight is unfortunately not so rare, consisting in lesions of the optic nerve and retina, inflammatory and atrophic, also in intraocular hemorrhages and in detachment of the retina. Some cases of amaurosis or amblyopia do not show any ophthalmoscopic lesions, and in them the cause may lie in the stretching of the nerve, or in inflammation of the nerve behind the globe (retro-bulbar neuritis), or by exudation in its sheath. It is said, too, that by pressure, the axis of the eyeball may be temporarily or perhaps permanently altered, giving rise to hyperopia or to myopia according to the direction in which its force is chiefly exerted. But even from visual dangers, most cases are ultimately safely delivered.

Thrombosis of the Orbital Veins and of the Cavernous Sinus.

Thrombosis of the veins occurs necessarily in phlegmonous inflammation of the orbit, and does not call for special notice. The process may, however, extend to the cavernous sinus and thence to other sinuses, causing cerebral symptoms of a recognized character, according to the parts involved. When the lesion extends to sinuses on both sides of the skull, we may have obstruction to the venous circulation in both orbits simultaneously, producing bilateral exophthalmus, œdema of the lids, with severe brain-symptoms.

In case, as often happens, the venous thrombosis is of a septic quality, either by local or general infection, then we have small abscesses in the skin and tissues of the lids. There may also be abscesses in the eye muscles, and the patient is likely to succumb by purulent meningitis, abscess of the brain, or pyæmia.

We also have thrombosis of the cavernous sinus in consequence of various intracranial lesions and associated with thrombosis of other cerebral sinuses. For example, Wreden[1] elaborately gives the history of cases, one of otitis media purulenta, and another of sarcoma in the superior nasal fossa which among other severe symptoms developed thrombosis of the cavernous sinus. There will be all the signs of phlegmonous inflammation of the

[1] Archives of Ophthalmology and Otology, vol. iv., 65, 1875; vol. v., 82, 1876.

orbit, and the swelling will perhaps reach the cheek and nose; there will be exophthalmus, perhaps of both globes, immobility of the eye, mydriasis, paralysis of the 6th and 3d nerves, and great pain from irritation of the ophthalmic branch of the 5th extending over all its distribution. There will be great turgidity of the retinal veins, amblyopia, perhaps total loss of sight, or papillitis. The very severe symptoms which attend this condition, gravely jeopardize life, although one of Wreden's cases recovered. Berlin discusses the subject at length[1] and instances a case in a horse in which by unskilful phlebotomy in the jugular vein thrombosis of one cavernous sinus and other lesions took place which proved fatal. The affection is more apt to be double than single. Some spot of caries, or local phlebitis, or purulent meningitis may be the starting point. It can also originate in caries outside the cranial cavity such as removal of an epulis (Landesberg)[2] which proved fatal by this occurrence.

Tumors of the Orbit.

There is an enormous literature on this subject, and the obscurity which attends an exact diagnosis of the nature, extent, and relations of the disease, makes every case an interesting study.

In an examination, we attend first to the objective symptoms, viz., the exophthalmus, its degree, and the direction in which the eye is pushed; the mobility of the eye, whether limited in any special direction, in all directions, or not at all; the appearance of the globe, whether unduly vascular or itself the seat of a tumor or deformity. We examine the tumor as to its resistance, solidity, elasticity, fixity, or mobility, fluctuation, pulsation, its smoothness, or lobular or nodular character, and whether it move with the eyeball. We press the globe back into the orbit and note whether this gives pain, how far it will recede, and whether, in retiring, the tumor also retire or be pressed forward. We listen upon the globe and over the temple by a stethoscope for murmur or pulsation. We note whether neighboring vessels about the forehead or lids be enlarged, whether the pre-auricular or the cervical lymphatic glands are hypertrophied. We inspect neighboring cavities, viz., the nostrils, the vault of the pharynx, the frontal and maxillary sinuses, so far as they are within the means of examination. In some rare cases we explore the tumor with a hypodermic syringe. The sensitiveness of the cornea and the fundus oculi are also examined.

The subjective examination will embrace the age, sex, present

[1] Graefe and Saemisch, "Handbook," vol. vi., p. 540.
[2] Centralblatt für Augenheilkunde, 1883, p. 332.

and previous health, constitutional diseases, especially syphilis, any hereditary tendency to cancer, or its possible existence in other parts of the body; the mode in which the disease appeared, and exactly at what point, if this can be located; its rate of progress; whether the onset was somewhat sudden or gradual; whether there has been pain, or occasional attacks of inflammation; whether a tumor was noted before proptosis appeared, or vice versa. We may also examine for diplopia, and sometimes we may learn that hypermetropia or even myopia has been developed since the growth began.

The upper lid often undergoes remarkable elongation as the globe advances, while in other cases the lids are stretched apart and cannot properly cover the eye; in the latter case the cornea may become inflamed and opaque. The examination of the orbit may be made by thrusting the little finger between the globe and the bony margin on all sides as deeply into the cavity as possible, not heeding the considerable displacement of the globe, as it yields to the pressure. The object is to elicit information as to the seat of the tumor; whether it spring from the walls of the orbit, be located within the cone of the recti muscles or be outside of them; whether it be attached to the globe or to the optic nerve; whether it enter the orbit from an adjacent cavity.

Many of these questions must be left unanswered. But we can often tell by the fixedness and hardness of a tumor that it is attached with some firmness to the bony walls; then it will be outside of the muscles. If the tumor be mobile, it will to a great extent be free in the orbit, although, perhaps, partly attached. If at the same time the globe is displaced in some oblique or lateral direction, the tumor is probably outside the muscles. If the globe comes straight forward, its motions are rather restricted, although natural, and the tumor seem fitted closely into the apex of the orbit, and vision has been destroyed at an early period, which ordinarily is not the case, there is reason to locate it within the cone of the muscles and it may be an outgrowth in or upon the optic nerve. A tumor of the optic nerve, of which several are recorded, will not at first, of necessity, destroy sight, but at an early stage blindness will follow.

It has also been noted that sometimes the nerve is not pushed out straight, but has an S-shaped curvature. Deformity in the contour of the orbit, which is rare, and stoppage of the nostrils, are indications of a growth in the antrum, and it may be discovered by examining the gums and the mouth, and the cheek. The use of the rhinoscopic mirror behind the velum palati will aid us in discovering encroachments from neighboring cavities. One may also explore the roof of the pharynx with the finger *per orem*. The

Digitized by Illinois College of Optometry

nostrils must be inspected by mirror and speculum, and be examined by a long probe or by a cotton holder. It is not infrequent to find polypi, especially in the upper fossæ.

The next question is as to the nature of the tumor, and with this and the previous inquiry are bound up both the prognosis and treatment of the disease. We must often speak with caution about the nature of an orbital tumor. The factors to be weighed are its rate and rapidity of growth; the age of the subject, and his previous history; the hardness, smoothness, nodular character, mobility, compressibility, fixedness, apparent vascularity; the state of the eyeball; and the existence of murmur or pulsation; the presence of distended or varicose vessels. We can speak with some confidence respecting osseous growths by their physical characters, the slowness of growth and painlessness, and the way the globe is displaced. Tumors rapid in development, especially in young subjects, attended, too, with large circumorbital or palpebral veins, and which may or may not pulsate or have a murmur, are likely to consist largely of blood-vessels, and may also be malignant. Tumors not very rapid in growth, either smooth or nodular, more or less mobile, and not painful, offer a wide field of speculation as to their character, as between fibromata, lipomata, sarcomata, myxomata, melanomata, etc. Cysts are sometimes easily made out by obscure elasticity, partial attachment, ovoid and smooth shape, but when deep and of long duration they are only recognized by being opened.

Another class of tumors easily diagnosticated are degenerations of the lachrymal gland.

There are also found echinococci, cysticerci, congenital serous cysts, and bloody cysts.

Angiomata and erectile tumors are very likely to be associated with similar anomalies of the skin, but this is not necessarily the case—they are usually congenital. Cavernous tumors not congenital, as well as those which are, can be generally made out by observing that they greatly increase in size by hanging the head downward and forward, so as to cause venous congestion. They are apt to be contained inside the cone of the muscles. They do not have pulsation or murmur (Berlin). The distinction between pure angiomata and highly vascular malignant growths, depends on the greater rapidity of growth of the latter, their greater firmness, and that the lymphatic glands are liable to be enlarged at an early stage and the eyeball itself to be implicated. But there will often be great uncertainty at the outset of the disease.

Among the rare ocular tumors are enchondromata and cylindromata, while epithelial cancer sometimes reaches from the outer parts into the orbital cavity. For description of tumors of lach-

rymal gland and of antrum, etc., see C. S. Bull, *N. Y. Medical Record*, Aug. 24th, 1889.

Very seldom are both orbits invaded, yet this happens sometimes with ossific growths, and I have seen both orbits occupied by lymphomata in a case of Hodgkin's disease; similar growths existing in the neck and elsewhere.

The above remarks include what may be stated respecting diagnosis and symptoms. As to course and prognosis, it may be said that some tumors rapidly increase. These are the malignant forms, which will embrace various forms of sarcomata, the so-called medullary cancer, and some melanotic growths. In these cases the eye may be involved, and the tumor may extend beyond the orbit, and possibly grow to an enormous size. Pictures of such cases are found in various books (Sichel, Dalrymple, Wells, etc.). When it has reached the external surface, the tumor becomes fungous, bleeds, emits offensive secretion and odor, causes hectic fever, emaciation, exhaustion, and death. It may also produce absorption of the adjacent bony walls, and the fatal result may take place by invasion of the brain.

Fibrous, fatty, cystic, enchondromatous, and less malignant tumors grow less rapidly, and give trouble by the displacement of the eye and the injury to sight. Angiomatous and cavernous tumors have been known in a few instances to disappear spontaneously. Bony tumors are very slow in growth, but may attain great magnitude, as I have witnessed. Mackenzie depicts a skull, of which both orbits are filled by a dendritic mass of osteoid hypertrophy. Osseous growths are not painful except by pressure upon and disturbance of adjacent sensitive parts. In almost all cases of orbital tumors the exophthalmus is sufficient reason for attempting relief. The injury to sight comes by neuritis (choked disc), detachment of retina, intraocular hemorrhages, etc., but in many cases the sight remains good for an indefinite time.[1]

Tumors of the optic nerve have within late years been mentioned considerably in literature; they are, however, rare, and none have come under my notice. Wolfheim ("Ianaug. Dissert.," Königsberg, 1887) has recorded sixty-one cases of which thirty-six were sarcomata. The references below[2] may be useful. In this country

[1] Andrews, Med. Rec., Sept. 3d, 1887; Pooley, Am. Oph. Soc., 1890, p. 611.

[2] Leber in Graefe u. Saemisch, Bd. v., p. 910, with references, 1874. Willemer, Graefe's Archiv, Bd. xxv., Abth. i., S. 161, cases up to 1878. Vossius, *ibid.*, Bd. xxviii., Abth. i., S. 1882. Johnston, Arch. of Ophth., vol. xiv., p. 151, 1885. Straub, Graefe's Archiv, Bd. xxxii., Abth. i., S. 205, 1886. Schiess-Gemuseus, *ibid.*, Bd. xxxiv., Abth. iii., S. 226, 1888. Vossius, "Grundriss der Augenheilk.," 1888, S. 371. Michel, "Die Krankh. des Auges im Kindesalter," 1889, p. 525; Zehender, xxix., June, p. 208, 1891, v. Garnier. Wolfheim gives 61 cases of which 36 were sarcomata. Inaug. Dissert. Königsberg, 1887.

Digitized by the Internet Archive in 2010

cases have been reported by Liddell, 1863, Strawbridge, Knapp, Gruening, Holmes, and Johnson. The cases of the last three authors are found in the *Archives of Ophthalmology* and are included in the references below. The case by Dr. Liddell has not been known to general literature and is reported in a pamphlet in my possession. A number of text-books refer to the subject but give no new cases. The best summary of the matter is given by Michel and Vossius.

Michel refers to tubercular growths in the optic papilla, and in the orbital portion of the nerve, and in his "Lehrbuch der Augenheilkunde," S. 642, 1884, quotes a case which he had seen of a tumor upon the intra-cranial portion of the nerve and the chiasm, in a man who had elephantiasis of one lower limb.

In by far the largest number of cases the orbital part of the nerve is the seat of the growth, which varies from a hazelnut to a goose egg in size. Sometimes the nerve goes through the tumor and is spread out in it, at other times it is found upon one side of it. The tumor grows either from the dural sheath or from the pial sheath, and the stem of the nerve. From the dural sheath grow endotheliomata; from the stem, including the pial sheath and its trabeculæ, occur the greater number, which are various forms of sarcomata, viz., fibro- and myxo-sarcoma, etc. Cystoid degeneration is frequent in portions of the tumors. These growths occur in the early period of life, *i.e.*, up to puberty in about four-fifths of the cases, and nearly half of them before the age of seven years (Willemer).

Symptoms vary somewhat acccording to the size and form and locality of the growth. As a rule the progress is slow (in one case eighteen years) painless, and blindness comes very early. (The case of Schiess was in the last respect very exceptional.) Papillitis or atrophy of the nerve appears early. Exophthalmus takes place either straight forward, or a little downward and outward. Mobility is little interfered with unless the growth be large. Often the tumor may be grasped between the fingers and recognized to lie within the cone of the recti muscles. It is sometimes elastic and sometimes firm. Sometimes a diagnosis of the neural character of the tumor is possible, but if large this cannot be expected.

Treatment consists in removal, which will usually include all the contents of the orbit. Strawbridge, Knapp, Gruening, and Schiess succeeded in preserving the globe while enucleating the tumor. In the cases of Strawbridge and Knapp the eye afterward suppurated.

Relapse of the growth has been noted only once, but the period of observation has usually not extended beyond one or two years. In five of the cases reported by Willemer death occurred as the

Digitized by Illinois College of Optometry

effect of the operation. In the above cases extension of intraocular tumors, such as choroidal sarcomata and gliomata, along the optic nerve are not included, neither are orbital tumors which may envelop the optic nerve.

A résumé of the neglected case of Liddell is as follows: The patient was a young woman æt. 20, who after having had mumps had swelling of the eyelids of the left eye which lasted two or three months. About five months later, *i.e.*, in the spring of 1851, sight in this eye grew dim, and six months later exophthalmus began and perception of light was soon lost. In twenty months longer exophthalmus was so great that the lids did not cover the globe, pupil widely dilated, and eye perfectly movable. In June, 1853, inflammation began, ending in atrophy of the eyeball. In 1858, when seen by Dr. Liddell, the tumor hung down almost to the level of the nostril, was tense and elastic. Pronouncing the tumor benignant, extirpation was performed and in doing it two cysts were ruptured: the orbit was wholly evacuated. The capsule of the tumor was composed of the expanded and thickened sheath of the optic nerve, which entered at the posterior end and reappeared of unusual size a quarter of an inch from the globe. The tumor was as large or larger than a goose egg. On section it appeared to consist of a laminate tissue (fibrous) whose color was of a reddish yellow. The ruptured cysts heretofore mentioned were lined by a smooth membrane. The patient was in good health five years later, with no return of the growth. Two illustrations accompany the paper.

Treatment.—The only proper proceeding is operative removal. Certain modifying considerations are to be kept in mind. Cysts which extend too deeply into the orbit to be perfectly extirpated, or which communicate with adjacent cavities, must, after partial removal, be treated by injections of stimulating fluids. For vascular or erectile tumors in very young subjects (infants), the use of red-hot needles, or of electrolysis, to coagulate the blood, is expedient. The operation may be repeated once in two or more weeks, according to the degree of reaction and to the rapidity of growth. Such tumors cannot be safely treated by irritating injections. In adults they may be attacked by excision, aided, if needful, by the actual cautery in some convenient form, viz., hot-iron, electric cautery or thermo-cautery. Often they are inclosed by a capsule of fibrous tissue which much facilitates the proceeding. In electrolysis it is better to have both needles of platinum, the positive pole to which oxygen goes must always be of platinum, it is in this that the greater amount of albuminous coagulation takes place. For small growths the negative pole may be applied by a sponge to the temple, but when the tumor is large both needles must enter the tumor, and consequently must be about two or three inches long. It is best to coat the needles for a certain distance with collodion where it is desired not to injure the skin. The positive needle being first entered may remain *in situ* while the negative needle after being held in position a few minutes at a little distance, may be

Digitized by the Internet Archive in 2011

entered in succession at different points around the positive as a centre, until a sufficient effect is attained. Reaction is sometimes considerable and it is prudent to not attempt much at a first sitting.

An illustration of an unusually large angiomatous tumor is given in Fig. 259. The child was a patient of Dr. C. S. Bull, by whose kind permission the case is presented. Several applications of electrolysis were made, but the success was not complete. The tumor was within as well as without the orbit.

For osteoid growths the best means of removal is by the chisel and mallet, attacking them at the base by very light and numerous blows until they loosen (Knapp). But Berlin sums up his remarks

FIG. 259.

on such tumors by some pregnant observations as to what is justifiable according to the situation of the growth. He has collected 32 cases which were operated on: of these, 9 had meningitis; 8 died; of the whole number, 16 had bony growths in the roof of the orbit, and of these 6 died, a fatality of thirty-eight per cent. This shows in a most startling way, how dangerous is interference in this particular category of cases. It certainly justifies absolute refusal to operate, unless there be urgent indications and a full presentation to the patient of the risks he incurs. The reasons for operating can only be pain, the safety of the eye, and conspicuous deformity. Osteoid tumors in other parts of the orbit may be removed with success, and if adjacent cavities are opened, no great harm is done. A small gouge with a strong wooden handle is a good instrument, or one may prefer a chisel and mallet. If the

Digitized by Illinois College of Optometry

latter be used, the strokes must be gentle and the proceeding slow. Knapp reports a case of fatal ending, in a case of osteoma upon the os planum whose removal was easy and recovery perfect as regarded the wound. Meningitis took place without apparent cause, but was attributed to irritation extending from the ethmoid cells which were filled with polypoid masses.

For tumors whose relations, size, and probable character render them fit for excision, the question arises: Can they be extirpated without sacrificing the globe? If unadherent to the eyeball, even if they include the optic nerve, this is generally feasible. In 1866, I excised a fibrous tumor of the orbit without removing the globe, but sight was lost by suppuration of the cornea, consequent on extrusion of the globe by inflammatory infiltration of the orbital tissues and exposure of the cornea. The tumor was above the globe, and my incision was made through the superior cul-de-sac of the conjunctiva, which resulted in ptosis, because the levator palpebræ had to be destroyed to reach the tumor. My purpose in choosing this route was to spare the levator, but the seat of the tumor defeated my design. The proper mode of approach to such a tumor would be through the upper lid at the margin of the orbit. In the rare cases of tumor of the optic nerve, the probability of extension along the nerve into the brain makes early operation important. Being situated within the space surrounded by the recti muscles, it is manifestly proper to attack the tumor through a wound in the conjunctiva.

In removing a tumor, first decide in what way it will be most accessible. If it be decided to go through the conjunctiva, choose the side which offers the nearest approach to the mass, pass between the recti muscles by a wound as large as can be made by drawing them asunder, or detach a tendon, if needful, and tie to it a thread, so that it may afterward be recognized. Use a pair of narrow and strong scissors, curved on the flat, with rounded points, to make the first opening, then with shut blades tear away the connective tissue down to the tumor, and push the tissues apart to expose the mass. Attempt to bring it forward by a strabismus-hook, or by catching it with a sharp hook if it be tough enough to bear traction, and carefully cut away its surrounding connections by small clips with the scissors. Progress must be slow, and tissues must be torn rather than cut, as far as may be possible. If the tumor be upon the optic nerve, push a strabismus-hook behind it to the apex of the orbit, and when this has caught the nerve, run the scissors alongside of it and cut the nerve beyond the hook; then this hook, or a sharp hook planted into the tumor, will pull it round to the front, reversing the globe and making its separation from the eye very easy. In case entire or sufficient removal cannot be

Digitized by Illinois College of Optometry

accomplished within the space thus available, the globe may have to be sacrificed. Before the operation, this possible contingency must be stated to the patient, and his consent obtained. Small pieces of ice pressed into the wound, or injections of water as hot as the hand can bear, or pressure by the finger, will control the bleeding, and the wound must not be closed until bleeding has stopped.

But the method above described is suitable for a small and exceptional number of cases. In the great majority the wound will be made through the skin. It should be parallel to the margin of the orbit, over the most prominent point of the tumor, and as large as can be of any use. Rigorous antisepsis must be observed. After going through the skin, the deeper dissection is to be done as already described. If possible the globe should be spared. In case the tumor be found to penetrate adjacent cavities, it may be impossible to follow it and accomplish complete extirpation. The surgeon must decide such questions according to his own judgment or the requirements of the case. By such a method of proceeding, it is surprising how successfully a tumor may be dug out, both as regards the loss of blood and immunity of healthy parts. All bleeding must be arrested before the wound is closed; it must be cleaned with solution of corrosive sublimate, 1 to 3,000, with a bulb syringe. Close the wound by fine silk sutures, dress the surface with a rag smeared with simple aseptic cerate, put over this a mass of absorbent cotton soaked with sublimate solution, and retain all by a flannel bandage which shall exert firm pressure. Generally an anodyne will be needed. The wound will not be opened, if pain and reaction be moderate, until after forty-eight hours.

Complete evacuation of the orbit ("exenteration") is called for when the eyeball is implicated in the growth, has already been destroyed, or when the tumor cannot otherwise be removed. It may be that only an ordinary enucleation may be necessary, and this be followed by excision of the tumor and nothing more. But other cases arise in which the orbit must be emptied of all its contents. In doing this, the lids are split asunder at the outer angle; the coverings of the mass are to be picked up and cleaned off until its surface is fully in view; then, with a blunt instrument (the scissors before mentioned, with shut blades, are my usual resort), insinuate between the tumor and the wall of the orbit at the most convenient point, and tear and push away the parts, keeping in contact with the bone until a way is made to the apex of the orbit. I strongly deprecate the use of knives in such an operation. The principal hemorrhage will occur at the apex of the orbit, and can be best arrested by prolonged pressure with the tip of the finger. When such an operation has been done for malignant disease, the walls of the orbit are sometimes washed with solution of chloride of zinc,

Digitized by the Internet Archive of Ophthalmology

or smeared with a paste of this substance. If freely applied, a scale of bone may, in consequence, be exfoliated, and serious risk is incurred of meningitis; but, done not too vigorously, greater security against recurrence of the disease is gained, and without dangerous risk.



FIG. 260.

The cavity should be copiously washed out with sublimate solution, packed with absorbent cotton similarly soaked, and the whole kept wet under the flannel bandage. The packing may be left for four to seven days without removal, until incipient suppuration requires it. Healing will ensue in four to eight weeks.

Still more serious measures may sometimes be called for when not only must the contents of the orbit be removed but the eyelids also be sacrificed. Such a necessity has occurred to me several times, and a recent instance is a patient who furnished the adjoining illustration, Fig. 260. The picture there presented was his appearance after a flap operation in 1880, rendered necessary by the removal of epithelial cancer of the inner portion of both lids and of parts about the caruncle. There was no return of the disease for five years, when it reappeared in the flap which had been taken from the forehead. It gradually extended until all the lower lid and some of the adjacent cheek, the lower half of the upper lid and the inner angle of the eye were implicated. The cornea was destroyed and the globe adhered to the upper lid. In October, 1889, I removed all the diseased parts, including the globe, found the disease had penetrated the ethmoid cells, which I had to open and scrape as clean as was possible, and then was obliged to shut up the orbit by a flap of skin brought up from the cheek which met the remnant of the upper lid. The available tissue was scanty and I was obliged to cut again upon the median line of the forehead, dissect up the skin on its left side, detaching the brow from the upper margin of the orbit, and by pushing down the integument, a half inch was gained that sufficed to reach the flap from the cheek. The incision shows clearly upon the picture, which was taken at the end of the third week after the operation, and it was ten inches in length, starting from the middle of the forehead and going to the ear in a curved line. After doing the operation two long strips of gauze soaked in sol. corros. sublim., 1 to 1,000, were packed into the orbit and brought down to the lowest point of the wound in the cheek. On the fourth day they were removed and very little sup-

Digitized by Google

puration in the cavity took place. The patient is comfortable if not comely (see Fig. 260). He remains well in October, 1893

Recurrent growths not infrequently demand attention, especially after excision of sarcomata, and the globe will usually have already been sacrificed. If these be not too large, say not bigger than a moderate-sized hen's egg, the mode of removal by a blunt instrument, scraping the walls of the orbit and shelling out the mass, is surprisingly easy and comparatively bloodless in many cases. It may be needful to remove a tumor as many as four times.

I have never seen cases which required resort to caustics to destroy a growth, and such occasions must be rare.

It is not unusual after successful operations, for the globe to become displaced forward, and so remain for some time. It may also happen that the muscles undergo disturbance and cause diplopia; or ptosis may follow from greater or less injury to the levator. Such disturbances will usually, in time, correct themselves. But a more serious matter is the liability of the cornea to become inflamed, both by possible exposure as swelling comes on, or as it may be bathed in secretions. Frequent washing with boracic-acid solution, 4 to 100, with sol. Labarraque, 1 to 10, the application of vaseline, and the closure of lids by rubber plaster, are the best preventives. Moreover, the sight is also endangered by the manipulations at the back of the globe and about the optic nerve. It is, therefore, not to be thought strange if the globe be saved, and sight be partially or totally lost. At the same time preservation of the form of the eye and its natural appearance is worthy of strenuous endeavor.

Prognosis as to recurrence and as to life are questions which must be decided by the facts of each particular case. In simple vascular growths, cysts, fibromata, osteoid growths and epithelial tumors, the prognosis will be either absolutely or relatively good. Nettleship reports recurrence *in loco* of a tumor fourteen years after its first removal. Sarcomata may not recur *in loco*, but in the liver or some remote organ and within one or five years. The prognosis for glioma and for highly vascular cancerous tumors is bad both as to recurrence and danger to life. The general state of the patient, the severity of the operation and the ascertained "malignity" of the growth are the factors to be considered. After exenteration it is impossible to wear an artificial eye, the lids retract and a screen is to be worn to hide the deformity.

Pulsating Exophthalmus.

Under this term are included affections of diverse nature, whose common features are protrusion of the globe and pulsation, which may be felt by pressure, and whose sound may be recognized by

the ear. The true pathological condition is various and may be purely vascular or may consist in highly vascular tumors which may or may not be malignant. It is difficult in many cases, accurately to distinguish between vascular malignant growths, or angiomata, arterio-venous aneurisms, varicose dilatation of veins, true arterial aneurisms, and thrombosis of the cavernous and adjacent sinuses. The literature of the subject is large; exact knowledge about it is small. In 1869 I tabulated the cases known to that date, where the common carotid had been tied for pulsating exophthalmus. Since then the subject has been summed up by Rivington, Harlan, Nieden, Schlaefke, and most fully by Sattler in Graefe-Saemisch, vol. VI., 744–948.

Schlaefke catalogued ninety-three cases of pulsating exophthalmus (*Archiv für Oph.*, XXV., iv., pp. 112–162), and Sattler discusses 106. To these may be added 11 more collected since Sattler's paper by Köhler, making the total 117 up to 1886. It is nevertheless a very rare disease. The cases may be traumatic or spontaneous. Out of Sattler's cases the traumatic were 59, idopathic, 32; Köhler's 11 cases were all traumatic, showing out of 102 cases about 70% to be traumatic. Of the spontaneous cases 6 occurred during pregnancy. Following injuries of the skull we have a variety of symptoms. The cases are usually rapid in development, vary in degree of protrusion, are liable to attacks of transient inflammation of the conjunctiva, and, in some cases show tokens of retarded circulation in chemosis or in swollen vessels. Hemorrhage from the nose is rather frequent and may be dangerous. It has also come from the conjunctiva. Seldom is there pain; the patient is often conscious of a pulsating bruit, and may have dizziness. Sometimes an enlarged vessel will be found, projecting at the upper and inner or at the lower and inner angle of the orbit, and it will pulsate; vision generally is unaffected; motions of the eye are natural in extent and co-ordination; there may be diplopia; in the fundus the vessels are enlarged, and sometimes pulsate. In some cases there are dilated vessels of the skin in the neighborhood of the lids. (Aneurismal dilatation of the capillaries and small vessels of the adjacent skin, which may extend into the orbit and cause protrusion of the eye and pulsation, are excluded from consideration.) Pressure on the common carotid stops the pulsation and also the bruit, both to the patient and to the examiner, while the globe retires a little into the orbit. The eye can be pressed into the orbit a certain distance, and the firmer the pressure the harder the pulsation. Stooping forward increases the protrusion and the pulsation, and is unpleasant to the patient, because of the sensation of weight. A few cases of spontaneous recovery are recorded.

Formerly, all cases having most or some of the above symptoms,

Digitized by Google

were styled aneurisms of the ophthalmic artery. Guthrie published a case of double exophthalmus, in 1803, in which, at the autopsy, he declared that there was an aneurism of each ophthalmic artery. Only one other similar has been seen, and that was in a cadaver (Carron du Villard[1]): one ophthalmic artery having an aneurism in the orbit.

On comparing the various catalogues of cases we find eighteen autopsies, which have been reported since Sattler's paper. Of these, two were cases of malignant tumor, in five cases there was no aneurism and the arteries were not diseased. There remain 11 cases of aneurism of the following varieties: In 2 cases the ophthalmic in the orbit; in 1 case the ophthalmic before entering the orbit; in 4 traumatic cases there was aneurism of the carotid in the cavernous sinus; in 3 cases carotid aneurism had ruptured in the sinus, in 1 case there was spontaneous enlargement of the carotid in the sinus. That is out of 11 cases of aneurism 8 were of the carotid in the sinus. Taking the 5 cases which were not aneurismal, in one it is thought that a small fissure of the carotid in the sinus must have been overlooked, because the vena ophthalmica was greatly enlarged and no other dilated vessels were present. In another of this group was Bauman's in which there was nothing but inflammation and distention of the cavernous, circular, and transverse sinuses, and phlebitis of the ophthalmic vein. Somewhat similar in character were the three remaining cases of the group.

Diagnosis.—The essential point in diagnosis is not so much to distinguish where a possible aneurism may be located, whether in the orbit or at the sinus, but whether the pulsating exophthalmus depends on a tumor, benign or malignant, or on an aneurism, or on inflammation of the sinuses. We may not attain certainty perhaps in this attempt, but our treatment and prognosis will be controlled in great measure by our belief in this regard.

As to vascular tumors, they are more resisting to pressure than aneurismal swellings. Their deviation from the axis of the orbit, in some lateral situation, will be important evidence of tumor; there may be some other discoverable growth in the vicinity: the development has been rather slow with a tumor, and there has been no serious injury; of course a true spontaneous aneurism of the ophthalmic artery or of the carotid in the skull would have the same features, but the further history would soon display different behavior. A malignant tumor would show hemorrhages, rapid growth, metastases, cachexia, and early death.

As to pulsating angiomata, they are less painful than malignant

[1] Berlin. klinische Wochenschrift, xxiii., S. 550, referred to in Jahresbericht über Ophthal., xvii. für 1886.

Digitized by the Internet Archive

growths, their expansibility and the probable concurrence of similar growths in adjacent parts will afford helpful suggestions.

With aneurismal swellings, or such as for a therapeutic purpose may be classed with them, the following points are to be noted: Rupture of the carotid in the sinus cavernosus is the most common lesion, and it is generally from injury. There is exophthalmus, pulsation, bruit, often audible to the patient. At the upper and inner angle of the orbit is apt to be a small soft tumor, there may be others about the opening of the orbit, the frontal veins may pulsate. Pressure on the common carotid checks pulsation. Often a varicose vessel with thick walls appears at the lower or upper angle of the median side of the orbit and communicates with facial vessels. Sometimes there is paralysis of ocular nerves, the sixth or the third, this designates the interference in the sinus. In the eye one may find distended retinal veins, atrophy of the nerve and with sudden onset there may be severe neuralgia of the ophthalmic branch of the fifth, and there is always pain. Vision may be unaffected, yet various ocular conditions are possible.

For further information reference may be made to authorities quoted, and especially, regarding the discrimination of varicose enlargements of the ophthalmic vein and its branches, and of thrombosis of the cavernous and other cerebral sinuses, to Sattler, l. c., p. 875 and p. 912.

An illustration of what was probably phlebitis of the ophthalmic veins coming from the cerebral sinuses is the following case, which occurred in my observation:

M. M., aged twenty-two, native of Ireland, single, was attacked with an illness four years ago, which kept her in bed for five weeks. She had fever, great pain in the head, nausea and vomiting; constant noise in the left ear, with some deafness, came on during the last two weeks. As she was recovering, she found on waking one morning from sleep, that the left eye was swollen, red, and protuberant. There was no pain nor loss of sight. The exophthalmus soon attained its maximum and the eye seldom gave her trouble. She had a few mild attacks of inflammation in it. It did not annoy her, except that if she stooped it would come farther out and feel very heavy. For nine months previous to the eye-trouble her menstruation had been very scanty. When on her way from Ireland to this country she stopped at Limerick, and there an attack of inflammation began, which continued until her arrival. She came to the New York Eye and Ear Infirmary on May 9th, 1881. The left eye projected half an inch beyond the other. There is some chemosis and anterior ciliary injection. Media clear, pupil normal; nothing wrong in the fundus, except that the veins on the papilla are enlarged; V = $\frac{20}{30}$. Below the eye, along the border of the orbit, is a pulsating swelling; the angular artery is much enlarged, pressure on the eye makes it recede into the orbit. By auscultation, no thrill is heard, but a low pulsating murmur. Pressure on the common carotid stops pulsation in the vessel below the globe. This vessel comes from the inner side of the orbit, and pushes out under the skin of the lower lid like a large varicose trunk.

On May 18th, patient etherized; the angular artery tied, and the protruding vessel exposed, and tied at the inner and lower side of the orbit; it was then cautiously dissected up and traced into the cavity of the orbit, until it reached the groove for the infra-orbital nerve, where it dipped down. A ligature was put about this end and the vessel excised. It proved to be a vein, and was larger than a crow's quill. No severe reaction occurred. In eighteen days both ligatures came away. In fifty days the patient was discharged. Pulsation had ceased, and the eye had retired one-fourth of an inch.

November 18th, 1881. The eye back to its proper place. The optic nerve normal; vessels of corect size; V = $\frac{20}{20}$.

Prognosis.—Very few cases recover spontaneously. Sight may or may not be preserved. A fatal issue in idiopathic cases comes from lesion of other arteries, by apoplexy or other brain lesions; in traumatic cases by profuse bleedings from the cavernous sinus, most frequently. With tumors the prognosis is what their nature indicates.

Treatment.—Sufficient time should be allowed for development of symptoms to enable one to form a fair judgment of the probable nature of the case. For a vascular, and perhaps for a cancerous tumor, if any operation were proper, it would be excision, while for a lesion of blood-vessels an attempt at such a proceeding would be most likely attended by dangerous hemorrhage and disastrous results. For vascular tumors electrolysis is not to be forgotten. Pressure on the globe is unavailable and ineffective; injections into the orbit of astringent fluids have been practised successfully, but doubtless these were cases of vascular tumor; injections of iodine have been made, but with fatal results. Pressure on the carotid by the fingers, or an instrument, has in some cases given happy results.

Sattler says, l.c., p. 926, that for idiopathic cases compression of the artery for a short time every day may succeed if kept up for weeks or months—for traumatic cases it must be unremittingly continued for three to six hours daily until all pulsation ceases. Out of 29 cases treated by compression, Sattler admits only 4 of complete and permanent cure, and 5 were improved. Nieden,[1] however, out of 12 cases thus treated reports 5 completely cured, and 7 benefited.

Ligature of the common carotid in the neck is the remedy most to be relied on. Sattler cites 63 cases, to these add 3 of Köhler's and we have 66 operations upon 61 patients; and in 17 there was no good effect or it was not permanent; in 8 death followed; in 41 the result was successful. Some among these were cases of tumor which reduced the fair proportion of successes. The good result was secured in from three to six weeks.

In 11 cases relapse followed, and for other particulars see Sattler.

[1] Archiv f. Augenheilk., viii., 127, 1879.

Digitized by Illinois College of Optometry

Enophthalmus Traumaticus.

A rare but very interesting lesion is met with, for knowledge of which I am indebted to Dr. Schapringer, who kindly permitted me to see the case and published an account of it in the *New Yorker Medicinische Monatschrift*, June, 1890. Only a few are recorded in literature, and I quote the references from Dr. S.'s paper. The case is briefly as follows: A girl seven years old was struck by a teacher in school and fell down, striking the right temple on an iron grating. She was made dizzy but not unconscious—no bleeding from nose or ear. Two hours later when she went home her mother noticed the drooping of the right upper lid and sinking of the globe. About six hours after the injury she was seen by Dr. S., who describes the following symptoms: At the temporal extremity of the right brow a black and blue spot the size of a half-dollar; the upper lid which is not swollen falls so as to cover half the pupil; in looking up the lid follows the eyeball normally; the globe has receded into the orbit about 2 mm. as nearly as could be estimated—the curve of the cornea not altered—the pupil behaves normally and is not contracted—tension of the globe decidedly lessened—blood-vessels of the retina, both arteries and veins, somewhat enlarged. Movements of eye perfect in all directions; no diplopia. No redness of skin of the right half of face or ear and no sweating. Sensibility normal on both sides, no headache. No tenderness when globe is pressed into the orbit. Vision normal. The case evidently is to be explained by a lesion of fibres of the sympathetic nerve. But what fibres? Evidently not those in the neck, which cause *contraction* of the pupil and redness and sweating of the skin of the face on the same side (Horner's observations, p. 436), added to ptosis. Neither is the twig of the oculo-motorius to the levator palpebræ at fault, because the lid and the globe would in that case not act consensually in looking upward. The ptosis, the enophthalmus, and the hypotony are accounted for by lesion of the fibres of the sympathetic which supply the orbital muscle of Müller and originate from the cavernous plexus; but the escape of the twig to the dilator pupillæ which forms one root of the ciliary ganglion shows that the injury is local in the orbit, and not severe enough to cause damage to it; while other twigs less capable of resistance have been rendered paretic by intra-orbital hemorrhage. After three days the symptoms disappeared. No account is given of the late appearance of subconjunctival ecchymosis which is apt to show itself from intra-orbital hemorrhage. Some undue secretion from the right nostril and swelling of its turbinated bone were noticed.

Other cases where the amount of injury was much more severe

are quoted; but the enophthalmus was in them attributed to cicatrization and atrophy of the orbital fat and connective tissue.

See references on p. 469 for lesions of cervical sympathetic.

See A. Nieden, Zehender, Klin. Monatsblätter, etc., 1881, p. 72.

C. Gessner, Archiv für Augenheil. (Graefe), Bd. xv., iii.; Arch. of Ophthalmology, xviii., p. 269, 1889.

Distention of Adjacent Cavities.

We must allude to affections of adjacent cavities which cause encroachment on the orbit, and chiefly the frontal sinuses, the ethmoid cells and the antrum of Highmore.

Distention of the frontal sinus by mucus or pus (*empyema*) is a chronic affection and can generally be easily recognized by the

Fig. 261

site of the swelling, which is above and farther back than the lachrymal sac, and has resisting walls. The condition may be consecutive to severe nasal catarrh, syphilis, or periostitis within its cavity. Polypus has been found in the cavity, and also small exostoses.

It is pertinent to call attention to the variable size and extent of this cavity. In young subjects it has no existence, but becomes

Digitized by Illinois College of Optometry

of notable size after thirty years of age, and beyond that period of life it may present the most remarkable variations in extent. Mackenzie has written the best chapter on this whole subject (see "Diseases of the Eye," pp. 93–121, Am. ed., 1855), in which he collects cases from the older writers. I have seen a few. The locality of the swelling will generally suggest its nature, and the wall of the sinus may be carefully opened by a strong knife. Afterward, long treatment by antiseptic and astringent injections will be required. It sometimes happens that a spontaneous opening takes place by absorption of the wall and then the appearances are those of a cyst. Fig. 261 shows a case recently under my care where the abscess opened spontaneously and its outlet can be seen above the tendo oculi of the right eye. Care must be taken not to mistake such a condition for an abscess of the lachrymal sac (see page 295).

It is also possible to mistake such a retention tumor for an exostosis because it may sometimes have a thick bony mass with irregular surface on its anterior wall. The finger must be forced deeply to disclose the error by reaching to the less resisting deep part. Great exophthalmus is sometimes produced and consequent diplopia. Sometimes there is profuse and perhaps puriform discharge from the corresponding nostril.

I have once had to sacrifice the pulley of the trochlearis muscle in operating on one of these tumors. The diplopia in a vertical sense was at first very annoying, but gradually diminished.

After operating, the secretions of the sac for a time escaped in front, but subsequently found their way backward through the middle nasal fossa into the posterior nares.

This case resembles that quoted below from Dr. Knapp.

It is necessary in all these cases to examine the nasal cavities and sometimes the cause will be found in hypertrophy of the middle turbinated bone.

Distention of the *ethmoid cells* of a similar kind is described by Dr. Knapp (see "Report of Fifth International Oph. Congress," 1877, p. 55). The patient was a girl, fourteen years of age, who had a tumor at the inner and upper corner of the orbit, resembling in all respects an exostosis. The surface of the bone was exposed by a free incision, and as a chisel was applied to its base for its removal, its walls promptly gave way and disclosed a cavity filled with stringy mucus. The opening was freely enlarged, the contents were fully evacuated, and it was found that some of the fluid used in syringing escaped from the nostril. In about a year the case was cured.

Tumors in the *antrum* press on the floor of the orbit, perhaps perforate it, and may displace the eye, and I have met with a case

Digitized by Google

in which a fibro-plastic tumor came up from the *spheno-maxillary fissure* and pressed the globe forward.

There are cases on record of congenital malformation, chiefly in the neighborhood of the lachrymal bone, and often in both orbits, by which the brain comes into direct relation with the orbit; its cerebro-spinal fluid pushes down the dura mater as a cyst, through an aperture in the bony walls.

Hemorrhage into the Orbit.

With very few exceptions, this results from injury, either by falls, blows, or penetration of a foreign body. The symptoms vary according to the amount effused. If large, there will be propulsion of the globe and ecchymosis of the lids and of the ocular conjunctiva. If the quantity be small, the eyeball will not advance, while the lids and conjunctiva will be discolored. Finally, the distinctive criterion of orbital hemorrhage of small quantity, is a tardy appearance of ecchymosis creeping down under the ocular conjunctiva and advancing toward the cornea. In some cases the lid alone is the seat of discoloration. Spontaneous cases are so very few, and their etiology so manifest, viz., scorbutus, violent coughing, etc., that we may confine ourselves entirely to orbital hemorrhage from injury. It has been pointed out by many distinguished surgeons, and is classical in literature, that this symptom indicates fracture of the orbit and most frequently of its roof. But Berlin (G. and S., VI., pp. 567–8) quotes six cases by von Hölder, where at the autopsy orbital hemorrhage appeared without any fracture of any part of the skull, as demonstrated by stripping off all the dura mater. But in these six cases there had been severe falls or blows, and in some of them there was intracranial hemorrhage. In some instances the intracranial bleeding had reached into the orbit, in other cases the orbital hemorrhage was idiopathic. As a proper offset to these observations, von Hölder furnished an account of 124 cases of fracture of the skull, in 79 of which he found fracture of the roof of the orbit, and of these 69 had hemorrhage into the cellular tissue of the orbit, and in the remaining 10, blood was confined to the vicinity of the periosteum. It follows that in cases of severe injuries (either fracture of the skull or commotion) with orbital hemorrhage, this symptom, in ninety-two per cent, indicates coincident fracture of the orbit, while in only eight per cent does it take place without fracture of the orbit.

In some cases, severe hemorrhage may find its outlet through the nose, and, perhaps, get into the stomach. This implies fracture of the inner wall and of the ethmoid cells.

Digitized by the Internet Archive in 2010

In every case of orbital bleeding, the local conditions give us anxiety, not specially on behalf of the eye and its surroundings, but because grave injury has probably been inflicted upon the skull. It may, however, happen that sight or other functions of the eye are imperilled. The bleeding may cause atrophy of the optic nerve by pressure, or laceration of the ophthalmic artery may cause false aneurism, or cut off the supply to the retina. The muscles may, one or more of them, be paralyzed. Such contingencies and others are easily possible. (See pp. 695, 696.)

Treatment consists in cold or iced-water compresses, a pressure-bandage, and rest. From three to four weeks will be necessary for removal of the extravasation. To attempt to let out the blood by an operation, when deeply situated, is useless, and likely to be hurtful. This subject is really introductory to another of which it usually forms an incident, viz.:

Wounds and Injuries of the Orbit.

Dislocation of the globe may be produced by a push with a cow's horn, by a man's thumb or finger in fighting, or by a blunt arrow, etc.; and by insane persons has been self-inflicted. I have seen it produced by a fall down-stairs when the orbital region struck against the top of the newel post. The globe was at the same time ruptured. Considerable force and tact were required to reduce it within the lids. Gouging, as it is popularly called, may or may not be attended with rupture of the muscles. The eyeball may seem unharmed, yet sight be wholly or partly destroyed by injury to the optic nerve, or by laceration of the choroid. Treatment will consist in replacement of the eye and cold-water dressings, pressure-bandage, and subsequent proceedings as the symptoms indicate.

A spontaneous thrusting forward of the eyeball outside the palpebral fissure has taken place in persons who have excessively prominent globes. It is sometimes feared in exophthalmic goitre, yet almost never realized. The upper lid can be easily slipped again in place and if required the palpebral fissure can be shortened at the outer angle by paring the edges of the lids and using a few stitches.

Wounds of the soft parts at the margin of the orbit are often caused by blows with the fist, especially when armed with brass-knuckles or wearing a large ring. It is often remarkable how clean cut and well defined the skin wound is, presenting to cursory inspection the appearance of an incised cut. It will be noted, however, that the deep parts of the skin are more extensively wounded than the surface because cut by the bony edge, that there is consid-

Digitized by Illinois College of Optometry

erable contusion and swelling, and the reaction is always greater than after a simple incised wound. Suppuration often follows.

To get rid of large clots of blood in the soft tissues, is sometimes a matter of three or four weeks; and the process of absorption may be somewhat hastened by pressure, or, if this be painful, by massage, while the surgery of the prize ring practises opening the swollen skin with a lancet. With careful antisepsis and accurate closure by the dressing of collodion and fibres of absorbent cotton this is quite permissible.

Gun-shot wounds of the orbit are common both in civil and military surgery. The most distressing cases are those in which the ball enters at the side and goes through the orbital walls transversely. It may lodge anywhere and may destroy one or both globes, or may leave each seemingly intact. Usually, the sight of one or of both eyes is destroyed, according to whether the missile enters one or both orbits. The ball has been known to go into the opposite upper jaw. Bleeding from the nose or mouth will indicate to some degree its direction. Life may be spared, or may be destroyed by inflammation extending to the cavity of the skull. I have seen two cases of this description. In one, the eye on the side of entrance was sound to outward appearance, but sightless; the other eye was atrophied. The explanation of the loss of sight is easily understood.

When the bullet takes some other than a transverse direction, the injury inflicted will depend greatly on its penetration, as well as on its special direction, and will often be fatal. A case worthy of record I have reported in the Transaction of the American Ophthalmological Society for 1881.

A circus proprietor, twenty-eight years of age, while in bed in a hotel in Texas, was awakened from sleep by a man who presented a pistol to his face and demanded his money, which was under his pillow. The assailant fired, seized the money, and fled. The ball entered the left orbit close to the outer canthus. For several weeks the patient was in bed, and was much of the time unconscious. Four months afterward I saw him. There was no cicatrix or irregularity which would indicate the place of entrance; the outer orbital margin was regular and smooth; the eye was sightless, though perfectly capable of motion in all directions. The ophthalmoscope showed a large laceration of the choroid on the outer side of the fundus, and atrophy of the optic nerve. The left ear was totally deaf—not able to hear the tuning-fork applied to the head. In the meatus auditorius was a swelling of the upper wall close to the membrana tympani, which was covered with tense skin, was tender to touch, hard, and about five millimetres across. It was just such a protuberance as would be made by a small pistol-bullet lodged in the bony meatus, and there I believed it to be. The patient did not experience any unpleasant symptoms, and resumed his travels as a showman. His other eye, which he had never depended on, had myopic astigmatism, and with —12c 180° he gained V = $\frac{20}{40}$. In 1891 his condition remains the same.

I have seen the eye made sightless by the entrance at the outer angle of the orbit, of a bullet from a toy pistol.

Blows upon the margin of the orbit sometimes implicate the supra-orbital or the infra-orbital nerves, and to their injury has been ascribed the loss of sight which sometimes has been known to ensue. The true cause in the great majority of cases is to be sought in fissure of the orbit reaching back to the optic foramen, as will be referred to later. Amaurosis by injury of these branches of the fifth nerve has long had a place in ophthalmic pathology, but it stands on very weak evidence.

Dislocation of the malar bone is an accident which can occur, and I have recorded an instance (see Trans. Am. Oph. Soc., 1880). It results generally from violent falls upon the face, whose force is spent directly on the bone. It may cause extensive orbital hemorrhage and possibly diplopia through interference with the inferior oblique muscle. It will be recognized by a notch near the middle of the inferior orbital margin, where the malar joins the superior maxillary bone, and by another notch where it joins the external process of the frontal bone, and often the zygomatic arch is bent or broken. Anæsthesia of the infra-orbital nerve, and pain in chewing, because of pressure on the canine and adjacent teeth, are symptoms which continue for some time. The symptoms vary a little according to the direction in which the bone is displaced.

Fractures of the walls of the orbit occur in a great variety of ways: by cuts, blows, falls on the head, by crushing forces, etc. Such an accident, with extrusion of the eyeballs from the sockets, has been caused spontaneously in child-birth when there was deformed pelvis (see case reported by Berlin in G. and S., VI., p. 588), and might result from injudicious handling of the forceps. If the roof is implicated, there will be danger of inflammation of the brain, yet out of 19 such cases collected by Berlin, 16 recovered. Fractures of the inferior orbital walls, besides opening the antrum, damage the infra-orbital nerve, and are liable to be followed by distressing neuralgia or by anæsthesia. Fracture here, and also of the inner wall of the orbit, will be succeeded by *emphysema* of the cellular tissue. In some cases this will be extensive, and a case is reported by Knapp of exophthalmus produced in this way. Nosebleed will also occur.

Double vision may result from injury of the orbital walls, and not always by implication of the nerves but by damage to the muscles at their origin in the apex. Such a diagnosis can rest only on probability, yet I think sufficient reasons can be adduced for this opinion in the following case:

Dr. T. J. H., æt. 37, a physician of Massachusetts, consulted me in January, 1893. In October, 1892, he was thrown from a horse, striking on the left

shoulder and the left side of the head. He was stunned but not unconscious, no vomiting. He had to go to bed for a few days. Subconjunctival ecchymosis appeared on the inner side of each eyeball soon after the injury. The following day he had diplopia, and ptosis of the right eye. At the present time the falling of the right upper lid has practically disappeared. The diplopia requires for correction a prism 10° base up, and a prism 15° base out over the right eye, which means that movement upward and outward is restricted. By the ophthalmoscope the optic disc was found a little gray and V = 0.8 (?). In the other eye V = 1.0.

By studying Figs. 262 and 263 it will be seen that a fracture at the apex involving the vicinity of the upper part of the spheno-maxillary fissure will include the origins of the rectus externus, the rectus superior, and of the levator palpebræ. Were these muscles damaged by lesion of their respective nerves it would

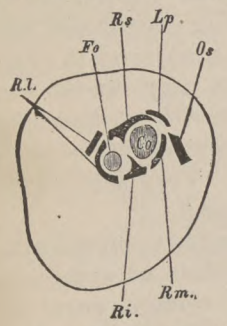

FIG. 262 shows schematically the origins of the ocular muscles. *Rl*, Rectus externus (lateralis); *Rs*, rectus superior; *Lp*, levator palpebræ; *Os*, obliquus superior; *Rm*, rectus internus (medius); *Ri*, rectus inferior; *Fo*, foramen of motor oculi (third) nerve; *Co*, canalis opticus.

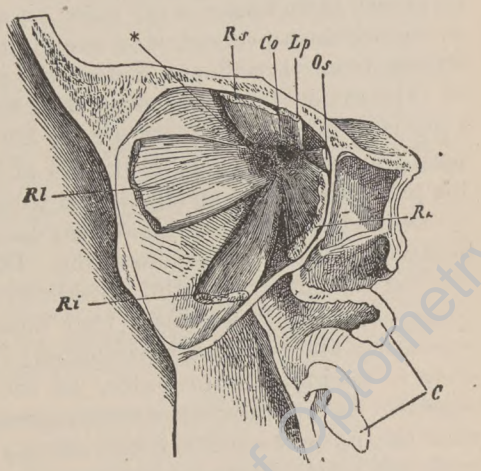

FIG. 263.

be difficult to understand why other muscles supplied by the third should escape injury; but supposing the mischief to consist in fissure and some displacement of a fragment of bone at the apex (the wing of the sphenoid) the explanation seems easy. Ptosis as a result of fracture of the orbit is not very rare. In the above case my belief is that the paresis of the levator palpebræ, of the rectus superior and rectus externus, and the lesion of the optic nerve were all due to fracture at the apex.

It will be noted that the rectus externus has two heads and is in close relation to the third nerve. The same anatomical relations are shown in Fig. 263, which displays the stumps of the divided muscles in the right orbit, and part of the nasal cavity.

Fractures of the orbital walls by penetrating wounds, as may happen in fencing, or by a bayonet, arrow, umbrella-ferrule, hook, key, etc., are relatively more serious than those just mentioned.

Digitized by the College of Optometry

This is true, most especially of the roof of the orbit. The external wound may be trifling, the eye often escapes harm, but if the cavity of the skull has been entered, the prognosis is very grave. In twenty-five per cent of the cases (Berlin) the patient immediately falls unconscious, but presently recovers. It is an important matter to know whether the wound has gone through the orbital roof. The outward opening is often small, it partially closes, and to find a way through it with a probe is very difficult, because the eyeball is violently pulled around as the weapon enters, and afterward returns to its place, thereby making the track sinuous. But there is very grave doubt as to the propriety of venturing to use a probe. The probability of the presence of a foreign body, or of the displacement into the skull of fragments of bone, may justify probing when the wound is recent and the symptoms urgent, but the surgeon's little finger is far safer as an exploring instrument, and, on the whole, a prudent man would, in the great majority of cases, refrain from meddling. Antiseptic precautions may render such an exploration less dangerous than it would be without them, but a discreet surgeon will not permit his professional curiosity to imperil the patient's limited chances of recovery. Very seldom will his probe or his finger be allowed to enter the orbit.

Cerebral symptoms, when they occur, may be due to intracranial hemorrhage, or to inflammation. The latter class of symptoms will be various, viz., pain, weakness, delirium, vertigo, paralysis, coma, etc. But it is notable that head-symptoms may be tardy in appearing, and be so long delayed as to make perforation of the roof seem to be highly improbable, yet the dreaded tokens may in time appear. In one case, forty days passed without any cerebral signs, then the patient suddenly died after a foreign body was extracted from the orbit. Berlin has gathered 52 cases of perforating wounds of the orbital roof, of whom 11, *i.e.*, twenty-one per cent, recovered; but of these, three were hemiplegic, one had persistent headache, and one became imbecile. The remaining 44, *i.e.*, seventy-nine per cent, died; of the deaths, one-half were from the immediate effects of the wound, and the other half from the subsequent complications.

At the autopsy, the bony aperture was generally small, and fragments had entered the cranial cavity. Wound of the brain may be small, or in some cases very large. Of the causes of death at a late period after the wound (18 cases), in 15 there was abscess of the brain, with or without meningitis; in 2, thrombosis of the longitudinal sinus; in 1, "pus at the base of the brain." In 6 of them, bits of bone were found in the brain-substance.

An illustration of what may ensue from fracture of the orbit, is the following:

Digitized by the Internet Archive in 2010

A boy fifteen years of age, while dodging through a crowd in a meat-market, stooped to get on more easily, and ran against a large meat-hook. Its point caught him in the right orbit, under its upper margin, tearing off the upper lid from the inner angle, fracturing the edge and perforating its roof. He was taken to the New York Hospital, and kept under treatment for six weeks. At the end of that time he came to the New York Eye and Ear Infirmary, and I found a scar running nearly the whole length of the upper lid beneath the brow, the lid everted and immovable, its conjunctival surface converted into a florid mass of papillary granulations; the cornea visible for its lower half, and in a state of fixed convergence. The globe could not be moved, but the lid could be turned with the finger, and could be slightly lifted by his efforts. The eye looked well, but was almost sightless. There was atrophy of the optic nerve, apparently the result of neuritis. At the upper margin of the orbit was a deep notch, which evidently went back into a deficiency in the roof. He was unable to say whether any fragments of bone had come out. By a pressure-bandage on the readjusted lid, the thickening of the conjunctiva, and the swelling of the lid so far abated in eight months, that I ventured to try to bring the cornea to the middle of the palpebral opening. I divided the rectus internus, and dissected the parts about the caruncle very freely, but could not turn the globe outward. I then attempted to bring forward the externus, but could not rotate the globe outward. Finally, I explored the orbit on its outer wall, behind the globe, and found that this surface had been forced inward, and that the eyeball had become adherent to the periosteum at its posterior part. I tore away this attachment, and then was able to rotate the eye to the middle of the palpebral slit, where I placed it, and closed up the conjunctival wounds. The reaction was not extreme, and the eye was permanently fixed in the position where I left it. Some vision in the outer part of the field was obtained, but the upper lid remains drooping over the upper half of the cornea, of normal thickness and without ectropion.

Fracture may go through the lamina cribrosa and the ethmoid, with or without fracture at the base of the skull. A notable symptom occasionally met with is the *dropping of clear fluid from the nose* when the patient sits up. A case is quoted in Berger and Tyrman ("Die Krankheiten der Keilbein-Höhle und der Siebbein-Labyrinthes, etc.," Wiesbaden, 1886), p. 74, where the flow took place from the nose when the man sat up, and from the ear when he lay upon the right side. Autopsy ten days after the injury disclosed fracture across the sella turcica and of the lamina cribrosa of the ethmoid.

Another class of cases of orbital fracture are those in which no ordinary symptoms of this lesion appear, but in which, after an injury to the head, *loss of sight occurs in one or both eyes*, and with very slight symptoms in the fundus oculi. After a time the optic nerve may show signs of inflammation or of atrophy. Again, there are many cases of fracture running through the *canalis opticus* or the roof of the orbit, simultaneously with fracture of the base, or in some other region of the skull. The profound injury sustained distracts attention from the state of sight, and we seldom know

that it has been impaired, nor would the patient, perhaps, be able to tell us anything about it. A most interesting study of these cases has been made by Dr. von Hölder, who, in his capacity of pathologist, examined 124 cases of fracture of the skull. Stripping the dura mater from the base, he was enabled to detect injuries to the bone and hemorrhages which would otherwise have escaped notice. During forty years he made these observations and took notes of what he found (Berlin, G. and S., VI., p. 604). Among the 124 cases, there were 86 of fracture at the base, and in 79 of them the fracture extended into the orbital roof. Von Hölder states that out of 86 cases of fracture at the base, in 63 he found a fissure or fracture running through the optic canal, and always through its upper wall, and sometimes also through the inner wall; occasion-

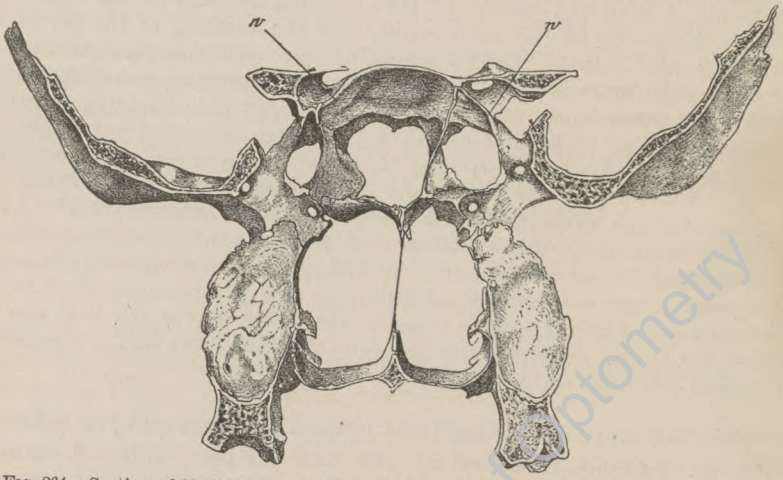

FIG. 264.—Section of Skull through the Canalis Opticus, seen from behind, and parts in front as well as behind the section taken away. The body of the sphenoid seen in the middle, with its unsymmetrical sinuses. The letters *n* and *n* point to the walls separating the optic canals from the sphenoidal sinuses. In this specimen they are excessively thin. In other cases one may be thin and the fellow very thick or both may be very thick. The optic canals are seen in oblique section, but their length and form are well displayed. This section is valuable to aid in understanding various lesions at the canalis opticus, both traumatic and spontaneous.

ally on both sides. In 42 cases there was hemorrhage into the sheath of the nerve, and he never found blood in the optic sheath, unless its bony canal was fractured. The blood may be derived from the cavity of the skull, or from the vessels of the sheath, or from the torn central artery of the retina.

Other observers have seen the same symptom. If the quantity were large, it might, as in a case reported by Knapp, be sufficient to injure sight by direct pressure on the nerve, but smaller quantities might also destroy sight by interference with the central retinal artery, causing ischæmia retinæ, and all the features, too, of embolism. Prescott Hewitt gathered 68 cases of fracture of the base, and found the orbit involved in 23.

Digitized by Illinois College of Optometry

Noyes' "Diseases of the Eye."

1

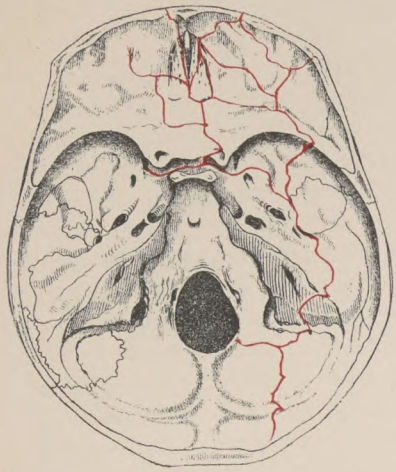

2.

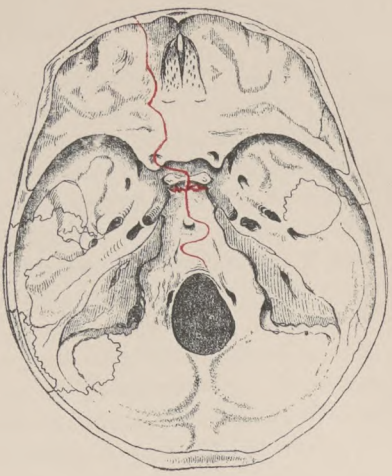

3.

4.

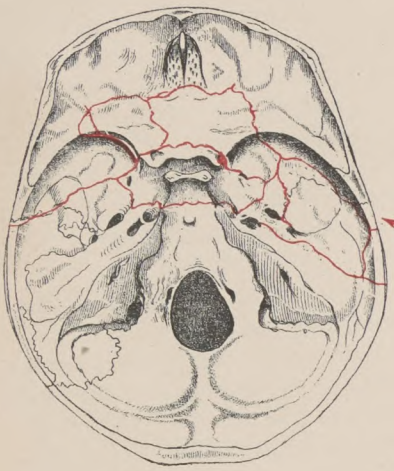

5

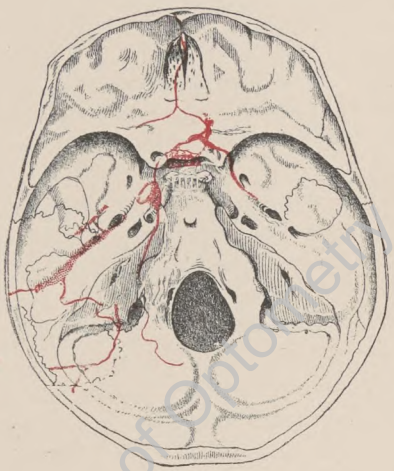

6

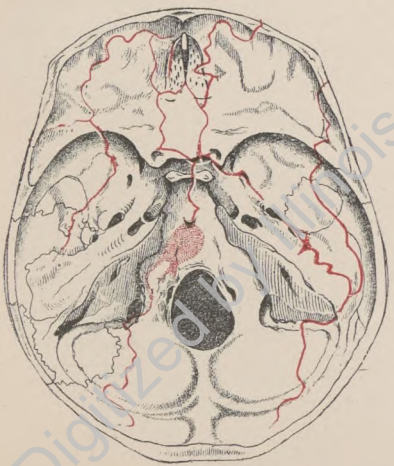

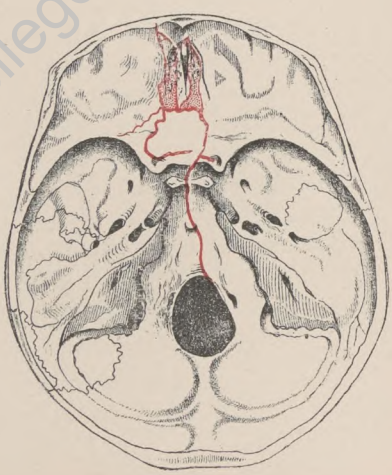

Digitized by Illinois College of Optometry

Digitized by Illinois College of Optometry

Possessed of these facts, it becomes intelligible why, after a fall on the head, total, or nearly total blindness may ensue, with, perhaps, no ophthalmoscopic lesions.[1] Ultimately, signs of inflammation or of atrophy or pigmentation of the disc may appear. Again, venous hyperæmia, ischæmia of arteries, opacity of the nerve or the retina by exudation, hemorrhage into the vitreous and into the retina will suggest intravaginal hemorrhage. For example, Berlin quotes 30 cases of blindness after injuries of the head, in which ophthalmoscopic examination was made. In 17 there was atrophy of the nerve and in two there was pigment-deposit in the disc. A case which I published was seen in the stage of neuritis. Another case I have seen which presented nothing but slight fulness of the veins. Other reported cases have exhibited hyperæmia of the disc, ischæmia, hemorrhages, etc.[2]

The possibilities which may follow from injuries of the canalis opticus and the ethmoid are emphysema of orbit and lids, injury of optic nerve and damaged sight, dropping of fluid from the nostrils, lesion of the carotid artery and cavernous sinus with resulting pulsating exophthalmus, anæsthesia of the second and third branches of the trigeminus nerve and lesion of other cerebral nerves.

The loss of sight in fracture at the canalis opticus may come on a few hours after receipt of the injury, as happened to a one-eyed man who was struck on the brow by a heavy potato and the result was extreme atrophy of the nerve. The precise lesion may be a hemorrhage into the nerve or its sheath, or its laceration by a splinter of bone. The quality of the process will vary accordingly and the loss of sight be sudden or gradual. Seggel gives two cases with charts of visual fields showing great and irregular limitation, *Archiv f. Augenheilkunde*, XXIV., 4, 293.

Treatment of these injuries of the orbit is to be conducted on general principles and according to the dominant symptoms. Of course we have nothing to say on the general subject of fracture of the skull. As to the orbit, loose and accessible bits of bone or foreign bodies are to be removed, all excitement to be avoided, antiphlogistic measures to be used, namely, cold applications, removal of secretions, and maintenance of free escape of discharges. In this connection it is important to consider what steps are to be taken when symptoms of abscess, deep in the orbit and perhaps in the brain, threaten. For orbital abscess there would be no hesitation in promptly giving a free outlet. The employment of antiseptic methods in the operation, and in the subsequent dressing are of course necessary. Should symptoms of brain trouble threaten and

[1] See Callan, Trans. Am. Oph. Soc., 1891, p. 174.

[2] See also Berger and Tyrman, l. c., pp. 75, 96.

Digitized by the Internet Archive in 2007 with funding from Microsoft Corporation

the escape of pus be so hindered as not to be otherwise insured, it might be proper to enucleate the globe. It also becomes a question as to the propriety of searching for pus in the substance of the frontal lobe of the brain. The existence of a perforation of the orbital roof would invite further exploration, and modern surgery moves in this direction. Some cases have been thus treated under constant antisepsis, yet the difficulties of perfect drainage are very great, and the tendency is to extension of the morbid process, and no cheering results are yet recorded in these cases when acute.

In cases of more chronic type the following may be cited from my own experience.

In 1857, a boy, ten years of age, was brought into the New York Hospital after having been run over by a street car. He had fracture of the occipital and frontal bones. He remained about three months in the institution. He recovered without paralysis or loss of any function, but was always subject to headaches, and had a small fistulous opening at the upper and inner angle of the right orbit, just under the brow. In 1865 I saw him and noted the fistula, and warned him that he was liable to have trouble from it. He lived a wild life, and was sometimes drunk. In the latter part of 1865 I was called to see him, and found he had serious brain symptoms. Consciousness was not quite abolished; pulse slow, respiration stertorous. He had had severe headache and been in bed for several days. By the ophthalmoscope I could only see hyperæmia of both nerves. The usual discharge from the fistula had recently ceased. I concluded that there must be an abscess near this spot within the cranial cavity, and determined to trephine the skull just above the fistula. A large crucial incision was made, and I trephined just outside of the supra-orbital notch. The dura mater bulged into the wound. I opened it and pus escaped. About half an ounce issued, and I put my finger into the cavity over the roof of the orbit. The patient, who had sunk into coma during the consultation over his case, recovered intelligence at once, in half an hour was able to talk, and made a good recovery. He had fungous granulations (hernia cerebri) from the wound, but at length by a pad and pressure-bandage and excision this was controlled, and he has never reported himself since.

Wound of the optic nerve is a rare injury, but of which I have seen two cases and Aschmann (Inaugural thesis, Zurich, 1884) has made a collection of twenty-one cases, of which two were in Horner's clinic and the rest gathered from literature. One of my cases is as follows:

In May, 1882, a boy aged 10 years, while playing soldier with a comrade and fencing with sharpened sticks, was wounded in the left orbit. The end of the stick broke off. He was not stunned nor did he feel much pain. He ran up one flight of stairs; and got his grandfather to pull out the piece with pliers. It measured 2½ inches in length, tapered to a sharp point; at its base it was about ¼ inch thick and was slightly bent at the distance of a quarter of an inch from the tip. Five hours after he was seen by Drs. Munn and

Digitized by University of Illinois College of Medicine

Schoonover, who found the globe mobile, pupil dilated and fixed, no hemorrhage in conjunctiva or skin; no external lesion of eye, but no perception of light. In twenty-four hours I saw the patient and found the wound at the infero-temporal angle of the orbit, and almost no reaction, no exophthalmus. Pushing the globe deep into the orbit caused pain, but movements of the eye were painless and perfect. Pupil between 4 and 5 mm. in diameter, slightly larger than the other and would neither dilate nor contract. No sensation of light. No photophobia in other eye. By ophthalmoscope, the nerve is intensely red, a little swollen, veins very turgid. The next day the color of the nerve was normal and vessels of usual size. After ten days the temporal side of the nerve was pallid. After four weeks the nerve became pale over the whole disc, and the vessels remained normal in size.

No serious symptoms occurred at any period, although he became quite excited from anxiety during the first few days of his confinement to bed. It seems clear that the optic nerve was penetrated near the apex of the orbit, perhaps only severely contused. The lesion was behind the entrance of the arteria centralis, and no other organ save the optic nerve was damaged. Probably the bony walls escaped injury, and it is likely that the nerve was hurt very near the optic canal.

Foreign Bodies in the Orbit.—Foreign bodies entering the orbit and passing out of sight are extremely difficult to find unless of considerable size. Even if they are large they may lodge in the orbit without destroying the globe, as happened in an instance reported by Mr. Carter, in which a piece of an iron hat-peg, $3\frac{3}{10}$ inches long, was buried in the cavity, and remained there for from ten to twenty days without the patient being aware of it. It was extracted without injury to the functions of the eye. It is not necessary to say that foreign bodies which can be seen or felt should be carefully and immediately extracted. But the point of difficulty is to decide, 1st, whether a foreign body has entered the cavity; and, 2d, how to find and remove it. A doubt arises as to the penetration of foreign bodies in cases of wounds by bird-shot. The place of entrance is very small, closes instantly, and heals promptly. It is often impossible to trace them, nor is it generally needful to meddle with them. I have known a fragment of iron of considerable size, struck off by a chisel, to enter and be completely hidden. The irregularity of the piece, the yielding nature of the tissues, and the sinuosity of the wound, make exploration by a probe very unsatisfactory. As above remarked, a reason for the difficulty is, that when the foreign body enters, it drags the eye around toward itself, and when it has found a lodgment, the globe returns to its position and thus twists the track of the wound.

A case, illustrating the difficulties of diagnosis and the proper mode of treatment in obscure cases, will illustrate what needs be said:

A man walking among bushes felt a twig strike his eye, and was convinced that a piece of it had found entrance. Some bleeding occurred; he suffered

considerable pain; he found his sight uninjured, and for some time he did not go to a physician. A chronic inflammation lingered about the lower part of the eye, and he was annoyed by some pain and discomfort. The physician looked at the inflamed part and everted the lower lid, but could see no sign of wound or scar and prescribed for what he regarded as simple conjunctivitis. The man's statement that a foreign body had entered or was present in the orbit, he did not credit. For two weeks treatment by astringents was kept up, when I was asked to see the case. I discovered in the inferior cul-de-sac a small projecting granulation, as large as a No. 2 shot, and around this the conjunctival and scleral hyperæmia concentrated. I at once assumed that there was a foreign body in the orbit and advised its removal. For two weeks longer the same medical treatment was continued, and the patient then was put into my care at the New York Eye and Ear Infirmary. No

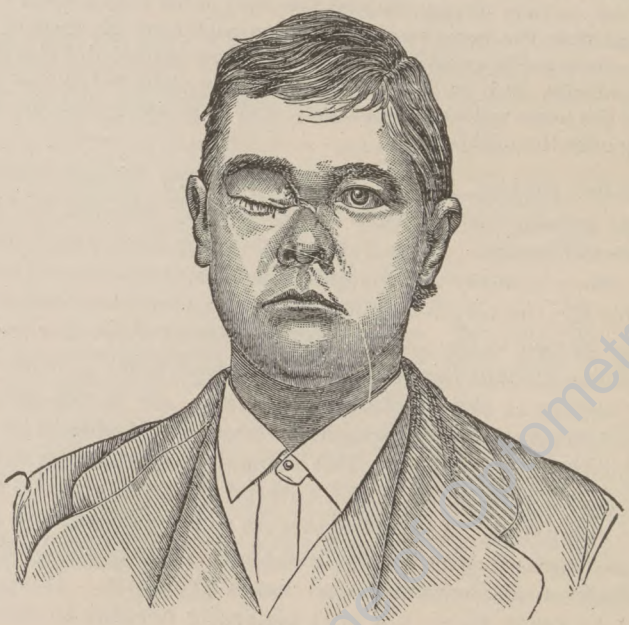

FIG. 265.

trace of an offending substance could be felt with the finger, nor could a probe be forced through the tissues. The patient was etherized; an opening made into the conjunctiva at the granulation, and by tearing and stretching the tissues, an opening was made large enough for the entrance of my little finger. Afterward my index finger was thrust in. No foreign body could be felt, nor could any sign of it be found by various exploring and grasping instruments. After prolonged manipulation, while with the finger pressed deeply into the orbit, I was also feeling along it with a pair of dressing forceps, I caught something which conveyed the sensation of a foreign body. Drawing upon it I brought forth a bit of twig about 1⅛ inches long, and large as Theobald's lachrymal probe, No. 8. It was softened by long maceration, was flexible, and offered so little resistance that its detection was rendered extraordinarily difficult. The yielding nature of the orbital contents greatly increases the difficulty of seizing a foreign body unless it have some stiffness or

Digitized by the Internet Archive College of Optometry

can be steadied by being pressed against the walls. The operation gave rise to no serious trouble, and in ten days the man was discharged cured.

From the above case, I venture to advise the insertion of the operator's finger into the orbit along the track of the foreign body, and to use it both as an explorer and as a means of guiding the search with forceps or other suitable instruments.

My experience in the following case brings up again the question of how far interference with the brain and intracranial cavity may be justifiable. The case was published *in extenso* in the *Am. Journal of the Medical Sciences*, July, 1882.

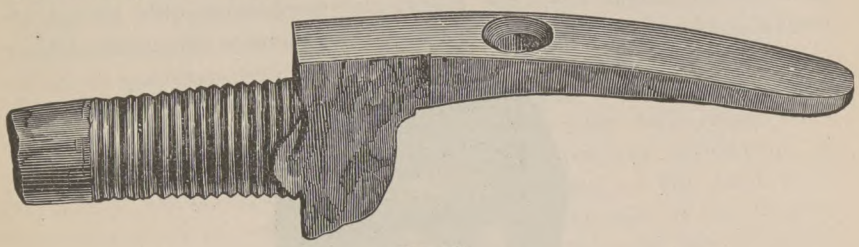

FIG. 266.

A boy, aged 19, was injured by the explosion of his gun, and the butt of the barrel, known as the breech pin, broke through the nose and went in out of sight. It was not known that a foreign body had lodged, the wounds healed except some sinuses and I saw him five months afterward. His appearance is shown in Fig. 265. Explorations discovered the foreign body depicted of natural size in Fig. 266. Extensive incisions and dissection were required to trace its situation and its form was totally unknown. By using large pliers, it was brought out from the nasal cavity and found to have penetrated the roof of the orbit and the frontal lobe of the brain—the position it occupied is shown upon a prepared skull in Fig. 267. Its presence in the brain had not been indicated by any symptoms whatever. On the fourteenth day evidence of abscess in the brain led to an operation for evacuating pus by enlarging the opening in the orbital roof. Pus was found outside of the dura mater and in the brain tissue. On the sixteenth day beginning paralysis of the opposite arm and leg showed that full relief was not secured against cerebral pressure. The skull was trephined at the spot shown in Fig. 267, an exploring needle introduced, and at the depth of $1\frac{3}{4}$ inches pus was found. A drainage tube was passed from the trephine hole to the orbital opening to give vent to pus.

FIG. 267.

From the beginning of treatment assiduous efforts were made to secure free vent to secretions and these efforts were not relaxed up to the end of

Digitized by Illinois College of Optometry

the case. Death took place on the thirty-ninth day after removal of the foreign body.

Exophthalmic Goitre, Graves' Disease, Basedow's Disease.

Under these names is described a condition presenting as symptoms, palpitation of the heart, hypertrophy of the thyroid gland, and protrusion of the eyeballs. While the fully developed disease includes these three items, any one of them may be wanting. Moreover, while both eyeballs are usually extruded, and can be pressed nearly back into their proper place by the fingers, one may be more advanced than the other, and sometimes only one is affected as is noted by Stellwag, and as I have once observed. Other

Fig 268.

symptoms are: extreme excitability of the patient; she is readily startled, and has flashes of heat; pallor, and flushing of the face quickly alternate; the action of the heart is very irregular and thumping, its pulsations may be habitually one hundred, or mount to one hundred and sixty; there may be some consecutive hypertrophy and systolic bruit, and also a bellows murmur over the large vessels. The thyroid presents variable and sometimes unsymmetrical enlargement. A choking in the throat (globus hystericus) is common; the patient may be unable, for an instant, to catch the breath or swallow. The eyes stand forward in a peculiar stare, and show the sclera above the cornea, and, as Graefe noted, this look of surprise or fear is aggravated by actual retraction of the upper lid, which exposes the globe more than the pushing forward of

Digitized by Illinois College of Optometry

the eye by a tumor is observed to do (see Fig. 268). Stellwag also noted the infrequency and slowness of the action of the lid in winking. By exposure the cornea and conjunctiva are irritated and congested, and ulceration of the cornea has been observed. Sometimes it is never fully covered by the lids, and is more exposed in sleep. The pupil usually is natural in its action, although mydriasis has been noted; movements of the eye are unimpaired, diplopia is rare and transient, vision is not involved, the circulation in the fundus is ordinarily not peculiar, yet Becker has noticed that the retinal arteries pulsate, and not in the disc alone, but over a considerable length; attacks of migraine can occur and with hemiplegia. The disease is complicated with anæmia, and in women often with amenorrhœa and chlorosis, and the patients are hysterical. Melancholia is common and mania may occur. We may also see digestive disturbances, nausea, vomiting, diarrhœa, bloody stools; also cough, profuse sweating, and Bulkley has cited two cases with urticaria. There may be nodules of inflammatory exudation, or patches of transient redness, and increased heat of the skin, varicose dilatations of vessels may take place on the nose or cheeks, and there may be ephemeral tumors on the eyebrows and lids, attended sometimes by dilated vessels. I have seen one case in which undoubted exophthalmic goitre was attended by firm tumors at the lower border of one orbit, and which, under the microscope, seemed to be composed of enlarged lymphatic gland tissue; only one eyeball was protruded. A case of Heymann's had repeated paroxysmal attacks of conjunctivitis with membranous exudation.

The disease occurs with greater frequency among women, according to Emmert (see *Arch. für Oph.*, XVII., p. 30), in the ratio of nine to one. The cause is not definitely ascertained: most of the lesions are traceable to disturbances of the sympathetic nerve, but where their origin may be is not determined. Some fix upon the cervical sympathetic, and others upon the cervical portion of the spinal cord. Sattler thinks the vaso-motor centre in the medulla to be the primary seat of the lesion (Graefe and Saemisch, VI., pp. 941–1024). In all these structures autopsies have found lesions, but not with uniformity. The heart is often a little, seldom greatly enlarged, and there may be insufficiency of the mitral valves; the thyroid gland shows in old cases some increase of connective tissue and colloid cystic degeneration, but at death it usually collapses; in the orbit rarely is anything abnormal discovered, and the ocular protrusion disappears. It is, therefore, justifiable to assign the cause of exophthalmus to vascular enlargements, and Snellen has corroborated this opinion by showing that, with a stethoscope, a distinct vascular murmur can be heard during life. Recklinghausen has found fatty degeneration of the ocular muscles.

An autopsy by Dr. White[1] found the sympathetic in the neck normal, likewise the spinal cord, save one or two insignificant hemorrhages. The lesions thought to be important were slight inflammatory signs at the lower end of the olivary bodies and from here up to the restiform bodies were numerous hemorrhages which could be further traced to the aquæductus Sylvii. This autopsy corroborates the view which Sattler and others hold that we are to look to the medulla oblongata for the site of the lesion, whatever organ in it may be at fault.

Following the publication of this autopsy is an article by Manby[2] in which the occurrence of exophthalmic goitre and of diabetes in different members of the same family is related. Three such families are mentioned—and the coincidence points to the vicinity of the fourth ventricle as perhaps the seat of trouble common to all these individuals.

The disease progresses slowly in most cases, while a few patients have the good fortune to reach an early recovery. There is great emaciation and prostration, and in fatal cases the end is brought about by asthenia or by phthisis.

For an extensive account of symptoms and characteristics of the disease see Gowers on "Diseases of the Nervous System." Both glycosuria and temporary albuminuria have been observed: sometimes extensive ophthalmoplegia externa—see paper by Fitzgerald,[3] and by Story[4] who noted atrophy of the optic nerves in one case.

Treatment.—This will be determined by the character of the leading symptoms. In many cases, and perhaps in the majority, pronounced anæmia will call for iron in various forms and long continued. Next in order will be remedies to improve the heart's action, hence digitalis is much employed, and general tonics such as quinine, strychnia, phosphoric acid will find place. The use of ergot has been popular and has to me seemed beneficial. Galvanism has been much tried and by Bartholow is said in three cases to have done evident service, but many writers confess their disappointment with it. Atropia or ext. belladonnæ is strongly commended by Gowers and must be given to constitutional effect. Janeway, so late as May, 1889, in a paper before the N. Y. County Med. Assoc., which graphically portrays the disease in its clinical aspects, speaks favorably of the tincture of strophanthus, five minims three times daily, gradually increased if necessary. He found it succeed when digitalis had failed. He emphasizes the importance

[1] British Med. Journal, March 30th, 1889.
[2] British Med. Journal, May 11th, 1889.
[3] Quoted in Ophthalmic Review, vol. ii., 148, 1883.
[4] Quoted in Ophthalmic Review, vol. ii., 161, 1883.

Digitized by Google

of iron and of rest both physical and mental; menstrual irregularities may either precede or succeed the disease.

Bromides and means of inducing sleep, especially sulphonal, will have occasional application. It is advisable to avoid opium, although Janeway, while giving this caution, says that exceptionally it has done good. Its danger is consequent impaired nutrition.

A formula which I have many times found useful is: ℞ Ferri pyrophosphatis, zinci bromidi, āā. ʒ i.; tr. digitalis, ʒ v.; fl. extr. ergotæ, ℥ iv. Dose a teaspoonful three times daily (Hammond). One will need to vary remedies in the long progress of a case and must test what will prove most effectual.

For attacks of dyspnœa and palpitation, hip baths, mustard to the feet, cold to the thyroid gland are helpful. Sometimes ether and chloroform are given, or a single dose of morphia for spasmodic attacks.

In all cases the greatest importance attaches to hopeful assurances of possible improvement and that the distressing symptoms are not so dangerous as the patient thinks. Cheerful surroundings, absence of care, avoidance of exitement, generous diet, sufficient sleep and adaptation of remedies to occasional symptoms, codeia, chloral, etc., besides steadfast perseverance in iron added to whatever other remedy above suggested proves most fitting, is the line to be followed. Should, from exposure, inflammation of the eye occur, prompt measures must be instituted.

For the exophthalmus no particular treatment is to be adopted, except, if the cornea and conjunctiva become dry through exposure, a little purified (white) vaseline or cosmoline may be put between the lids two or three times daily. A pressure-bandage is sometimes comforting, and pushing back the globes into the orbits gives some relief; it may be necessary to hold the lids in approximation by a strip of rubber plaster, or even to do tarsoraphy for partial closure of the lids at the outer angle. Partial division of the levator, as suggested by Graefe, is not practised.

A recent discussion on the treatment of this disease is found in *N. Y. Medical Record*, July 11th, 1891. Rest in bed, great attention to careful feeding, massage are much insisted on by Dr. W. H. Draper, who also thinks iod. potass. beneficial in addition to digitalis, etc. The general view was that the disease, being a neurosis, is to be dealt with on general indications derived from symptoms, and that no special remedy can claim control. The experiences of an electro-therapeutist are given by Rockwell, *N. Y. Med. Record*, September 30th, 1893.

Recovery may take place within one to five years. A fatal result may take place by exhaustion, by intercurrent phthisis, and occasionally the disease is complicated with organic heart lesion.

CHAPTER XXI.

USE OF ARTIFICIAL EYES.

Prothesis Oculi.—Great care must be taken to have artificial eyes fit easily and not be too large. They are of very little use when both the globe and much of the contents of the orbit have been removed; they serve best when an eye, only a little reduced in size remains, and its surface is not sensitive. But generally they are to be worn after the globe has been enucleated and the other tissues are left. Under these circumstances a moderate degree of mobility is possible, but varies in different persons. It is unavoidable that a deep furrow should remain in most cases beneath the brow, because the drawing together of the conjunctiva in the central cicatrix pulls down the superior cul-de-sac. When an eye fits well, a patient is not conscious of its presence. Great pains must be taken to preserve its polish. The enamel will begin to dissolve away in a year or more, according to the quality of the material and of the ocular secretions. The eye should be washed carefully with clean water or with dilute alcohol, but not kept in water for hours, as during sleep. It should never be worn during sleep. If much discharge from the conjunctiva is excited, the shell must be very carefully examined for loss of smoothness on its edges or surface, and the conjunctiva treated by mild astringents or boracic-acid solutions. A little vaseline will prevent the drying on the shell, of secretion which may be unavoidable. If, as happens after long use or carelessness, the conjunctiva become granular, with papillary hypertrophy, the shell must be laid aside and the parts treated until the membrane recovers. Shrinkage may take place by which the conjunctival space is much reduced, and only a small eye can be worn. Sometimes the membrane becomes xeromatous and no space may remain to hold a shell. Burns of the eye or other injuries sometimes leave no cavity in which a shell can be inserted. In several such instances I have enabled the patient to wear an eye by cutting the tissues apart and introducing a piece of conjunctiva from the rabbit. The transplantation is difficult and tedious, and may need to be done two or three times. After the healing has been completed greater space is gained, and this is farther improved by wearing shells of gradually increasing size

Digitized by Google

until room for a suitable one is secured. It may take six months to attain this result. A young man has recently presented himself for whom I did such a proceeding eleven years ago. He has constantly worn a shell which is an excellent counterfeit, it gives no trouble, and the conjunctival sac is healthy. Similar operations are done to make room when by trachoma, or by long use of a shell, the sinuses are obliterated. Such cases are very difficult to deal with, but sometimes success is gained and the shell can be worn for a few years longer.

With children who lose an eye, or have one which is much atrophied, an artificial eye is of importance to prevent arrest of development of the orbit and muscles. Such is the common belief, yet I have a patient now seventeen years old from whom one eye was removed when she was a little over a year old because of glioma, and not only does she survive, but the orbit and the region of the eye is symmetrical with the other. The conjunctiva has shrunken to some degree, and it may be assumed that after many years a greater diminution of the cavity will ensue. Especially does this occur with those who have trachoma. It may be worn for a few hours daily to adapt the parts to its presence. Constant wear is undesirable, from risk of breakage, and because irritation of the conjunctiva is to be avoided. Unusual pains must be taken to keep the parts in a healthy state.

FIG. 269.

The shell may need to have notches cut in its edge, or require some peculiarity of form to fit special irregularities. It is not very rare to find an artificial eye irritate the parts so much as to cause sympathetic disease of the other one. I have several times seen this take place, and then its use must be absolutely forbidden. In recent cases of enucleation the shell should not be worn until all redness and swelling have disappeared—that is, in from two to three weeks. If the eyeball should be sunken because of an inflammation, the stump may not permit the use of a shell for two or three months. An eye should not be worn upon a stump which is known to contain a foreign body; enucleation should be practised.

Mr. Mules, of Manchester, England, advocates the use in certain cases of an artificial vitreous which is a sphere of thin glass introduced within the sclera after all its contents have been removed. The scleral cavity must be thoroughly washed with sol. corrosive sublimate, 1 to 3,000, all bleeding checked, and when the thin globe is inserted it is held in place by silk sutures in the sclera. Such a proceeding requires several weeks for healing to be complete, and is applicable to cases where the form of the globe is not much

altered. There has not yet been much experience of surgeons with it. While some unfavorable testimony has been given, Mr. R. B. Carter[1] reports 13 operations, of which 5 were failures, 7 immediate successes, and 1 succeeded upon employing at a second trial a smaller ball. He thinks the use of a horse-hair drain at the equator and below important. He uses boroglyceride freely as an antiseptic during the operation. Severe chemosis frequently occurs and demands incisions. He speaks in much praise of the good appearance and mobility of the eye in successful cases. One case of sympathetic ophthalmia following this proceeding has been reported. Hence the need of caution.

Lang, 1887, reports eight cases: speaks of the severe reaction and that the average stay in hospital was twenty-four days. Cross mentions a case where the artificial vitreous excited sympathetic ophthalmia, which disappeared after its removal.

Lang[2] has in sixteen cases put a hollow glass or silver globe within the *capsule of Tenon* after enucleation. Bleeding is fully checked by ice and irrigation, the ball inserted, the upper and lower edges of the now whitened capsule brought together by a silk stitch on the middle line, a horse-hair drain inserted, and one other stitch put in on each side; the conjunctiva united by stitches. Iced antiseptic dressing, "Alembroth wool," or absorbent cotton with bichloride 1:3,000 constantly applied. In five days patients able to go out. Surface stitches removed, deep ones left. The sphere is about two-thirds the diameter of removed eye. Frost has done a similar operation. Probably this proceeding will find favor; it is worth trying.

To insert an artificial eye, lift the upper lid with the fingers of one hand, moisten the shell and slip its larger end vertically under the upper lid. As it passes up, turn it into the horizontal position, until it rides above the lower lid; with the other hand draw down the edge of the latter and let it slip into place. To take out the shell, push under its lower edge a small hook or the head of a large pin to pull it forward, and at the same time depress the lower lid. Raise it up gently and it will slide out by pressure of the lids. Most persons soon learn to take out the shell with their fingers and have no fear of dropping it.

Artificial eyes made of celluloid have been introduced within a few years and are commended because they are inexpensive. But they are less perfect in appearance than those of glass and they have been found to corrode easily and to excite very soon severe conjunctival irritation. An additional objection is that, when they begin to corrode or decompose, they emit a peculiarly foul odor.

[1] Medical Press and Circular, Aug. 17th, 1887.
[2] Trans. Oph. Soc. United Kingdom, vol. vii., 286, 1887.

Digitized by the Internet Archive

CHAPTER XXII.

STATISTICS OF EYE DISEASES.

THE best statement we have on this topic is in an article by Cohn in Eulenburg's "Real-Encyclopedia der Heilkunde," 1880, p. 602, based upon returns from 67 institutions between the years 1869 to 1875 and embracing nearly 300,000 patients.

The relative frequency of the diseases is thus tabulated:

Diseases of:	Per cent.
Conjunctiva	30.
Cornea	21.
Sclera	0.4
Iris	6.
Choroidea	1.
Glaucoma	1.
Retina, Optic Nerve, Amblyopia, Amaurosis,	5.
Lens	6.
Corpus Vitreum	0.7
Globe	2.
Refraction, Accommodation,	12.
Muscles	3.
Fifth Nerve	0.2
Lachrymal Apparatus	2.
Orbit	0.2
Lids	9.
Various	1.5
	100.0

Besides the above statistics valuable suggestions may be gained by a study of statistics of blindness, and the following tables from treatises by Magnus are reproduced with a few comments.

In his treatise on blindness among youth, 1886, Magnus confines himself to those below 20 years of age, and analyzes the statistics of 64 European institutions for instruction of the blind. He gathers 3,204 cases of incurable blindness in both eyes, and subdivides them into, 1. congenital; 2, produced by idiopathic disease of the eye; 3, produced by injuries; 4, produced by general diseases.

He gives the following tables, pp. 12, 13, l. c.

Digitized by the College of Optometry

	Total.	Males.	Females.
AMAUROSIS CONGENITA.	Per Cent. **551=17.19**	Per Cent. **327=16.32**	Per Cent. **224=18.75**
Anophthalmus	16=0.50	6=0.30	10=0.84
Microphthalmus	81=2.53	43=2.14	38=3.18
Buphthalmus	38=1.19	26=1.29	12=1.00
Atrophia nervi optici	113=3.53	62=3.09	51=4.27
Retinitis pigmentosa	73=2.28	40=1.99	33=2.76
Atrophia retinæ	17=0.53	12=0.59	5=0.42
Choroiditis and choroido-retinitis	21=0.66	12=0.60	9=0.80
Coloboma choroideæ	3=0.09	3=0.15	0=0.00
Irido-choroiditis	14=0.44	11=0.55	3=0.25
Kerato-conus	3=0.09	3=0.15	0=0.00
Keratitis	1=0.03	1=0.05	0=0.00
Albinismus	4=0.12	2=0.10	2=0.17
Glioma retinæ	1=0.03	1=0.05	0=0.00
Cataracta complicata congen	118=3.68	78=3.88	40=3.36
Undetermined conditions[1]	43=1.34	25=1.24	18=1.50
Adhesion of lids to globe	1=0.03	0=0.00	1=0.08
Myopia	4=0.12	2=0.10	2=0.17

BLINDNESS FROM IDIOPATHIC DISEASES OF THE EYE.

	Total.	Males.	Females.
	Per Cent. **1060=33.08**	Per Cent. **626=31.16**	Per Cent. **434=36.32**
Blennorrhœa neonatorum	753=23.50	415=20.66	338=28.28
Blennorrhœa gonorrhoica	15= 0.47	14= 0.70	1= 0.08
Trachoma	42= 1.31	27= 1.34	15= 1.26
Conjunctivitis diphtheritica	14= 0.44	6= 0.25	8= 0.67
Conjunctival diseases of undetermined character	26= 0.81	20= 1.00	6= 0.50
Keratitis	15= 0.47	11= 0.55	4= 0.33
Iritis	6= 0.19	2= 0.10	4= 0.33
Irido-choroiditis	61= 1.90	41= 2.04	20= 1.67
Choroiditis	14= 0.44	8= 0.40	6= 0.50
Sublatio retinæ	27= 0.84	18= 0.90	9= 0.75
Myopia	4= 0.12	4= 0.19	0= 0.00
Glioma retinæ	1= 0.03	1= 0.05	0= 0.00
Neuro-retinitis hemorrhagica	1= 0.03	1= 0.05	0= 0.00
Atrophia nervi optici	74= 2.31	54= 2.69	20= 1.67
Glaucoma	6= 0.19	4= 0.19	2= 0.17
Phthisis bulbi essentialis	1= 0.03	0= 0.00	1= 0.08

BLINDNESS FROM INJURIES.

	Total.	Males.	Females.
	Per Cent. **261=8.15**	Per Cent. **202=10.06**	Per Cent. **59=4.94**
Injuries of eye	76=2.37	63=3.13	13=1.09
Injuries of head	33=1.03	25=1.24	8=0.67
Operations	5=0.16	4=0.19	1=0.08
Ophthalmia sympathetica	147=4.58	110=5.47	37=3.10

[1] In the table of amaurosis congenita occurs an error of 10, viz., instead of "undetermined conditions 53, of which males 35"; the percentage shows that the figures should be 43 and 25 respectively. The correction is made in the text.

Digitized by Illinois College of Optometry

BLINDNESS FROM CONSTITUTIONAL DISEASES.

	Total.	Males.	Females.
	Per Cent.	Per Cent.	Per Cent.
	1063=33.17	**686=34.15**	**377=31.54**
Scrofula	243=7.58	142=7.07	101=8.45
Syphilis	32=1.00	23=1.14	9=0.75
Brain and its membranes	262=8.18	200=9.96	62=5.19
Atrophia nervi optici after hemorrhage	2=0.06	0=0.00	2=0.17
Rubeola (Morbilli)	114=3.56	73=3.63	41=3.43
Scarlatina	97=3.03	60=2.98	37=3.10
Variola	240=7.49	141=7.02	99=8.28
Exanthemata, unknown	14=0.44	9=0.45	5=0.42
Typhus	32=1.00	20=1.00	12=1.00
Purpura hemorrhagica	1=0.03	1=0.05	0=0.00
Orbital phlegmon	1=0.03	1=0.05	0=0.00
Pertussis	4=0.12	1=0.05	3=0.25
Cholera	1=0.03	1=0.05	0=0.00
Febris intermittens	1=0.03	1=0.05	0=0.00
Lead poisoning	2=0.06	1=0.05	1=0.08
Tobacco poisoning	1=0.03	1=0.05	0=0.00
Unknown	16=0.50	11=0.55	5=0.42

BLINDNESS FROM UNKNOWN CAUSES.

	Total.	Males.	Females.
	Per Cent.	Per Cent.	Per Cent.
	269=8.40	**168=8.36**	**101=8.45**

SUMMARY.

	Total.	Males.	Females.
	Per Cent.	Per Cent.	Per Cent.
Congenital	551= 17.19	327=16.32	224=18.75
Idiopathic eye disease	1060= 33.08	626=31.16	434=36.32
Injuries	261= 8.15	202=10.06	59= 4.94
General diseases	1063= 33.17	686=34.15	377=31.54
Unknown causes	269= 8.40	168= 8.36	101= 8.45
	3204=100%		

Again we have 2,528 cases of blindness of both eyes among both adults and children observed by Schmidt-Rimpler, Stolte, Uhthoff, Hirschberg, Landesberg, Bremer, Seidelmann, Katz, Magnus:

CONGENITAL BLINDNESS.

	No.	Per Cent.
Anophthalmus and microphthalmus	27	1.068
Megalophthalmus	11	0.435
Cataracta complicata (accreta)	3	0.119
Choroiditis	4	0.158
Atrophia nervi optici	19	0.751
Retinitis pigmentosa	19	0.751
Atrophia retinæ	2	0.079
Anomalies of the cornea	5	0.198
Tumors	1	0.039
Undetermined	6	0.237
	97	

Digitized by Illinois College of Optometry

BLINDNESS FROM IDIOPATHIC EYE DISEASE.

	No.	Per Cent.
Blennorrhœa neonatorum	275	10.876
Trachoma and blennorrhœa in adults	240	9.492
Conjunctivitis diphtheritica	9	0.356
Cornea, diseases of	204	8.068
Irido-choroiditis, cyclitis, iritis	224	8.860
Choroiditis myopica	24	0.949
Choroiditis, choroido-retinitis	28	1.107
Retinitis pigmentosa acquisita	32	1.266
Retinitis apoplectica	3	0.119
Neuro-retinitis	20	0.791
Sublatio retinæ	120	4.746
Glaucoma	227	8.978
Atrophia nervi optici	196	7.751
Tumors of eye and vicinity	9	0.356
Undetermined	85	3.362
	1696	

BLINDNESS FROM INJURIES.

	No.	Per Cent.
Direct injury or wounds	102	4.034
Unsuccessful operations	49	1.938
Injuries of the head	7	0.277
Sympathetic ophthalmia	114	4.509
	272	

BLINDNESS FROM CONSTITUTIONAL DISEASES.

	No.	Per Cent.
Syphilis	12	0.470
Blennorrhœa gonorrhoica[1]	23	0.910
Scrofula	1	0.039
Irido-choroiditis from meningitis	36	1.424
Atrophia vel neuritis optica cerebralis	176	6.961
Atrophia optica spinalis	59	2.333
Atrophia vel neuritis optica from hæmetemesis	10	0.396
Atrophia optica from emesis	2	0.079
Atrophia optica from hemorrhoidal hemorrhage	1	0.039
Atrophia optica from erysipelas faciei	2	0.079
Atrophia optica with insanity	1	0 039
Atrophia optica with epilepsy	4	0.158
Atrophia optica after dysentery	2	0.079
Retinitis nephritica	5	0.198
Typhus	24	0.949
Rubeola	16	0.633
Scarlatina	13	0.514
Variola	56	2.216
Unknown exanthemata	6	0.235
Heart disease	1	0.039
Pregnancy and parturition	11	0.431
Toxic amaurosis	1	0.039
Orbital diseases	1	0.039
	463	

Congenital diseases, 97; Idiopathic eye diseases, 1,696; Injuries and wounds, 272; Constitutional diseases, 463. Total, 2,528.

[1] This item ought to come among idiopathic diseases.

Digitized by Illinois College of Optometry

Among cases of congenital blindness *cataract* takes the first place, there being 20.51% of this class. The eye was in many instances otherwise defective, such as by absence of the iris, coloboma of the iris, etc. In all, the impossibility of securing useful vision by curing the cataract, indicated accompanying defect in the percipient structures. That this should be probable, is suggested by the large number of cases belonging to other classes in which these structures were involved, while the lens happened to escape. Among the 118 cases of cataract 74 were operated on, and in 44 no attempt was made.

It is understood that not only arrest of development but active disease during intra-uterine life gives rise to cataract.

Microphthalmus was found in 81 cases. In three patients, while one eyeball was abnormally small, the other eye was not developed at all. In most cases other complications existed, viz., in 20 there was cataract, in 12 coloboma iridis, etc. The possibility of perception of light is not always excluded. I have seen a case at the N. Y. Ophth. Soc., by whom presented I regret to have forgotten, in which both eyes were microphthalmic and vision good. Nystagmus is common, and such patients often have the trick of digging their fingers into the orbits to excite phosphenes. The theory has been advanced that in some instances the condition is due, not to arrest of development, but to intra-uterine panophthalmitis and consequent phthisis bulbi. In some cases the eyes were not larger than peas, and in respect to size there is great variation.

Megalophthalmus as a congenital condition occurs only one-third as often as microphthalmus, and it has been variously interpreted. Regarded by some as the result of uveitis serosa, others have spoken of it as being sometimes a glaucoma. The details of the pathological anatomy may be found in a paper by Grahamer.[1]

Blennorrhœa neonatorum furnishes the largest number of cases of blindness, both in the table of young persons and among adults; in the former reaching 23.5% and in the latter 10.8%. Among the latter the number would naturally be fewer because they less frequently live in asylums. That the future will show a great reduction in the number of blind persons from this cause, there can be no doubt, since the early antiseptic proceedings recommended by Credé and Haussmann both for the child and the mother are being adopted in public and private practice. In addition to what has been said already (see p. 333), statistics gathered by Dr. Howe,[2] of Buffalo, N. Y., lend additional weight to the importance of the treatment. He brings together two groups of cases, in one group 8,798 cases in

[1] Graefe's Archiv f. Oph., xxx., 3, p. 265.
[2] Trans. Med. Soc. State of New York, p. 263, 1889.

Digitized by Illinois College of Optometry

which no precautions were taken, and another group of 8,574 cases in which one drop of a 2% nitrate of silver solution was applied to the eye. In the former the cases of blennorrhœa reached 8.66%, in the latter it was reduced to 0.656%.

Glaucoma contributes almost 10% of the cases of blindness, and naturally it scarcely shows among the young subjects.

Sympathetic ophthalmia claims its victims among all ages—viz., 4.58% among the young and almost the same among the older, viz., 4.5%. The number of blind persons through unsuccessful operation upon adults, viz., 49, were almost all cases of cataract; and the majority of them, viz., 30, belong to one operator, Katz, of Düsseldorf. No explanation is given of the cause or of the method of operating.

Further comment on the tables is needless. To such as choose to study them many fruitful suggestions will occur. Papers which may be studied are "Die Blindheit," Magnus, Breslau, 1883; "Die Jugend-Blindheit," Magnus, Wiesbaden, 1886; "Die Ursachen und die Verhütung der Blindheit," Fuchs, Wiesbaden, 1885; also "The Blind of New York," by H. S. Oppenheimer, Trans. Am. Oph. Soc., 1891, p. 156, a careful analysis of 572 cases; report of the committee on causes and prevention of blindness, Trans. Am. Oph. Soc., 1890, p. 531.

Digitized by Illinois College of Optometry

BIBLIOGRAPHY.

Treatises.

Mackenzie: Treatise on Diseases of the Eye. London, 1840.
Jaeger: Grauen Staar, etc. Inaug. Dissert., 1844.
Dalrymple: Pathology of the Human Eye. London, 1852.
Sichel, J.: Iconographie Ophthalmologique. Paris, 1852–1859.
Jaeger: Beiträge zur Pathologie des Auges. Wien, 1856.
Hasner: Beiträge über Augenheilkunde. Prag, 1860.
Jaeger: Ueber die Einstellung des Dioptrischen Apparates im menschlichen Auge. Wien, 1861.
Liebreich: Atlas d'Ophthalmoscopie. Paris, 1863.
Schweigger: Vorlesungen über den Gebrauch des Augenspiegels. Berlin, 1864.
Donders: Accommodation and Refraction of the Eye. London, 1864.
Helmholtz: Physiologische Optik. Leipzig, 1867.
Lawson: Injuries of the Eye, Orbit, and Eyelids. London, 1867.
Knapp: Die intraoculären Geschwülste. Carlsruhe, 1868.
Albutt: The Ophthalmoscope in Diseases of the Nervous System and of the Kidneys. London, 1871.
Anstie: Neuralgia. New York, 1872.
Cohn: Schussverletzungen des Auges. Erlangen, 1872.
Magnus: Ophthalmoscopischer Atlas. Leipzig, 1872.
Hybord: Du Zona Ophthalmique. Paris, 1872.
Mauthner: Vorlesungen über die Optischen Fehler der Augen. Wien, 1872.
Stellwag: On the Eye. Fourth Am. Ed. New York, 1873.
Fick: Handbuch der Physiologie. Wien, 1874.
Magnus: Die Sehnervenblutungen. Leipzig, 1874.
Erichsen: On Railway and Other Injuries of the Nervous System. London, 1866; New York, 1875.
Galezowski: Traité des Maladies des Yeux. Paris, 1875.
Pagenstecher und Genth: Atlas der pathologischen Anatomie des Augapfels. Wiesbaden, 1875.
Abadie: Traité des Maladies des Yeux. Paris, 1876.
Bouchut: Ophthalmoscopie Médicale. Paris, 1876.
Carter: On the Eye. Edited by Dr. Green. Philadelphia, 1876.
Galezowski: Traité d'Ophthalmoscopie. Paris, 1876.
Dickinson: Diseases of the Kidney. London, 1877.
Kühne: Untersuchungen aus dem physiologischen Institut der Universität Heidelberg, 1877–1880.
Gowers: Medical Opthalmoscopy. London, 1879.

Digitized by the Illinois College of Optometry

Horner: Krankheiten des Auges im Kindesalter. Handbuch der Kinderkrankheiten. Gerhardt, 1879.
Klein: Lehrbuch der Augenheilkunde. Wien, 1879.
Landolt: Examination of the Eyes. Translated by Dr. Burnett. Philadelphia, 1879.
Perrin et Poncet: Atlas des Maladies profondes de l'œil. Paris, 1879.
Rood: Modern Chromatics. New York, 1879.
Sichel fils: Traité d'Ophthalmologie. Paris, 1879.
Vetsch: Ueber den Frühjahrscatarrh der Conjunctiva. Inaugural Dissertation. Zurich, 1879.
Wecker and Landolt: Traité complet d'Ophthalmologie. Tome premier, première partie. Paris, 1879.
Zehender: Lehrbuch der Augenheilkunde. Stuttgart, 1879.
Alt: Lectures on the Human Eye (Histology and Pathology). New York, 1880.
Arlt: Klinische Darstellung der Krankheiten des Auges. Wien, 1881.
Bernhardt: Hirngeschwülste. Berlin, 1881.
Cohn: Real-Encyclopedia der Heilkunde. Wien, 1880.
Emmert: Auge und Schaedel. Berlin, 1880.
Flint: Practice of Medicine. Philadelphia, 1881.
Gerlach: Beiträge zur Normalen Anatomie des menschlichen Auges. Leipzig, 1880.
Graefe and Saemisch (abbreviated to G. and S.): Handbuch der gesammten Augenheilkunde, in 7 vols. Leipzig, 1880. (The names of the contributors are Profs. Arlt, Arnold, Jr., Aubert, Becker, Berlin, Förster, Alfred Graefe, Hirsch, Iwanoff, Landolt, Leber, Leuckart, Manz, Merkel, Michel, Nagel, Saemisch, Sattler, Schirmer, Schmidt, Snellen, Schwalbe, Waldeyer, v. Wecker.)
Jeffries: Color blindness. Boston, 1880.
Le Conte: Sight. New York, 1881.
Meyer: Maladies des Yeux. Paris, 1880.
Munk: Ueber die Functionen der Grosshirnrinde. Berlin, 1881.
Nagel: Mittheilungen aus der Ophthalmiatrischen Klinik in Tübingen. 1880.
Nettleship: Diseases of the Eye. Am. Ed. Philadelphia, 1880.
A. Robin: Des Troubles oculaires dans les Maladies de l'Encéphale. Paris, 1880.
Schweigger: Handbuch der Augenheilkunde. Fourth Edition. Berlin, 1880.
Soelberg Wells: On the Eye. Edited by Dr. Bull. Philadelphia, 1880.
Wilbrand: Hemianopsia. Berlin, 1881.
Fuchs: Das Sarcom des Uvealtractus. Wiesbaden, 1882.
Haussmann: Die Bindehaut-Infection der Neugeborenen. Stuttgart, 1882.
Moore: Fünf Lustren Ophthalmologischer Wirksamkeit. Wiesbaden, 1882.
Rothmund: Mittheilungen aus der Klinik zur München. 1882.
Magnus: Die Blindheit. Breslau, 1883.
Ross: Diseases of the Nervous System. New York, 1883.
Wernicke: Lehrbuch der Gehirnkrankheiten. Cassel, 1881-1883.
Aschman: Wounds of the Optic Nerve. Inaug. Thesis. Zurich, 1884.
Bull: The Ophthalmoscope and Lues. Christiana, 1884.
Juler: Handbook of Ophthalmic Science and Practice. London, 1884.
Meynert: Psychiatrie. Wien, 1884.
Michel: Lehrbuch der Augenheilkunde. Wiesbaden, 1884.
Schmidt-Rimpler: Augenheilkunde und Ophthalmoscopie. Braunschweig, 1884. Am. Ed., Wm. Wood & Co., 1889.

Digitized by the Internet Archive in 2010 with funding from Microsoft Corporation

Swanzy: Handbook of Diseases of the Eye. London, 1884.
Walter: Klinische Studien über Netzhautablösungen. Inaug. Dissert. Zurich, 1884.
Edinger: Zehn Vorlesungen über den Bau der nervösen Centralorgane. Leipzig, 1885.
Fuchs: Die Ursachen und die Verhütung der Blindheit. Wiesbaden, 1885.
Ziegler: Haab: Pathologische Anatomie des Auges. Jena, 1885.
Landolt: The Refraction and Accommodation of the Eye. Translated by Culver. Edinburgh, 1886.
Schwalbe: Anatomie der Sinnesorgane. Erlangen, 1886.
Loring: Text-book of Ophthalmoscopy. Part I. New York, 1886.
Magnus: Die Jugendblindheit. Wiesbaden, 1886.
Da Gama Pinto: Untersuchungen über intraoculäre Tumoren. Wiesbaden, 1886.
Wedl und Bock: Pathologische Anatomie des Auges. Atlas. Wien, 1886.
Bunge: Ueber Exenteration des Auges. Halle, 1887.
Gowers: Diseases of the Brain. Philadelphia, 1887.
Nordenson: Die Netzhautablösung. Wiesbaden, 1887.
Stilling: Untersuchungen über die Entstehung der Kurzsichtigkeit. Wiesbaden, 1887.
Herzog Karl Theodor: Ein Beitrag zur pathologischen Anatomie des Auges. München, 1887.
Wilbrand: Die Seelenblindheit. Wiesbaden, 1887.
Alexander: Syphilis und Auge. Wiesbaden, 1888.
Gowers: Diseases of the Nervous System. Phila., 1888.
Obersteiner: Anleitung beim Studium des Baues der nervösen Centralorgane. Wien, 1888.
Vossius: Grundriss der Augenheilkunde. Leipzig und Wien, 1888.
Fuchs: Lehrbuch der Augenheilkunde. Leipzig und Wien, 1889.
Magnus: Die Entstehung der reflectorischen Pupillenbewegung. Breslau, 1889.
Mauthner: Vorträge der Augenheilkunde. Wiesbaden, 1879–1889.
Wilbrand: Die hemianopische Gesichtsfeld-Formen und das optische Wahrnehmungszentrum, Atlas, Wiesbaden, 1890.
Berger und Tyrman: Die Krankheiten der Keilbein-Höhle und des Siebbein-Labyrinthes, etc., Wiesbaden, 1886.
M. Foster: Text-book of Physiology. 5th edition. Macmillan, London, 1891.
Dana: Text-book of Nervous Diseases. Wm. Wood & Co., 1892.
Ferrier: The Localization of Cerebral Disease. 1879.
M. P. Jacobi: Hysteria and Brain Tumors. Putnam Sons, New York, 1888.
Berger: Anatomie Normal et Pathologique de l'Œil. Paris, 1893.
Charcot: Clinique des Maladies du Système Nerveux, T. 1. New York, 1892.
Reference Handbook of the Medical Sciences. Vols. I. to IX. Wm. Wood & Co., 1886–1893.
Starr: Brain Surgery. Wm. Wood & Co., 1893.
Gray: Nervous and Mental Diseases. Lea Brothers & Co., Philadelphia, 1893.
Berger: Les Maladies des Yeux dans leurs Rapports avec le Pathologie Générale. Paris, 1892.
De Schweinitz: Diseases of the Eye. W. B. Saunders, Philadelphia, 1892.
Herter: The Diagnosis of Diseases of the Nervous System. 1892.
Knies: Das Sehorgan und seine Erkrankungen. Wiesbaden, 1893.
Cohn: Uterus und Auge. Wiesbaden, 1890.
Norris and Oliver: A Text-book of Ophthalmology. Lea Brothers & Co., Philadelphia, 1893.

Digitized by the Internet Archive of Optometry

Wilbrand: Ophthalmiatrische Beiträge zur Diagnostik der Gehirn-Krankheiten. Wiesbaden, 1884.
Wilbrand and Saenger: Ueber Sehstörungen bei functionellen Nervenleiden. Leipzig, 1892.
Cohn: Lehrbuch der Hygiene des Auges. Wien und Leipzig, 1892.
Henschen: Klinische und Anatomische Beiträge zur Pathologie des Gehirns. Erster und zweiter Theilen. Upsala, 1890, 1892.
Fischer: Ueber die Embolie des Arteria Centralis Retinæ. Leipzig, 1891.

JOURNALS, REPORTS, TRANSACTIONS, ETC.

A. v. Graefe's Archiv für Ophthalmologie. Berlin.
Annales d'Oculistique. Brussels, Belgium.
Klinische Monatsblätter für Augenheilkunde. Zehender. Stuttgart.
Centralblatt für Augenheilkunde. Hirschberg. Leipzig.
Archives of Ophthalmology. Knapp and Hirschberg. New York and Wiesbaden.
Archives d'Ophthalmologie. Panas, Landolt, Poncet. Paris.
Transactions of the American Ophthalmological Society. New York
Ophthalmic Hospital Reports. London.
Brain: A Journal of Neurology. London.
American Journal of Medical Sciences. Lea & Co. Philadelphia.
Medical Record. Wm. Wood & Co. New York.
Medical Journal. D. Appleton & Co. New York.
Jahresbericht der Augenheilkunde. Nagel, Vols. I to VII., 1870–1876. Michel, Vols. VIII. to XVIII., 1877–1888.
Trans. of the Fifth International Med. Congress, Phila., 1877.
Medical News, Philadelphia.
American Practitioner.
Zeitschrift für Heilkunde.
Journal of Nervous and Mental Disease. New York.
American Journal of Ophthalmology. St. Louis.
Ophthalmic Review. Manchester, Eng.
St. Thomas Hospital Reports. London.
Transactions of the Ophthalmological Society of the United Kingdom. Churchill. London.
Recueil d'Ophthalmologie. Paris.
Brooklyn Medical Journal. Brooklyn, N. Y.
Bericht der Ophthalmologischen Versammlung zu Heidelberg.
Boston Medical and Surgical Journal. Boston.
Transactions of the Medical Society of the State of New York. Albany, N. Y.
Birmingham Medical Review. Birmingham, Eng.
Bulletins et Mémoires de la Société Française d'Ophthalmologie.
Medico-Chirurgical Transactions. London.
Archiv für Psychiatrie.
Berliner klinische Wochenschrift. Berlin.
British Medical Journal.
Medical Press and Circular. London.
Trans. Am. Med. Association. Chicago, Ill.
The Ophthalmic Record. Nashville, Tenn.
Annals of Ophthalmology and Otology. St. Louis, Mo.
The Review of Insanity and Nervous Disease. Milwaukee, Wis.

Many books and treatises and other sources of information are referred to in the text which are omitted in the above lists.

Digitized by the Internet Archive of Optometry

INDEX.

Abducens, nucleus of, 155
Abscess, cerebral, 163, 671
intra-cranial, 726
of antrum, 726
of brain, 163, 671
of ethmoid, 726
of frontal sinus, 726
of lachrymal sac, 295
of orbit, 731, 732
pre-lachrymal, 306
Abrine, 355
Abrus precatorius, 354
Accommodation, 16 *et seq.*, 61
and convergence, relation between, 85
binocular, 18
changes in crystalline lens in, 17
errors of, 61
mechanism of, 16 *et seq.*
monocular, 18
paralysis of, 66
paresis of, 66
range of, 17 *et seq.*
relative, 18 *et seq.*, 138
spasm of (see Spasm of accommodation)
table showing range of, at different ages, 18
Acetate of lead, 234
in blepharitis, 253
Actual cautery, in corneal inflammation, 233
in hypopyum keratitis, 399, 401
in trachoma, 233
Acuity of vision, 21, 24, 37, 70
improved by glasses, 90
peripheral, 26
Adenoma of Meibomian glands, 260
Adenoid tissue of conjunctiva, 309
Advancement, capsular, 224
in muscular asthenopia, 225, 229
in ocular paralysis, 167 *et seq.*
in strabismus, 190
of ocular muscles, 169 *et seq.*
author's method, 169 *et seq.*, 229, 230
various methods, 169
of Tenon's capsule, 190
versus tenotomy, 196
After-images, 52
Agraphia, 656, 657, 703, 714
Albinism, 574
Albugo, 378, 411
Albuminuria, 612, 672, 716
of pregnancy, 613, 620, 621, 635
induction of labor in, 622
Alcoholic amblyopia, defective color sense in, 28
Alcoholism, 66
Alexia, 656, 703, 714
Alternating anæsthesia, 149
motor paralysis, 149
Amaurosis (see Amblyopia)
congenita, statistical tables, 772, 773
due to fifth nerve injury, 754
fugax, 702
in young children, 718
Amblyopia, 694 *et seq.*
alcoholic, 28, 678, 682 *et seq.*
central, 181
congenital, 609, 699
crossed, 645, 714
ex abusu, 28, 678, 682 *et seq.*
ex anopsia, 699
following orbital fracture, 695, 757, 759
from general hemorrhage, 698
from irritation of teeth, 704
from lead, 700
from osmic acid, 699
from quinine, 700
from salicylic acid, 700
from suppression of menstruation, 701
from tobacco, 28, 435, 678, 682 *et seq.*
glycosuric, 700
hysterical, 681, 701
in spinal cord concussion, 696, 697
medial, 181
monocular, congenital, 181 *et seq.*
in strabismus convergens, 180, 181
without squint, 181 *et seq.*
of diabetes, 622
of epilepsy, 701
of pregnancy, 701
toxic, 662, 678, 682 *et seq.*, 699
traumatic, 694 *et seq.*
treatment of, 705
uræmic, 700
varieties of, 694
without ophthalmoscopic lesions, 732, 759

Digitized by Illinois College of Optometry

Ametropia, 69, 129
Amimia, 656, 657
Amnesia, 714
Amotio retinæ, 630
Amyloid degeneration of conjunctiva, 357, 362
tumors, 260
Anæmia, 66, 208
Anæsthesia, alternating, 149
of cornea in glaucoma, 551, 559
Anæsthetics, 235 *et seq.*
in examination of eyes, 37
Anatomy of base of brain, 146 *et seq.*
of brain, 145 *et seq.*, 653 *et seq.*
of choroid, 573
of conjunctiva, 247 *et seq.*, 308 *et seq.*
of cornea, 371 *et seq.*
of cranium, 145
of crystalline lens, 471
of eyelid, 247 *et seq.*
of frontal bone, 145
of globe, 1
of iris, 430 *et seq.*
of lachrymal apparatus, 292 *et seq.*
of medulla, 147 *et seq.*
of ocular muscles, 132 *et seq.*
of optic nerve, 641 *et seq.*
of optic nerve, compared with ophthalmoscopic picture, 48
of orbit, 144, 249, 722 *et seq.*
of pons, 147 *et seq.*
of retina, minute, 594 *et seq.*
of sclera, 424
of visual path (see Hemianopia)
of vitreous body, 512
Anchyloblepharon, 291
Aneurism, 163, 437
orbital, 744, 746
Angioma of choroid, 593
of conjunctiva, 357, 360
of orbit, 735, 736, 744
Angle alpha, 14, 15, 114, 178
in hyperopia, 83
gamma, 14, 114, 178
in hyperopia, 83
in myopia, 102
of iris, 430
secretory, 8
Aniridia with glaucoma, 562
Anisometropia, 86, 101, 128 *et seq.*
Anophthalmus, atrophy of visual apparatus in, 646
congenital, 646
Anterior chamber, 2, 371, 430
in glaucoma, 54, 551
ciliary arteries, 7, 573
perforated space, 147, 641, 642, 644
principal focus, 11
pyramid of medulla, 146
Antero-posterior diameter of globe, 1
Antimetropia, 129
Antisepsis, 233
Antiseptics in operative work, 234 *et seq.*
Antrum, tumors of, 736, 750
Aphasia, 175, 714
mixed, 657
motor, 656, 657
sensory, 656
Aphemia, 656, 657
Apoplexy, 435, 606, 715
Apraxia, 649, 656
Aqueductus Sylvii, 146, 147, 150, 152, 641
Aqueous chamber, 2
humor, 2
derivation of, 4
effects of section of cervical sympathetic on secretion of, 9
Aquo-capsulitis, 442
Arciform fibres, 148
Arcus senilis, 374, 410
lentis, 473
Area of Martegiani, 512
Argyll-Robertson pupil, 162, 435, 688
Argyria conjunctivæ, 318
Aristol, 234
Arteria centralis retinæ, 6
embolism of, 601
Arterial pulsation, 598
in glaucoma, 549, 554
Arteries, anterior ciliary, 7, 424
at base of brain, 145
long ciliary, 7, 424, 573
posterior ciliary, 6, 424
short ciliary, 6, 424
Arterio-sclerosis, general, 620
Arteritis obliterans, 163
Artery, hyaloid, 8
internal carotid, 145
Artificial eyes, use of, 768 *et seq.*
pupil, in corneal opacity, 412
vitreous, 418, 545, 769
Asepsis, 233
Asthenopia, 129, 197 *et seq.*
accommodative, 85, 88, 197
due to nasal catarrh, 217
in anisometropia, 129
in myopia, 94
muscular, 197, 202 *et seq.*
cases of, 227 *et seq.*
exciting causes of, 208 *et seq.*
general considerations, 206 *et seq.*
in myopia, 108
myotic, 207
neurotic, 207
objective symptoms, 209 *et seq.*
operations for, 224 *et seq.*
prisms in, 223
refraction in, 221 *et seq.*
spasm of muscles in, 225, 227
subjective symptoms, 209
treatment of, 219 *et seq.*
without refractive error, 221
neurasthenic, 197
reflex, 197
subdivisions of, 197
Asthenopic symptoms in astigmatism, 127
in hyperopia, 87

Digitized by Illinois College of Optometry

Astigmatism, 69, 111 *et seq.*, 375
acquired, 111
against the rule, 114
apparatus for demonstrating, 113
caused by pterygium, 370
compound, 112, 114
hyperopic, 112
myopic, 112
congenital, 111
correction of, 73 *et seq.*
diagnosis of, 118 *et seq.*
diagrams illustrating, 113
due to pressure of lids, 125
following cataract extraction, 502
Green's tests for, 118 *et seq.*
hyperopic, 112
irregular, 111, 126
lenticular, 114
in cataract, 480
mathematical theory of, 113
methods of testing, 121 *et seq.*
mixed, 112, 115
myopic, 112
ophthalmoscopic picture in, 73 *et seq.*
Pray's test types for, 121
regular, 111 *et seq.*
simple, 112, 114
symptoms of, 117
varieties of, 112
Asymmetry of skull, 724
Atrophic ring in myopia, 99
Atropia, 240, 241
in asthenopia, 198
in astigmatism, 120 *et seq.*
in castor oil, 240
in correction of errors of refraction, 70 *et seq.*
in hyperopia, 84, 86, 89
in muscular asthenopia, 219
in myopia, 106, 107
in spasm of accommodation, 65
in strabismus, 186, 187
toxic effects of, 240 *et seq.*, 446, 447
Atropine conjunctivitis, 314
Axis of cornea, 14, 178
of globe, 1, 14

BANDAGES, 231, 232
Basal paralysis of ocular muscles, 158
Basedow's disease, 163, 251, 764 *et seq.*
treatment of, 766 *et seq.*
Base of brain, anatomy of, 146 *et seq.*
Benzoate of sodium, 233
Bident, Agnew's, for dislocated lens, 476
Binocular accommodation, 18
fusion, cerebral element in, 195
vision, 132 *et seq.*
conditions of, 135 *et seq.*
in anisometropia, 129
limitations of, 138
Blenorrhœa, 319
chronic, 340, 350, 351
neonatorum, 775
Blepharitis marginalis, 252, 256
Blepharo-adenitis, 252
Blepharophimosis, 276, 278
Blepharoplasty, 271 *et seq.*
author's methods, 272 *et seq.*
Blepharospasm, 155, 281
section of supra-orbital nerves in, 695
Blind headache, 599
spot, 20, 181
size of, 26
Blindness caused by pressure on globe, 695
cerebral, 694
congenital, 775
statistical tables, 772, 773
mental, 694, 703
mind, 656, 714
monocular, undiscovered, 718
psychic, 649, 654, 655, 656, 657, 703
simulated, 719
methods of detecting, 720, 721
uræmic, 616
Blisters, 244
in ocular paralysis, 166
Blood-vessels, conjunctival, 7
of retina, 49
Blue light after cataract extraction, 31
Boiled water in operative work, 234
Bony growths in conjunctiva, 357
Borax, 233
Boric acid, 233
in operative work, 234
Bowman's director, 299, 300
membrane, 371, 372
Brachium, 150, 643, 646
anticum, 644, 646
posticum, 645, 646
Brain, abscess of, 671
anatomy of, 145 *et seq.*, 653 *et seq.*
arteries at base of, 145
diseases, 692
lesions, 688 (see also Hemianopia)
localizing areas of, 654 *et seq.*
physiology of, 653 *et seq.*
tumor, 159, 163, 664, 665, 670, 671, 672, 675, 676, 677, 678, 689, 715 (see also Hemianopia)
Broca's convolution, 657, 703
Bromide of potash before operations, 238
Brücke's dissecting spectacles, 215
lenses, 36
Bulbar paralysis, 155, 162
Buphthalmus, 553
Burns of eye, 287 *et seq.*, 529, 530

CALABAR bean, 241
Calcareous deposit in conjunctiva, 357, 414
in cornea, 414
Calcarine fissure, 647, 649
Canal of Cloquet, 8, 512, 558
of Fontana, 4
of Petit, 8, 462, 472, 512
hemorrhage into, 513

Digitized by Illinois College of Optometry

Canal of Schlemm, 4, 6, 8, 373, 463, 558, 568
of Sylvius, 146, 147
Canaliculi, 292
chalky concretions in, 294
double, 294
leptothrix in, 294
occlusion of, 294
slitting of, 299
stricture of, 294
Canalis opticus, fracture of, 757, 759
section of skull through, 758
Cancer of cornea, 423
Cancerous disease of conjunctiva, 357, 359
Canities, 261
Cantholysis, 278, 388
in trachoma, 354, 357
Canthoplasty, 266, 276, 278, 388
in trachoma, 356, 357
Canthotomy, 265
in purulent conjunctivitis, 329
in trachoma, 354
Capsular advancement, 224
Capsule of lens, 2
of Tenon, 1, 168, 169, 424
Capsulitis in iritis, 445
Capsulotomy in cataract extraction, 499
peripheral, 501
Carbolic acid as a disinfectant, 233, 235
Cardinal points, 11, 12
table of, 13
Caries in dacryocystitis, 295, 296, 305, 306
of cranial bones, 584
Caruncle, 169, 247, 308
retraction of, 189, 190
Caruncula lachrymalis (see Caruncle)
Cataract, 478 *et seq.*
absorption of, 489, 490
anterior polar, 478, 482
artificial ripening of, 494, 495
black, 481
capsular, 478, 501
capsulo-lenticular, 478
causes of, 479
complicated, 478, 480, 486
complications in, 485
congenital, 478, 479, 480, 482, 483, 484, 490, 491, 775
diabetic, 479, 488
diagnosis of, 484 *et seq.*
discission of, 490, 491
disturbance of vision in, 480
electricity in, 488
extraction, 234 *et seq.*, 489, 492 *et seq.*
after-treatment in, 504 *et seq.*
antisepsis in, 496
astigmatism following, 502
complications following, 506 *et seq.*
danger of too small wound in, 499
delirium after, 232
Cataract extraction, entanglement of capsule after, 503
Graefe's linear, 495
incarceration of iris after, 502
instruments for, 238 *et seq.*, 503 *et seq.*
intra-ocular hemorrhage after, 489
iridectomy in, 499
iritis following, 506, 507
Lebrun's incision in, 495
Liebreich's incision in, 495
prolapse of iris after, 502, 505
purulent infiltration of wound after, 506
removal of capsule in, 501
Ring's mask after, 505
simple, 501 *et seq.*
simple linear, 492, 493
statistics of, 503
striped keratitis following, 507
toilet of eye after, 500
use of syringe in, 496, 500
various sections in, 496
fluid, 478
focal illumination of, 481
following iridectomy, 567
galvanism in, 488
glasses, 58, 510, 511
hard, 478, 479, 480, 495
hypermature, 479, 480
idiopathic, 480, 481
incipient, 481
inflammatory, 478, 479
in glaucoma, 551
in myopia, 101
juvenile, 478
lamellar (laminated), 474, 480, 482, 490, 492
lenticular, 478
astigmatism in, 480
light preception in, 485
massage in, 488
membranous (see secondary)
mixed, 480
Morgagnian, 479, 480
myopia produced by, 480
objective symptoms in, 480 *et seq.*
panophthalmitis following discission of, 491
partial, 478, 480
pathology of, 478 *et seq.*
percentage of success in operations for, 488
posterior polar, 480, 482
prognosis in, 486
progressive, 480
rate of progress of, 480, 487
reclination (couching) of, 490
ripe, 480
secondary, 507 *et seq.*
complicated, 508, 509
senile, 478, 480, 481, 485
simple, 480
soft, 478, 479, 480, 486, 492
spontaneous cure of, 488

Digitized by the Illinois College of Optometry

Cataract, spontaneous improvement of vision in, 487
spontaneous luxation of lens in, 488
stage of irritation in, 487
subjective symptoms in, 480
symptoms of, 480 *et seq.*
traumatic, 478, 480, 482, 520, 522
zonular, 474, 480, 482, 490, 492
Catarrho-rheumatic ophthalmia, 314
treatment of, 318
Catoptric test, 474
Cauterization in conical cornea, 422
in trachoma, 350, 354, 356
Cavernous sinus, 144, 145
rupture of carotid in, 746
thrombosis of, 730, 732, 733, 744
tumors of orbit, 735, 736, 744
Cellulitis, orbital, 729 *et seq.*
Centre of motion, 14
Cerebellum, 146, 658
lesions of, 658
peduncles of, 147
tumor of, 671, 675, 709
Cerebral apoplexy, 435, 606
blindness, 694
embolism, 435
hemorrhage, 163, 609
localization, 156, 157, 653 *et seq.*, 675
tumor (see Brain tumor)
Cerebro spinal meningitis, 435, 514, 516, 584, 585, 683
Cervical sympathetic (see Sympathetic, cervical)
Chalazion, 254
forceps, 254
Chalky concretions in canaliculi, 294
Chamber, anterior, 2
aqueous, 2
posterior, 2
Chancre of conjunctiva, 358
of eyelid, 259, 358
Chemosis, 327, 401
Cherry red spot, 661
in embolism of central retinal artery, 602, 604
Cheyne-Stokes respiration, 438
Chiasm, optic, 145, 147, 641, 642, 643, 644, 646, 654, 715
arrangement of fibres in, 643, 652
Chloroform anæsthesia, 237
Chlorosis, 672, 677
Choked disc, 663, 674
Cholera, 600, 660
Cholesterin in vitreous, 513
Chondroma of choroid, 593
Chorio-capillaris, 559, 573
Choroid, 3, 5
anatomy of, 573
colloid degeneration of, 50, 575, 577, 616
coloboma of, 574
detachment of, 588
embolism in, 576, 584
Choroid, hemorrhages of, 576, 587
laceration of, 587
ossification of, 593
rupture of, 520
sarcoma of, 592, 593, 632, 639
supratraction of, 97 *et seq.*
tubercle of, 578, 588
tumor of, 589 *et seq.*
vessels of, 52
visibility of, 52
Choroidal atrophy, 578, 579
senile, 582
changes in myopia, 581 *et seq.*
crescent, 96 *et seq.*, 105
in myopia, 96 *et seq.*, 105
mode of formation of, 97
ring in glaucoma, 559
Choroidea (see Choroid)
Choroiditis, 575 *et seq.*
acute, 580
chronic, 580
circumscripta, 580
connective-tissue changes in, 577, 578, 580
disseminata, 579, 581, 624
exudative, 578
guttate, 580
hemorrhagic, 576
Hutchinson's classification of, 583
in myopia, 95
metastatic, 514, 584, 585
pathology of, 575 *et seq.*
prognosis in, 581
proliferation of pigment in, 577
suppurative, 584
symptoms of, 578 *et seq.*
syphilitic, 577, 579, 580
treatment of, 583
vascular changes in, 577
visual acuity in, 581
Cilia, 248
ensnaring of, 262
Ciliary body, 3, 5, 462 *et seq.*
glands of, 464
gumma of, 467
morbid growths in, 470
pars non plicata, 5
pars plicata, 5
ganglion, 17, 424, 432, 464, 724
muscle, 6, 462, 463
Ciliary muscle, action of, 6
in myopia, 100
mode of action of, 16
structure of, 63
nerves, 17, 464, 574
regeneration of, 542
processes, 3, 5, 462
region, wounds of, 521, 522
vessels, 463
Cilio-retinal vessels, 49
Cilio-spinal centre, 163
Circle of Haller, 6, 573
of Willis, 145
Circular venous sinus, 4
Circum-corneal hypertrophy of conjunctiva, 362, 363

Digitized by Illinois College of Optometry

Citrine ointment, 256
in blepharitis, 252
Cloquet's canal, 8, 512, 558
Cocaine, 235 *et seq.*, 240, 243
antidotes to, 237
corneal bleb produced by, 236
effect of, on tension, 236
in determining errors of refraction, 71
in facial neuralgia, 237
in glaucoma, 236
in hyperopia, 89
in operative work, 236
in tenotomy, 188, 224, 226
summary of effects of, 235 *et seq.*
toxic effects of, 237
with atropine, 237
with eserine, 237
Cold applications, 244
in iritis, 448
in purulent conjunctivitis, 323
douches in muscular asthenopia, 220
Collodion and cotton dressing, 266
Colloid bodies in optic papilla, 669
degeneration of choroid, 50, 575, 577, 616
Collyria, 245
Coloboma lentis, 473, 474
of choroid, 574
of eyelids, 280
of iris, 439, 775
of macula lutea, 105, 597
of sheath of optic nerve, 105, 658
Color-blindness, 28 *et seq.*, 700
heredity in, 28, 29
methods of testing, 29, 30
Color chart, 27
fields, 27 *et seq.*
half-blindness, 712
perception in glaucoma, 549, 550
sense, 27 *et seq.*
congenital defect of, 28
in optic nerve atrophy, 686, 689
in optic neuritis, 667
Colored rings in glaucoma, 551, 559
Columns of Burdach, 148
of Goll, 148
Commissure of Gudden, 643, 644, 645, 646, 647, 652, 715
of Meynert, 643, 644, 645, 646, 652, 657, 715
Conarium, 148
Condyloma of iris, 443
Congenital paralysis of ocular muscles, 173
Conical cornea, 126, 375, 419 *et seq.*, 461
Conjugate foci, 15
deviation, 161, 165, 175, 654, 655
cases of, 175, 176
movements of eyes, 157
Conjunctiva, 1, 247 *et seq.*, 308 *et seq.*
adenoid tissue of, 309
amyloid degeneration of, 357, 362
anatomy of, 247 *et seq.*, 308 *et seq.*
angioma of, 357, 360
Conjunctiva, blood-vessels of, 309, 310
bony growths in, 357
calcareous deposits in, 357
cancerous disease of, 357, 359
chancre of, 358
circum-corneal hypertrophy of, 362, 363
congenital fibrous growths in, 357, 359
cystoid growths in, 357, 359
dermoid growths in, 359
diseases of, 310 *et seq.*
epithelial disease of, 357, 359
epithelium of, 309
foreign bodies in, 367
foreign bodies on, 523
granuloma of, 358, 360
gummy tumor of, 358
herpes of, 363, 366
hyaline degeneration of, 343
hypertrophy of, 325, 331
laceration of, 520
lupoid disease of, 357, 358, 359
lymphoid tissue of, 309
mucous patches on, 358
nerves of, 310
nitrate of silver staining of, 318
papilloma of, 357, 358
pemphigus of, 362, 366
physiology of, 308 *et seq.*
pigment patches in, 357, 360
sarcoma of, 359
syphilitic lesions of, 357, 358
tubercular deposits in, 357, 358
vernal catarrh of, 362, 363
xerosis of, 360 *et seq.*
Conjunctival diseases, frequency of, 310
sac, germs in, 234
vessels, 7
Conjunctivitis, 311 *et seq.*
amyloid, 343
catarrhalis, 313 *et seq.*
complications of, 315
duration of, 315
sequelæ of, 315
treatment of, 316 *et seq.*
croupous, 332 *et seq.*
diphtheritic, 332 *et seq.*
due to atropine, 314
follicular, 314, 340
granular (see Trachoma)
in eczema, 363
metastatic, in gonorrhœa, 315
œdematosa, 313 *et seq.*
papillary, 314
phlyctenular, 363, 364
plastic, 332 *et seq.*
treatment of, 336 *et seq.*
purulent, 319, 325 *et seq.*
contagious nature of, 326
corneal complications in, 327, 330, 331
grattage in, 330, 331
protection of fellow eye in, 332
symptoms of, 327

Digitized by Illinois College of Optometry

Conjunctivitis, purulent, treatment of, 328 *et seq.*
vaseline treatment of, 328
vertical division of lid in, 329
secondary, 315
simplex, 313 *et seq.*
subdivisions of, 311
symptomatic, 315
syphilitic, 343
traumatic, 367
tuberculous, 343
Contusions of globe, 519
Conus in myopia, 96
Convergence, amplitude of, 85
Coquilles, 231
Corelysis, 449, 454, 461
Cornea, 1, 2, 35
actual cautery in ulceration of, 233
alteration of curve of, by pterygium, 370
anæsthesia of, in glaucoma, 551, 559
anatomy of, 371 *et seq.*
angle of aperture of, 374
anterior elastic lamina of, 371, 372
anterior principal focus of, 12
axis of, 14, 178
blunted sensibility of, in malarial keratitis, 388
calcareous deposit in, 414
canals of, 372, 373
cancerous ulceration of, 423
cell proliferation of, 375
conical, 375, 419 *et seq.*, 461
operative treatment of, 421 *et seq.*
curetting of, in trachoma, 354
in vascular keratitis, 388
curve of, 14
divisions of, 371
eczema of, 379 *et seq.*
epithelioma of, 423
epithelium of, 372
fibroma of, 423
fistula of, 406, 411, 414
focal distance of, 374
foreign bodies in, 523
herpes of, 383
index of refraction of, 10, 374
inflammation of, 375 *et seq.* (see Keratitis)
irregular astigmatism of margin of, 412
lacunæ of, 372
layers of, 371
limbus of, 3, 371
lymph channels of, 8
marginal vessels of, 371
morbid growths of, 423
nerves of, 374
nodal point of, 12
nutrition of, 373, 374
opacities of, 377, 378, 411 *et seq.*
detection of, by ophthalmometer, 126
optical centre of, 12
Cornea, papilloma of, 423
paracentesis of, 426
parenchyma of, 372
pathology of, 375 *et seq.*
pemphigus of, 385
perforation of, 405
in purulent conjunctivitis, 324, 327, 331
physiology of, 374 *et seq.*
posterior elastic lamina of, 371, 373, 377
posterior principal focus of, 12
radius of curve of, 371
refractive index of, 10, 374
ring ulcer of, 406
sarcoma of, 423
sclerosis of, 410, 427
sensibility of, 36
sloughing of, in plastic conjunctivitis, 337
staphyloma of, 411, 414
tattooing of, 412, 413, 461
transplantation of, 422
tubercular disease of, 423
ulceration of, 376, 377, 394, 405 *et seq.*
wounds of, 521
Corneal corpuscles, 372, 373
irregularity, after trachoma, 357
opacity, methods of detecting, 126, 377, 378
Corpora albicantia (mammillaria), 145, 642
candicantia (mammillaria), 147, 641, 642
geniculata, 145, 147, 645, 715
mammillaria (candicantia), 145, 147, 641, 642, 643, 644
quadrigemina, 146, 147, 641, 643, 644, 645, 646, 652, 657, 715
quadrigemina, lesions of, 164
quadrigemina, section through, 150
Corpus ciliare, 462
geniculatum externum (laterale), 641, 642, 643, 644, 646, 657, 715
geniculatum internum (mediale), 150, 641, 642, 643, 645, 657
striatum, 657
subthalamicum, 146, 150
vitreum, 2, 512
Corrosive sublimate as a disinfectant, 233
in operative work, 234
strong solutions of, in purulent conjunctivitis, 330
strong solutions of, in trachoma, 351 *et seq.*
Cortical areas of localization, 156, 157
paralysis of ocular muscles, 164, 165
Crab's-eyes, 367
Cranial nerves, origins of, 152
relations of, at base of brain, 152
Cranium, anatomy of, 145
Crètes' prism, 210

Digitized by Illinois College of Optometry

Crossed cylinders, 118, 128
paralysis of third nerve, 159
Croupous and diphtheritic inflammation, 334
Crura cerebri, 145, 146
Crusta, 146, 147
Crystalline lens (see Lens)
Cul-de-sac, 308
Cuneus, 646, 647, 648, 649, 715
Cupping in ocular paralysis, 166
Curetting of cornea in vascular keratitis, 388
Cyclitis, 407, 464 *et seq.*
plastic, 465, 467
prognosis in, 468
purulent, 467
sero-fibrinous, 465
serous, 442, 466
acute, 466
symptoms of, 466
traumatic, 468
treatment of, 468
varieties of, 466
Cylindrical glasses, 53, 54
Cysticercus cellulosæ, 514, 518
in anterior chamber, 543
in orbit, 735
in vitreous, 514, 518
Cystic tumors of lids, 254
Cystitome, 499
Cystoid cicatrix after iridectomy, 567
Cysts of conjunctiva, 357, 359
of iris, 452
of orbit, 735

Dacryocystitis, 294 *et seq.*, 315
caries in, 295, 296, 305, 306
causes of, 298
diagnosis of, 297
phlegmonous, 295
prognosis in, 298
symptoms of, 295, 296
treatment of, 298 *et seq.*
use of probes in, 299 *et seq.*
Daltonism, 28
Daturia, 240, 241, 243
Decentration of lenses, 202
Decussation of fibres of nuclei of third nerve, 154
of Forel, 150
of Meynert, 150
of pyramids, 146
Delirium after cataract extraction, 232
Dermoid growths of conjunctiva, 359
Descemet's membrane, 371, 373, 377
Descemitis, 407, 442, 575
Detachment of choroid, 588
of retina, 630 *et seq.*
in myopia, 101
pathogenesis of, 632
prognosis in, 634
spontaneous recovery in, 634
treatment of, 634 *et seq.*
Deviation of eyes as a diagnostic feature, 165
Diabetes, 66, 67, 164, 235, 445, 487, 612, 622, 683, 684, 689, 716
mellitus, 163, 479
due to lesion of fourth ventricle, 150
Diachylon ointment, 253
in eczema of lid, 256
Diagrammatic eye of Donders, 15
Dialysis of iris, 520
Dilator pupillæ, 431
Dioptric interval, 56
series, equivalent in inches, 57
Dioptry, 55
Diphtheria, 67, 84, 163, 183, 333, 434, 613, 620, 689
paralysis of accommodation after, 66
Diplococci, 326
Diplopia, due to fracture at apex of orbit, 754
monocular, 697
vertical, 141
Direct method of using ophthalmoscope, 39, 41
Discission in secondary cataract, 508 *et seq.*
Diseases of the eye, general treatment of, 231 *et seq.*
Disinfection, 233
Dislocation of globe, 752
of lens, 473 *et seq.*, 520
congenital, 473, 475
in cataract, 488
traumatic, 475, 477
treatment of, 475 *et seq.*
Dispersion circles, 15
Distichiasis, 261
Distortion of images by cylinders, 128
Dobell's solution, 298
Donders' diagrammatic eye, 15
Double images, 159
after tenotomy, 191
non-recognition of, 160
vision in strabismus, 177
Drusen, 575
Dry cups in myopia, 110
heat, 245
Duboisia, 240, 241
in correction of errors of refraction, 71
in hyperopia, 89
in spasm of accommodation, 65, 66
Dura mater, arrangement of, 654
Dyer's method of systematic exercise of eyes, 219, 220, 223
Dynamic squint, 202 *et seq.*, 215
Dyslexia, 703

Ecchymosis of lids, 280
sub-conjunctival, 368, 519
Echinococcus in orbit, 735
Ectopia lentis, 473, 475
Ectropium, 267
flap operations in, 268 *et seq.*, 271 *et seq.*
hypertrophic, 267

Digitized by Harris Collection of Ophthalmology

Ectropium, mechanical treatment of, 325
stitching of lids together in, 325
treatment of, 268 *et seq.*
Eczema, 256, 315
acute phlegmonous, 365
corneæ, 379 *et seq.*
of lids, 256
Egyptian ophthalmia, 339
Electricity in ocular paralyses, 166
Electrolysis in trichiasis, 262
in vascular tumors of orbit, 738
Electro-magnet in removal of foreign bodies from vitreous, 525 *et seq.*
Embolism, cerebral, 604, 715
in choroid, 576, 584
of central retinal artery, 601, 689
of retinal vessels, 600 *et seq.*
Empyema of orbit, 754, 759
Encanthus, 280
Endocarditis, 584
Enophthalmus, 436, 469
traumatic, 748
Entropium, 262 *et seq.*
after trachoma, 357
operations for, 263 *et seq.*
senile, 263
spasmodic, 263
Enucleation, danger to life after, 545 *et seq.*
in panophthalmitis, 586
in staphyloma of sclera, 428
in sympathetic ophthalmia, 538, 540
of eye, 402
method of operating, 544
of staphylomatous globe, 417
Epicanthus, 280
Epilation, 253, 262
Epilepsy, 64, 175, 435, 660, 688
amblyopia of, 701
of retina, 598
Epiphora, 293, 296
Episcleral tissue, 424
Episclēritis, 425
Epistaxis, 95
Epithelial cancer, 259
disease of conjunctiva, 357, 359
Epithelioma of cornea, 423
Equator, 1
Erysipelas, 315, 395, 584, 671, 676, 689, 729, 730, 731
Eserine, 241
after cataract extraction, 503
and cocaine in glaucoma, 563
in asthenopia, 198
in glaucoma, 563
in muscular asthenopia, 219
in paralysis of accommodation, 67
Esophoria, 214
Ether anæsthesia, 237
inhaler, author's, 238
Ethmoid cells, distention of, 750
fracture of, 757, 759
Evisceratio bulbi, 401, 402
Evisceration, inefficacy of, as a protection from sympathetic ophthalmia, 538
in panophthalmitis, 587
in staphyloma of sclera, 428
in sympathetic ophthalmia, 532, 540, 544
Examination of eye, 35 *et seq.*
anæsthetics in, 37
Excavation of optic nerve in glaucoma, 549, 550, 551, 554, 559
physiological, 555
resembling glaucoma, 556
Excision in trachoma, 350
of apex in conical cornea, 422
of follicles in trichiasis, 262
of pupil, 442, 444, 451
Exenteration (see Evisceration) of orbit, 741
Exophoria, 214
Exophthalmic goitre, 163, 251, 764 *et seq.*
treatment of, 766 *et seq.*
Exophthalmus, 37, 141, 401, 436
pulsating, 743 *et seq.*
treatment of, 747
Expression in trachoma, 352
Eye diseases, relative frequency of, 771
statistics of, 771 *et seq.*
Eye-douches, 244
Eyelashes, 248
diseases of, 261 *et seq.*
evulsion of, 253
Eyelid, chancre of, 358
coloboma of, 280
phlegmon of, 255
vertical division of, in purulent conjunctivitis, 329
Eyelids, 35, 247 *et seq.*
affections of muscles of, 281 *et seq.*
anatomy of, 247 *et seq.*
ecchymosis of, 280
gangrene of, 255
glands of, 250
injuries of, 278 *et seq.*
lacerations of, 278
muscles of, 248 *et seq.*
wounds of, 278 *et seq.*
Eye-shades, 231
Eye-stones, 367

FACIAL and hypoglossal nerves, relations of, 156
nerve, nucleus of, 155
tic, 281
False passage by probe, 301
Far point, 17
Fascia, oculo-orbital, 1, 168, 169, 724
inflammation of, 728
Fasciculus cruciatus, 715
non-cruciatus, 715
opticus, 715
retroflexus, 150
Fever, intermittent, 383, 672
puerperal, 584, 729
recurrent, 66, 67, 584

Digitized by Illinois College of Optometry

Fever, relapsing, 514
scarlet, 67, 183, 315, 584, 613, 615, 616, 620, 672, 689
typhoid, 66, 67, 584, 672, 689
typhus, 383, 672, 689, 729
Fibres of Müller, 463, 594, 617, 620
Fibroid tumors of conjunctiva, 357, 359
Fibroma of choroid, 593
of cornea, 423
Field of vision, 21, 24 *et seq.*, 653
by reduced light, 26
defective, in asthenopia, 216
incorrect projection of, 140
in glaucoma, 549, 550, 551, 554, 555, 559
in optic nerve atrophy, 686, 688, 689
in optic neuritis, 666, 667
in toxic amblyopia, 701
methods of taking, 24 *et seq.*
sector-like defects in, 667, 712
spiral restriction of, 704
temporary limitation of, 182
Fifth nerve, effect of irritation of, on intra-ocular tension, 470
influence of, on intra-ocular secretion, 9
nuclear origin of, 155
Filamentous keratis, 384
Filaria in anterior chamber, 453
Fillet, 148, 150, 643, 646, 657
Filtration angle, 558
First principal focus, 11
Fistula corneæ, 406, 411, 414
lachrymal, 296, 305
Flap extraction, 495
from forehead, 272, 274
from temple, 272
from zygoma, 272, 273
naso-buccal, 272, 273, 274
operation, Knapp's, 273
Wolfe's, 271, 274
operations, author's methods, 272 *et seq.*
in ectropium, 268 *et seq.*, 271 *et seq.*
in symblepharon, 290
with pedicle, 271
Flint's tablets, formula for, 677
Flocculus of cerebellum, 146
Foci of glasses, 55 *et seq.*
Focus, anterior principal, 11
of cornea, 12
first principal, 11
posterior principal, 11
of cornea, 12
principal, of crystalline lens, 12
second principal, 11
Folliculosis, 340, 341
Fontana's canal, 4
Foreign bodies in conjunctiva, 367
in cornea, 523
in globe, 523 *et seq.*
in globe, general considerations, 529
Foreign bodies in orbit, 761 *et seq.*
in vitreous, 523 *et seq.*
in vitreous, statistics of, 528
on conjunctiva, 523
Formatio reticularis, 148 *et seq.*
Form sense, 21
Fornix, 308
Förster's operation for ripening cataract, 494
Fossa patellaris, 472, 512
Fourth ventricle, lesions in vicinity of, 658
Fovea centralis, 5, 595
appearances of, 50, 52
detachment of, 631
minute structure of, 20
vascularity of, 48
Fracture of canalis opticus, 757, 759
of ethmoid, 757, 759
of lamina cribrosa, 757
of orbit, 754 *et seq.*
Frontal bone, anatomy of, 145
sinus, distention of, 749
emphysema, 671, 749
Fundus oculi as seen by ophthalmoscope, 47 *et seq.*
Fungus hæmatodes of eye, 637 *et seq.*

GALVANIC current in paralysis of accommodation, 67
Galvanism in exophthalmic goitre, 766, 767
in muscular asthenopia, 220
Galvano-cautery, 233
Ganglion, ciliary, 17, 424, 432, 464, 724
of Gasser, 9, 145, 146
of Luys, 644, 652
of Soemmering, 146
Gangrene of lid, 255
Gasserian ganglion, 9, 145, 146
Gelsemine, 242
General paresis, 67, 162
Germs in conjunctival sac, 234
Gerontoxon, 410
Glands of Henle, 250
of Krause, 250, 309
of lids, 250
of Moll, 250, 308
Glass, French, German, 56
index of refraction of, 55, 56
shell, after symblepharon operation, 289
Glasses, 53 *et seq.*
arrangement of, 54 *et seq.*
bi-cylindric, 58
blue, in myopia, 111
cataract, 58, 510, 511
colored, 68, 231
after use of atropia, 65
in nystagmus, 175
comparison of old and new systems of numbering, 56, 57
cylindrical, 53, 54
decentering of, 90, 202
effect of change of position on power of, 56, 57

Digitized by Illinois College of Optometry

Glasses, foci of, 55 *et seq.*
for aphakia, 58, 510, 511
Franklinic, 87
hyperbolic, 53
incidental effects of, 131
in paralysis of accommodation, 68
metric system of numbering, 56
nomenclature of, 54 *et seq.*
old method of numbering, 56
properties of, 53 *et seq.*
protective, 231
radii of curvature of, 55
smoked, in myopia, 110
spherical, 53
sphero-cylindric, 59, 118, 128
varieties of, 53 *et seq.*
Glaucoma, 548 *et seq.*, 776
absolute, 551, 553, 567
acute inflammatory, 556
after cataract extraction, 562
anterius, 570
central vision in, 554
chronic, 551 *et seq.*, 556
cocaine in, 236
diagnosis of, 554 *et seq.*
double, 552
etiology of, 557 *et seq.*
hemorrhagic, 553, 607
heredity of, 557
in microphthalmus, 562
in myopia, 549, 569, 570
in second eye following iridectomy on first, 566
iridectomy in, 564 *et seq.*
malignant, 567
operative treatment of, based on pathological examinations, 570 *et seq.*
optico-ciliary neurectomy in, 565
paracentesis in, 570
pathogenesis of, 557 *et seq.*
pathology of, 559 *et seq.*, 570 *et seq.*
prognosis in, 556 *et seq.*
retention theory of, 563
sclerotomy in, 564 *et seq.*
secondarium, 553
secondary degenerations in, 553
simplex, 548
stretching of infra-trochlear nerve in, 566
subacute, 552
subjective symptoms of, 550
symptoms of, 548 *et seq.*
treatment of, 563 *et seq.*
value of operations in, 565, 570
with absence of iris, 562
with deep anterior chamber, 570
with inflammation, 551, 552
Glioma retinæ, 467, 514, 637 *et seq.*
Globe, anatomy of, 1
antero-posterior diameter of, 1
axis of, 1
lymph circulation of, 8
measurements of, 2
nutrition of, 8
Globe, poles of, 1
protrusion of, 37
vessels of, 6
Glycosuria, 672, 700 (see also Diabetes)
Gonococcus of Neisser, 322, 326, 376, 445
Gonorrhœal ophthalmia, 325 *et seq.*
Gout, 378, 445, 449, 557, 570, 606, 677, 692
Graduated tenotomy, 224
Graefe's equilibrium test, 206, 214
Grafting, Reverdin's method, 271
Thiersch's method, 271, 272, 290
Grafts in symblepharon, 290
Granuloma of conjunctiva, 358, 360
of iris, 452
Grattage, Gibson's eversion forceps for, 352, 353
in purulent conjunctivitis, 330, 331
in trachoma, 352 *et seq.*
scarificator for, 352
Graves' disease, 163, 251, 764 *et seq.*
Gray tubercle of Rolando, 155
Gumma of ciliary body, 467
of iris, 443
Gummata, 163
Gummy tumors of conjunctiva, 358
Gun-shot wounds of orbit, 753
Gymnastic prisms, 220, 223

Hallucinations, hemianopic, 712
Halo around macula lutea, 50
in glaucoma, 551, 559
Hebetudo visus, 197
Hebra's ointment in blepharitis, 253
Hemeralopia, 627, 703
Hemi-achromatopsia, 712
Hemiamblyopia, 181
Hemianæsthesia, 162, 657
Hemianopia, 216, 644, 647, 649, 657, 701, 707 *et seq.*
binasal, 707, 709 *et seq.*
bitemporal, 647, 707, 709, 710
boundary line in, 711, 712
central, 707 *et seq.*
cortical, 713, 714
diagnosis of, 715 *et seq.*
due to aneurism of internal carotid, 708
due to lesion of angular gyrus, 714
of calcerine fissure, 714
of chiasm, 709, 710
of crus, 713
of cuneus, 714
of internal capsule, 157, 713
of optic radiations, 714
of orbit, 708
of primary ganglia, 713
of tractus, 712 *et seq.*
due to localized meningitis, 713
tumor at base of brain, 713
epitome of symptoms of (Seguin), 716
for color, 712

Digitized by Illinois College of Optometry

Hemianopia, homonymous, 644, 647, 657
homonymous, lateral, 707, 710
diagram illustrating, 715
homonymous quadrants of, 712
lesions producing, 708 *et seq.*
location of lesion in, 644
monocular, 708
peripheral, 707 *et seq.*
peripheral limitation of visual fields in, 714
prognosis in, 717
pupillary reaction in, 433
treatment of, 717
Wernicke's pupillary symptom in, 708, 709, 713, 714
with retro-bulbar neuritis, 708
Hemianopic hallucinations, 712
Hemianopsia (see Hemianopia)
Hemiataxia, 162, 164
Hemiopic pupillary inaction, 708, 709, 713, 714
Hemiplegia, 64, 157, 159, 162, 175, 469, 657
crossed, 160
Hemorrhage, amblyopia from, 698
beneath conjunctiva, 519
cerebral, 163, 609
following iridectomy for glaucoma, 566, 569
into anterior chamber, 519
into canal of Petit, 513
into choroid, 587
into orbit, 751
into retina, 605 *et seq.*
into sheath of optic nerve, 759
into vitreous, 513, 517, 520
Hemorrhages in myopia, 95, 101
Herpes corneæ, 380, 383
treatments of, 384 *et seq.*
of conjunctiva, 363, 366
zoster frontalis, 315
ophthalmicus, 256, 257, 258, 366, 383
Herpetiform keratitis, 385
Heterophoria, 214
Hexagonal pigment-epithelium of retina, 5
Hippus, 434, 438
Hodgkins' disease, 736
Homatropia, 240, 241
in correction of errors of refraction, 71
in hyperopia, 89
in spasm of accommodation, 68
Hooks, Snellen's, 22
Hordeolum, 253
Horizontal meridian, 1
Horner's disease, 469, 748
muscle, 169, 250
Horny growths, 260
Horopter, 134
Hot applications, 244
in glaucoma, 564
in interstitial keratitis, 393
in iritis, 447, 448
Hot applications in purulent conjunctivitis, 330, 331
Humor, aqueous, 2
vitreous, 2
Hyalitis, 512 *et seq.*
diagnosis of, 515
in soft cataract, 517
prognosis in, 516 *et seq.*
purulent, 513, 514, 517
treatment of, 516 *et seq.*
Hyaloid artery, 8, 512, 513, 518
membrane, 512
Hydrocephalus, 671
internus, 644
Hydrochinon, 233
Hydrophthalmus, 553
in myopia, 102
Hydrotherapy in ocular paralyses, 166
Hyoscine, 240, 241
in spasm of accommodation, 65
Hyperæmia palpebralis, 311, 312
Hyperæsthesia retinæ, 197
Hyperbolic glasses, 421
Hyperesophoria, 214
Hyperexophoria, 214
Hypermetropia (see Hyperopia)
Hyperopia, 69, 82 *et seq.*
anatomical characteristics of, 83
axial, 91
complications of, 86
diagnosis of, 86
extreme, 90
facultative, 84
in strabismus convergens, 179 *et seq.*
mydriatics in, 89
prognosis in, 86
size of image in, 72
statistics of, 90 *et seq.*
treatment of, 87
Hyperphoria, 213, 214, 216, 223, 229
Hypoglossus, relations of, 156
Hypopyum, 375, 440
keratitis, 395, 397 *et seq.*
course and symptoms of, 398
etiology of, 397
treatment of, 398 *et seq.*
Hypotony, 466, 468
Hysteria, 64

Illumination by plane mirror, 36
focal, 35
oblique, 35
Images, determination of size of, 12, 15
produced by glasses, 54
Inch, Austrian, 55
English, 55, 56
equivalent in dioptries, 57
Paris, 55, 56
Prussian, 55
Index of refraction, 10
of cornea, 10, 374
of crystalline lens, 10, 12
of glass, 55, 56
Indirect method of using ophthalmoscope, 40, 42

Digitized by the Illinois College of Optometry

Infundibulum, 641, 642
Injuries of globe, 519 *et seq.*
Inoculation with blenorrhœal pus in trachoma, 354
Insanity, 67
Internal capsule, 146, 148, 157, 657, 715
Inter-pupillary distance, 137, 433
Intra-ocular tension (see Tension)
Inverted image, method of using ophthalmoscope by, 40
Iodine injections in detachment of retina, 636
Iodoform, 233
Iridavulsion, 460
Iridectomy, 245, 454
  cystoid cicatrix after, 567
  explanation of effects of, in glaucoma, 568
  followed by cataract, 567
  for therapeutic purposes, 454
  for visual purposes, 454
  in cataract extraction, 499
  in conical cornea, 421
  in corneal affections, 388
  in corneal opacity, 412
  in detachment of retina, 636
  in glaucoma, 564 *et seq.*
    statistics of, 572
  in iritis, 450, 451
  in pterygium, 370
  in zonular cataract, 492
  instruments, 455, 456
  method of operating, 456 *et seq.*, 569
  value of, in glaucoma, 570
Irideremia, 439
Iridesis in conical cornea, 422
Irido-cyclitis, 465
Iridodesis, 454, 461
Irido-dialysis, 460
Irido-donesis, 439
Irido-rhexis, 454, 460
Iridotomy, 246, 412, 454, 459
Iris, 2, 35, 430 *et seq.*
  absence of pigment in, 439
  anatomy of, 430 *et seq.*
  angle of, 430
  avulsion of, 416
  coloboma of, 439, 775
  complete removal of, 246
  condyloma of, 443
  congenital defects of, 439
  cysts in, 452
  dialysis of, 520
  functional diseases of, 434 *et seq.*
    pathology of, 437
    prognosis in, 437
    treatment of, 437
  granuloma of, 452
  incarceration of, after cataract extraction, 502
  inflammation of, 440 *et seq.*
  lymphomata of, 452
  operations on, 454 *et seq.*
  pigment of, 431
  pillars of, 430
  physiology of, 430 *et seq.*
Iris, prolapse of, 521
    after cataract contraction, 502, 505
  sarcoma of, 452
  sphincter of, 5
  tremulous, 439
  tubercle of, 443, 452
  tumors of, 451 *et seq.*
  vascular growths in, 452
Iritis, 440 *et seq.*
  causes of, 445
  chronic, 450
  complications of, 443
  constitutional treatment of, 448
  following cataract extraction, 506, 507
  gonorrhœal, 445, 449
  gouty, treatment, 449
  gummy, 442, 443
  iridectomy in, 450, 451
  paracentesis in, 447, 450
  plastic, 442
  prognosis in, 446
  quiet, 443
  rheumatic, 443, 445, 447
    treatment of, 449
  sequelæ of, 444 *et seq.*
  serous, 407, 442, 466, 533, 575
  signs of, 440 *et seq.*
  spongy, 442, 570
  suppurative, 442, 443
  traumatic, 442
  treatment of, 446 *et seq.*
  varieties of, 442
Iritomy, 459
  in zonular cataract, 492
Ischæmia of retina, 600

Jaborandi, 241, 242
Jequirity in trachoma, 354, 355
  in vascular keratitis, 388

Karyokinesis, 372, 375
Keratitis, 378 *et seq.*
  bullosa, 385
  dendritica, exulcerans, mycotica, 409
  diffusa, 389 *et seq.*
  filamentosa, 384
  herpetiformis, 385
  interstitialis, 389 *et seq.*
    consecutiva, 386
    etiology of, 389 *et seq.*
    prognosis in, 392
    symptoms of, 390 *et seq.*
    treatment of, 393
  iridectomy in, 388
  malarial, 388, 389
  mycotica, 376, 395
    dendritica, 376, 389
  neuro-paralytica, 395, 402 *et seq.*
  nummularis, 385, 410
  parenchymatosa, 389 *et seq.*
  phlyctenularis, 379 *et seq.*
    treatment of, 381 *et seq.*
  postica, 407 *et seq.*

Digitized by the Illinois College of Optometry

Keratitis, postica, pathology of, 408
scrofulosa, 380
sequelæ of, 411 *et seq.*
subdivisions of, 378
superficialis purulenta discreta, 396
suppurativa, 394 *et seq.*
symptoms of, 378 *et seq.*
vasculosa, 386 *et seq.*
xerotica, 395
zonularis, following glaucoma, 410
Kerato-malacia, 376, 394, 395, 404
Keratoscopy (see Shadow test)
Kidney disease, 609, 612, 613, 615, 616, 620, 621, 622, 688
Kopiopia, 197

Labarraque's solution, 233
in epithelioma, 259
Labio-glosso-laryngeal paralysis, 175
Laceration of choroid, 587
Lachrymal abscess, 295
apparatus, anatomy of, 292 *et seq.*
diseases of, 292 *et seq.*
fistula, 305
gland, 292
diseases of, 293
dislocation of, 294
extirpation of, 307
tumors of, 735
gouge, 303
knife, Agnew's, 299, 300
author's, 299, 300
probes, 299 *et seq.*
sac, 35, 292
abscess of, 295
catarrh of, 294 *et seq.*
chronic distention of, 294
excision of, 303
micro-organisms in, 295
obliteration of, 303, 304
phlegmonous inflammation of, 295, 304
syringing of, 302, 306
trouble, danger from, in cataract extraction, 295
Lachrymation, excessive, 307
Lachrymo-nasal duct, 292
Lagophthalmus, 283
La grippe, 163, 682
Lamina cinerea terminalis, 644
cribrosa, 424, 650
fracture of, 757
fusca, 573
Lanolin, 237
Lead poisoning, 163, 612, 672, 683, 688
Leech, artificial, 243
Heurteloup's, 243
Leeches, 243
in myopia, 109
in ocular paralysis, 166
in spasm of accommodation, 65
Lemniscus, 148, 150, 643, 646, 657
Lens, Brücke's, 36
crystalline, 2, 35, 471 *et seq.*
anatomy of, 471
capsule of, 2
Lens, crystalline, changes in, in accommodation, 17
coloboma of, 473, 474
concussion of, 697
development of, 472
dislocation of, 473 *et seq.*
congenital, 473, 475
in cataract, 488
prognosis in, 475
symptoms of, 474
traumatic, 475, 477
treatment of, 475 *et seq.*
increase of refractive index of, in deeper layers, 15
increase of size of, with age, 561
index of refraction of, 10, 12
luxation of, 520
optical centre of, 12
principal focus of, 12
radii of curvature of surfaces of, 12
removal of, from vitreous, with spoon, 501
sclerosis of, 479, 481, 485
size of, 498
suspensory ligament of, 5, 430, 462, 472, 512
toric, 59
Lenses (see Glasses)
forms of, 54
properties of, 10
Lenticular ganglion, 17
Lepra, 452
Leptothrix lachrymalis, 294, 306, 307
Lesser circles, 1
Leucocythemia, 452, 612, 622
Leucoma, 378
adhærens, 378, 405
corneæ, 411
Ligament, pectiniform, 4
Ligamentum annulare, 6
Light sense, 30
in optic nerve atrophy, 686
streak, explanation of, on retinal vessels, 50 *et seq.*
subjective sensations of, 31
Lightning stroke, loss of sight by, 698
Limbus corneæ, 3, 371
Line of fixation, 178
Lippitudo, 252
Liquor plumbi subacetatis, 253
Listing's reduced eye, 12
Localization, cerebral, 653 *et seq.*
Locomotor ataxia, 66, 67, 162, 434, 436, 645, 686
Long ciliary arteries, 7, 424, 573
Lupoid growths, 259
Lupus non exedens, 259
of conjunctiva, 357, 358, 359
treatment of, 260
Luy's body, 146, 150
Lymph channels of cornea, 8
of eye, 557, 558
circulation of globe, 8
current, intraocular, 8

Digitized by the Illinois College of Optometry

Lymph space, intra-vaginal, of optic sheath, 8
spaces, perivascular, 8
Lymphoid tissue of conjunctiva, 309
Lymphomata, 163
of iris, 452

Macula corneæ, 378, 411
lutea, 5, 595
coloboma of, 105, 597
halo around, 50
vascularity of, 48
Madarosis, 253, 261
Maddox prism, 210, 212
rod, 210, 212
Magnet, Bradford's, 525
Gruening's, 525
Hirschberg's, 525
in removal of foreign bodies from vitreous, 525 *et seq.*
Magnifying power of ophthalmoscope, 42
Malar bone, dislocation of, 754
Malaria, 208, 378, 445
Malarial keratitis, 388, 389
Malingering, 719
Mariotte's blind spot, 181
Massage in cataract, 488
in muscular asthenopia, 219
in retinal embolism, 605
Masturbation, 66
Measles, 183, 315, 613, 620, 672
Measurements of globe, 2
Mechanical exercise in ocular paralyses, 166
Medulla oblongata, 146
anatomy of, 147 *et seq.*
tracts of, 147
"Medusa head" nerve, 614, 663
Megalophthalmus, 775
Megalopsia, 581, 624
Megrims, 598 *et seq.*
Meibomian glands, 250, 308
Membrana limitans, 50
externa, 595
interna, 595
pupillaris perseverans, 439
Meningitis, 163, 516, 665, 672, 673, 675, 676, 689, 715, 718, 730, 740, 742
cerebro-spinal, 672, 673, 676
following enucleation, 545 *et seq.*
tubercular, 163, 671, 672, 677
Menstrual disorders, 95, 609, 612
Mental blindness, 694, 703 (see Mind b. and Psychic b.)
Mercurials in iritis, 448
Meridians of globe, 1
Metamorphopsia, 101, 581, 587, 609, 624, 630, 634, 695
Methyl violet, 234
Metric angle, 203
of convergence, 433
system of numbering glasses, 56
Meynert's bundle, 150
Microbes in conjunctival sac, 234
Micro-organisms in corneal ulceration, 394, 395
in dacryo-cystitis, 295
in pterygium, 369
Microphthalmus, 439, 468, 775
Micropsia, 581, 624
Microsporon trachomatosum, 344
Migraine, 599, 702
Miliary aneurisms of retina, 610
Milium, 260
Mind blindness, 656, 714 (see Mental b. and Psychic b.)
Miner's nystagmus, 174
Mobility of eye, 36
Moles, 261
Molluscum contagiosum, 256, 257
Monocular accommodation, 18
Moon blindness, 704
Motor areas of brain, 156, 157, 654 *et seq.*
tracts, 147 *et seq.*
Mucous patches on conjunctiva, 358
Multiple sclerosis, 164, 672, 683
Mumps, 584
Muscæ volitantes, 100, 486, 513
Muscarine, 242
Muscle, ciliary, 6
of Bowman, 463
of Brücke, 463
of Horner, 169, 250
of Müller, 436, 724, 748
of Riolani, 248
Muscles, methods of testing, 204, 205, 210 *et seq.*
ocular (see Ocular muscles)
of eyelids, 248 *et seq.*
Muscular apparatus, normal status of, 204 *et seq.*
asthenopia, 197, 202 *et seq.*
insufficiency, 202 *et seq.*
general considerations, 206 *et seq.*
vertical, 216, 223, 229
relations, reversal of, for distance and near, 218
Music deafness, 656
Mydriasis, 434
Mydriatics, 240, 241, *et seq.*
danger from, in glaucoma, 564
in astigmatism, 118
in hyperopia, 89
Myelitis, 469
acute, accompanied by optic neuritis, 672, 673
Myopia, 69, 92 *et seq.*
atrophic changes in, 110
axial, 92
cataract in, 101
causes of, 93 *et seq.*
central choroidal changes in, 101
centre of motion in, 102
choroidal changes in, 101, 581
complications in, 97 *et seq.*
congenital, 92, 95, 103
constitutional causes of, 95
detachment of retina in, 93, 101, 110

Digitized by Illinois College of Optometry

Myopia, diagnosis of, 103
due to occupation, 104
functional disturbances in, 96
hemorrhages in, 95, 101, 110
hereditary, 103
hydrophthalmus in, 102
inflammatory, 95, 109
influence of muscles in producing, 94 *et seq.*
in school children, 104
malignant, 581
monocular, 96
muscular asthenopia in, 108
incapacity in, 101
ophthalmoscopic picture in, 96 *et seq.*, 105
optic nerve atrophy in, 582
pathological anatomy of, 96 *et seq.*
prevalence of, 93
prisms in, 109
prognosis in, 102 *et seq.*
prophylaxis, 103
scotoma in, 110
selection of glasses in, 106 *et seq.*
size of image in, 72
slowly progressive, 107
spasm of accommodation in, 104
stationary, 107
statistics of, 103 *et seq.*
tenotomy in, 227
treatment of, 106 *et seq.*
with cataract, 480
Myosis, 434, 435
from irritation of cerebral centre, 435
paralytic, 435, 438
Myotics, 240, 241
general conclusions, 243

Nævi, 260, 261
Nasal catarrh as a cause of asthenopia, 217
duct, 292
catarrh of, 294
obstruction of, 294
stricture of, 299
Near point, 17
Nebula, 278
Needles for advancement, 229
Nerve, optic (see Optic nerve)
Nerves, cranial, 145 *et seq.*
diagram showing origins of, 152
relations of, at base of brain, 152
long ciliary, 425, 432, 433
ocular, 133, 147 *et seq.*
short ciliary, 425, 432, 433
Neuralgia, dental, 66
facial, cocaine in, 237
Neuritis optica, 662 *et seq.*
after orbital affections, 676
albuminurica, 677
anatomical characteristics of, 667 *et seq.*
apoplectica, 665
axial, 678, 679, 680, 681, 683, 684
Neuritis optica, axial, congenital, 686
brain symptoms in, 675
chemical irritation theory of, 674
descendens, 662, 664 *et seq.*
diagnosis of, 675
etiology of, 670
germ theory of, 674
glycosurica, 677
hemorrhagica, 665
idiopathica, 672
interstitialis, 668
monocularis, 664
partial, 662
pathogenesis of, 673 *et seq.*
pathology of, 684, 685
peri-axial, 681
prognosis in, 676
relation of, to intra-cranial disease, 670 *et seq.*
retrobulbaris, 662, 665, 678 *et seq.*, 732
cases of, 680, 681
causes of, 681, 683
due to alcohol, 678, 682 *et seq.*
la grippe, 682
tobacco, 678, 682 *et seq.*
toxic, causes of, 683
opthalmoscopic picture in, 682
treatment of, 682, 684
with hemianopia, 708
subjective symptoms of, 666 *et seq.*
syphilitica, 676
treatment of, 677 *et seq.*
with dropping of fluid from nose, 686
Neuro-retinitis descendens, 662, 664 *et seq.*
following sunstroke, 672
pigmentosa, 629
sympathetica, 535
syphilitica, 623
with brain tumor, 665
Nicotine paralysis, 162
poisoning, 163
Night blindness, 703
Nitrate of silver, 234
in blepharitis, 252
in conjunctival inflammations, 318, 322, 323, 324, 326, 329, 336, 350, 351
in eczema of lids, 256
in lachrymal troubles, 298, 299, 302, 307
in trachoma, 350, 351
Nodal point, 11
of cornea, 12
Nubecula, 378, 411
Nuclear paralysis of ocular muscles, 160, 161, 162
Nuclei of fifth nerve, 155
of third nerve, 152 *et seq.*
Nucleus cuneatus, 148

Digitized by Illinois College of Optometry

Nucleus gracilis, 148
of facial nerve, 155
of sixth nerve, 155
of trochlearis, 153, 154
Nummular keratitis, 385
Nutrition of globe, 8
Nyctalopia, 705
Nystagmus, 173 *et seq.*, 474, 574
etiology of, 174 *et seq.*
in congenital cataract, 484
monocular, 173, 174
treatment of, 175

OBLIQUE illumination, 35
Occlusion of pupil, 442, 444, 451, 465
Ocular muscles, actions of, 133
advancement of, 169 *et seq.*
anatomy of, 132 *et seq.*
diagram of origins of, 755
physiology of, 132 *et seq.*
spasm of, 173 *et seq.*
paralyses, etiology of, 163 *et seq.*
prognosis in, 166
treatment of, 166 *et seq.*
Oculo-motorius, 152
Oculo-orbital fascia, 1, 168, 169, 724
inflammation of, 728
Œdema of retina, 606, 608
Olivary bodies, 146
Opacities in vitreous, 513, 514, 515, 516
Opaque nerve fibres, 597, 658
Operating mask, 239
Operative interference in muscular asthenopia, 224
work, antiseptics in, 234 *et seq.*
general considerations, 238 *et seq.*
Ophthalmia migratoria, 536
neonatorum, 319 *et seq.*
corneal complications in, 324
prophylaxis, 321, 322
Credé's method, 322
statistics of, 321
treatment of, 322 *et seq.*
varieties of, 319, 320
tarsi, 252
Ophthalmomalacia, 466, 468
Ophthalmometer, description of, 123 *et seq.*
Helmholtz's, 16, 378
in detection of conical cornea, 419
of corneal opacities, 378
in determining astigmatism, 121 *et seq.*
Javal's, 70, 103, 357, 378
method of using, 123 *et seq.*
Ophthalmometry, 121, 123
Ophthalmoplegia externa, 155, 160
Ophthalmoscope, 39 *et seq.*
as an optometer, 74
author's, 43, 45
binocular, 44
direct method of employing, 39, 41
in determining refraction, 71 *et seq.*, 121 *et seq.*
Ophthalmoscope, indirect method of employing, 40, 42
magnifying power of, 42
varieties of, 43 *et seq.*
Ophthalmoscopic picture, 47 *et seq.*
Optic centre, 656
centres, primary, 715
chiasm, 145, 147
disc, anatomically oval, 122, 659
congestion of, 611
"woolly," 666, 676
lobes, 715
nerve, 2, 641 *et seq.*
anæmia of, 660
anatomy of, 641 *et seq.*
anomalies of, 105
arrangement of fibres in, 651, 652
atrophies following destruction of, 645
atrophy of, 164, 686 *et seq.*
causes of, 687 *et seq.*
congenital, 609, 687
experimental, 690
from cerebral causes, 689
hereditary, 687
in myopia, 585
interstitial, 690, 691
medullary, 689
morbid anatomy of, 689 *et seq.*
ophthalmoscopic picture in, 686 *et seq.*
parenchymatous, 688
partial, 686
primary, 689
prognosis in, 691
subdivision of, 687
symptoms of, 686 *et seq.*
treatment of, 692 *et seq.*
capillary congestion of, 610
colloid degeneration of, 616
coloboma of sheath of, 105, 658
congenital abnormalities of, 180 *et seq.*, 658
congenital defects of, 180, 658
connective-tissue septa of, 650
crossing fibres of, 643, 647, 651, 652
direct fibres of, 642, 647, 651, 652
diseases of, 653 *et seq.*
emergence of, 147
excavation of, in glaucoma, 549, 550, 551, 554, 559
fasciculi of, 650
hemorrhage into, 660, 661, 663
into sheath of, 661, 662, 759
hyperæmia of, 659
inter-vaginal space of, 650
intra-cranial portion of, 649 *et seq.*
lymph spaces of, 650
macular fibres of, 651
number of fibres in, 651
orbital portion of, 649 *et seq.*

Digitized by Illinois College of Optometry

Optic nerve, physiological excavation of, 555
physiology of, 641 *et seq.*
pupillary fibres of, 651
sheath, 649, 650, 673, 724
dropsy of, 674
inter-vaginal lymph space of, 8
stretching of, in atrophy, 693
tumor of, 734, 736 *et seq.*
wounds of, 696, 760, 761
neuritis (see Neuritis optica)
papilla, 650
colloid bodies in, 669
connective tissue on, 659
radiations, 644, 645, 647, 715
thalamus, 146, 147, 150, 641, 642, 644, 645, 646, 657, 715
tract, 145, 146, 150, 642, 643, 644, 645, 646, 654, 715
arrangement of fibres in, 652
roots of, 644, 645, 646
Optical axis, length of, 13
centre of cornea, 12
of crystalline lens, 12
Optico-ciliary neurectomy, 592, 540, 542
in glaucoma, 565
vessels, 424
Optometers, 80 *et seq.*
Ora serrata, 5, 48, 462, 596
Orbicularis, paralysis of, 283, 294
Orbit, abscess communicating with, 726
abscess of, 731, 732
anatomy of, 144, 249, 722 *et seq.*
axis of, 724
bony tumors of, 736, 739
caries of, 726, 728
cerebral symptoms following injury of, 756
diseases of, 725 *et seq.*
distention of cavities adjacent to, 749
emphysema of, 754
exenteration of, 741
foreign bodies in, 761 *et seq.*
fracture of apex of, 754, 755
fracture of, 520, 695, 696, 754 *et seq.*
gun-shot wounds of, 753
hemorrhage into, 751
injuries of, 66
lesions of, 696
origins of ocular muscles at apex of, 755
penetrating wounds of, 755, 756
periostitis of, 689, 725 *et seq.*
treatment of, 727
phlegmonous inflammation of, 546, 665, 726, 729 *et seq.*
tumors of, 671, 733 *et seq.*
prognosis in, 743
recurrence of, 743
symptoms of, 737
treatment of, 738 *et seq.*
varieties of, 735, 736
Orbit, vascular tumors of, 735, 736, 743, 744, 745
wounds and injuries of, 752 *et seq.*, 759 *et seq.*
Orbital cellulitis, 401, 729 *et seq.*
following evisceration, 546
deep incisions in, 731
effects of, on vision, 732
treatment of, 730 *et seq.*
cysts, 735
fracture, amblyopia following, 757
muscle of Müller, 724, 748
paralyses, 158, 163
symmetrical, 158
periostitis, 689, 725 *et seq.*
tumors, 671, 733 *et seq.*
veins, thrombosis of, 730, 732, 733
Orthophoria, 214
Ossification of choroid, 593
Oxide of zinc, 256
in blepharitis, 252

PACHYMENINGITIS, 163
Painful vision, 197
Palpebral fissure, 247
ligaments, 247
Panas' solution in operative work, 234
Pannus, 338, 346, 352, 377, 387, 388
crassus, 338
tenuis, 338
Panophthalmitis, 401, 402
enucleation in, 586
evisceration in, 587
following discission of cataract, 491
intra-uterine, 775
suppurative, 588 *et seq.*
Papillitis, 616, 662, 663, 664, 666, 667, 668, 669, 670, 671, 673, 674, 675
diagnosis of, 675
etiology of, 670 *et seq.*
relation of, to intra-cranial disease, 670 *et seq.*
with brain tumor, 664
Papilloma of conjunctiva, 357, 358
of cornea, 423
Papillomata, 260
Paquelin's cautery, 233
Paracentesis corneæ, 245, 246, 247
in myopia, 110
effects of, on intra-ocular tension, 9
in conical cornea, 421
in glaucoma, 570
in iritis, 447, 450
Paralexia, 703
Parallax, 75
of vessels in glaucoma, 549
test, 210
Paralysis, bulbar, 162
motor, alternating, 149
nicotine, 162
of accommodation, 66
treatment of, 67
of ocular muscles, 139 *et seq.*
basal, 158
collateral symptoms in, 159

Digitized by Google

Paralysis of ocular muscles, congenital, 173
cortical, 164, 165
diagnosis of, 140 *et seq.*, 158 *et seq.*
diagrams illustrating, 142
etiology of, 163 *et seq.*
intra-cranial, 144
location of lesion in, 144 *et seq.*,
nuclear, 160 *et seq.*
peripheral, 163
position of head in, 140
prognosis in, 166
recurrent, 158
rheumatic, 158, 163
sub-cortical, 464, 165
symptoms of, 139 *et seq.*
treatment of, 166 *et seq.*
of orbicularis, 283, 294
of superior oblique, 196
of third nerve, crossed, 159
orbital, 158, 163
Paraphasia, 656
Paraphimosis, 325
Paresis of accommodation, 66
treatment of, 67
of ocular muscles, 139 *et seq.*
Pars non plicata of ciliary body, 462
Pars plicata of ciliary body, 462
Partial tenotomy, 224, 226, 227
Pectiniform ligament, 4, 373
Pediculus pubis, 261
Peduncles, 145 *et seq.*
of cerebellum, 147
Pedunculus cerebri, 641, 643, 645
Pemphigus of conjunctiva, 362, 366
of cornea, 385
Perimeter, 25, 26
forms of, 25
Schweigger's hand, 653
Perineuritis, 662, 665
following meningitis, 673
Periostitis of orbit, 689, 725 *et seq.*
Peripheral paralyses of ocular muscles, 163
Peritomy in trachoma, 354
in vascular keratitis, 388
Perivasculitis, 687
Pernicious anæmia, 609
Pes pedunculi, 146, 147, 150
Petit's canal, 8
Phantom image of retinal vessels, 32
Phenacetine after tenotomy, 227
Phlebitis of ophthalmic vein, 746
of retinal vessels, 603
Phlegmon of lid, 255
of orbit, 729 *et seq.*
Phlyctenular conjunctivitis, 363, 364
keratitis, 379 *et seq.*
Phorometer, 210, 211, 213
Phosphorus in muscular asthenopia, 219
poisoning, 612
Photometer, 31
Photophobia, 87
cocaine in, 381
Phtheiriasis, 261
Phthisis, 437, 766
bulbi, 406, 466
essential, 470
Physiology, general, of eye, 10 *et seq.*
of brain, 653 *et seq.*
of conjunctiva, 308 *et seq.*
of cornea, 374 *et seq.*
of iris, 430 *et seq.*
of ocular muscles, 132 *et seq.*, 134
of optic nerve, 641 *et seq.*
Pigment patches in conjunctiva, 357, 360
proliferation in choroiditis, 577
Pigmentation of retina, 50
Pilocarpine, 241
constitutional effects of, 242
hypodermic injection of, 242
in asthenopia, 198
in muscular asthenopia, 219
in myopia, 109
in paralysis of accommodation, 67
injections in detachment of retina, 635
Pince-ciseaux of Wecker, 459, 492
Pineal gland, 148
Pinguecula, 360
Pink eye, 315
bacillus of, 315
Pituitary body, 146, 642
Placido's disc, 126, 378, 419, 420
Pleurisy, 435
Plica semilunaris, 308
Pneumonia, 672
Poles of globe, 1
Polio-encephalitis, 164
Polycoria, 440
Pons Varolii, 145 *et seq.*
anatomy of, 147 *et seq.*
lesions of, 149, 160, 161
Pooley's operation for ripening cataract, 494
Posterior chamber, 2, 430
ciliary arteries, 6, 573
perforated space, 146, 642
principal focus, 11
Poultices, 244
Powder burns, 278, 523
Pregnancy, amblyopia of, 701
Pre-lachrymal abscess, 306
Presbyopia, 61 *et seq.*
reserve accommodation in, 62
selection of glasses in, 61 *et seq.*
Pressure, effects of, on intra-ocular tension, 9
Primary ganglia, 709
Principal meridians, 1
point, 11
Prism, Crètes', 210
dioptry, 59, 201
holder, 210, 213
pile, 210, 211
Prisms, 53, 59
angle of deviation of, 59
refraction of, 59
degree of displacement by, 59
in muscular asthenopia, 223

Digitized by Illinois College of Optometry

Prisms, in myopia, 109
in ocular paralysis, 167
linear displacement by, 59
nomenclature of, 59, 201
properties of, 198 *et seq.*
Probe, author's, 302
Becker's conical, 299
Bowman's, 302
false passage by, 301
perforated, 302
Theobald's, 301, 302, 303
Weber's conical, 301
Williams', 301
Probes in dacryocystitis, 299 *et seq.*
Prothesis oculi, 768 *et seq.*
Protrusion of globe, 37, 141, 401, 436
Pseudo-glioma, 516, 585
Psychic blindness, 649, 654, 655, 656, 657, 703 (see Mental b. and Mind b.)
Pterygium, 368 *et seq.*
change of corneal curve by, 370
crassum, 368
following scleritis, 426
micro-organisms in, 369
pathology of, 369
removal of, before cataract extraction, 487, 496
tenue, 368
treatment of, 369 *et seq.*
Ptosis, 289, 469
as a symptom of sympathetic disease, 287
congenital, 160
double, 164
nuclear, 160
due to lipomata, 287
in trachoma, 343
in tumors of orbit, 753
operations, 285 *et seq.*
partial, 357
single, 160
treatment of, 285 *et seq.*
Pulsation of retinal arteries, 598
vessels, 51
in glaucoma, 549, 554
Pulvinar, 146, 147, 641, 642, 644, 657, 715
Puncta lachrymalia, 247, 292, 293
eversion of, 294
stoppage of, 294
Punctum agendi, 89, 205
proximum, 17
remotum, 17
Puncture of cornea, 245, 246, 247
Pupil, 2, 35
consensual action of, 433
contraction of, 431, 435
in accommodation, 433
in convergence, 432, 433
diameter of, 432, 433
dilatation of, 431, 433
exclusion of, 442, 444, 451
extensive adhesions of, 450
in glaucoma, 549, 551, 559
in various diseases, 434 *et seq.*
occlusion of, 442, 444, 451, 465
Pupil, reflex action of, 433, 434, 435
seclusion of, 465
Pupillary centre (cerebral), 432
reaction in hemianopia, 433
reaction, 645
Pupiloscopy (see Shadow test)
Purkinje's images, 16, 472, 474
Pustular ophthalmia, 380
Pyoktanin, 234
Pyorrhea, 319

QUININE amblyopia, 700

RABBIT'S conjunctiva transplantation of, 290
Rachitic teeth, 483
Radiating visual fibres of Gratiolet, 644, 645, 646, 647, 715
Radii of curvature of glasses, 55
of surfaces of crystalline lens, 12
Radix descendens, 645, 646
Rami communicantes, 6
Range of accommodation, 17 *et seq.*
table showing, at different ages, 18
Recurrent paralysis of ocular muscles, 158
Red nucleus, 146, 150, 658
Reduced eye of Listing, 12
Refraction, correction of, in muscular asthenopia, 220, 221
Cuignet's test for, 76
errors of, 69 *et seq.*
Schmidt-Rimpler's test for, 71
Refractive errors, diagnosis of, 70 *et seq.*
index (see Index of refraction)
Relative accommodations, 18 *et seq.*
Resorcin, 233
Respiratory centre, 150
Retina, 2, 5, 594 *et seq.*
anæmia of, 598
anæsthesia of, 216, 704
anomaly of vessels of, 49
blood-vessels of, 49
capillary aneurism of, 606
cerebral layers of, 595
cystoid degeneration of, 560, 632
detachment of, 630 *et seq.*
diagnosis of, 633
etiology of, 632
evacuation of fluid in, 111
in myopia, 93, 101, 110
pathogenesis of, 632
prognosis in, 634
treatment of, 634 *et seq.*
diseases of, 597 *et seq.*
epilepsy of, 598 *et seq.*
epithelial layer of, 595
functions of, 20
glioma of, 467, 514, 637 *et seq.*
hexagonal pigment epithelium of, 5, 595
hyperæmia of, 597

Digitized by the Boston Medical Library Consortium

Retina, hyperæsthesia of, 197, 204, 705 *et seq.*
hysterical, 706
ischæmia of, 600
laceration of, 631, 633
layers of, 594 *et seq.*
miliary aneurisms of, 610
minute anatomy of, 594 *et seq.*
œdema of, 606, 608
after blows, 612
Purkinje's phantom image of vessels of, 32
sclerosis of, 626
serous effusion in, 611
structure of, 20
torpor of, 703, 704
visibility of, dependent on pigment, 49
whitish opacity of, after blows, 695
Retinal arteries, spasm of, 598 *et seq.*
hemorrhage, 605 *et seq.*
in new-born children, 606, 608
phlebitis, 603
reflexes, 50
vessels, influence of cervical sympathetic on, 598, 599
spasm of, 702
Retinitis, 610 *et seq.*
acute traumatic, 612
albescens punctata, 626
albuminurica, 613 *et seq.*
cause and development of, 615
diagnosis of, 615
induction of labor in, 621
in pregnancy, 615
pathology of, 617 *et seq.*
prognosis in, 616
statistics of, 616
treatment of, 621
apoplectica, 607 *et seq.*
centralis, 611
circum-papillaris, 662, 665
circumscripta, 625
due to oxaluria, 626
phosphorus poisoning, 626
etiology of, 612
glycosurica, 622
hemorrhagica, 607 *et seq.*, 622
leucocythæmica, 622
pigmentosa, 579, 626 *et seq.*
diagnosis of, 628
field of vision of, 627
ophthalmoscopic picture in, 50, 627 *et seq.*
pathology of, 626 *et seq.*
prognosis in, 629
subjective symptoms, 627
treatment of, 629
plastica, 611
proliferans, 514, 612
purulenta, 612
simplex, 613
splenica, 606
symptoms of, 610 *et seq.*
syphilitica, 623 *et seq.*
prognosis in, 626
treatment of, 625
visual disturbance in, 624
traumatica, 695
Retino-choroiditis, 535
Retinoscopy (see Shadow test)
Rheumatic paralysis of ocular muscles, 158, 163
Rheumatism, 66, 95, 235, 445, 449, 570, 606, 677, 681, 692, 725
Rickets, 483
Rods and cones, 20, 595
Rupture of choroid, 520

Saemisch's incision in hypopyum keratitis, 400
in ulcus rodens, 406
Sarcoma of choroid, 592, 593, 632, 639
of conjunctiva, 359
of cornea, 423
of iris, 452
Scalping of lids, 267
Scarification in purulent conjunctivitis, 329, 330
in trachoma, 347, 352
Scarpa's nail, 302
Scheiner's test, 81 *et seq.*
Thomson's modification of, 70, 81 *et seq.*, 121, 420
Schematic eye, 13
measurements of, 13
Schlemm's canal, 4, 6, 8
Sclera, 1, 3, 424 *et seq.*
anatomy of, 424
staphyloma of, 427
Scleral puncture in detachment of retina, 635
ring in glaucoma, 551
Scleritis, 425 *et seq.*
circumscripta, 426
diffusa acuta, 426
Sclero-choroidal ring, 559, 560
Sclero-keratitis, 427
Sclerosis, cerebro-spinal, 66
disseminate, 67, 175
of cornea, 410
of lens, 479, 481, 485
Sclerotica (see Sclera)
Sclerotomy, 245, 416, 538
in glaucoma, 564 *et seq.*
posterior, 566, 567
Scotoma, 31, 609, 625, 629
absolute, 181
central, 604, 605, 606, 623, 667, 678, 679, 686, 689, 700
for color, 28, 89, 181, 622, 667, 678, 679, 681, 684, 686, 689, 700
in glaucoma, 555
in myopia, 110
negative, 31, 625
paracentral, in glaucoma, 555
peripheral, 678, 688
positive, 31, 625
ring-shaped, 625, 627, 629, 680, 684
scintillans, 702
temporary, 182

Digitized by Illinois College of Optometry

Scotomata in glaucoma, 549, 555, 559
Scrofula, 445, 483, 692, 725
Scrofulous teeth, 391
Seclusion of pupil, 465
Second principal focus, 11
sight, 63, 480
Secondary deviation, 139
Secretory angle, 8
Sella turcica, 145
Semilunar fold, 169
Sensitive nerves, effects of irritation of, on intra-ocular tension and pupil, 9
Sensory crossing, 148
tract, 148
Septicæmia, 729
Shadow test, 70, 76 *et seq.*, 86, 103, 121 *et seq.*
Short ciliary arteries, 6, 573
Shot-silk appearance of retina, 610
Shrinking of tissues after trachoma, 357
Simple optical system, 11
Sinus, cavernous, 144, 145
circular, venous, 4
Sinuses, cerebral, 145
Sixth nerve, nucleus of, 155
Skiascopy (see Shadow test)
Skin diseases, 256
Skin flaps, 271 *et seq.*
grafts, 271 *et seq.*
transportations, 271
Snow blindness, 389, 704
Spasm of accommodation, 63, 68, 215
causes of, 64
diagnosis of, 65
in myopia, 104
methods of detecting, 210, 215
treatment of, 65
of muscles in muscular asthenopia, 225, 227
of ocular muscles, 173 *et seq.*
of orbicularis, 281
Speech area, 657
motor, 656
Sphenoidal fissure, 144, 145
Spherical glasses, 53
Sphincter iridis, 5
special nucleus for, 432
pupillæ, 431
Spinal cord, amblyopia in concussion of, 696
columns of, 146
decussation of fibres of, 148
disease, 162, 692
in ocular paralyses, 164
effect of irritation of, on intra-ocular tension, 9
effect of section of, on intra-ocular tension, 469
irritation of, 64
lesions, 688
meningitis, 434
Staphyloma, 406
intercalary, 427
of cornea, 411, 414
excision of, 417 *et seq.*
Staphyloma of cornea, treatment of, 416 *et seq.*
of sclera, 427, 467
treatment of, 428
pellucidum, 419
posterior, 97 *et seq.*
Stenopaic slit, 411, 420
spherical lens, 210
Stereoscope, practice with, after tenotomy, 191
Stimulating applications in muscular asthenopia, 220
Stokes' lens, 118
Strabismus, 177 *et seq.*
alternating, 177
bilateral, 177
concomitans, 177
convergens, 177
classification as to refraction, 185
in hyperopia, 85
relation of abduction to adduction in, 182 *et seq.*
course of, 184 *et seq.*
deorsum-vergens, 177, 196
divergens, 177
in myopia, 186
operation for, 191
etiology of, 179
in myopia, 94
intermittent, 177, 196
method of operating for, 188 *et seq.*
method of measuring, 178, 179
monolateral, 177
operative treatment of, 187 *et seq.*
paralyticus, 177
periodic, 195
permanent, 177
phenomena of vision in, 183 *et seq.*
statistics, 182 *et seq.*
sursum-vergens, 177, 196
treatment of, 186
varieties of, 177
Stratum zonulare, 643, 644
Stretching of infra-trochlear nerve in glaucoma, 566
Striped keratitis, 507
Strumous ophthalmia, 380
Strychnia in muscular asthenopia, 219
in ocular paralyses, 166
in spasm of accommodation, 65, 66
Stye, 253
Style, 302
Sub-conjunctival ecchymosis, 368
Sub-cortical lesions, 157
paralysis of ocular muscles, 164, 165
Subjective sensations of light, 31
Sublatio retinæ, 630
Sub-retinal effusion in choroiditis, 580
Substantia nigra, 146, 148, 150
Sulcus orbito-palpebralis, 248
palpebro-malaris, 248
Sulphur as a disinfectant, 233
Sunstroke followed by neuro-retinitis, 672
Superior oblique, paralysis of, 196

Digitized by Google

Suppression of image, 137
in strabismus, 184
Supra-choroidea, 8, 559
Supratraction of choroid, 97 *et seq.*
Suspensory ligament of lens, 5, 430, 462, 472, 512
Symblepharon, 288 *et seq.*
operation, Arlt's, 289
Knapp's, 290
Teale's, 290
skin flaps in, 290
skin grafts in, 290
transplantation of rabbit's conjunctiva in, 290
treatment of, 289 *et seq.*
Sympathetic, cervical, effect of division of, on pupil, 438
on secretion of aqueous, 9
effect of irritation of, on pupil, 436, 438
section or paresis of, on intra-ocular tension, 469
effect of lesions of, 748
influence of, on intra-ocular tension, 8, 9
on pupil, 9
on retinal vessels, 598, 599
irritation of, 64
lesions due to disease of, 436 *et seq.*
symptoms of irritation of, 436
inflammation (see Sympathetic ophthalmia)
irritation, 64, 531, 532, 533
ophthalmia, 531 *et seq.*, 776
after ciliary wounds, 522
causes of, 531
ciliary nerve theory of, 536, 537
enucleation in, 538
evisceration in, 532, 540, 544
following cataract extraction, 505, 531
germ theory of, 536, 537
injections of corrosive sublimate into vitreous in, 541
irritative, type of, 532, 533
mode of transmission of, 536 *et seq.*
pathology of, 535 *et seq.*
period of latency in, 532
prognosis in, 533
statistics of, 532
treatment of, 538 *et seq.*
Synchisis, 513
scintillans, 513
Syndesmitis, 311
Synechia, anterior, 405
posterior, 440, 441, 444, 449, 450
totalis, 465
Syphilis, 66, 67, 162, 235, 256, 285, 304, 378, 389, 390, 391, 392, 403, 445, 448, 483, 517, 570, 577, 579, 580, 583, 606, 611, 612, 623, 624, 625, 628, 637, 672, 676, 681, 683, 692, 715, 718, 725, 728, 749
Syphilis, as a cause of ocular paralyses, 163
sloughing of flaps in, 268
Syphilitic lesions of conjunctiva, 357, 358
teeth, 391
ulcerations, 259
Syringe, use of, in cataract extraction, 494, 500

Tabes dorsalis (see Locomotor ataxia)
Tactile bodies of Krause, 310
Tapetum, 574
Tarsitis, 255
Tarsoraphy, 278, 284
Tarsus, 247
inflammation of, 255 *et seq.*
subcutaneous division of, 357
Tattooing in conical cornea, 421
of cornea, 412, 413, 461
Tegmentum, 146, 148, 643
Teleangiectatic tumors, 260
treatment of, 260, 261
Tendo oculi, 293
Tenonitis, 158, 728
Tenon's capsule, 1, 168, 169, 424
advancement of, 190
Tenotomy, graduated, 224
improvement of vision after, 193 *et seq.*
in muscular asthenopia, 224 *et seq.*
in myopia, 227
in nystagmus, 175
in ocular paralyses, 167 *et seq.*
in strabismus, 188 *et seq.*
instruments for, 188 *et seq.*
mechanism of, 192 *et seq.*
partial, 224, 226, 227
ultimate results of, 192 *et seq.*
Tension, intra-ocular, 8, 9, 548
determination of, by manometer, 9
effect of irritation of fifth nerve on, 470, 557
effect of mydriatics on, 240
effect of section of cord on, 469
effect of section or paresis of cervical sympathetic on, 469
examination of, 36
in cataract, 480
in detachment of retina, 633
in glaucoma, 548, 551, 554
methods of reducing, 246
nervous control over, 8, 9
periodic variation of, in glaucoma, 549
Tensor choroideæ, 463
Tentorium cerebelli, 145
Test letters, order of legibility of, 23
Test types, 22 *et seq.*
Burchardt's, 23
Green's, 22, 23
Little's, 117
Monoyer's, 22, 33
Pflüger's, 23
Pray's, 121

Digitized by Illinois College of Optometry

Test types, Snellen's, 22, 23, 24, 33
Tests for simulated blindness, 720, 721
Thalamus opticus (see Optic thalamus)
Theobald's hooks for tenotomy, 189
Third nerve, decussation of fibres of nuclei of, 154
nuclei of, 64, 152 *et seq.*
Thrombosis of cavernous sinus, 730, 732, 733, 744
of orbital veins, 730, 732, 733
of retinal vessels, 600 *et seq.*
Thymol, 233
Tobacco amblyopia, 28, 435, 678, 682 *et seq.*
Toric lenses, 59
Tortuous scleral vessels in glaucoma, 549, 551, 559
Trachoma, 337 *et seq.*
actual cautery in, 233, 350, 354, 356
acute, 340
cantholysis in, 354, 357
canthoplasty in, 356, 357
canthotomy in, 354
chronic, 340, 342
coccus, 340, 344
conditions favoring, 338 *et seq.*
contagiousness of, 339
corneal irregularity after, 357
curetting of cornea in, 354
duration of, 343
excision in, 350
expression in, 348 *et seq.*
follicular, 340, 341, 348
forceps, author's, 348, 349
Knapp's roller, 350
Prince's ring, 350
geographical limitations of, 338, 339
grattage in, 352 *et seq.*
hygienic conditions in, 350, 351
hypertrophic, 343
inoculation with blenorrhœal pus in, 354
isolated deposits of, 342
jequirity in, 354, 355
lymphoid infiltration in, 342
micro-organisms in, 339, 340, 344, 351
mixed, 342, 351
papillary, 340, 348
pathological anatomy of, 344 *et seq.*
peritomy in, 354
prophylaxis, 347
ptosis in, 343
racial susceptibility to, 339
sequelæ of, 340, 343, 344, 357
strong bichloride solutions in, 351 *et seq.*
subdivisions of, 337, 338, 340
treatment of, 347 *et seq.*
vegetable fungus in, 344, 345
Tractus opticus (see Optic tract)
Transverse axis, 1
Tremulous iris, 439
Trephining in conical cornea, 422
Trial cases, 54
varieties of, 57
frames, 58
glasses, 38
Trichiasis, 261, 262
after trachoma, 357
partial, 262, 264
treatment of, 262 *et seq.*
Trichinosis, 66
Trigeminus, motor root of, 146
Trochlearis nucleus, 153, 154
Tuber cinereum, 146, 641, 642, 644
Tubercle of choroid, 578, 588
of cornea, 423
of iris, 443, 452
Tubercular disease of conjunctiva, 357, 358
Tuberculosis, 445, 589, 715, 718
Tumor of brain (see Brain tumor)
of cerebellum, 671, 675, 709
of choroid, 589 *et seq.*
diagnosis of, 591
prognosis in, 592
treatment of, 591
of iris, 451 *et seq.*
of optic nerve, 734, 736 *et seq.*
of orbit, 671, 733 *et seq.*
prognosis in, 743
recurrence of, 743
symptoms of, 737
treatment of, 738 *et seq.*
vascular, 735, 736, 743, 744, 745
Turkish bath, 242
in muscular asthenopia, 219
Tylosis, 253, 261
Tyrrell's hook in iridectomy, 412

Ulcers of cornea, 405 *et seq.*
Ulcus corneæ serpens, 377, 395, 397 *et seq.*
rodens, 377, 406
Unstriped fibres of Müller, 251
Uræmic blindness, 616
Uterine disease, 84, 127, 208, 672, 677, 683, 689
Uvea, 6, 424, 430, 431, 573
Uveitis anterior, 407 *et seq.*, 442, 466
maligna, 531
serosa, 442, 531, 533, 534, 575

Valve of Vieussens, 146
Varicella, 315
Variola, 315, 445
lesions of eye in, 365
Vascular growths in iris, 452
Velum medullare anticum, 146
Venæ vorticosæ, 573
Venous pulsation, 598
in glaucoma, 549, 554
Ventricle, third, 145, 146
Verbal deafness, 656
Vernal catarrh of conjunctiva, 362, 363, 409
Vertical axis, 1
meridian, 1

Digitized by Illinois College of Optometry

Vertical muscular insufficiency, 216, 223, 229
Vessels of globe, 6
Vision, average, 21, 22
effect of illumination on, 23, 24
sudden obscurity of, in glaucoma, 551
Visual acuity, 21, 24, 37, 70
improved by glasses, 90
normal, 21
peripheral, 26
apparatus, scheme of central, 646
area, 647, 649
diagrams showing, 648
centres, 647, 653, 654
primary, 645
field (see Field of vision)
image, suppression of, 137, 184
line, 14, 178
memories, 649, 654, 714
path, anatomy of (see Hemianopia)
purple, 32 *et seq.*, 595
radiations, 644, 645, 646, 647, 715
rose, 32
Vitreous, 2, 512
artificial, 418, 769
blood-vessels in, 514
body (see Vitreous)
cholesterin in, 513
connective tissue in, 513
cysticercus in, 514, 518
degeneration of, in myopia, 101
detachment of, 513
fluid, 513
in choroiditis, 578, 581
foreign bodies in, 514, 518, 523 *et seq.*
hemorrhage into, 513, 517, 520
humor (see Vitreous)
inflammation of (see Hyalitis)
Vitreous, membranes in, 514, 517, 520, 581
opacities, 513, 514, 515, 516
in choroiditis, 581
prolapse of, 515, 522
pus in, 513, 514, 517

WARTS, 260
Watch-glass in purulent conjunctivitis, 332
Wecker's scissors, 459, 492
in secondary cataract operations, 510
Wernicke's pupillary symptom, 708, 709, 713, 714
Wharton Jones' sliding flap, 268, 270
White precipitate ointment, 256
Whooping cough, 383, 600
Word blindness, 657
deafness, 656
Wounds and injuries of orbit, 759 *et seq.*
of globe, 519 *et seq.*
complicated, 523 *et seq.*
of optic nerve, 760, 761

XANTHELASMA, 256, 257
Xeroma, 356
Xerophthalmus, 361
Xerosis, 342, 344, 360 *ei seq.*
idiopathic, 361

YELLOW ointment in blepharitis, 252, 253
oxide of mercury, 234
spot, 5
vascularity of, 48

ZONA ophthalmique, 257
Zonula of Zinn, 5, 6, 43, 462, 472

Digitized by Illinois College of Optometry

Digitized by Illinois College of Optometry

INDEX OF AUTHORS.

Abadie, 75, 224, 352, 541, 566
Adamück, 635
Agnew, 84, 169, 173, 232, 296, 299, 303, 476, 505, 509
Alexander 392, 445
Alt, 370, 464, 468, 470, 532, 535, 536, 561, 665, 669
v. Ammon, 270, 276, 281
Anagnostakis, 263, 266
Andrews, 500, 545, 736
Angelucci, 601, 603
Annuske, 671
Argyll-Robertson, 435, 688
Arlt, 95, 248, 264, 267, 289, 365, 386, 390, 397, 441, 443, 483, 534, 545, 635
Arnaut, 351
Aschmann, 760
Atkinson, 700
Aub, 695
Aubert, 21, 25, 32, 216
Ayers, 32, 33, 423

Badal, 80, 566
Bartholow, 766
Bärwinkel, 469
Batten, 95
Baumann, 745
Baumgarten, 359
Bechterew, 155
Becker, 2, 16, 33, 48, 244, 299, 472, 511, 545, 546, 589, 591, 599, 765
Benedict, 673
Benson, 545
Berger, 657, 666, 711, 757
Berlin, 104, 131, 511, 524, 603, 612, 695, 703, 735, 739, 751, 754, 756, 758, 759
Bernhardt, 671
Bernheimer, 643
Berry, 555, 632
Berthold, 435
Bezold, 361
Bibber, 287
Birdsall, 155
Birnbacher, 560
Bjerrum, 31, 555
Bock, 513
Boè, 541
Boland, 697
Boll, 32
Bonnet, 224
Bouchut, 664
Bouillaud, 656
Bowman, 120, 299, 302, 371, 372, 373, 422, 461, 474, 494, 508, 539, 635
Bradford, 525
Brailey, 487, 531, 535, 536, 576, 635
Bremer, 773
Brettauer, 488
Broca, 656, 657
Brugger, 386
Brunner, 700
Budge, 436
Bulkley, 765
Bull, C. S., 166, 256, 306, 358, 359, 362, 476, 502, 557, 568, 570, 572, 616, 637, 638, 666, 671, 709, 728, 736, 739
Bull, Ole B., 623, 679
Buller, 332, 698
Bunge, 544, 545, 586, 595, 596, 651, 685
Burchardt, 23
Burke, 44
Burnett, 14, 30, 201, 230, 339, 371, 374, 664
Burow, 80

Carl Theodor, Herzog, 97, 100, 620,
Carmalt, 640
Carron du Villard, 745
Carter, 492, 761, 770
Cattell, 23, 24
Chamberlain, 244
Charcot, 645, 697, 701, 714
Cheatham, 355
Chibret, 339, 401, 402
Chisholm, 505, 672
Claude-Bernard, 438
Coccius, 16, 559
Cohn, 6, 22, 93, 103, 104, 107, 310, 344, 347, 366, 447, 535, 771
Collins, 163, 165, 166, 362, 439, 464, 466, 470, 473, 474, 559, 561, 562, 563, 570, 571
Conheim, 589, 608
Cooper, White, 366
Coppez, 355
Coppin, 636
Couper, 43
Courtaix, 705
Credé, 322, 775
Critchett, 169, 329, 335, 418, 422, 461, 532, 539, 562
Cross, 532, 540, 544, 770
Cuignet, 76, 86, 103, 121, 702
Culver, 12
Cunier, 224
Cusco, 44
Czermak, 384, 385, 560

Digitized by Illinois College of Optometry

Da Gama Pinto, 375, 407, 639
Dagunet, 259
Dalrymple, 736
Dana, 658, 675, 697
Davis, 51
De Beck, 358
Dechambre, 184
Decker, 385
Déjérine, 657
Delafield, 638
Dennett, 201, 202
Derby, H., 24, 94, 540, 629
Derby, R. H., 255, 335
De Schweinitz, 201, 403, 440, 604, 613, 623, 667, 700
Desmarres, 254, 460
Despagnet, 705
Deutschmann, 326, 535, 536, 537, 541, 545, 674, 675
Dianoux, 264
Dickinson, 615
Dieffenbach, 188
Dimmer, 51, 576
Dobrowlsky, 83, 86, 114
D'Oench, 545
Donaldson, 649
Donders, 9, 15, 17, 18, 19, 29, 30, 51, 83, 84, 85, 90, 91, 93, 100, 102, 112, 115, 128, 134, 178, 179, 180, 184, 197, 250, 411, 472, 532, 536, 555
Dracoulidès, 533
Dransart, 636
Duane, 219
Duchenne, 162
Dunglison, 367
Dunn, 705
Dürr, 104
Dyer, 25, 219, 220

Eales, 604
Earles, 615
Edes, 672
Edinger, 147, 151, 153, 154, 155, 645
Edmunds, 671, 673, 674
Elsching, 588
Ely, 705
Emmert, 64, 241, 375, 389, 409, 765
Eperon, 196
Erb, 672
Erichsen, 697
Erisman, 107
Etters, 164
Eulenberg, 438
Eversbusch, 431, 658
Exner, 657

Ferguson, 123
Ferrier, 157, 165, 656
Fick, 26, 112, 284
Fieuzal, 664
Filehne, 684
Fischer, 691
Fisher, 605
Fitzgerald, 766
Flarer, 264
Flemming, 372, 375
Flint, 334
Fontan, 162, 408
Forel, 150
Förster, 25, 26, 31, 157, 494, 580, 625, 683, 711
Foster, F. P., 307
Foster, M., 34, 645
Franke, 447
Fränkel, 589
Freyer, 330
Fries, 698
Frost, 534
Fuchs, 93, 104, 105, 164, 254, 370, 385, 431, 465, 557, 561, 589, 590, 591, 592, 684, 776

Galezowski, 162, 349, 506, 622, 636, 665, 688, 704, 705
Galleuga, 557
Garlick, 671
Garnier, 736
Gaule, 403
Gauss, 12
Gayet, 234, 264, 505
Geissler, 488
Genth, 667
Gerhardt, 437
Gerlach, 6, 169, 472
German, 345
Gessner, 749
Gibson, 352
Gifford, 536, 537, 558, 605
Giraud-Teulon, 44, 58, 74
Goldzieher, 164, 536
Gowers, 160, 161, 165, 175, 281, 282, 284, 598, 603, 622, 645, 664, 667, 674, 697, 699, 712, 766
Gradle, 210
Graefe, v., 2, 19, 80, 95, 97, 139, 154, 158, 159, 160, 184, 187, 189, 192, 202, 205, 213, 214, 224, 225, 240, 243, 263, 297, 307, 333, 337, 360, 382, 383, 400, 410, 422, 423, 461, 470, 488, 490, 495, 505, 548, 555, 562, 564, 565, 566, 567, 569, 572, 600, 601, 623, 635, 660, 674, 679, 695, 764, 767
Graefe, Alfred, 175, 182, 184, 196, 224, 362, 540, 544, 545, 586, 600, 635, 720
Grahamer, 775
Graser, 240
Gratiolet, 644, 645
Gray, 692
Green, John, 22, 33, 57, 59, 118, 192, 240, 265, 266, 267, 507, 510
Griffith, 593, 730
Groenow, 711
Grossmann, 328
Grosz, 636
Gruening, 191, 236, 287, 354, 525, 566, 569, 570, 665, 700, 737
Grünhagen, 431, 557
Gudden, 154, 643, 644, 645, 646, 647, 652, 690, 715
Guérin, 224
Gunn, 545
Guthrie, 745

Digitized by Illinois College of Optometry

Haab, 376, 383, 395, 589, 646
Haas, 696
Hall, 154
Haltenhoff, 315
Hamilton, 176
Hancock, 568
Hansen, 195
Hansen-Grut, 376, 389, 409
Harlan, 196, 290, 321, 702, 721, 744
Hasner, 385, 386
Haussmann, 321, 775
Hay, 421
Heil, 473
Heisrath, 352
Helmholtz, 16, 20, 21, 39, 112, 378, 472
Henle, 145, 146, 148, 309
Henschen, 647, 648, 649, 651, 652, 657, 675, 708, 709, 711, 713, 714, 718
Hensen, 438
Herter, 672, 703
Hess, 385
Hewitt, 758
Heyl, 330
Heymann, 765
Higgins, 403, 635
Hilbert, 255
Hildebrand, 528
Hippel, 94, 104, 348, 351, 352, 403, 422, 557
Hirschberg, 29, 80, 178, 179, 241, 321, 360, 365, 422, 447, 518, 525, 528, 538, 539, 605, 606, 616, 622, 635, 638, 672, 697, 699, 773
Hirshfeld, 337
Hjort, 16
Hock, 679
Holden, 689
Hölder, 695, 751, 758
Holmes, 737
Holmgren, 29
Holtz, 672
Höltze, 240
Horner, 28, 93, 110, 169, 287, 321, 361, 363, 364, 366, 374, 377, 380, 383, 384, 390, 392, 395, 397, 436, 438, 450, 452, 469, 470, 491, 632, 700, 748
Horsley, 157, 164
Horstmann, 2
Hotz, 265, 266, 267, 287
Howard, 163
Howe, 339, 621, 775
Hubbell, 156
Hughes, 587
Hulke, 666
Hun, 648, 718
Hunnius, 165
Hutchinson, 66, 257, 390, 392, 394, 437, 438, 443, 579, 583, 616, 683, 705

Iodko, 700
Isler, 185
Iwanoff, 83, 380, 632, 665

Jaarsma, 241
Jackson, E., 43, 201, 612
Jackson, Hughlings, 664, 671, 673
Jacobson, 337, 560
Jaeger, 2, 96, 97, 99, 580, 582, 613, 690
Jaesche, 264
Janeway, 176, 283, 766, 767
Jany, 406
Jatzow, 710
Javal, 55, 56, 70, 74, 103, 104, 114, 116, 121, 123, 124, 126, 184, 192, 357, 378, 419, 557, 562
Jeffries, B. Joy, 30, 259
Jeffries, J. A., 165
Johnson, G. Lindsay, 594
Johnson, W. B., 736, 737
Jones, Wharton, 268, 270
Juler, 335

Kahler, 152, 153
Kalish, 488
Kansocki, 343
Katz, 773, 776
Kendall, 366
Kerschbaumer, 502
Kipp, 388, 389, 518
Klein, 293, 372
Knapp, H., 58, 113, 190, 192, 196, 254, 260, 273, 290, 350, 401, 418, 442, 476, 501, 502, 509, 525, 557, 581, 589, 590, 600, 603, 638, 684, 695, 700, 710, 728, 730, 737, 739, 740, 750, 758
Knapp, P. C., 697
Knies, 8, 152, 153, 154, 157, 164, 361, 362, 403, 442, 536, 560, 561, 652, 654
Köhler, 744, 747
Koller, 235, 635
Kölliker, 472, 595
Kollock, 361
König, 29
Königshofer, 24
Krause, 542, 651
Krenchel, 195
Kubli, 362
Kühne, 32, 33
Kuhnt, 595, 673
Kuschbert, 361

Laker, 558, 689
Landesberg, 386, 733, 773
Landolt, 12, 13, 14, 18, 27, 83, 91, 103, 178, 179, 182, 184, 202, 203, 225, 241, 330, 701
Lang, 717, 770
Lange, 470
Langley, 30
Laqueur, 125, 557, 563
Laurence, 307
Lawford, 671
Lawson, 278, 532, 538, 539
Leber, 4, 6, 48, 361, 374, 384, 395, 535, 536, 541, 542, 561, 622, 626, 627, 632, 633, 634, 666, 673, 674, 675, 679, 684, 686, 687, 698, 699, 701, 705, 736
Lebrun, 495
Leconte, 32
Leeser, 434
Lennox, 472
Leube, 162

Digitized by Illinois College of Optometry

Liddell, 737, 738
Liebreich, 44, 105, 495, 597, 598, 602, 622, 631, 684
Lippincott, 494, 500
Listing, 12
Litter, 699
Loiseau, 76
Loring, 39, 43, 45, 48, 50, 51, 57, 96, 103, 104, 105, 168, 227, 360, 459, 510, 511, 597, 601, 604, 605, 608, 613, 621, 622, 623, 673, 701
Luys, 644, 652

Mackenzie, 536, 548, 736, 750
Maddox, 202, 210, 212
Magnus, 155, 432, 436, 601, 602, 661, 664, 718, 771, 773, 776
Manby, 766
Mandelstamm, 698
Manz, 597, 623, 673
Marchand, 712
Marpman, 234
Mascart, 80
Mathewson, 259, 666, 671
Mathiessen, 113
Mauthner, 17, 23, 56, 63, 158, 159, 161, 163, 392, 532, 538, 605, 708
McHardy, 25
McKeown, 494, 525
Meigs, 608, 621
Meissner, 134
Merkle, 2, 132, 471, 755
Meyer, Adolf, 576
Meyer, E., 271, 540
Meynert, 150, 643, 644, 645, 646, 652, 657, 715
Michel, 156, 166, 340, 344, 469, 550, 577, 578, 588, 589, 590, 598, 603, 605, 620, 626, 652, 684, 689, 703, 717, 736, 737
Miles, 534
Mills, 157, 165
Minor, 388, 684
Mitchell, Weir, 117, 438, 709
Mittendorf, 241, 243
Möbius, 437, 438
Monoyer, 22, 33
Moore, 315, 621, 701, 702
Mooren, 66, 377, 383, 389, 392, 406, 495, 557, 626, 672
Morton, 474
Motais, 168, 169, 546
Mules, 418, 482, 545, 603, 605, 769
Müller, 436, 536, 559, 561, 576, 724, 748
Munk, 165, 649, 703
Muttermilch, 344, 345

Nagel, 2, 18, 23, 55, 56, 65, 80, 82, 97, 202, 203, 433, 692
Natanson, 562
Naumhoff, 606, 608
Neese, 528
Neisser, 322, 361, 376, 445
Nettleship, 43, 48, 49, 77, 80, 333, 335, 336, 410, 540, 545, 570, 579, 580, 583, 602, 604, 605, 651, 666, 680, 684, 685, 687, 691
Neumann, 334
Nicati, 438, 464, 469
Niedeke, 536
Nieden, 217, 744, 747, 749
Noiszewski, 344
Nordenson, 633
Norris, 237, 710, 712, 713
Nothnagel, 159
Nuel, 385

Obersteiner, 147, 155
Obriga, 165
Oeller, 673
Ogle, 438
Oglesby, 174, 175
Ohlemann, 538
Oliver, 28, 121, 709, 713, 714
Oppenheim, 697
Oppenheimer, 382, 776

Pagenstecher, 561, 664, 667, 668, 730
Panas, 234, 500, 501, 531
Parinaud, 664, 673, 674
Passavant, 449
Pell, 164
Perlia, 152, 153, 154, 161
Perrin, 80
Peters, 708
Peterson, 166
Pflüger, 23, 160, 570
Pick, 152, 153
Picquè, 675
Plehn, 80, 81
Pollak, 479
Poncet, 596, 622, 632, 690
Pooley, 494, 526, 534, 621, 664, 736
Pope, 265
Porteau, 438
Porterfield, 81
Posch, 24
Pray, 121
Prentice, 59, 201, 203
Prevost, 165
Prince, 169, 173, 350, 370
Prout, 254, 260, 362
Purkinje, 32, 472, 474
Purtscher, 659

Querenghi, 432, 433, 464

Raab, 639
Raehlmann, 175, 341, 343, 344, 362, 421, 434
Randall, 83, 90
Randolph, 536, 537
Ranney, 209
Recklinghausen, 765
Reich, 341, 344, 664, 671, 697
Reid, 344
Reinhardt, 647
Reiss, 700
Reuss, 2
Reute, 39
Reverdin, 271
Richet, 271

Digitized by Illinois College of Optometry

Ring, 505
Risley, 487
Rivington, 744
Robin, 174
Rockwell, 767
Rohmer, 541
Rood, 32, 431
Roosa, 57, 85, 252, 355, 452, 700
Ross, 165, 436
Rossander, 532
Ruppell, 447
Rushmore, 255
Ryerson, 370

Saemisch, 264, 377, 395, 400, 406, 409, 601, 602
Salzer, 651
Salzmann, 26
Samelsohn, 367, 651, 678, 701
Sands, 601
Sanson, 474
Sargent, Elizabeth, 606
Sattler, 340, 344, 348, 356, 376, 406, 573, 576, 744, 745, 746, 747, 765, 766
Savage, 212
Schaefer, 157, 164, 165
Schapringer, 748
Scheiner, 70, 81, 121, 420
Schell, 182, 183, 287
Schiess, 540, 544, 545, 636, 639, 737
Schiess-Gemuseus, 474, 532, 537, 736
Schiff, 175
Schirk, 25
Schirmer, 85, 252
Schlaefke, 744
Schmeichler, 435
Schmidt, 604, 615
Schmidt-Rimpler, 71, 76, 337, 406, 651, 673, 708, 773
Schnabel, 96, 443, 514
Schöbl, 372
Schoeler, 8, 9, 163, 321, 636, 637
Schoen, 51, 374, 560, 562, 574
Schueller, 51
Schulten, 8
Schultze, 20
Schwalbe, 4, 250, 372, 431, 512, 604, 650, 673, 724
Schweigger, 26, 84, 181, 182, 183, 185, 194, 197, 447, 501, 503, 505, 532, 541, 543, 555, 556, 561, 566, 601, 653, 711, 718
Scott, 158
Seabrook, 488
Seeligmüller, 438
Seggel, 23, 24, 91, 94, 160, 440, 679, 759
Segger, 182
Seggert, 22
Seguin, 672, 709, 715, 716, 718
Seidelmann, 773
Sichel, 635, 736
Siemerling, 152, 155
Silex, 597
Smith, Priestley, 25, 26, 63, 179, 216, 238, 472, 477, 479, 560, 561, 562, 567, 568, 571, 603, 604, 605, 662, 666, 668
Snellen, 21, 22, 33, 80, 254, 260, 265 267, 290, 535, 561, 562, 572, 721, 765
Soemmering, 146, 150
Sous, 80
Spaulding, 534, 535, 730
Spitzka, 147, 154, 155
Starr, 147, 148, 149, 152, 153, 157, 161, 438, 654, 657, 701, 702, 703, 718
Steffan, 672
Stellwag, 338, 380, 410, 673, 764, 765
Stevens, 25, 172, 210, 213, 216, 218, 224, 226, 229, 330
Stewart, 216
Stilling, 8, 30, 92, 94, 95, 99, 301, 401, 558, 645, 650, 672, 679, 721
St. John, 174, 528
Stolte, 772
Stölting, 560
Story, 51, 766
Straub, 160, 736
Strawbridge, 423, 737
Streatfield, 265, 449
Stricker, 20
Stromeyer, 395
Strumpel, 697
Sturm, 113
Sulzer, 571
Swanzy, 165, 264, 435, 718
Symons, 392
Sziklai, 242

Tangeman, 513
Tay, 583
Teale, 290
Terson, 452
Theobald, 189, 301, 302, 303, 475, 699
Thiersch, 271, 272, 290
Thomson, 30, 70, 81, 82, 121, 420
Trousseau, 510
Truc, 339
Tscherning, 92, 93, 103
Tweedy, 317
Tyrmann, 666, 757
Tyrrell, 329

Uhthoff, 159, 161, 651, 679, 682, 685, 687, 773
Ulrich, 86, 182, 183, 186, 667

Van Aurep, 243
Van Duyse, 506
Vetsch, 363, 638
Volkers, 438
Vossius, 343, 372, 651, 665, 672, 678, 685, 730, 736, 737

Wadsworth, 39, 182, 615, 616, 639
Wagner, 644
Walter, 632
Walton, 656
Warlomont, 76
Weber, 169, 301, 560, 561, 567
Webster, 531, 535, 545
Wecker, 169, 173, 190, 224, 264, 287, 354, 355, 413, 492, 501, 510, 541, 565, 635, 693

Digitized by Illinois College of Optometry

Wedl, 513, 559
Weeks, 315, 323, 617, 620, 622, 682
Weigert, 334
Weiss, 84, 97, 98, 99, 102, 589
Wells, 736
Wernicke, 148, 164, 165, 665, 703, 708
White, 604, 766
Wicherkiewitz, 570
Widmark, 355, 704
Wiethe, 709
Wilbrand, 182, 216, 438, 704, 708, 709, 710, 711, 712, 713, 714, 717, 718
Wilde, 163, 165, 166
Willemer, 735, 737
Williams, E., 301, 399, 401, 529, 534
Williams, H. W., 174, 301
Williams, R., 707
Wilson, 328
Woinow, 30, 178, 432
Wolfe, 271, 274, 635, 636
Wolfheim, 736
Wolfring, 337
Wreden, 732, 733

YOUNG, THOMAS, 118

ZEHENDER, 141, 698, 736
Ziegler, 589, 699
Zimmerman, 691

Digitized by Illinois College of Optometry

Digitized by Illinois College of Optometry

Digitized by Illinois College of Optometry

PLATE IV.

Digitized by Illinois College of Optometry

LINDNER, EDDY & CLAUSS, LITH. N. Y.

Digitized by Illinois College of Optometry

Digitized by Illinois College of Optometry

Digitized by Illinois College of Optometry

PLATE V.

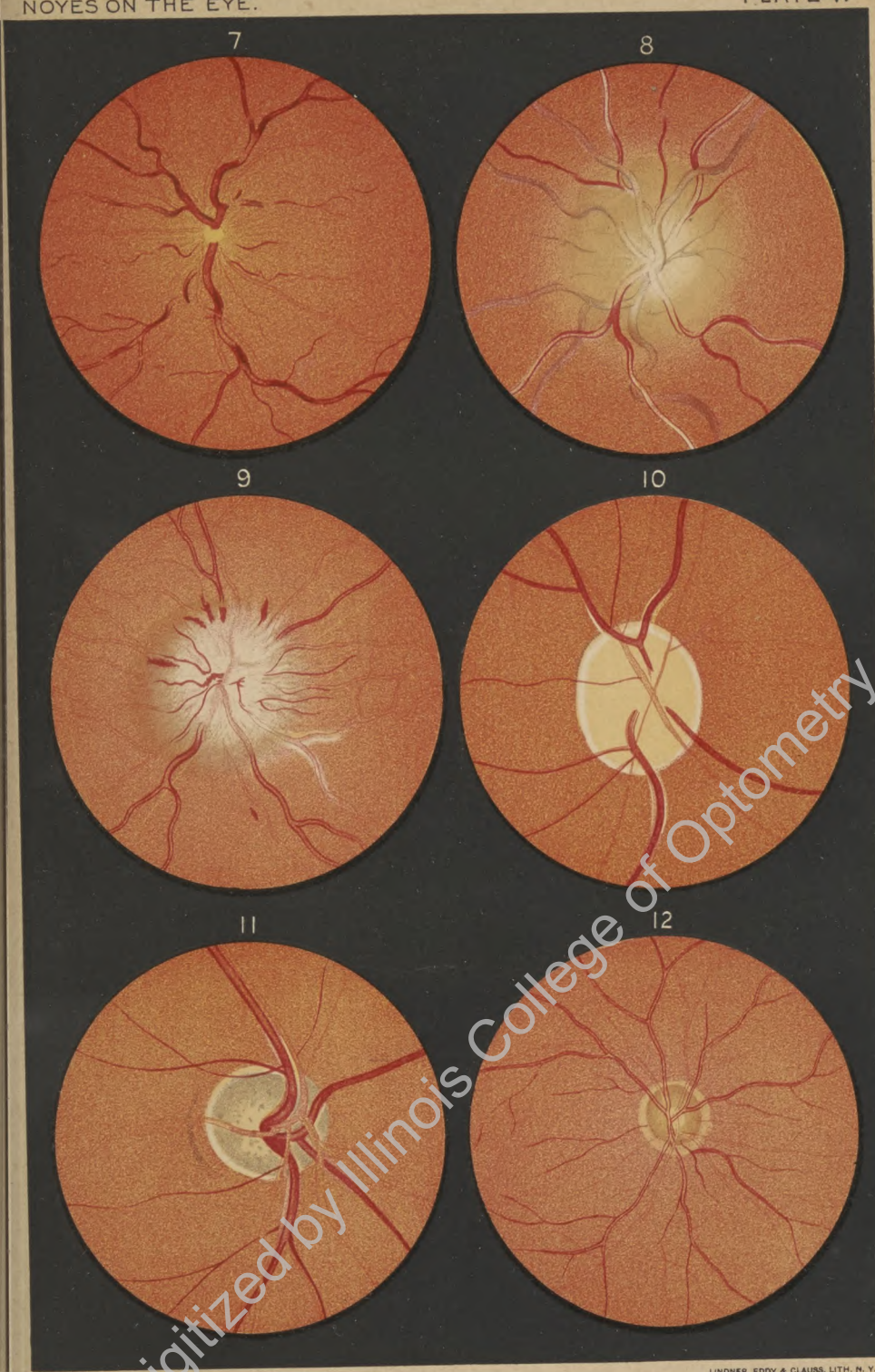

LINDNER, EDDY & CLAUSS, LITH. N. Y.

Digitized by Illinois College of Optometry

Digitized by Illinois College of Optometry

Digitized by Illinois College of Optometry

Digitized by Illinois College of Optometry

LINDNER, EDDY & CLAUSS, LITH. N. Y.

Digitized by Illinois College of Optometry

Digitized by Illinois College of Optometry

Digitized by Illinois College of Optometry

Digitized by Illinois College of Optometry

PLATE VII.

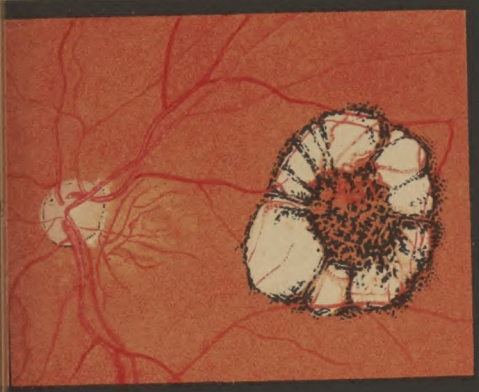

23

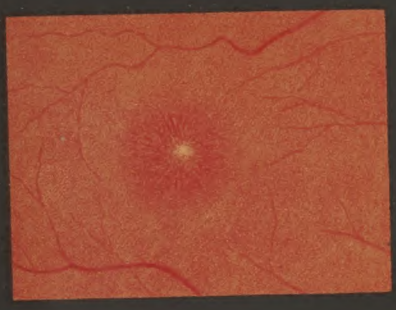

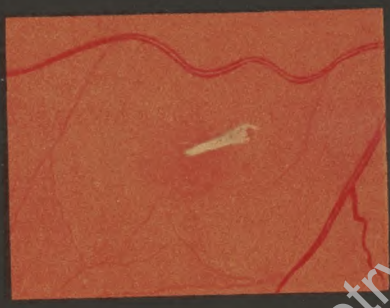

24

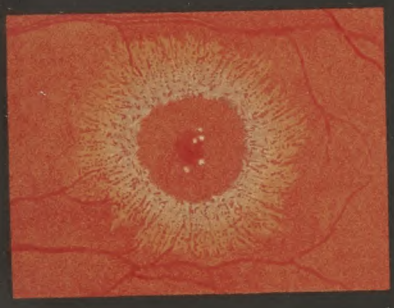

25

26

Sackett & Wilhelms Litho Co N.Y.

Digitized by Illinois College of Optometry

Digitized by Illinois College of Optometry

DESCRIPTION OF CHROMO-LITHOGRAPHS.

FIG. 1.—Normal fundus oculi: moderate degree of pigment. Jaeger.

FIG. 2.—Atrophy of optic nerve and retina. Jaeger, Pl. x., fig. 50. Man, 25. No perception of light; cause obscure. Had frequent and severe headaches, repeated attacks of intermittent fever. Blindness within nine months. Disc slightly excavated, color grayish-green, texture somewhat opaque. Retinal arteries very small, with thickened walls, veins disproportionately large, and both they and the arteries bordered with white lines of connective tissue.

FIG. 3.—Neuro-retinitis apoplectica. Jaeger, Pl. xiv., fig. 65. Man, 53. V = perception of light. Trouble of sight gradually coming on for months, grew suddenly worse within a week, just recovered from *delirium tremens*. Nerve deeply red, œdematous, outline obliterated. Arteries very small, thready; veins flexuous, large, their tortuosity often in the vertical plane, as indicated by the darker and fainter portions of the curves; numerous hemorrhages in streaks proceeding from capillaries and small vessels. Retina œdematous, especially near the disc.

FIG. 4.—Retinitis albuminurica. Man, 19. Nerve a little flushed, but practically normal. The region of the macula surrounded by numerous brilliant, glistening, white spots arranged in a somewhat radiating manner. Among them a few pigment specks. In the vicinity are other similar white spots less distinct. (Amount of albumin very large, was dropsical.) Retina otherwise normal, vessels normal.

FIG. 5.—Myopia, with congenital excavation of optic nerve, etc. Jaeger, Pl. xxvii., fig. 119. Man, 21. Myopia—$\frac{1}{3}$. Depth of excavation not given, but it covers the entire surface of the nerve and the vessels are pushed to the nasal side. The pigment epithelium has disappeared from the surface of the choroid over the lower part of the fundus, exposing its vessels. Ten years later it is said no other change had occurred than the removal of the pigment epithelium over the whole fundus; vision continued nearly normal. The case presents all the signs of glaucomatous excavation in a myopic eye. No mention is made whether arteries would pulsate under light pressure.

FIG. 6.—Atrophy of optic nerve. Jaeger, Pl. x., fig. 51. Woman, 46. Erysipelas of face five weeks previous, severely affecting the lids and orbital tissues. V=0; the eye normal. Atrophy succeeding neuro-retinitis. Nerve opaque, retinal arteries either obliterated or reduced.

FIG. 7.—Neuro-retinitis serosa. Jaeger, Pl. xiii., fig. 62. Woman, 27. Loss of sight following childbirth; suffered extremely from headache, health very poor. History does not indicate cerebral tumor. Other eye has similar condition in less degree; nerve swollen, deeply red, infiltrated, outline abolished; optic fibres conspicuous as radiating lines. Arteries small; veins engorged, very tortuous.

FIG. 8.—Papillitis with both serous and plastic infiltration of the nerve. Swelling very marked, edge blurred and diameter increased; arteries very tortuous, marked by infiltration; veins swollen, very dark. Lesion confined chiefly to nerve, sometimes called "choked disc." Condition found in cerebral tumor.

FIG. 9.—Papillitis with more intense plastic infiltration than in Fig. 8, attended by hemorrhages in both nerve and retina. Striation of nerve strongly pronounced.

FIG. 10.—White atrophy of optic nerve following meningitis. Liebreich. Female, 19. Nerve white, opaque, border sharply defined and exhibiting a distinct scleral ring, shallow excavation. Arteries small; veins broad, not tortuous, bordered for short distance from disc with connective tissue.

FIG. 11.—Gray atrophy of optic nerve following tabes dorsalis. Liebreich. Man, 40. Absolute blindness. Nerve grayish, slightly excavated, border sharply defined, tissue opaque, lamina cribrosa distinct; arteries small; veins broad. (Atrophy of nerve with spinal-cord lesion does not invariably present the gray color of this picture.)

FIG. 12.—Atrophy of optic nerve and retina. Jaeger, Pl. ix., fig. 48. Female, 46. Became blind after successive childbirths, each attended by several hemorrhages. For six years had the usual appearances of simple white atrophy (see Fig. 10), but after an illness, which seems to have been meningitis, further degeneration took place in the optic nerves, giving rise to its peculiar hue of gray yellow-green, with dense opacity and slight excavation. Vessels much attenuated.

FIG. 13.—Colloid deposits upon optic nerve and on the adjacent retina. Lawson, Trans. Oph. Soc. United Kingdom, vol. iii., Pl. viii., fig. 1. Man, 23. Had syphilitic choroido-retinitis with pigment patches at periphery; retina hazy, floating bodies in vitreous. The masses consist of white, translucent, beaded-like bodies heaped together to the height of 2.5 D. On the nerve they are less individualized and of duller hue. Spangles of cholesterin occur on the surface. There has been neuritis. (See p. 563, where a similar deposit is referred to after neuro-retinitis.)

FIG. 14.—Colloid deposits in region of macula. Nettleship, Trans. Oph. Soc. United Kingdom, vol. iv., Pl. ii., fig. 2. Female, 41. $V=\frac{20}{20}$ Hm. 5D. Had no power of accommodation, spots grayish yellow, some better defined than others, none sharply cut. "The most defined ones are surrounded by a shaded gray ring, such as might be produced by a slightly prominent nodule." This statement describes the true growth and character of these formations. Compare Fig. 194, p. 526.

FIG. 15.—Tubercles of choroid and neuritis optica. Male. Trans. Oph. Soc. United Kingdom, vol. iv., p. 160. Girl, 10. Acute miliary tuberculosis, and double optic neuritis. Course of disease very rapid, viz., 14 days from apparent beginning of illness. Some 8 to 10 nodules present, yellowish-white at centre, shading into color of normal choroid, in which they were imbedded; three of them beneath retinal vessels. At autopsy abundant tubercles in lungs, kidneys, liver, and spleen, and scattered in the vessels in the Sylvian fissure. Attempt to discover bacilli in the choroidal tubercles did not succeed, while giant cells and patches of retrograde tubercle were easily detected. The eye lesions resemble closely the early stage of choroiditis disseminata, and are to be certainly distinguished only by the general symptoms of the case.

Digitized by Illinois College of Optometry

FIG. 16.—Syphilitic retinitis with hemorrhages and new blood-vessels in the vitreous. Nettleship, Trans. Oph. Soc. United King., vol. iv., p. 150. Had chancre a year previously and secondary symptoms. Had iritis, hyalitis, hemorrhage into retina both at periphery and about macula. From edge of nerve, which was pale and hazy, a flat, transparent, vascular membrane grew out into the vitreous, its vessels looped and numerous, and one large one formed its anterior free border. At a later time more vessels developed. After a year, the vitreous became clear, the hemorrhages were absorbed, the vascular membrane remained. $V=\frac{20}{100}$.

FIG. 17.—Retinitis (after possible embolism). Jaeger, Pl. xv., fig. 70. Man, 32. Had had some rheumatic pains for six months. Had insufficiency of the mitral valve and slight contraction of the left auriculo-ventricular opening. Five days before examination, at 9 A.M., the left eye became suddenly and completely blind as by a black cloud coming over it, without pain or other symptoms. There is no perception of light. Other eye normal. A faint grayish haze overspreads the optic nerve and the surrounding retina for a distance beyond the macula, it follows the principal vessels going up and down, but it gradually fades out toward the periphery. All the blood-vessels are pervious, but reduced in size—it is not stated whether by pressure the blood current could easily be stopped—at the macula a minute red spot said to be a hemorrhage (?). The periphery of the optic nerve very red, at its centre a physiological excavation. Two and a half months later there was complete atrophy of the nerve, retinal vessels still more reduced, and bordered by connective tissue, giving the appearance seen in Fig. 6. The diffused opacity had disappeared. The suddenness of the attack, the instant and permanent blindness, the kind of diffused opacity, the minute red spots, near, if not in the fovea centralis (as is probable), and the consecutive atrophy suggest embolism, and to this the signs of heart disease add further probability. The partial continuance of the retinal circulation and the absence of any unusual co-ordinate vessels make it probable that the stoppage of the arteria centralis was incomplete, although sufficient to destroy the function of the retina. On this subject see p. 548 and Fig. 202.

FIG. 18.—Case of epithelioma, which, beginning upon the lower lid, after many years invaded the conjunctiva bulbi and the cornea, and compelled evisceration of the orbit. The ulceration of the skin has been replaced by cicatricial tissue, the eyelids shrunken and adherent to the globe, and the new growth covers the outer and lower part of the cornea, as an exuberant granulating mass.—Noyes.

FIG. 19.—Extra papillary coloboma. Dr. G. L. Johnson, *Archiv f. Augenheilkunde*, XXI., 291, 1890. This picture represents what by some is called coloboma at the macula, and is one of a series of plates of cases which are interpreted to be congenital defects and not illustrations of choroido-retinitis. In his description, Dr. J. speaks of the white annular patch subdivided by lines of pigment which concentrate upon a central red mass of choroidal vessels and pigment, which he likens to a nævus of the skin. The visual field excessively small, viz. $30° \times 23°$ $V=\frac{6}{36}$. No central scotoma. The sclera is exposed, and its excessive whiteness is thought by Dr. J. to distinguish cases of coloboma from atrophy due to choroiditis, in which he says a yellowish tinge will be found. He also claims that the deposition of pigment above rather than below the retinal vessels is distinctive. The paper is worthy of study, and if one does not concur fully in the interpretation of the cases, the subject is ably handled. The picture from this point of view has peculiar interest. See Loring, "The Ophthalmoscope," Vol. I., p. 95. Most observers would class the cases as instances of choroiditis congenita.

FIGS. 20, 21, 22, 24, 25, from Dr. G. Lindsay Johnson, *Archiv für Ophthal.*, XXI., p. 1, 1892, represent various appearances found at the macula lutea in normal eyes. Fig. 20 is the usual picture—not intending to mean that the fine radiating red streaks around the fovea are blood-vessels, but the dark coloration often present. Fig. 21 presents an annular halo of reflection seen most perfectly by the inverted image, but also visible in the upright method. It flickers and changes its breadth as the light falls in different directions. The yellowish dots grouped in and around the fovea are quite common, do not affect vision, and are probably colloid. Fig. 22 is an illustration of an extreme degree of surface reflection from a large region near the macula. Such a picture is found in dark eyes and in young subjects. The evanescent glittering quality of the appearance cannot be perfectly rendered, but is fairly suggested. Again the same yellow dots appear at the fovea, which is deep red rather than yellow. Note the shading along the retinal arteries as evidence of the unusual amount of connective tissue. Fig. 24 is meant to show an elongated reflex proceeding from the fovea, and which will change both length and direction as the point of view varies. Fig. 25 considerably resembles Fig. 21, but is far less frequent. The ring is to be interpreted in both figures as being a reflex from an annular elevation of the retina. The crescent at the fovea is not an uncommon type of reflex. (See p. 47.)

FIG. 23 —Neuro-retinitis from thrombosis.—Noyes. The picture was drawn about a week after the onset of sudden blindness. The nerve is swollen, infiltrated, marked by a hemorrhage, the arteries slender, the veins turgid. Exudation, which at the outset covered most of the central part of the fundus, appears now in masses between the nerve and the macula, and follows as well as conceals the vessels. It also extends on the nasal side in small patches and in a general infiltration. The fovea is cherry red. The distinction from embolism is in the continuance of a feeble circulation instead of its entire suspension, in the absence of the white infiltration surrounding the fovea on all sides, and in the papillitis and hemorrhages. Central vision was at first almost abolished. When the drawing was made V = fingers at 3 feet. Visual field at the first barely included the macula and comprised a narrow ellipse reaching out on the temporal side to about 40°. This increased about 10° in all directions after the lapse of a week.

FIG. 26.—Vaccinia of the eyelids, girl five years old, in the fifth day of the eye affection and ten days after vaccination on the arm. In a week the crusts had fallen, the ulceration healed, the lid normal. At no time was the cornea implicated, and the conjunctiva but slightly. The sore on the arm was very large and phlegmonous.—Noyes. (See Zimmermann, *Archiv für Ophthalmology*, XXI., p. 215, 1890.)

Digitized by Illinois College of Optometry

Digitized by Illinois College of Optometry

Digitized by Illinois College of Optometry

Digitized by Illinois College of Optometry

Glaucoma 554

Digitized by Illinois College of Optometry

107164

RE
46
.N8
1896

14014

Digitized by Illinois College of Optometry

Digitized by Illinois College of Optometry